



Archived at the Flinders Academic Commons:

<http://dspace.flinders.edu.au/dspace/>

This is the published version of this article.

The original is available at:

<http://content.karger.com/ProdukteDB/produkte.asp?doi=10.1159/000338627>

Please cite this as: Wang, B. Z., Siriwardana, P. and Taranath, D., 2012. Macular hypoplasia in congenital disorder of glycosylation type Ia. *Case Reports in Ophthalmology*, 3(1), 142-144.

DOI: 10.1159/000338627

© 2012 S. Karger AG, Basel

This is an Open Access article licensed under the terms of the Creative Commons Attribution-NonCommercial-NoDerivs 3.0 License (www.karger.com/OA-license), applicable to the online version of the article only. Distribution for non-commercial purposes only.

This is an Open Access article licensed under the terms of the Creative Commons Attribution-NonCommercial-NoDerivs 3.0 License (www.karger.com/OA-license), applicable to the online version of the article only. Distribution for non-commercial purposes only.

Macular Hypoplasia in Congenital Disorder of Glycosylation Type Ia

Bob Z. Wang^a Pradeep Siriwardana^b Deepa Taranath^{a, b}

^aDepartment of Ophthalmology, Flinders Medical Centre and Flinders University, Bedford Park, S.A., and ^bDepartment of Paediatric Ophthalmology, Women's and Children's Hospital, North Adelaide, S.A., Australia

Key Words

Congenital disorders of glycosylation · Macular hypoplasia

Abstract

Congenital disorders of glycosylation are a rare group of metabolic disorders that can result in multiorgan disease. This article describes a novel finding of macular hypoplasia in congenital disorders of glycosylation type Ia.

Introduction

Congenital disorders of glycosylation (CDG) are a rare group of metabolic disorders caused by defective synthesis of N-linked oligosaccharides [1]. These oligosaccharides have important biological functions, particularly in maintaining protein stability and facilitating cell-to-cell communication.

CDG type Ia (CDG-Ia) is the most common type of CDG, and the clinical presentation of this disorder is highly variable, ranging from no involvement with normal development to significant neurological impairment with multisystem involvement [2] including ophthalmic manifestations.

This article describes a case of macular hypoplasia associated with CDG-Ia.

Case Report

An 8-week-old female Caucasian infant was referred by a paediatrician for ocular assessment. She was born at 38 weeks' gestation to non-consanguineous parents by spontaneous vaginal delivery following a normal pregnancy. She developed early feeding problems, which led to failure to thrive. She was also noted to have poor sucking, generalized hypotonia, mild hip dysplasia, stroke-like

Dr. Bob Wang

Department of Ophthalmology, Flinders Medical Centre and Flinders University
Flinders Drive, Bedford Park, SA 5042 (Australia)
Tel. +61 8 8204 5511, E-Mail bobzwang@gmail.com

episodes and significant gastro-oesophageal reflux with associated poor coordination of feeding. In addition, the infant had bilateral moderate to severe hearing loss.

At 3 months of age, the infant's transferrin isoform analysis demonstrated significantly elevated levels of disialo- and asialotransferrin. She also had low levels of antithrombin III, protein C and protein S as well as borderline hypothyroidism. TORCH panel involving testing for antibodies to *Toxoplasma gondii*, rubella, cytomegalovirus and herpes simplex virus was negative. Magnetic resonance imaging of the brain showed ponto-cerebellar hypoplasia. Genetic analysis revealed that she was compound heterozygous for the p.R14H and p.G208A mutations in the phosphomannomutase 2 (*PMM2*) gene, consistent with a diagnosis of CDG-Ia.

On ocular examination, the infant appeared to demonstrate momentary awareness of but did not follow or fixate on light. She showed good doll's eye movements and had frequent upturning of eyes but no nystagmus. Anterior ocular segment examination including slit-lamp examination was unremarkable, and in particular there were no signs of iris transillumination suggestive of albinism. Fundoscopy showed macular hypoplasia with blond retinal background ([fig. 1](#)).

Follow-up ocular examination at 5 months of age continued to show persisting visual inattention, roving eye movements and bilateral macular hypoplasia. By 20 months of age, the patient was fixating and following well with each eye. Pendular nystagmus was noted, as was a 30-prism-dioptre left esotropia. Extra-ocular movements were full, and there were no signs of iris transillumination. Cycloplegic refraction was within normal limits (right eye +2.50 dioptres; left eye +2.50 dioptres). Fundus examination continued to show macular hypoplasia.

Electrophysiological studies including cutaneous flash electroretinogram (ERG) were normal. Pattern-reversal ERG and visual-evoked cortical potentials were simultaneously recorded and demonstrated normal retinocortical time.

Discussion

CDG-Ia can result in multiorgan disease. In up to 70% of cases, it is associated with ocular abnormalities resulting in reduced visual acuity [3, 4]. The most common ocular feature is esotropia [4, 5]. This disorder has also been associated with progressive myopia, retinitis pigmentosa, optic neuropathy, optic disc hypoplasia, retinal coloboma, cone and rod dysfunction and bull's eye maculopathy [3–6].

Although CDG-Ia has been associated with bull's eye maculopathy [5], our case highlights that CDG-Ia may be also associated with macular hypoplasia. This association has not been previously described.

The exact pathogenesis of macular hypoplasia in CDG-Ia is unknown, although it is likely to be related to the abnormal development of the retina and optic nerve that occurs in patients with CDG-Ia [5].

Given that ocular pathology may be the first indication of CDG-Ia [7], CDG-Ia should be considered when assessing patients with macular hypoplasia. Equally important, patients with CDG-Ia require a thorough ophthalmic examination.

Disclosure Statement

The authors have no commercial or conflict of interest to declare.

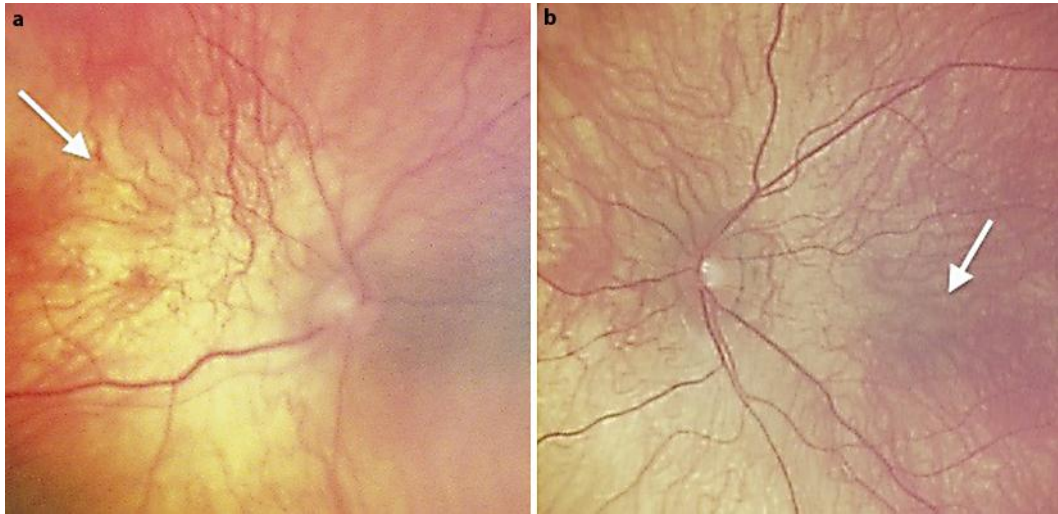


Fig. 1. Fundus photographs of the right eye (a) and left eye (b) showing macular hypoplasia (white arrows) with blond retinal background and underlying choroidal vessels visible.

References

- 1 Grunewald S: The clinical spectrum of phosphomannomutase 2 deficiency (CDG-Ia). *Biochim Biophys Acta* 2009;1792:827–834.
- 2 Sparks SE, Krasnewich DM: *Congenital Disorders of Glycosylation Overview*. University of Washington, Seattle, 1993–2005.
- 3 Erlandson A, Bjursell C, Stibler H, Kristiansson B, Wahlstrom J, Martinsson T: Scandinavian CDG-Ia patients: genotype/phenotype correlation and geographic origin of founder mutations. *Hum Genet* 2001;108:359–367.
- 4 de Lonlay P, Seta N, Barrot S, et al: A broad spectrum of clinical presentations in congenital disorders of glycosylation I: a series of 26 cases. *J Med Genet* 2001;38:14–19.
- 5 Morava E, Wosik HN, Sykut-Cegielska J, et al: Ophthalmological abnormalities in children with congenital disorders of glycosylation type I. *Br J Ophthalmol* 2009;93:350–354.
- 6 Jensen H, Kjaergaard S, Klie F, Moller HU: Ophthalmic manifestations of congenital disorder of glycosylation type 1a. *Ophthalmic Genet* 2003;24:81–88.
- 7 Stromland K, Hagberg B, Kristiansson B: Ocular pathology in disialotransferrin developmental deficiency syndrome. *Ophthalmic Paediatr Genet* 1990;11:309–313.