



Archived at the Flinders Academic Commons:

<http://dspace.flinders.edu.au/dspace/>

This is the published version of this article. The original is available from: <http://www.racgp.org.au/afp>

Chu, E.R. & Chen, C.S., 2009. Optic neuritis - more than a loss of vision. *Australian Family Physician*, 38(10), 789-793.

© 2009 Royal Australian College of General Practitioners.
Published version of the paper reproduced here with permission from the publisher.



Edward R Chu

MBBS, is resident medical officer, Department of Ophthalmology, Flinders Medical Centre and Flinders University, South Australia.

Celia S Chen

MBBS, MPH, FRANZCO, is a consultant ophthalmologist and Senior Lecturer, Department of Ophthalmology, Flinders Medical Centre and Flinders University, South Australia. celia.chen@health.sa.gov.au

Optic neuritis

More than a loss of vision

Background

Optic neuritis is an acute inflammation of the optic nerve that results in painful loss of vision. Patients often present to a general practitioner, and early recognition is important as treatment may improve the speed of vision recovery.

Objective

This article provides information on the signs and symptoms of optic neuritis and discusses appropriate referral, investigations and management.

Discussion

Optic neuritis is the presenting symptom in up to one-fifth of people with multiple sclerosis. Diagnosis of optic neuritis is based on history and examination, therefore obtaining pertinent information and performing proper ophthalmic examination is essential. Prompt recognition and appropriate referral is important to facilitate investigations such as magnetic resonance imaging of the brain that can help predict risk in the development of multiple sclerosis.

■ **Optic neuritis (ON) is the presence of an acute inflammation of the optic nerve that results in painful loss of vision. It is the most commonly encountered optic neuropathy in general practice,¹⁻⁴ and is often associated with multiple sclerosis (MS).^{3,4} Studies show that in about 15–20% of MS cases, ON was the presenting symptom and more than half of people with MS experience at least one episode of ON during their disease.^{5,6} The risk of developing MS can be stratified by appropriate imaging investigations at the diagnosis of ON. Therefore, early recognition is important to ensure timely referral, investigation and treatment; prompt treatment can hasten visual recovery.**

Epidemiology

Annually, the incidence and prevalence of ON in the United States of America is five per 100 000 and 115 per 100 000 respectively.⁷ There are no published Australian data. Caucasians, females and people living in higher latitudes are more likely to be affected.⁸⁻¹¹ It commonly occurs between the ages of 15–49 years (mean age 30–35 years³).

In children, ON has a mean onset of 9–12 years;^{3,12} commonly coincides with the peak incidence of viral infection;³ and has equal gender distribution.³

Aetiology

Optic neuritis may be due to demyelination (associated with MS),^{2,3} infection, parainfection or autoimmune disease. In adults, demyelinating causes are common, and idiopathic demyelinating ON is the commonest cause.

In adults, infectious causes are rare but include herpes zoster, Lyme disease, syphilis, tuberculosis, cat scratch disease, toxoplasmosis, toxocariasis, cytomegalovirus and fungi, adenovirus, measles, mumps or chicken pox.^{2,3} Parainfectious causes from sinus disease, vaccination and encephalitis have been reported.¹⁻³ Autoimmune ON has been reported in systemic lupus erythematosus, Sjogren syndrome, ankylosing spondylitis, diabetes mellitus, temporal arteritis, and sarcoidosis.¹⁻³

In children, ON is commonly caused by infection such as adenovirus, measles, mumps and chickenpox, followed by parainfectious causes postvaccination.³

Pathology

Inflammation of the optic nerve and its lining results in inflammation of the extraocular recti muscles that surround the optic nerve. Recti muscle involvement results in ocular pain, especially with eye movements. Regardless of aetiology, inflammatory cells surround the optic nerve² resulting in swelling and fragmentation of the nerve tissue.² Subsequently, these fragments are phagocytised by macrophages resulting in further degeneration of the nerve and the signs of optic nerve dysfunction.²


Clinical features

History and examination are the basis of diagnosis.²⁻⁴ Adult patients with ON often notice a unilateral decrease in vision.²⁻⁴ Bilateral involvement can occur, but this is more common in children or in Asian populations and is referred to as 'optospinal MS'.^{3,4,9} Colour vision is usually affected, with colours appearing 'washed out' (*Figure 1*) before any decline of vision occurs.^{4,11} There is often orbital pain in or around the eye,¹¹ which is typically described as 'dull', 'achy',

Figure 1. Normal colour vision (left). Red desaturation during an episode of ON (right) (red objects appear washed out)



Figure 2. A sample of an Ishihara pseudoisochromatic plate. The colour vision testing should be performed in good lighting and monocularly by covering one eye at a time. The eye with ON usually shows colour deficit resulting in abnormal response (eg. reporting a number 3 when it is a number 8 on the plate) or not being able to see the number on the plate



or 'boring'. A salient feature is increased pain with extraocular movement.¹¹ Ocular pain can either precede or simultaneously occur with subacute unilateral visual loss, which can progress over several hours to days, peaking within 10 days.¹⁻³

Proper ophthalmic examination is essential to determine whether a patient has ON. Clinical signs of optic nerve dysfunction are:

- decreased visual acuity (VA)
- decreased colour vision
- presence of relative afferent pupillary defect (RAPD)
- reduction in subjective brightness
- visual field defect
- abnormal contrast sensitivity, and
- certain appearances of the optic nerve (swelling, peripapillary haemorrhage or pallor).

Visual acuity and colour vision

In general practice, the signs of optic nerve dysfunction can be elicited from testing the VA using a Snellen chart, or an age dependent chart for children, to determine the degree of vision loss.^{1,3} Visual acuity in ON can range from 6/6 to no perception of light. Examination of colour vision is imperative and this can be detected with the use of a pseudo-isochromatic plates such as Ishihara plates (*Figure 2*). The most common pattern in ON is red-green confusion.¹³

Relative afferent pupillary defect is the most important objective sign of unilateral ON and it is vital that this test is performed correctly (see the article 'Sudden loss of vision' in this issue). If a RAPD is not demonstrated, possibilities include bilateral simultaneous optic ON or previous contralateral eye ON.^{14,15}

The Optic Neuritis Treatment Trial (ONTT) showed approximately 48% of patients with ON in one eye had evidence of optic neuropathy in the contralateral eye.¹⁶ In children, ON is quite often bilateral and simultaneous.

Subjective decrease in brightness is another indicator of optic nerve dysfunction. This can be performed by shining a light source in each eye separately, and then asking the patient if the light appears equally bright. The light will appear less bright in the affected eye.

Field defects

In the general practice setting, visual field defect can be elicited with a red pin to compare blind spots between the examiner and the patient. Diffuse visual field defects may not be elicited using direct confrontation and may only be detected by ophthalmologist directed automated perimetry (*Figure 3*).

Fundoscopy

Anterior ON involves the optic nerve head and occurs in about 35% of patients. With the use of a direct ophthalmoscope, optic nerve swelling or papillitis can be seen (*Figure 4*).^{8,11} Sometimes, peripapillary haemorrhage or retinal exudate are also seen. The presence of papillitis, peripapillary haemorrhage and retinal exudate

with a normal MRI brain decrease the risk of developing MS.^{17,18}

Retrobulbar ON, where the inflammation occurs behind the optic nerve head, is more typical of idiopathic demyelinating disease and occurs in two-thirds of cases.^{8,11} In retrobulbar ON, the optic nerve looks normal but may develop pallor after 8 weeks from the onset of ON (*Figure 5*). A young female with vision loss, pain with eye movements and a normal looking optic nerve is likely to have retrobulbar ON.

Racial variants

There are racial variants in ON presentation that are important to note. A Singapore study demonstrated that ocular pain is less common in Asians compared to caucasians, while papillitis and disc haemorrhages are more common in Asians.¹⁹ Furthermore, African Americans were noted to have significant decreased VA at onset and after 1 year following a single initial episode of ON compared to caucasians within the same study group.²⁰

Children

The presentation of ON in children is different to that seen in adults. Bilateral disease (simultaneous or sequential)^{3,9} is more common and visual loss is often profound. A history of viral illness 2 weeks before ocular features and recent vaccination is important.^{3,13} The most common visual field deficit in children is central scotoma.^{3,13} Other visual field defects include generalised constriction and altitudinal defects.^{3,13}

Investigations

The diagnosis of ON is largely based on clinical features – investigation confirms the diagnosis and helps determine pathogenesis.

Brain MRI

A noncontrast MRI is the most important baseline investigation

Figure 3. Automated perimetry grey scale showing a) a normal right visual field at baseline. The right blind spot's inferior and temporal borders are noted by the black arrows; b) the right visual field of the same person during acute episode of ON showing an inferior arcuate scotoma (area seen as black areas in the grey scale). The blind spot (original inferior margin denoted by a white arrowhead) has enlarged inferiorly and nasally

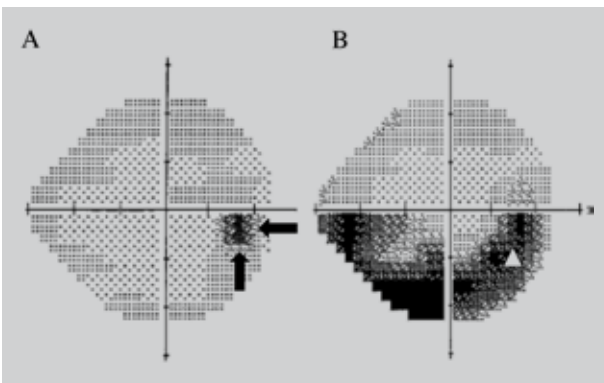


Figure 4. Papillitis with peripapillary haemorrhage (arrows) surrounding the optic nerve of the right eye during an acute episode of ON

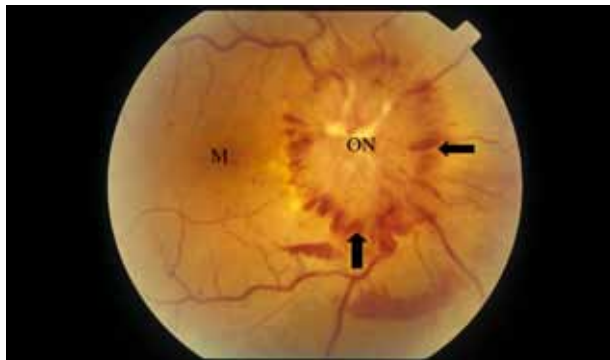
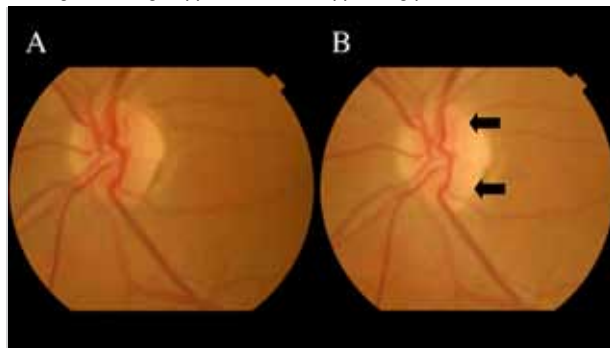


Figure 5. a) In retrobulbar ON the appearance of the optic nerve is normal at onset; b) Optic nerve pallor (arrows) is usually seen 8 weeks after the episode of retrobulbar ON with the neuroretinal rim losing the orange appearance and appearing pale



to help predict the risk of developing clinically definite MS.^{17,18} The cumulative probability of developing MS by 15 years after the onset of ON is 50% (95% confidence interval, 44–56%). This risk increased to 72% in patients with one or more lesions on MRI.¹⁷ The characteristic demyelinating lesions are 3 mm or more in diameter, ovoid, located in periventricular areas of the white matter, and radiate toward the ventricular spaces (*Figure 6*).⁴ Retrobulbar ON is best seen on a T1 weighted gadolinium enhanced MRI of the orbit, seen as a hyperintense signal of the optic nerve.

Diagnostic criteria of MS were updated in 2001 with the McDonald criteria taking into account the advances in MRI imaging.²¹ The McDonald criteria classifies a person as having MS when there are clinical features of two or more attacks and two or more objective clinical lesions on MRI.

In children, the relationship between MRI lesions and MS is less definite. However, recent studies have demonstrated that the presence of one or more white matter lesions on baseline MRI brain increases the risk of MS.^{12,22}

Lumbar puncture

Lumbar puncture is now used less commonly and is controversial,¹ but cerebrospinal fluid (CSF) examination is useful in patients with

normal or atypical MRI brain.^{4,11} Oligoclonal bands are present in 69% of patients with ON.⁴ The risk of MS within 5 years in patients with oligoclonal bands is 65% in contrast to 10% in patients without oligoclonal bands with a normal MRI brain.⁴

Visual evoked potential

Visual evoked potential (VEP) may be helpful when diagnosis is uncertain.⁴ Patients with ON or MS will have a delay in latency with preserved waveforms in conventional VEP.^{23,24} Multifocal VEP is more refined and has been shown to help predict progression of MS when a delay in latency is present but is not widely available.²³

Other investigations

In typical cases blood tests are not useful.^{3,8} However, in atypical cases such as in patients over 50 years of age, in males, or in nondemyelinating forms of ON, further workup is required.³ Immunocompromised individuals require a septic workup including blood and CSF for serological and microbiological analysis. If autoimmune causes are suspected, inflammatory markers such as antinuclear antibody, extractable nuclear antigen, and other appropriate markers should be obtained with subsequent referral to a rheumatologist. Chest X-ray is useful in suspected sarcoidosis.^{1,3}

Management

There are two objectives in the management of demyelinating ON: hasten visual recovery and reduce the risk of developing systemic MS. In acute ON, visual function generally spontaneously improves over weeks, and 95% of patients return to visual acuity of at least 6/12 within 12 months.²⁵

The recommended treatment for acute demyelinating ON is intravenous methylprednisolone which speeds recovery but does not affect the long term visual outcome.^{1,8,10} High dose intravenous methylprednisolone of 1 g/day in a single or divided doses (250 mg four times per day) for 3 days is the mainstay of treatment,²⁵ often

followed by a tapering oral steroid course.¹¹ Oral steroids alone are not recommended as studies have shown it resulted in a higher recurrence of ON in the same or fellow eye at the 10 year mark.^{10,11}

In autoimmune causes of ON, steroids are the mainstay of treatment. If infectious causes are suspected, steroids should be withheld until appropriate antimicrobial agents are instituted.

There are no set guidelines for treatment of ON in children. Several studies recommended the use of intravenous methylprednisolone (10–30 mg/kg/day for 3–5 days) to treat vision loss.^{3,13,22}

Several large, randomised controlled trials demonstrate that an immunomodulator reduces the development of MS after ON.^{4,26–29} In Australia, the approved use of immunomodulators is restricted to ambulatory patients with specifically defined relapsing-remitting MS.²⁹ However, immunomodulators may be available on compassionate grounds in selected patients and referral of these patients to a neurologist or neuro-ophthalmologist for consultation and management is warranted.

Summary of important points

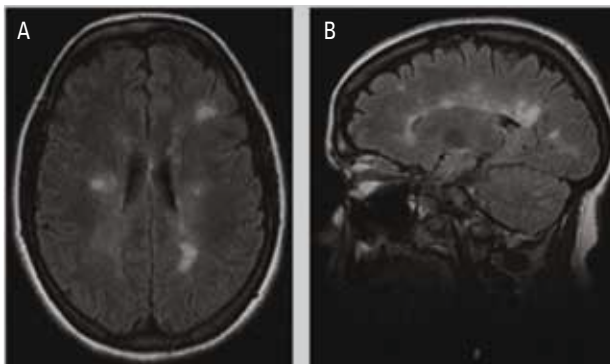
- Demyelinating optic neuritis may be related to MS.
- Diagnosis is largely based on history and physical examination.
- Patients often present with vision loss and discomfort around the eye that is aggravated by eye movement.
- Clinical signs include decreased visual acuity, decreased colour vision, presence of RAPD, decreased subjective brightness and visual field abnormality. Appearance of the optic nerve head can either be swollen (papillitis) or normal.
- The characteristic white matter lesion on MRI brain is the most important predictor in the development of MS.
- Early recognition of ON is essential for prompt referral to an ophthalmologist.
- Treatment for the acute episode of ON with IV methylprednisone followed by oral prednisolone hastens the rate of vision recovery.

Conflict of interest: none declared.

References

1. Foroozan R, Buono LM, Savino PJ, Sergott RC. Acute demyelinating optic neuritis. *Curr Opin Ophthalmol* 2002;13:375–80.
2. Germann CA, Baumann MR, Hamzavi S. Ophthalmic diagnoses in the ED: Optic neuritis. *Am J Emerg Med* 2007;25:834–7.
3. Boomer JA, Siatkowski M. Optic neuritis in adults and children. *Semin Ophthalmol* 2003;18:174–80.
4. Balcer LJ. Optic neuritis. *N Engl J Med* 2006;354:1273–80.
5. Confavreux C, Vukusic S, Moreau T, et al. Relapses and progression of disability in multiple sclerosis. *N Engl J Med* 2000;343:1430–8.
6. Arnold AC. Evolving management of optic neuritis and multiple sclerosis. *Am J Ophthalmol* 2005;139:1101–8.
7. Rodriguez M, Siva A, Cross SA, et al. Optic neuritis: A population-based study in Olmsted County, Minnesota. *Neurology* 1995;45:244–50.
8. Murphy MA. Clinical update on optic neuritis and multiple sclerosis. *Med Health R I* 2008;91:57–9.
9. Hickman SJ, Dalton CM, Miller DH, Plant GT. Management of acute optic neuritis. *Lancet* 2002;360:1953–62.
10. Beck RW, Cleary PA, Trobe JD, et al. The effect of corticosteroids for acute optic neuritis on the subsequent development of multiple sclerosis. The Optic Neuritis Study Group. *N Engl J Med* 1993;329:1764–9.
11. Osborne BJ, Volpe NJ. Optic neuritis and risk of MS: Differential diagnosis and management. *Cleve Clin J Med* 2009;76:181–90.

Figure 6. MRI brain. a) Sagittal T1 weighted imaging showing multiple paraventricular lesions radiating from the ventricle. These lesions are commonly described as 'Dawson finger'; b) Axial T1 weighted imaging through the lateral ventricle showing multiple characteristic hyperintense lesions located in paraventricular and juxtacortical distribution



12. Bonhomme GR, Waldman AT, Balcer LJ, et al. Pediatric optic neuritis: Brain MRI abnormalities and risk of multiple sclerosis. *Neurology* 2009;72:881–5.
13. Morales DS, Siatkowski RM, Howard CW, Warman R. Optic neuritis in children. *J Pediatr Ophthalmol Strabismus* 2000;37:254–9.
14. Kolappan M, Henderson AP, Jenkins TM, et al. Assessing structure and function of the afferent visual pathway in multiple sclerosis and associated optic neuritis. *J Neurol* 2009;256:305–19.
15. Henderson AP, Trip SA, Schlottmann PG, et al. An investigation of the retinal nerve fibre layer in progressive multiple sclerosis using optical coherence tomography. *Brain* 2008;131:277–87.
16. Keltner JL, Johnson CA, Spurr JO, et al. Baseline visual field profile of optic neuritis. The experience of the optic neuritis treatment trial. Optic Neuritis Study Group. *Arch Ophthalmol* 1993;111:231–4.
17. The Optic Neuritis Study Group. Multiple sclerosis risk after optic neuritis. Final Optic Neuritis Treatment Trial follow-up. *Arch Neurol* 2008;65:727–32.
18. Optic Neuritis Study Group. High- and low-risk profiles for the development of multiple sclerosis within 10 years after optic neuritis. Experience of the Optic Neuritis Treatment Trial. *Arch Ophthalmol* 2003;121:944–9.
19. Lim SA, Goh KY, Tow S, et al. Optic neuritis in Singapore. *Singapore Med J* 2008;49:667–71.
20. Phillips PH, Newman NJ, Lynn MJ. Optic neuritis in African Americans. *Arch Neurol* 1998;55:186–92.
22. Alper G, Wang L. Demyelinating optic neuritis in children. *J Child Neurol* 2009;24:45–8.
25. Atkins EJ, Bioussé V, Newman NJ. The natural history of optic neuritis. *Rev Neurol Dis* 2006;3:45–56.
21. McDonald WI, Compston A, Edan G, et al. Recommended diagnostic criteria for multiple sclerosis: Guidelines from the International Panel on the diagnosis of multiple sclerosis. *Ann Neurol* 2001;50:121–7.
23. Fraser C, Klistorner A, Graham S, et al. Multifocal visual evoked potential latency analysis: Predicting progression to multiple sclerosis. *Arch Neurol* 2006;63:847–50.
25. National Institute for Health and Clinical Excellence. Multiple sclerosis: Management of multiple sclerosis in primary and secondary care. Guideline 8. [online]. November 2003. Available at www.nice.org.uk/Guidance/CG8/NiceGuidance/pdf/English [Accessed 26 November 2003].
26. Jacobs LD, Beck RW, Simon JH, et al. Intramuscular interferon beta-1a therapy initiated during a first demyelinating event in multiple sclerosis. *N Engl J Med* 2000;343:898–904.
27. Comi G, Filippi M, Barkhof F, et al. Effect of early interferon treatment on conversion to definite multiple sclerosis: A randomised study. *Lancet* 2001;357:1576–82.
28. CHAMPS Study Group. Interferon beta-1a for optic neuritis patients at high risk for multiple sclerosis. *Am J Ophthalmol* 2001;132:463–71.
29. Kappos L, Freedman MS, Polman CH, et al. Effect of early versus delayed interferon beta-1b treatment on disability after a first clinical event suggestive of multiple sclerosis: A 3-year follow-up analysis of the BENEFIT study. *Lancet* 2007;370:389–97.