

Archived at the Flinders Academic Commons:

<http://dspace.flinders.edu.au/dspace/>

This is the publisher's copyrighted version of this article.

The original can be found at: <http://www.journals.uchicago.edu/toc/cid/current>

© 2004 by the Infectious Diseases Society of America. All rights reserved.

Published version of the paper reproduced here in accordance with the copyright policy of the publisher. Personal use of this material is permitted. However, permission to reprint/republish this material for advertising or promotional purposes or for creating new collective works for resale or redistribution to servers or lists, or to reuse any copyrighted component of this work in other works must be obtained from the publisher , University of Chicago Press

First Documentation of In Vivo and In Vitro Ivermectin Resistance in *Sarcoptes scabiei*

Bart J. Currie,^{1,2} Pearly Harumal,¹ Melita McKinnon,¹ and Shelley F. Walton¹

¹Infectious Diseases Division, Menzies School of Health Research, Charles Darwin University, and ²Infectious Diseases Unit, Northern Territory Clinical School, Flinders University, Royal Darwin Hospital, Darwin, Northern Territory, Australia

Ivermectin is increasingly being used to treat scabies, especially crusted (Norwegian) scabies. However, treatment failures, recrudescence, and reinfection can occur, even after multiple doses. Ivermectin resistance has been documented for some intestinal helminths in animals with intensive ivermectin exposure. Ivermectin resistance has also been induced in arthropods in laboratory experiments but, to date, has not been documented among arthropods in nature. We report clinical and in vitro evidence of ivermectin resistance in 2 patients with multiple recurrences of crusted scabies who had previously received 30 and 58 doses of ivermectin over 4 and 4.5 years, respectively. As predicted, ivermectin resistance in scabies mites can develop after intensive ivermectin use.

Ivermectin is increasingly being used to treat scabies, especially in those with hyperinfestation (crusted or Norwegian scabies) [1, 2]. Scabies is endemic in many remote Aboriginal communities in the Northern Territory of Australia, and a minority of patients develop crusted scabies. Unlike in most reports of crusted scabies, the cases we treat in these communities often involve no overt immunosuppression, and the reason that this select cohort develops hyperinfestation remains unclear [3]. We have been using ivermectin since 1992 to treat >50 patients with crusted scabies. However, treatment failure or early recrudescence is common after single-dose ivermectin, and multiple doses have usually been required to achieve a cure [3]. With adequate treatment, there is excellent clinical response, with crusts fully resolved and normal skin or residual patchy depigmentation. Nevertheless, exposure of these susceptible individuals to scabies in their communities continues, and recurrent crusted scabies several months to a year after initial cure is common [4]. By means of

genotyping of *Sarcoptes scabiei* mites from patients with repeated infestations, we found that, although the majority of recurrent scabies are probably the result of reinfestation from inadequately treated contacts, there was evidence that, in cases of severe crusted scabies, even treatment with 3 doses of ivermectin administered 14 days apart may be inadequate to prevent relapse [5]. We therefore increased the ivermectin regimen for patients with severe crusted scabies to 5 doses (each 200 $\mu\text{g}/\text{kg}$) administered on treatment days 1, 2, 15, 16, and 29, on the basis of a protocol for strongyloidiasis complicating AIDS [6].

By use of a simple in vitro assay to assess the survival of scabies mites on petri dishes coated with various acaricides, we previously found no evidence of decreased ivermectin sensitivity in mites obtained from patients who were administered multiple courses of ivermectin [7], including 1 patient who had had received >50 doses. However, we now report 2 patients with recurrent severe crusted scabies who developed in vivo and in vitro resistance to ivermectin after receiving multiple ivermectin doses.

MATERIALS AND METHODS

Larvae, nymphal instars, and adult *S. scabiei* were separated from skin scrapings obtained from patients with crusted scabies before and during treatment. Ovicidal activity was not measured. To circumvent differences

Received 1 December 2003; accepted 7 March 2004; electronically published 11 June 2004.

Reprints or correspondence: Dr. Bart J. Currie, Menzies School of Health Research, PO Box 41096 Casuarina, Northern Territory 0811, Australia (bart@menzies.edu.au).

Clinical Infectious Diseases 2004;39:e8-12

© 2004 by the Infectious Diseases Society of America. All rights reserved.
1058-4838/2004/3901-00E2\$15.00

in survival ability, all mites were tested within 3 h of being obtained, as described elsewhere [7]. The determination of sensitivity to ivermectin of mite populations was assessed at a concentration of 100 $\mu\text{g/g}$ of ivermectin (Equimec Paste; Merial Australia) diluted in Emulsifying Ointment British Pharmacopoeia 88 (BP88) (Sigma Pharmaceuticals). In earlier studies in our laboratory, we had established 100 $\mu\text{g/g}$ as the ivermectin concentration for in vitro testing, which was adapted from the in vitro acaricidal experiments of Brimer et al. [8]. At a concentration of 100 $\mu\text{g/g}$ ivermectin, we demonstrated a mean *S. scabiei* mite killing time of 60 min [7]. Approximately 0.1 g of the test product was applied in a thin layer with cotton swabs to the bottom, top, and sides of 36-mm petri dishes. BP88-coated petri dishes were used as controls. Determination of mite survival after placement on the petri dishes was as described elsewhere [7].

Results were analyzed by use of a log-rank test for survival (SPSS software, version 10.0.5; SPSS). The study was approved by the Human Research Ethics Committee of the Northern Territory Department of Health and Community Services and Menzies School of Health Research.

RESULTS

Case report 1. A 36-year-old Aboriginal woman from a remote coastal community in the tropical Top End of the Northern Territory of Australia sought care in January 2000 for severe crusted scabies involving hands and feet, thighs, trunk, and buttocks. She had a history of recurrent crusted scabies since 1992. The results of multiple immunological investigations, including serological testing for HIV and human T cell leukemia virus 1 (HTLV-1), were negative, and T cell subsets were normal. Since 1995, the patient had received 30 doses of ivermectin, 17 of which were administered during 1999, including 2 doses that were administered in December 1999. A further course of therapy with ivermectin together with topical 5% permethrin cream and topical keratolytic therapy with 10% urea and 5% lactic acid in sorbolene cream was initiated. Live *S. scabiei* mites from skin scrapings were seen microscopically up to day 26 after commencement of ivermectin therapy, by which time in vitro testing had shown decreased sensitivity of mites, with some mites alive 9 h after in vitro exposure to ivermectin at a concentration of 100 $\mu\text{g/g}$ (figure 1). Because no in vitro resistance to the other acaricides tested was observed, topical 5% permethrin cream was increased to treatment on alternate days, and the condition of the patient's skin steadily improved, with the first clear skin scrapings occurring on day 30 after initiation of therapy. Two months later, the patient had no evidence of scabies, but there was considerable depigmentation of her hands and feet. In April 2001, she again presented with crusted scabies, but in vitro testing showed no ivermectin resistance (figure 1), and she

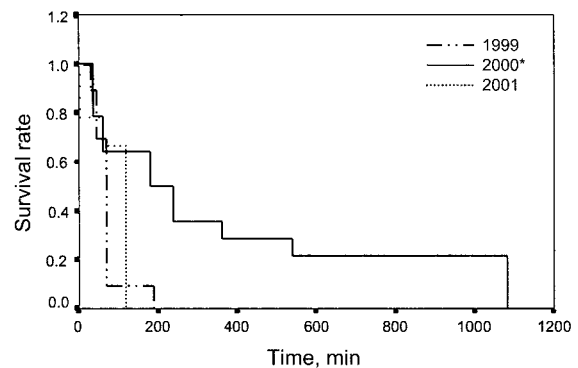


Figure 1. Kaplan-Meier survival curves of scabies mites obtained from patient 1 in 1999 ($n = 10$), 2000 ($n = 14$), and 2001 ($n = 9$) after admissions to the hospital for treatment of crusted scabies. Mites were tested in petri dishes coated with ivermectin at a concentration of 100 $\mu\text{g/g}$. * $P = .0048$.

responded to 7 doses of ivermectin administered at a higher dose (21 mg per dose, at a concentration of 280 $\mu\text{g/kg}$) over a 28-day period with topical 25% benzyl benzoate and keratolytic therapy.

Case report 2. A 47-year-old Aboriginal man from a different remote Top End community presented in August 2000 with severe crusted scabies involving all limbs, buttocks, and lower back. Since 1996, he had received 58 doses of ivermectin for multiple episodes of recurrent crusted scabies. The results of multiple immunological investigations, including serological testing for HIV and HTLV-1, were negative, and T cell subsets were normal. The patient received seven 18-mg doses of ivermectin at a concentration of 270 $\mu\text{g/kg}$ during the next 30 days, together with topical 5% permethrin cream alternating with topical keratolytic therapy with 10% urea and 5% lactic acid in sorbolene cream, and subsequently 12% salicylic acid in cetomacrogel cream. He also required intravenous antibiotics to treat secondary sepsis. Although there was gradual clinical improvement during a month of treatment, multiple live mites were still present on days 12, 19, and 26 after commencement of ivermectin therapy, and the patient had to leave the hospital for family reasons after receiving his seventh dose of ivermectin. The patient subsequently returned to the hospital 3 weeks after receiving his last dose of ivermectin, and the condition of his crusted scabies was clinically worse than at the time of discharge. There were numerous live mites still present. In vitro testing of mites obtained at admission showed some with prolonged survival, after exposure to ivermectin at a concentration of 100 $\mu\text{g/g}$ (figure 2).

Because of the failure of our standard topical therapy regimen and the apparent in vitro and in vivo ivermectin resistance, we commenced therapy with topical 25% benzyl benzoate with tea tree oil added (to make a 5% tea tree oil solution). The rationale for this was that benzyl benzoate and 5% tea tree oil were

consistently the topical scabicides that killed scabies mites the quickest in our earlier *in vitro* studies [7]. The severe burning sensation that the patient felt for several minutes after application of the benzyl benzoate was controlled by inhalation of 50% nitrous oxide/50% oxygen mixture. He was administered 11 doses of the combination topical therapy over a 4-week period, as well as a further 7-dose course of ivermectin therapy (18 mg/dose), and the condition of his skin rapidly improved. Skin scrapings obtained 10 days after this therapy was initiated showed only 2 of 100 mites to be alive, and at 20 days, no mites were present. At discharge, the patient had no clinical or microscopic evidence of scabies, although there was considerable depigmentation of his feet and lower legs. In May 2001, he again presented with crusted scabies, but *in vitro* testing showed no evidence of ivermectin resistance (figure 2). His illness responded to 6 doses of ivermectin administered over a 21-day period together with topical 25% benzyl benzoate/5% tea tree oil and topical keratolytics.

Figure 3 shows *in vitro* survival curves for ivermectin exposure for the mites obtained from patients 1 and 2 after their admissions in 2000 (at which time *in vivo* ivermectin resistance was present), compared with that for mites obtained from patients 1 and 2 at other admissions and that for mites from 3 other patients with crusted scabies.

DISCUSSION

To our knowledge, this is the first report of *in vivo* or *in vitro* ivermectin resistance in *S. scabiei*. Ivermectin insensitivity or differential responsiveness has emerged as a major problem in a number of intestinal nematodes of goats, sheep, and cattle, with most cases being related to intensive ivermectin use over a period of several years [9, 10]. No ivermectin-resistant arthropod has previously been reported from any animal or human infestations or field situation [9, 10], although there are reports showing ivermectin resistance can be induced in the laboratory under intense drug exposure in the horn fly (*Haematobia irritans*) [11], fruit fly (*Drosophila melanogaster*) [12], and a species of tick (*Boophilus microplus*) [13].

The potential for development of ivermectin-resistant *S. scabiei* was a concern in treating our patients, who have required many doses of ivermectin for treatment of their recurrent crusted scabies [5, 7]. Unlike most patients previously documented with crusted scabies, our patients have not had a severe immunosuppressive illness and, therefore, have survived long enough to require an unprecedented number of ivermectin doses. The reason for the development of crusted scabies in our patients remains uncertain, although the possibility of a specific immune defect predisposing them to hyperinfestation with *S. scabiei* is currently being investigated. Genotyping studies [5] and the development of ordinary scabies in hospital staff

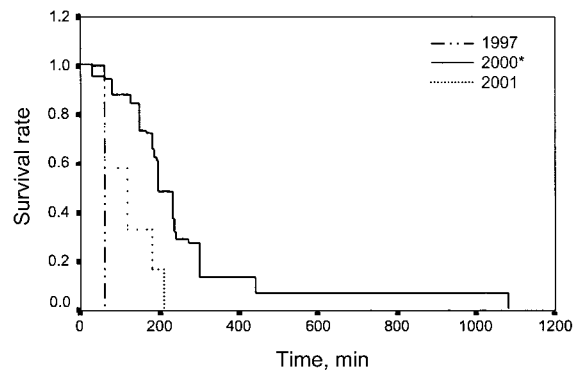


Figure 2. Kaplan-Meier survival curves of scabies mites obtained from patient 2 in 1997 ($n = 7$), 2000 ($n = 63$), and 2001 ($n = 13$) after admissions to the hospital for treatment of crusted scabies. Mites were tested in petri dishes coated with ivermectin at a concentration of 100 $\mu\text{g/g}$. * $P < .00001$.

who were infected from these patients with crusted scabies make differences in *S. scabiei* virulence an unlikely explanation.

The exact mechanisms of ivermectin action and resistance remain to be elucidated and appear to vary between organisms. Ivermectin inhibits signal transmission at the neuromuscular junction of some arthropods by stimulating release of the inhibitory neurotransmitter gamma-aminobutyric acid from presynaptic nerve terminals [2]. However, paralysis and death of invertebrate nerve and muscle cells has also been attributed to ivermectin binding to glutamate-gated chloride channels, resulting in increased chloride ion permeability and hyperpolarization [14]. Ivermectin is also believed to bind to and be transported by a P-glycoprotein membrane transport protein [15]. These efflux pump proteins are thought to be involved in the multidrug-resistance phenotype seen in some human cancers, and mutations in the *Plasmodium falciparum* gene encoding the P-glycoprotein homologue have recently been shown to confer antimalarial drug resistance [16]. Alterations in P-glycoprotein gene structure and/or its transcription have been described in ivermectin-resistant sheep nematode parasites, *Haemonchus contortus* [15]. Another potential mechanism for ivermectin resistance is mutation in the glutamate-gated chloride channels that modulate ivermectin activity. There is also support for this mechanism from other studies with *H. contortus* [17] and from chemical mutagenesis studies in fruit flies [12]. It is therefore possible that, under intense drug selection pressure, mutations of scabies P-glycoprotein encoding genes and/or of the gene family encoding the glutamate-gated chloride channels may account for our cases of ivermectin resistance.

The presence of ivermectin-sensitive mites in the recurrences that our 2 patients experienced in 2001 suggests that the earlier ivermectin-resistant scabies infections were eradicated, but that

our patients were reinfected from contacts after they returned to their communities. These 2 patients have had 74 and 91 doses of ivermectin, respectively. Attempts at prophylaxis against recurrent infection by giving monthly ivermectin doses have failed to prevent the infection in several individuals we have treated (unpublished results). We are currently assessing the administration of topical therapy with permethrin or benzyl benzoate once every 2 weeks as prophylaxis for high-risk individuals who have had recurrent crusted scabies. However, we are concerned about the possible emergence of resistance to these topical therapies with such a program. Although resistance of head lice (*Pediculus capitis*) to 1% permethrin has been widely reported [2, 18], there has to date been no documented clinical evidence of tolerance of scabies mites to 5% permethrin [19], although we reported evidence for increasing in vitro killing time [7]. Our in vitro testing also showed that 25% benzyl benzoate killed scabies mites more quickly than did 5% permethrin [7], but clinical resistance to benzyl benzoate has been suspected elsewhere [20]. Lindane (1% gamma benzene hexachloride) has been successfully used for many years in treating scabies [21], but in vivo and in vitro mite resistance to lindane has occasionally been documented [2, 22–24], and lindane has been withdrawn from sale in several countries, including Australia, because of well-documented but rare instances of neurotoxicity and aplastic anemia [25].

The rapid in vitro scabicial action of 5% tea tree oil [7, 26] and its successful use in combination with benzyl benzoate in 1 of our patients warrants further study of this (and possibly other) combination topical therapies. We found that the combination of 5% tea tree oil in 25% benzyl benzoate killed scabies mites in vitro at least as quickly as benzyl benzoate alone (unpublished observation).

Initial recommendations for the use of ivermectin to treat crusted scabies were for a single dose at a concentration of 200

$\mu\text{g}/\text{kg}$, with a second dose administered 2 weeks later for refractory cases [1]. The importance of concomitant keratolytic therapy and topical scabicides to kill mites in the thick crusts has been emphasized [1, 2, 27, 28]. The difficulty in eradicating scabies mites in patients with particularly severe crusted scabies was supported by the presence of live mites in 1 patient 19 days after ivermectin therapy was initiated, despite a good (but incomplete) clinical response; in vitro testing showing no evidence of ivermectin resistance [28]. A recent comparative study concluded that, in treating cases of ordinary scabies, a single application of 5% permethrin cream was superior to a single 200 $\mu\text{g}/\text{kg}$ dose of ivermectin [29]. It was suggested that ivermectin may not be ovicidal because of inadequate penetration of the thick eggshell, as well as possibly being ineffective against the younger stages of the parasite inside the egg because, at that point in the life cycle, the parasite's nervous system has not yet developed. This supports the rationale for a second dose of ivermectin to kill mites emerging from eggs after administration of the first dose. However, the timing of the second dose may be important: a study of experimental scabies challenge in pigs showed efficacy of ivermectin persisting for only 9 days after administration of a single dose [30]. Therefore, a weekly dosing interval may be superior to dosing every 2 weeks in treating cases of crusted scabies. The possibility of the use of doses exceeding 200 $\mu\text{g}/\text{kg}$ has also been raised [27, 31].

In light of concerns that a 2-week dosing interval is inadequate, we have further modified our protocol for treating recurrent crusted scabies to a 5-dose regimen with doses of 200 $\mu\text{g}/\text{kg}$ administered on days 1, 2, 8, 9, and 15 of therapy, with an additional 2 doses on days 22 and 29 for the most severe cases. Further dosing and dose-interval studies are required in order to define optimal ivermectin regimens for treating crusted scabies of varying degrees of severity.

The emergence of ivermectin resistance in *S. scabiei* after intensive ivermectin use over a period of several years reflects the failure to control the current community epidemics of scabies in our region, with treated individuals often being reinfected from untreated contacts. There is now an even more urgent reason to focus on community-based prevention and control programs [4, 23].

Acknowledgments

We thank our medical and nursing colleagues at Royal Darwin Hospital, including Daniel O'Brien, Adam Jenney, Julian Elliott, Mark Douglas, Marilyn Hassell, Josh Davis, Anna Ralph, Sarah Huffam, Dale Fisher, Nick Anstey, and Alison Bucklar, for meticulous patient care and assistance with these studies, and Susan Jacups, for help with statistical analysis.

Financial support. Australian National Health and Medical Research Council and the Cooperative Research Centre for Aboriginal and Tropical Health, Darwin.

Conflict of interest. All authors: No conflict.

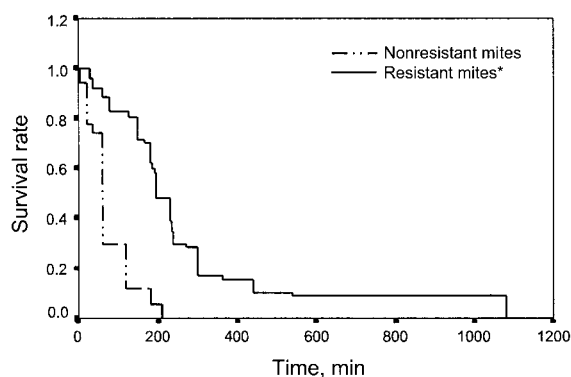


Figure 3. Kaplan-Meier survival curves of ivermectin-resistant scabies mites obtained from patients 1 and 2 in 2000 ($n = 77$), in comparison with nonivermectin-resistant mites obtained from patients 1 and 2 and from 3 other patients with crusted scabies ($n = 50$). * $P < .00001$.

References

1. Meinking TL, Taplin D, Hermida JL, Pardo R, Kerdel FA. The treatment of scabies with ivermectin. *N Engl J Med* **1995**; 333:26–30.
2. Chosidow O. Scabies and pediculosis. *Lancet* **2000**; 355:819–26.
3. Huffam SE, Currie BJ. Ivermectin for *Sarcoptes scabiei* hyperinfestation. *Int J Infect Dis* **1998**; 2:152–4.
4. Currie BJ, Carapetis JR. Skin infections and infestations in Aboriginal communities in northern Australia. *Australas J Dermatol* **2000**; 41: 139–43.
5. Walton SF, McBroom J, Mathews JD, Kemp DJ, Currie BJ. Crusted scabies: a molecular analysis of *Sarcoptes scabiei* variety *hominis* populations from patients with repeated infestations. *Clin Infect Dis* **1999**; 29:1226–30.
6. Torres J, Isturiz R, Murillo J, Guzman M, Contreras R. Efficacy of ivermectin in the treatment of *Strongyloidiasis* complicating AIDS. *Clin Infect Dis* **1993**; 17:900–2.
7. Walton SF, Myerscough MR, Currie BJ. Studies in vitro on the relative efficacy of current acaricides for *Sarcoptes scabiei* var *hominis*. *Trans R Soc Trop Med Hyg* **2000**; 94:92–6.
8. Brimer L, Bonlokke L, Pontoppidan C, Henriksen SA, Gyrd-Hansen N, Rasmussen E. A method for in vitro determination of the acaricidal effect of ivermectin using *Sarcoptes scabiei* var *suis* as test organism. *Vet Parasitol* **1995**; 59:249–55.
9. Shoop WL. Ivermectin resistance. *Parasitol Today* **1993**; 9:154–9.
10. Sangster NC, Gill J. Pharmacology of anthelmintic resistance. *Parasitol Today* **1999**; 15:141–6.
11. Byford RL, Craig ME, DeRouen SM, et al. Influence of permethrin, diazinon and ivermectin treatments on insecticide resistance in the horn fly (Diptera: Muscidae). *Int J Parasitol* **1999**; 29:125–35.
12. Kane NS, Hirschberg B, Qian S, et al. Drug-resistant *Drosophila* indicate glutamate-gated chloride channels are targets for the antiparasitics nolidisporic acid and ivermectin. *Proc Natl Acad Sci USA* **2000**; 97: 13949–54.
13. Benavides E, Romero A. Preliminary results of a larval resistance test to ivermectins using *Boophilus microplus* reference strains. *Ann N Y Acad Sci* **2000**; 916:610–2.
14. Burkhart CN. Ivermectin: an assessment of its pharmacology, microbiology and safety. *Vet Hum Toxicol* **2000**; 42:30–5.
15. Xu M, Molento M, Blackhall W, Ribeiro P, Beech R, Prichard R. Ivermectin resistance in nematodes may be caused by alteration of P-glycoprotein homolog. *Mol Biochem Parasitol* **1998**; 91:327–35.
16. Reed MB, Saliba KJ, Caruana SR, Kirk K, Cowman AF. Pgh1 modulates sensitivity and resistance to multiple antimalarials in *Plasmodium falciparum*. *Nature* **2000**; 403:906–9.
17. Prichard R. Genetic variability following selection of *Haemonchus contortus* with anthelmintics. *Trends in Parasitology* **2001**; 17:445–53.
18. Downs AM, Stafford KA, Hunt LP, Ravenscroft JC, Coles GC. Widespread insecticide resistance in head lice to the over-the-counter pediculocides in England, and the emergence of carbaryl resistance. *Br J Dermatol* **2002**; 146:88–93.
19. Taplin D, Meinking T. Pyrethrins and pyrethroids in dermatology. *Arch Dermatol* **1990**; 126:213–21.
20. Yonkosky D, Ladia L, Gackenhaimer L, Schultz M. Scabies in nursing homes: an eradication program with permethrin 5% cream. *J Am Acad Dermatol* **1990**; 23:1133–6.
21. Taplin D, Rivera A. A comparative trial of three treatment schedules for the eradication of scabies. *J Am Acad Dermatol* **1983**; 9:550–4.
22. Hernandez-Perez E. Resistance to antiscabietic drugs. *J Am Acad Dermatol* **1983**; 8:121–3.
23. Taplin D, Porcelain SL, Meinking TL, et al. Community control of scabies: a model based on use of permethrin cream. *Lancet* **1991**; 337: 1016–8.
24. Fraser J. Permethrin: a Top End viewpoint and experience. *Med J Aust* **1994**; 160:806.
25. Roos TC, Alam M, Roos S, Merk HF, Bickers DR. Pharmacotherapy of ectoparasitic infections. *Drugs* **2001**; 61:1067–88.
26. Walton SF, McKinnon M, Pizzutto S, Dougall A, Williams E, Currie BJ. Acaricidal activity of *Melaleuca alternifolia* (tea tree) oil: in vitro sensitivity of *sarcoptes scabiei* var *hominis* to terpinen-4-ol. *Arch Dermatol* **2004**; 140:563–6.
27. Taplin D, Meinking TL. Treatment of HIV-related scabies with emphasis on the efficacy of ivermectin. *Semin Cutan Med Surg* **1997**; 16: 235–40.
28. Currie B, Huffam S, O'Brien D, Walton S. Ivermectin for scabies. *Lancet* **1997**; 350:1551.
29. Usha V, Gopalakrishnan Nair TV. A comparative study of oral ivermectin and topical permethrin cream in the treatment of scabies. *J Am Acad Dermatol* **2000**; 42:236–40.
30. Arends JJ, Skogerboe TL, Ritzhaupt LK. Persistent efficacy of doramectin and ivermectin against experimental infestations of *Sarcoptes scabiei* var. *suis* in swine. *Vet Parasitol* **1999**; 82:71–9.
31. Burkhart CG, Burkhart CN, Burkhart KM. An epidemiologic and therapeutic reassessment of scabies. *Cutis* **2000**; 65:233–40.