

Archived at the Flinders Academic Commons

<http://dspace.flinders.edu.au/dspace/>

This is the publisher's copyrighted version of this article.

The original can be found at:

<http://bjo.bmjournals.com/cgi/content/full/84/2/205>



Apoptosis is a prominent feature of acute anterior uveitis in the Fischer 344 rat

J R Smith, P H Hart, S D Standfield, D J Coster, S J Wing and K A Williams

Br. J. Ophthalmol. 2000;84;205-211
doi:10.1136/bjo.84.2.205

Updated information and services can be found at:
<http://bjo.bmjournals.com/cgi/content/full/84/2/205>

These include:

References

This article cites 31 articles, 19 of which can be accessed free at:
<http://bjo.bmjournals.com/cgi/content/full/84/2/205#BIBL>

4 online articles that cite this article can be accessed at:
<http://bjo.bmjournals.com/cgi/content/full/84/2/205#otherarticles>

Rapid responses

You can respond to this article at:
<http://bjo.bmjournals.com/cgi/eletter-submit/84/2/205>

Email alerting service

Receive free email alerts when new articles cite this article - sign up in the box at the top right corner of the article

Topic collections

Articles on similar topics can be found in the following collections
[Ophthalmology](#) (1565 articles)

Notes

To order reprints of this article go to:
<http://www.bmjournals.com/cgi/reprintform>

To subscribe to *British Journal of Ophthalmology* go to:
<http://www.bmjournals.com/subscriptions/>

Apoptosis is a prominent feature of acute anterior uveitis in the Fischer 344 rat

J R Smith, P H Hart, S D Standfield, D J Coster, S J Wing, K A Williams

Abstract

Aims—To examine the hypothesis that apoptosis of infiltrating cells contributes to spontaneous resolution of uveitis in clinically relevant rodent models.

Methods—Experimental melanin induced uveitis (EMIU) was induced in Fischer 344 rats by immunisation with 250 µg bovine ocular melanin. Endotoxin induced uveitis (EIU) was induced by injection of 200 µg *Escherichia coli* lipopolysaccharide. Formalin fixed, paraffin embedded ocular cross sections were stained by terminal deoxynucleotidyl transferase mediated deoxyuridine triphosphate biotin nick end labelling (TUNEL) to identify apoptotic cells. Indirect immunoperoxidase staining of paraformaldehyde lysine periodate fixed tissue cross sections was used to demonstrate expression of inducible nitric oxide synthase (iNOS).

Results—TUNEL positive mononuclear cells were observed in the anterior uvea during both EMIU and EIU at all selected time points. However, whereas the majority of mononuclear cells appeared apoptotic from the outset of disease, neutrophils were notably TUNEL negative at all time points examined. Many infiltrating neutrophils expressed iNOS.

Conclusion—Apoptosis occurs early in the course of rat EMIU and EIU, and may contribute to resolution of these diseases. In general, infiltrating mononuclear cells die rapidly, while neutrophils survive, producing inducible nitric oxide synthase which may contribute to disease pathogenesis.

(*Br J Ophthalmol* 2000;84:205–211)

Department of
Ophthalmology,
Flinders University of
South Australia,
Adelaide, Australia

J R Smith
S D Standfield
D J Coster
K A Williams

Department of
Microbiology and
Infectious Diseases

P H Hart

Arthritis Research
Laboratory, University
of Adelaide, Adelaide,
Australia
S J Wing

Correspondence to:
Dr K A Williams,
Department of
Ophthalmology, Flinders
Medical Centre, Bedford
Park, South Australia 5042,
Australia

Accepted for publication
15 September 1999

waxing and waning nature of acute anterior uveitis is a result of FasL mediated apoptosis.^{3–6} However, there is no published work to support this hypothesis directly.

Acute anterior uveitis is a recurrent inflammatory disease of the iris and/or ciliary body of the eye that occurs commonly, causes disabling photophobia, and may ultimately result in blinding complications.⁷ The disease mechanisms are poorly understood. Ethically, collection of iris and/or ciliary body from patients with acute anterior uveitis cannot generally be justified but information is available from two animal models that have clinical features in common with the human disease. Endotoxin induced uveitis (EIU), an inflammation of the anterior uvea lasting several days, is observed when small rodents are injected systemically with bacterial lipopolysaccharide.^{8–9} The predominant infiltrating cell is the neutrophil, but resident tissue macrophages are probably the cells that first respond to lipopolysaccharide.¹⁰ Experimental melanin induced uveitis (EMIU) is induced in rats by immunisation with bovine ocular melanin.¹¹ Disease in this model is characterised by anterior uveal inflammation which remits after a month but spontaneously relapses in many animals.^{12–13} Inflammation is antigen driven¹² and is controlled by CD4 positive T lymphocytes.¹³

Given that uveitis can cause damage to intraocular structures, we hypothesised that apoptosis of infiltrating leucocytes might occur late in the course of EIU and EMIU and that toxic mediators such as nitric oxide might be released within the local microenvironment, before the death of the infiltrating cells. We used terminal deoxynucleotidyl transferase mediated deoxyuridine triphosphate biotin nick end labelling (TUNEL) to detect apoptotic cells in ocular cross sections of rats with EMIU or EIU. Further, we correlated induction of inducible nitric oxide synthase (iNOS) with disease progression in these models.

Materials and methods

ANIMALS

Male and female Fischer 344 and DA rats were used aged 8 weeks or less. Animals were housed at 21°C and 50% humidity in a 12 hour light and 12 hour dark cycle, and were fed water and dried ration (New Joint Stock, Ridley Agriproducts, Murray Bridge, SA, Australia) ad libitum. Experimental protocols were developed in accordance with the National Health and Medical Research Council of Australia Statement for the Use of Animals in Research. All procedures and euthanasia were carried out under halothane (Zeneca Ltd, Macclesfield) inhalation anaesthesia.

Many cells including neutrophils, monocytes, macrophages, and lymphocytes express Fas (CD95) on their surface. The interaction between Fas and its receptor, Fas ligand (FasL, CD95L), triggers apoptosis of the Fas bearing cell.¹ The eye enjoys a degree of immune privilege, explained in part by the constitutive expression of Fas ligand within this organ.² Expression of FasL has been localised to the cornea, the anterior uvea, and the retina of both murine² and human³ eyes. Corneal allografts from FasL negative mice into recipients of normal phenotype are rejected in all cases, whereas around half of FasL positive grafts survive.^{4–5} Introduction of herpes simplex virus into the eye leads to severe invasive infection in FasL deficient mice, but relatively minor inflammation in normal phenotype control animals.² It has been postulated that the

INDUCTION OF EXPERIMENTAL MELANIN INDUCED UVEITIS

Ocular melanin was extracted from bovine choroids according to the protocol described by Broekhuysse and colleagues,¹¹ and quantified as a dry weight. Rats received 125 µg of bovine ocular melanin in a 1:1 emulsion of sterile, non-pyrogenic 0.9% normal saline and Hunter's TitreMax adjuvant (Sigma Chemical Company, St Louis, MO, USA) in a total volume of 60 µl by right hind footpad injection. Immediately afterwards, they were injected intraperitoneally with the same quantity of melanin mixed with 1 µg of pertussis toxin (Sigma Chemical Company) in a total volume of 40 µl normal saline.

INDUCTION OF ENDOTOXIN INDUCED UVEITIS

Rats were injected in one hind footpad with 200 µg of *Escherichia coli* 055:B55 lipopolysaccharide (Sigma Chemical Company) solubilised in 100 µl normal saline.

MONITORING OF UVEITIS AND COLLECTION OF UVEITIC EYES

Animals were examined daily at the slit lamp to identify the onset and course of uveitis. For TUNEL, groups of 3–7 animals were killed at predetermined time points. Rats with EMIU were killed at the time of injection, on days 1–2 (time of disease onset), days 3–7 (maximal inflammation), and during weeks 2–3 (resolution) of clinical uveitis. Rats with EIU were killed at the time of injection and at 24 hours (maximal inflammation) and 48 hours (resolution) after injection. For staining for iNOS, groups of 3–4 rats with EMIU were killed before development of uveitis, on days 1–2, 3–5, 7, and during weeks 2–3 of clinical disease.

INDUCTION OF ADJUVANT ARTHRITIS

The ankle joint of a rat with adjuvant induced arthritis was examined as a control tissue. Adjuvant arthritis was induced in a DA rat by subcutaneous injection of 0.1 ml of complete Freund's adjuvant (Difco, Detroit, MI, USA) at the base of the tail.¹⁴ The rat was killed at day 12 when arthritis was florid.

STAINING BY TUNEL

TUNEL was performed according to a modification of a published method.¹⁵ Eyes were fixed in 10% buffered formalin for a minimum of 24 hours and paraffin embedded. The ankle joint was decalcified as previously described¹⁴ before similar fixation. Sections of 5 µm were deparaffinised, hydrated through graded alcohols to distilled water, and permeabilised with 0.16 units/ml proteinase K (Merck, Darmstadt, Germany) for 10 minutes. Nick end labelling was accomplished by incubating sections with 0.11 units/ml terminal deoxynucleotidyl transferase in pH 6.6 buffer containing 5 mM cobalt chloride, 200 mM potassium cacodylate, 25 mM TRIS-HCl, 250 µg/ml bovine serum albumin, 0.375 nM biotinylated deoxy-uridine triphosphate (dUTP) and 75 µM deoxy-adenosine triphosphate (all from Boehringer-Mannheim, Mannheim, Ger-

many) for 60 minutes at 37°C. The reaction was terminated by washing in 0.6 M sodium chloride 0.06 M sodium citrate buffer for 15 minutes, in Dulbecco's A phosphate buffered saline (PBS) for 1 minute, and in PBS containing 2% volume/volume (v/v) fetal calf serum (Trace Biosciences, Sydney, NSW, Australia) and 0.2% v/v Triton-X100 (Sigma Chemical Company) for 30 minutes. Non-specific binding sites were blocked with 10% v/v heat inactivated (56°C, 30 minutes) normal swine serum (Commonwealth Serum Laboratories, Melbourne, VIC, Australia) for 10 minutes, and the sections were washed for 10 minutes with PBS containing 0.2% weight/volume (w/v) gelatin (PBS gelatin) before endogenous peroxidase was blocked with 0.07% v/v hydrogen peroxide in methanol for 20 minutes. Sections were washed again in PBS gelatin for 10 minutes and then incubated with a 1 in 300 dilution of horseradish peroxidase conjugated streptavidin (Dako Corporation, Carpinteria, CA, USA) in PBS for 1 hour. Sections were washed in PBS gelatin, and developed for 5 minutes in 9 mM TRIS-HCl buffer at pH 7.6 with 40 mM sodium azide, 20 mM 3,3'-diaminobenzidine tetrahydrochloride, 9 mM imidazole, and 0.07% v/v hydrogen peroxide (all from Sigma Chemical Company). Finally, sections were counterstained with haematoxylin. Negative control sections were stained in an identical manner, but with omission of biotinylated dUTP from the nick end labelling mixture. Positive control sections were treated for 10 minutes with 10 U/ml DNase I (Boehringer-Mannheim) before TUNEL staining.

VIDEO IMAGE ANALYSIS OF TUNEL SECTIONS

Ocular cross sections from selected rats were scanned at a magnification of 200× using a computer assisted colour video image analysis system (Video-Pro 32, Leading Edge, Adelaide, SA, Australia). Images were captured using a Panasonic CCD video camera and digitised with a PV 100 16 bit colour video digitiser card in an Intel 80486 DX processor based personal computer. The digitised image was displayed on a SVGA monitor in a 640 × 480 pixel variable window with 21 bit resolution. Transmitted light intensity and stability of light output were standardised. Video image analysis measurements were made of the total area stained blue (by haematoxylin) and brown (by the TUNEL chromogen product). The total number of haematoxylin stained cell nuclei (representing nuclei of both uveal cells and infiltrating cells) was determined using feature counting.

STAINING FOR INDUCIBLE NITRIC OXIDE SYNTHASE

Enucleated eyes from Fischer 344 rats were fixed in paraformaldehyde lysine periodate¹⁶ for 4 hours and dehydrated in 7% and 15% w/v sucrose in PBS. They were then embedded in Tissue-Tek OCT (Miles Incorporated, Elkhart, IN, USA) and snap frozen in liquid nitrogen. Ocular cross sections were cut by cryostat at 8 µm thickness. Sections were incubated for 10

minutes at room temperature with 10% v/v normal swine serum in PBS, then with a monoclonal murine anti-rat iNOS antibody (IgG2a isotype) (Transduction Laboratories, Lexington, KY, USA) or SAL5, an isotype matched irrelevant control antibody (the gift of Dr L Ashman, Hanson Centre for Cancer Research, Adelaide, SA, Australia) for 18 hours. At this point, and subsequently, the sections were washed with PBS gelatin. They were incubated for 30 minutes with biotinylated affinity isolated goat anti-mouse immunoglobulin (Dako Corporation) diluted 1:500 in PBS containing 1% v/v normal rat serum, washed, and then incubated for a further 30 minutes with horse-radish peroxidase conjugated streptavidin (DAKO Corporation) diluted 1 in 1000 in PBS. Sections were developed and counterstained as described above.

Results

APOPTOSIS DURING EIU AND EMIU

In the initial stages of EMIU, many TUNEL negative neutrophils were observed infiltrating the uvea and anterior chamber, but most mononuclear cells were TUNEL positive (Fig 1). During the period of florid inflammation, there were many positive staining mononuclear cells infiltrating the anterior uvea, the aqueous, and vitreous, and sometimes the limbus and choroid. In one representative, severely inflamed eye, 79% (SD 4%) of iris cells, 75% (3%) of ciliary body cells, and 88% (7%) of aqueous cells were TUNEL positive by video image analysis. As the disease began to resolve, apoptotic mononuclear cells were still detectable, although numbers of infiltrating cells were reduced.

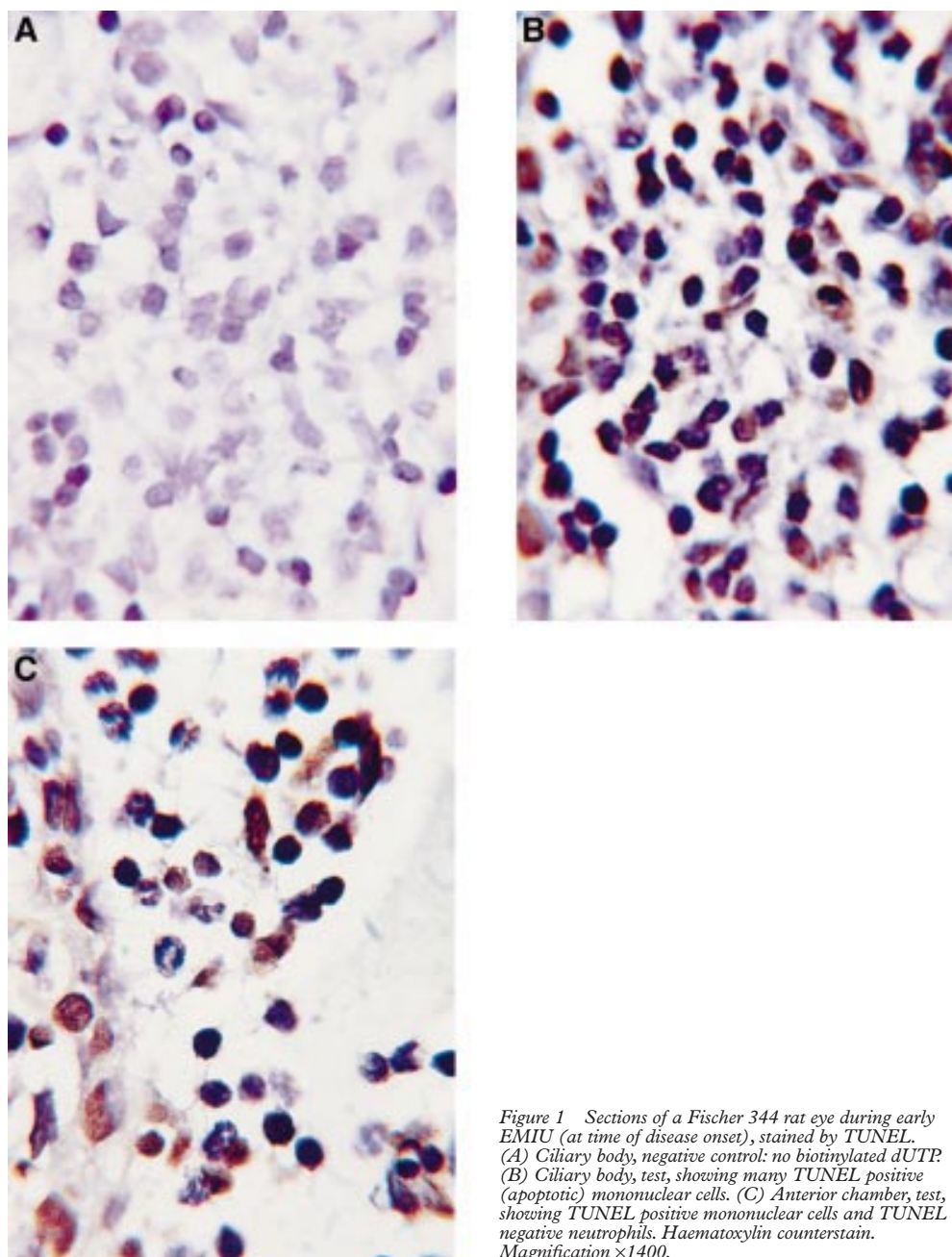


Figure 1 Sections of a Fischer 344 rat eye during early EMIU (at time of disease onset), stained by TUNEL. (A) Ciliary body, negative control: no biotinylated dUTP. (B) Ciliary body, test, showing many TUNEL positive (apoptotic) mononuclear cells. (C) Anterior chamber, test, showing TUNEL positive mononuclear cells and TUNEL negative neutrophils. Haematoxylin counterstain. Magnification $\times 1400$.

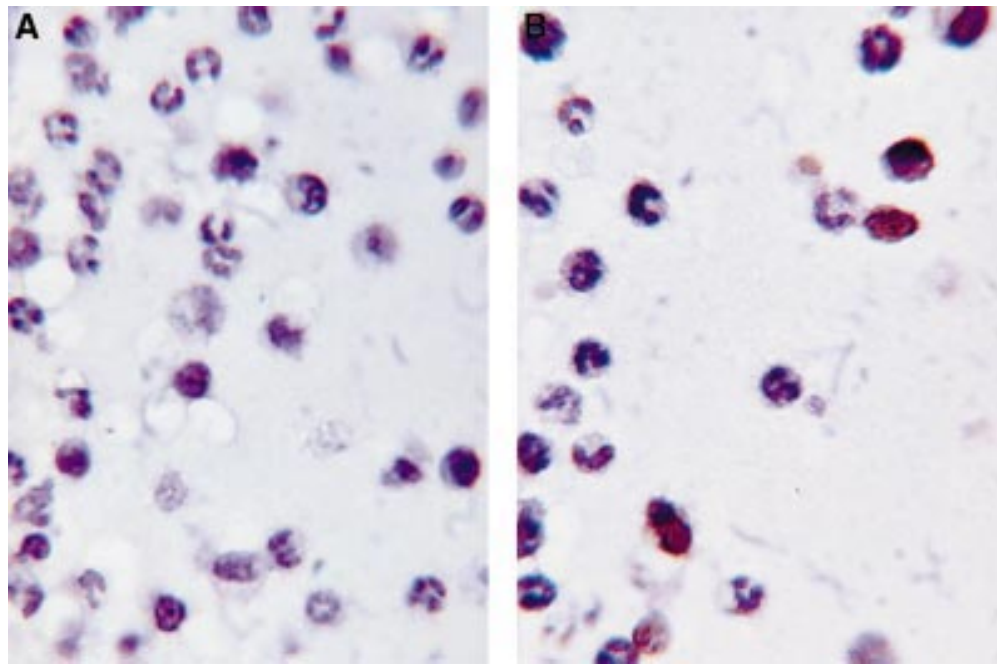


Figure 2 Photomicrograph demonstrating TUNEL positive mononuclear cells and TUNEL negative polymorphonuclear cells in the aqueous exudate of a Fischer 344 rat with EIU, 24 hours after lipopolysaccharide injection. (A) Negative control: no biotinylated dUTP; (B) TUNEL test run. Haematoxylin counterstain. Magnification $\times 1400$.

The Fischer 344 rat showed moderate anterior segment inflammation and vitritis in response to systemic endotoxin injection. At 24 hours (the time of maximal inflammation), infiltrating cells were seen in the aqueous and vitreous. The majority were TUNEL negative neutrophils, although a moderate number of TUNEL positive mononuclear cells were also present (Fig 2). In one representative eye, 40% (8%) of aqueous cells were TUNEL positive, but readings taken from the uveal tissues did not vary significantly from baseline. At 48 hours, a moderate infiltrate was still present in some eyes, but these cells were generally in the vitreous. TUNEL negative neutrophils predominated, but some TUNEL positive mononuclear cells were also present.

No TUNEL positive nuclei were observed in negative control sections (biotinylated dUTP omitted from the nick end labelling mixture). All nuclei were TUNEL positive in the positive control sections (treatment with DNase I before TUNEL staining). In test sections from rats killed before the onset of clinical and histological uveitis, an unexpectedly high background of TUNEL positive cells was noted. When quantified by video image analysis, this background amounted to 58% (20%) and 56% (18%) total cells in the iris and ciliary body, respectively. However, cells infiltrating the aqueous or vitreous during uveitis were plainly distinguishable from the background.

In contrast with the results obtained with the ocular sections, very few apoptotic nuclei were visible in the infiltrate present in the ankle joint of a DA rat with florid adjuvant arthritis, included as a control for severely inflamed tissue infiltrated with leucocytes (Fig 3).

EXPRESSION OF iNOS DURING EMIU

Immunohistochemical analysis of ocular cross sections demonstrated that iNOS was present neither in normal Fischer 344 rat eyes, nor in eyes enucleated immediately before the onset of EMIU. However, during the first week of clinical uveitis, many iNOS positive cells were observed in the anterior uvea and in the inflammatory exudate (Fig 4). Most positive cells had a polymorphonuclear appearance. These cells expressing iNOS were not detectable from the end of the first week of the inflammation, resolution of disease occurring at between 2–3 weeks after disease was first observed.

Discussion

Staining by TUNEL showed that apoptosis was a prominent feature in both melanin induced and endotoxin induced models of uveitis and that cell death began very early, at the time of onset of clinically apparent and histologically evident inflammation. However, whereas infiltrating mononuclear cells were found to die rapidly in situ, infiltrating neutrophils were found to survive. If apoptosis is FasL mediated, which seems most likely given the constitutive expression of this molecule within the anterior uvea,^{2,3} and given that FasL could readily be detected in the rat eye by immunoperoxidase staining (data not shown), the neutrophil must become refractory to this death signal. Watson and colleagues have recently demonstrated that the cross linking of the adhesion molecule CD11b on the neutrophil surface, the endothelial transmigration of neutrophils into inflammatory sites and, of particular relevance to EIU, the presence of lipopolysaccharide in the local microenviron-

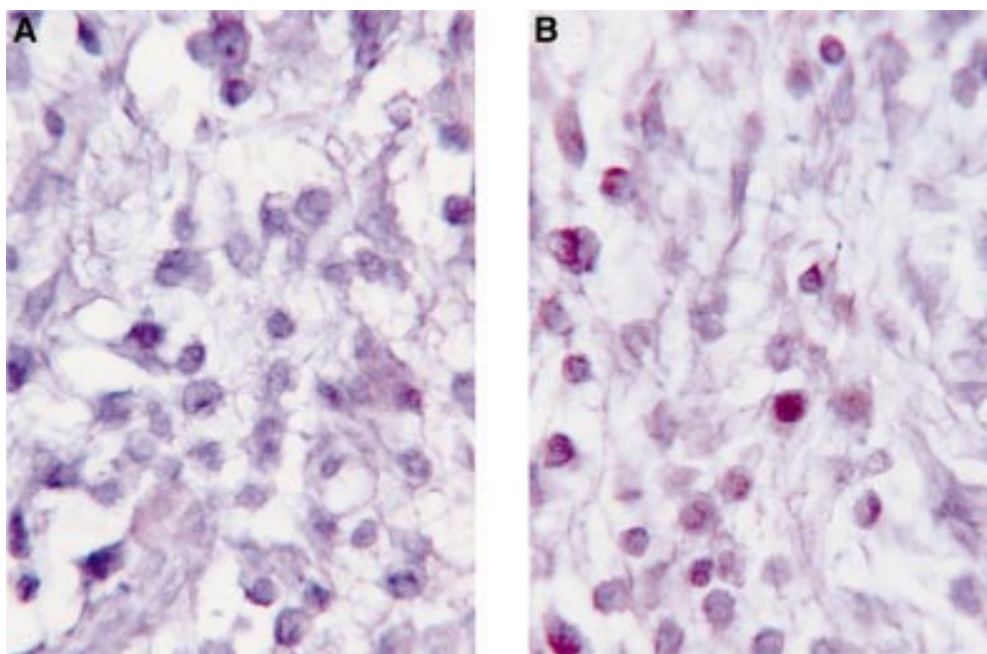


Figure 3 Photomicrograph of an inflamed ankle joint from a DA rat with adjuvant arthritis, showing very few TUNEL positive infiltrating cells. (A) Negative control: no biotinylated dUTP; (B) TUNEL test run. Haematoxylin counterstain. Magnification $\times 1400$.

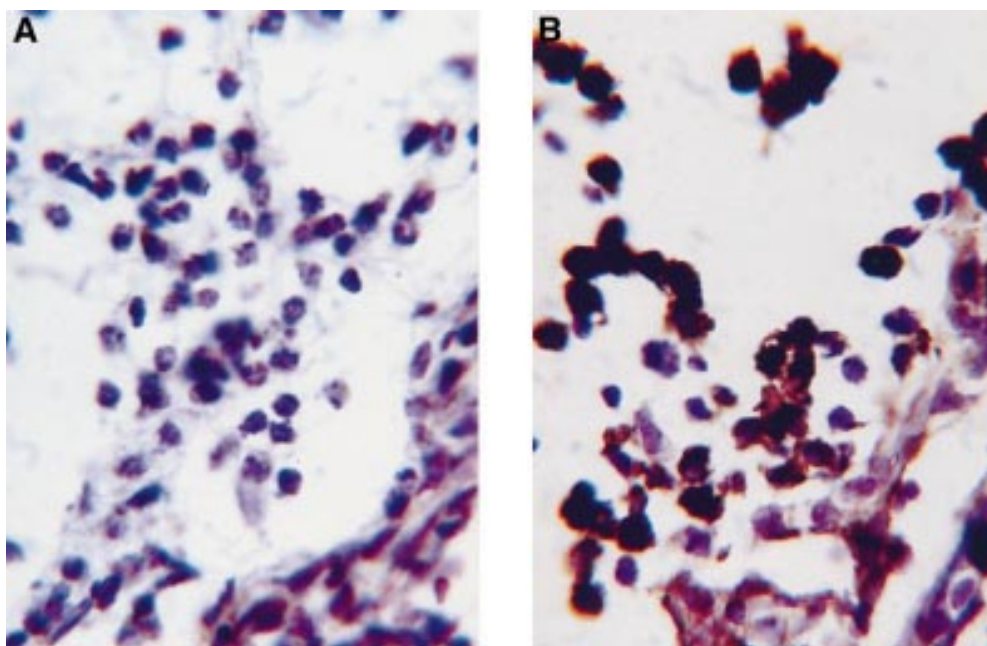


Figure 4 Photomicrograph demonstrating iNOS in cells in the anterior uvea and aqueous exudate of a F344 rat at the onset of EMIU. (A) Negative control: SALS; (B) anti-iNOS antibody. Immunoperoxidase stain with haematoxylin counterstain. Magnification $\times 1400$.

ment, are all capable of blocking FasL induced apoptosis of neutrophils.¹⁷

In addition to the Fas-FasL interaction, there are other mechanisms by which apoptosis may be induced. The tumour necrosis factor receptor (TNFR), TNFR1 or p55, which is structurally related to FasL, may trigger apoptosis after binding tumour necrosis factor alpha (TNF- α).¹⁸ It follows that TNF- α , a pro-inflammatory cytokine believed to be expressed in the anterior uvea of rats with uveitis,^{19, 20} is possibly signalling the apoptosis

of infiltrating leucocytes which we observed. Yet, why mononuclear cells should be susceptible to this signal whilst neutrophils are resistant to it, cannot be explained on the basis of current knowledge.

Our findings led us to speculate that the neutrophil may play an important effector part in uveitis, even in T lymphocyte mediated disease as exemplified by EMIU. Neutrophils release an enormous range of pro-inflammatory mediators including eicosanoids, platelet activating factor, cationic proteins, and

cytokines.²¹ They also produce iNOS, an enzyme which catalyses the generation of the free radical, nitric oxide (NO).²² There is substantial evidence for a pathogenic role for nitric oxide in EIU, particularly in relation to breakdown of the blood-aqueous barrier. Expression of iNOS mRNA and its translated product by infiltrating and local cells is detected during EIU,²³⁻²⁵ and drugs which inhibit iNOS activity significantly reduce the severity of the inflammation.²⁶⁻²⁸ That iNOS is not obligatory for disease expression is highlighted by our finding that EIU occurs even in iNOS gene knockout mice.²⁹ However, our observation that iNOS is expressed during the early stages of EMIU lends weight to the suggestion that nitric oxide is at least one of the molecular mediators of uveitis, produced by the neutrophil which has managed to avoid FasL mediated apoptosis.

What then is the role of the mononuclear cell in uveitis? In a recent study, reverse transcriptase polymerase chain reaction was used to determine mRNA expression of a range of cytokines in the iris and ciliary body during EMIU.¹⁹ Only mRNA for TNF- α , a cytokine that can be produced by neutrophils, rose to high levels. In contrast, mRNA levels of interferon gamma, interleukin (IL) 2, IL-4, IL-6, IL-10, IL-12, cytokines which are produced predominantly by lymphocytes and/or monocytes, showed little or no increase. In EIU, mRNAs for a variety of cytokines are detected before infiltrating leucocytes are seen,³⁰⁻³² but resident tissue macrophages responding directly to lipopolysaccharide could contribute to the production of many of these cytokines. In situ hybridisation has, in fact, localised TNF- α and IL-1 mRNA to "histiocyte-like" cells in the anterior uvea.²⁰ These findings fit with our observation that most infiltrating mononuclear cells seen in the eye during EMIU and EIU are either dead or dying, and are not releasing a cascade of cytokines. Although the phenotype of these mononuclear cells was not determined in this study, previous work indicates they are lymphocytes and macrophages/monocytes.¹⁰⁻¹⁵ In marked contrast with the findings in the eye, relatively few apoptotic cells of any phenotype were observed in the ankle synovium during florid adjuvant arthritis, a finding that was to be expected given that FasL is not constitutively expressed in this tissue.

In summary, the available evidence leads us to hypothesise that apoptosis of mononuclear cells may certainly contribute to the resolution of uveitis, but that neutrophils refractory to the Fas-FasL mediated death signal may be responsible for tissue damage. Treatment directed specifically against the neutrophil or neutrophil products may have significant therapeutic value both in T lymphocyte controlled disease and in predominantly neutrophil mediated inflammation. Clinical similarities between the two animal models of acute anterior uveitis and acute anterior uveitis in humans lead us to consider the possibility that there are parallels for disease pathogenesis at both cellular and molecular levels. Treatments

which specifically target the neutrophil may be useful in the management of human acute anterior uveitis.

We thank Professor S Wesselingh and Ms M Lewis for expert advice, and Mr R Yates for animal husbandry. This work was supported by The National Health and Medical Research Council of Australia, The Ophthalmic Research Institute of Australia, and The Flinders Medical Centre Foundation.

- Nagata S, Golstein P. The Fas death factor. *Science* 1995;267:1449-56.
- Griffith TS, Brunner T, Fletcher SM, et al. Fas ligand-induced apoptosis as a mechanism of immune privilege. *Science* 1995;270:1189-92.
- Chan C-C, Matteson DM, Li Q, et al. Apoptosis in patients with posterior uveitis. *Arch Ophthalmol* 1997;115:1559-67.
- Stuart PM, Griffith TS, Usui N, et al. CD95 ligand (FasL)-induced apoptosis is necessary for corneal allograft survival. *J Clin Invest* 1997;99:396-402.
- Yamagami S, Kawashima H, Tsuru T, et al. Role of Fas-Fas ligand interactions in the immunoregulation of allogeneic mouse corneal transplants. *Transplantation* 1997;64:1107-11.
- Griffith TS, Ferguson TA. The role of FasL-induced apoptosis in immune privilege. *Immunol Today* 1997;18:240-4.
- Rothova A, Van Veenendaal WG, Linssen A, et al. Clinical features of acute anterior uveitis. *Am J Ophthalmol* 1987;103:137-45.
- Rosenbaum JT, McDevitt HO, Guss RB, et al. Endotoxin-induced uveitis in rats as a model for human disease. *Nature* 1980;286:611-13.
- Kogiso M, Tanouchi Y, Mimura Y, et al. Endotoxin-induced uveitis in mice 1. Induction of uveitis and role of T lymphocytes. *Jpn J Ophthalmol* 1992;36:281-90.
- McMenamin PG, Crewe J. Endotoxin-induced uveitis. Kinetics and phenotype of the inflammatory cell infiltrate and the response of the resident tissue macrophages and dendritic cells in the iris and ciliary body. *Invest Ophthalmol Vis Sci* 1995;36:1949-59.
- Broekhuysse RM, Kuhlmann ED. Experimental autoimmune anterior uveitis. The preparation of uveitogenic melanin. *Invest Ophthalmol Vis Sci* 1993;34:698-700.
- Broekhuysse RM, Kuhlmann ED, Winkens AHM. Experimental autoimmune anterior uveitis (EAAU). III. Induction by immunization with purified uveal and skin melanins. *Exp Eye Res* 1993;56:575-83.
- Smith JR, Hart PH, Standfield SD, et al. Experimental melanin-induced uveitis in the Fischer 344 rat is inhibited by anti-CD4 monoclonal antibody, but not by mannose-6-phosphate. *Clin Exp Immunol* 1999;115:64-71.
- Spargo LD, Hawkes JS, Cleland LG, et al. Recruitment of lymphoblasts derived from peripheral and intestinal lymph to synovium and other tissues in normal rats and rats with adjuvant arthritis. *J Immunol* 1996;157:5198-207.
- Gavrieli Y, Sherman Y, Ben-Sasson SA. Identification of programmed cell death in situ via specific labeling of nuclear DNA fragmentation. *J Cell Biol* 1992;119:493-501.
- McLean IW, Nakane PK. Periodate-lysine-paraformaldehyde fixative: a new fixative for immunoelectron microscopy. *J Histochem Cytochem* 1974;22:1077-83.
- Watson RWG, Rotstein OD, Jimenez M, et al. Augmented intracellular glutathione inhibits Fas-triggered apoptosis of activated neutrophils. *Blood* 1997;11:4175-81.
- Magnusson C, Vaux DL. Signalling by CD95 and TNF receptors: not only life and death. *Immunol Cell Biol* 1999;77:41-6.
- Woon M-D, Kaplan HJ, Bora NS. Kinetics of cytokine production in experimental autoimmune anterior uveitis (EAAU). *Curr Eye Res* 1998;17:955-61.
- Yoshida M, Yoshimura N, Hangai M, et al. Interleukin-1 α , interleukin-1 β , and tumor necrosis factor gene expression in endotoxin-induced uveitis. *Invest Ophthalmol Vis Sci* 1994;35:1107-13.
- McCull SR, Showell HJ. Neutrophil-derived inflammatory mediators. In: Hellewell PG, Williams TJ, eds. *Immunopathology of neutrophils*. London: Academic Press, 1994:95-114.
- Lowenstein CJ, Dinerman JL, Snyder SH. Nitric oxide: a physiologic messenger. *Ann Int Med* 1994;120:227-37.
- Goureau O, Bellot J, Thillaye B, et al. Increased nitric oxide production in endotoxin-induced uveitis. Reduction of uveitis by an inhibitor of nitric oxide synthase. *J Immunol* 1995;154:6518-23.
- Jacquemin E, De Kozak Y, Thillaye B, et al. Expression of inducible nitric oxide synthase in the eye from endotoxin-induced uveitis rats. *Invest Ophthalmol Vis Sci* 1996;37:1187-96.
- McMenamin PJ, Crewe JM. Cellular localisation and dynamics of nitric oxide synthase expression in the rat anterior segment during endotoxin-induced uveitis. *Exp Eye Res* 1997;65:157-64.
- Tilton RG, Chang K, Corbett JA, et al. Endotoxin-induced uveitis in the rat is attenuated by inhibition of nitric oxide production. *Invest Ophthalmol Vis Sci* 1994;35:3278-88.
- Parks DJ, Cheung MK, Chan C-C, et al. The role of nitric oxide in uveitis. *Arch Ophthalmol* 1994;112:544-6.

- 28 Mandai M, Mittag TW, Kogishi J, *et al.* Role of nitric oxide synthase isozymes in endotoxin-induced uveitis. *Invest Ophthalmol Vis Sci* 1996;**37**:826–32.
- 29 Smith JR, Hart PH, Coster DJ, *et al.* Mice deficient in TNFR p55 and p75, IL-4 or iNOS are susceptible to endotoxin-induced uveitis. *Invest Ophthalmol Vis Sci* 1998;**39**:658–61.
- 30 De Vos AF, Klaren VNA, Kijlstra A. Expression of multiple cytokines and IL-1RA in the uvea and retina during endotoxin-induced uveitis in the rat. *Invest Ophthalmol Vis Sci* 1994;**35**:3873–83.
- 31 De Vos AF, Klaren VNA, Kijlstra A. Simultaneous induction of cytokine expression in the anterior uvea during endotoxin-induced uveitis in the rat. *Exp Eye Res* 1996;**62**:581–4.
- 32 Planck SR, Huang X-N, Robertson JE, *et al.* Cytokine mRNA levels in rat tissues after systemic endotoxin treatment. *Invest Ophthalmol Vis Sci* 1994;**35**:924–30.