

University of Helsinki  
&  
Children's Hospital  
Pediatric Surgery  
Helsinki University Central Hospital  
&  
ORTON Orthopaedic Hospital  
ORTON Foundation  
Helsinki  
&  
Children's Hospital  
Pediatric Surgery  
Turku University Central Hospital

## Surgical Treatment of Spinal Deformities in Children and Adolescents

Tuomas Jalanko

Academic dissertation

*To be presented with the permission of the Medical Faculty, University of  
Helsinki, for public examination in the Haartman Institute Auditorium, Helsinki  
University, on September 14<sup>th</sup> at 12 noon.*

Helsinki 2012

**Supervised by:**

Associate professor Ilkka Helenius, MD PhD

Children's Hospital

Turku University Central Hospital

Turku, Finland

**Reviewed by:**

Professor Seppo Seitsalo, MD PhD

ORTON Orthopaedic Hospital

Helsinki, Finland

Associate professor Helena Saraste, MD PhD

Karolinska University Hospital

Stockholm, Sweden

**Opponent:**

Professor Benny Dahl, MD PhD

Rigshospitalet

Copenhagen University Hospital

Copenhagen, Denmark

Cover drawing by Mikko Jalanko. Anatomical drawings by Helena Schmidt.

ISBN: 978-952-9657-63-6 (paperback) ; 978-952-9657-64-3 (pdf)

ISSN: 1455-1330

UNIGRAFIA Helsinki University Print

Helsinki 2012

As to diseases, make a habit of two things—to help, or at least to do no harm.

- Hippocrates

# TABLE OF CONTENTS

<b>TABLE OF CONTENTS</b> .....	<b>5</b>
<b>LIST OF ORIGINAL PUBLICATIONS</b> .....	<b>8</b>
<b>ABBREVIATIONS</b> .....	<b>9</b>
<b>ENGLISH ABSTRACT</b> .....	<b>11</b>
<b>SUOMENKIELINEN ABSTRAKTI</b> .....	<b>13</b>
<b>INTRODUCTION</b> .....	<b>15</b>
<b>REVIEW OF LITERATURE</b> .....	<b>17</b>
<b>Spine</b> .....	<b>17</b>
Function, Anatomy and Development.....	17
Radiography.....	19
<b>Scoliosis</b> .....	<b>23</b>
Historical aspects.....	23
Nomenclature and Classification of Scoliosis.....	23
Primary Scoliosis.....	25
Adolescent Idiopathic Scoliosis.....	25
Epidemiology.....	25
Etiology & Pathogenesis.....	25
Natural History.....	26
Clinical picture & Diagnosis.....	27
Treatment.....	27
Congenital scoliosis.....	37
Epidemiology.....	37
Etiology & Pathogenesis.....	37
Natural history.....	38
Clinical Picture & Diagnosis.....	42
Treatment.....	43
Secondary Scoliosis.....	53
Skeletal Dysplasia.....	53
Diastrophic Dysplasia.....	55
Epidemiology.....	55
Etiology & Pathogenesis.....	55
Natural History.....	55
Clinical picture & Diagnosis.....	57
Treatment.....	58
Neuromuscular scoliosis.....	60
Epidemiology.....	60
Etiology & Pathogenesis.....	60
Natural History.....	61
Clinical picture & Diagnosis.....	64
Treatment.....	65
<b>Spondylolisthesis</b> .....	<b>73</b>

Historical aspects .....	73
Classification of spondylolisthesis.....	73
Isthmic Spondylolisthesis .....	75
Epidemiology .....	75
Etiology & Pathogenesis.....	75
Natural History .....	76
Clinical picture & Diagnosis.....	78
Treatment.....	79
<b>AIMS OF THE PRESENT STUDY .....</b>	<b>87</b>
<b>MATERIALS AND METHODS.....</b>	<b>88</b>
Patients & Treatment Methods .....	88
Study design .....	97
Clinical evaluation .....	97
Radiographic evaluation .....	98
Health-related-quality-of- life Questionnaires .....	99
Statistical Methods .....	100
Ethical Considerations .....	100
Financial Support .....	100
<b>RESULTS .....</b>	<b>101</b>
Surgical Treatment of Congenital Scoliosis by Hemivertebra Resection.....	101
Operative Results.....	101
Radiological Outcomes .....	101
Clinical Outcomes .....	103
Health-related-quality-of-life.....	103
Complications .....	103
Treatment of Scoliosis in Diastrophic Dysplasia .....	104
Brace treatment.....	104
Operative Treatment .....	105
Operative Data .....	105
Radiologic Outcomes.....	105
Clinical Outcomes .....	106
Health-related-quality-of-life Outcomes.....	106
Complications .....	106
Surgical Treatment of Neuromuscular Scoliosis with the Total Pedicle Screw and Hybrid Constructs .....	109
Operative Results.....	109
Radiological Outcomes .....	110
The Health-related-quality-of-life Outcomes.....	110
Complications .....	112
Surgical Treatment of Isthmic Spondylolisthesis in Children and Adolescents .....	114
The Whole Study Population.....	114
The Matched Cohorts.....	116
Operative Results.....	116
Radiological Outcomes .....	119
Clinical Outcomes .....	122
Health-Related-Quality-of-Life Outcomes.....	124
Complications.....	124
Outcome of the Children with Low-grade Slips without Significant Preoperative Pain.....	124

<b>DISCUSSION .....</b>	<b>125</b>
Surgical Treatment of Congenital Scoliosis by Hemivertebra Resection.....	125
Treatment of Scoliosis in Diastrophic Dysplasia .....	128
Surgical Treatment of Neuromuscular Scoliosis with the Total Pedicle Screw and Hybrid Constructs .....	131
Surgical Treatment of Isthmic Spondylolisthesis in Children and Adolescents .....	134
<b>CONCLUSIONS .....</b>	<b>138</b>
<b>SUMMARY .....</b>	<b>139</b>
<b>ACKNOWLEDGEMENTS.....</b>	<b>140</b>
<b>REFERENCES .....</b>	<b>142</b>
<b>ORIGINAL PUBLICATIONS .....</b>	<b>162</b>

# LIST OF ORIGINAL PUBLICATIONS

This thesis is based on the following original publications, which are referred to in the text by their Roman numerals:

- I. **Jalanko T.**, Rintala R., Puisto V., Helenius I., 2011. Hemivertebra resection for congenital scoliosis in young children: comparison of clinical, radiographic, and health-related quality of life outcomes between the anteroposterior and posterolateral approaches. *Spine*, 36, pp. 41-49.
- II. **Jalanko T.**, Remes V., Peltonen J., Poussa M., Helenius I., 2009. Treatment of spinal deformities in patients with diastrophic dysplasia: a long-term, population based, retrospective outcome study. *Spine*, 34, pp. 2151-2157.
- III. Mattila M.\*, **Jalanko T.\***, Puisto V., Pajulo O., Helenius I., 2012. Hybrid versus total pedicle screw instrumentation in patients undergoing surgery for neuromuscular scoliosis: A comparative study with matched cohorts. Submitted.
- IV. **Jalanko T.**, Helenius I., Remes V., Lamberg T., Tervahartiala P., Yrjonen T., Poussa M., Schlenzka D., Operative treatment of isthmic spondylolisthesis in children: a long-term, retrospective comparative study with matched cohorts. *European Spine Journal*, 20(5), pp. 766-775.

\*The authors contributed equally to the study

*These articles are reproduced with the kind permission of their copyright holders.*

# ABBREVIATIONS

AIS = Adolescent idiopathic scoliosis

AP = Anteroposterior

ASF = Anterior spinal fusion

CD = Cotrel-Dubousset instrumentation

CSVL = Center sacral vertical line

DMD = Duchenne muscular dystrophy

ER = Estrogen receptor

FVC = Forced vital capacity

MEP = Motor response evoked potential

MMC = Myelomeningocele

MRI = Magnetic resonance imaging

NMS = Neuromuscular scoliosis

NMSC = Neuromuscular scoliosis correction (by surgical methods)

NS = non-significant (in statistical tests)

ODI = Oswestry disability index

PFT = Pulmonary function test

PL = Posterolateral

PSF = Posterior spinal fusion

P-VCR = Posterior vertebral column resection

SIADH = Syndrome of inappropriate antidiuretic hormone

SMA = Spinal muscular atrophy

SPO = Smith-Petersen osteotomy

SRS-24 = Scoliosis Research Society 24 questionnaire

SSEP = Somatosensory evoked potential

TPS = Total pedicle screw

VAS = Visual analog score



VEPTR = Vertical Expandable Prosthetic Titanium Rib

VC = Vital capacity

VCR = Vertebral column resection

VSD = Ventral derotation spondylodesis

## ENGLISH ABSTRACT

Scoliosis (lateral curvature of the spine) and spondylolisthesis (forward displacement of a vertebra in relation to its adjacent vertebra) are common spinal deformities in children and adolescents. The most common cause of scoliosis in young people is the adolescent idiopathic scoliosis (prevalence 1.5 – 4.1 %). Scoliosis can arise by various other ways such as by congenital spinal anomalies, skeletal dysplasia or neuromuscular diseases, in which cases the deformity is usually more severe, disabling and possibly fatal. In children and adolescents, isthmic spondylolisthesis (caused by stress fracture in the pars interarticularis) is the most common form of spondylolisthesis and presents itself by low back pain, postural anomalies or radiculating pain to the lower extremities. The natural history of isthmic spondylolisthesis is commonly benign but in some patients the deformity becomes so severe that it causes unrelenting pain and a risk for a neurologic deficits of the lower extremities.

While most of these spinal deformities in children and adolescents can be treated successfully with conservative treatment methods (bracing, physical therapy, activity modification), surgical treatment is validated when the deformity is progressive and causes marked imbalance of the trunk, disability, pain or impairment of pulmonary function. The golden standard in spinal deformity surgery is posterior spinal fusion. Large, rigid scoliosis curves in diastrophic dysplasia and neuromuscular disease, and early-onset scoliosis, caused by congenital spinal anomalies, are difficult conditions to manage by traditional treatment methods. Specialized surgical methods (combined anteroposterior approach and spinal osteotomies) are often warranted and this may complicate postoperative recovery. The newest instrumentation systems, the total pedicle screw (TPS) and hybrid (combination of hook, wire and screw) constructs, have achieved better spinal deformity correction in adolescent idiopathic scoliosis than older systems. In severe non-idiopathic scoliosis, their use has not been established. It is believed that these new segmental spinal instrumentations can improve outcomes in the more severe forms of scoliosis as well and that the necessity to perform combined anteroposterior approach would decrease. The aim of this study was to evaluate the outcomes of modern surgical techniques and instrumentations and the need to perform the combined anteroposterior approach in the following areas: hemivertebra excision in congenital scoliosis and spinal fusion in diastrophic dysplasia, neuromuscular scoliosis and isthmic spondylolisthesis.

In total, 402 patients were treated for scoliosis (n=104) or isthmic spondylolisthesis (n=298) in the Children's Hospital of the Helsinki University Central Hospital and ORTON Orthopaedic Hospital in Helsinki, Finland and were included in this retrospective cohort study. Congenital scoliosis patients (n=21) were consecutively operated on by hemivertebra resection and divided into two equal sized unmatched cohorts according to the surgical approach (anteroposterior vs posterior only). All diastrophic dysplasia patients (n=17) who were treated at our institution by bracing (n=8) and/or surgery (n=12) were enrolled. In neuromuscular scoliosis, we formed two matched (age, gender, deformity, neurologic condition) cohorts of patients who were operated on by total pedicle screw (n=33) or hybrid instrumentation (n=33). In isthmic spondylolisthesis, we compared surgical treatment results between a group of child patients (n=41; 24 females ≤ 12 years; 17 males ≤ 14 years) and a matched (gender, operative method, the degree of deformity, age at final follow-up) cohort of adolescent patients (n=41; 24 females > 12 years; 17 males > 14 years) who were extracted from the same original cohort of 298 patients. Patients' clinical medical records, radiographs and health-related-quality-of-life questionnaires (Scoliosis Research Society 24 [SRS-24], Oswestry disability index [ODI], Visual analog scale [VAS] for back pain) were evaluated to assess treatment outcomes.

Congenital scoliosis patients, who were operated on by posterior only hemivertebra excision had similar median radiographic major curve correction (64 % vs. 76 %), SRS-24 total score (102 vs. 104) and sub-domain outcomes and complication rate (40 % vs 17 %) at short-term final follow-up when compared to patients operated on by the anteroposterior hemivertebra excision (p=NS for all comparisons). In diastrophic dysplasia, 4 out of 8 patients progressed to surgery despite of brace treatment. At a median of 14 years after surgery, diastrophic dysplasia patients who underwent anteroposterior spinal fusion had a better major curve correction (32 % vs 15 %, p=0.017) and ODI (11 % vs. 30 %, p=0.025) while SRS-24 and VAS outcomes and the amount of complications (40 % vs 50 %) were similar. Neuromuscular scoliosis patients who were operated on by hybrid instrumentation underwent anteroposterior surgery more often (39 % vs 12 %) and Ponte osteotomies less often (27 % vs. 64 %) than patients operated on by TPS constructs. At short-term final follow-up, pelvic obliquity and sagittal balance corrections and complication rates were similar between TPS and hybrid instrumentation groups, but major curve correction was better in the TPS group (75 % vs 64 %, p=0.001). In isthmic spondylolisthesis, children and adolescents had similar health-related-quality-of-life outcomes (children vs. adolescents; low-grade slip: SRS-24: 95.9 vs. 92.0, ODI: 5.2 vs. 7.5, VAS low-back pain: 18.9 vs. 21.2; high-grade slip: SRS-24: 95.6 vs. 90.6, ODI: 3.4 vs. 6.9, VAS low-back pain: 10.5 vs. 22.1; statistically significant differences in ODI and VAS in high-grade patients). Bony remodeling after surgery lead to slip correction (14 % points) in children with high-grade slips while in adolescents this was not observed.

In conclusion, this study suggests that posterior spinal surgery with modern segmental instrumentation can achieve comparable results with the combined anteroposterior approach in patients undergoing surgical treatment of neuromuscular scoliosis and congenital scoliosis due to hemivertebra. The necessity to perform combined anteroposterior spinal fusion was decreased in neuromuscular scoliosis patients with the use of the total pedicle screw construct and Ponte osteotomies. The combined anteroposterior approach still holds a place in the treatment of severe scoliosis resulting from diastrophic dysplasia and high-grade isthmic spondylolisthesis in both children and adolescents.

# SUOMENKIELINEN ABSTRAKTI

Skolioosi (selkärangan käyristyneisyys sivusuunnassa) ja spondylolisteesi (selkänikaman siirtyminen eteenpäin viereiseen nikamaan nähden) ovat yleisiä selkärankaepämuodostumia lapsilla ja nuorilla. Skolioosin yleisin syy nuorilla ihmisillä on nuoruusajan idiopaattinen (tuntemattomasta syystä johtuva) skolioosi, jonka esiintyvyys on 1.5 – 4.1 %. Skolioosi voi syntyä myös muista syistä johtuen kuten synnynäisten selkänikamaepämuodostumien, luustokehityshäiriön tai hermo-lihastaudin takia, jolloin epämuodostuma on yleensä vaikeampi, invalidisoivampi ja mahdollisesti kuolemaan johtava. Spondylolisteesin yleisin muoto lapsilla ja nuorilla on istminen spondylolisteesi (syynä rasitusmurtuma lannerangan alimman selkänikaman pars interarticulariksessa) ja sen oireita on alaselkäkipu, seisomatasapainon häiriö tai alaraajoihin säteilevä kipu. Istmisen spondylolisteesin luonnonhistoria on yleensä hyvänlaatuisen, mutta joidenkin harvojen potilaiden kohdalla nikaman siirtymä etenee niin vaikeaksi, että se aiheuttaa hellittämätöntä alaselkäkipua, merkittävän alaselän virheasennon ja voi johtaa alaraajojen hermostovaurioon.

Vaikka suurin osa lasten ja nuorten selkärangan virheasunnoista voidaan hoitaa konservatiivisesti (korsettihoito, fysioterapia, rasituksen välttäminen), leikkaushoitoa tarvitaan etenevissä virheasunnoissa, jotka aiheuttavat merkittävän vartalon epätasapainon, invaliditeetin, selkäkipun tai hengitystoiminnan heikkenemisen. Selkärangan luuduttaminen takakautta on yleisin leikkaushoitomuoto selkärangan virheasunnoissa. Isot, jäykät skolioosikäyryydet diastrofisisessa luustokehityshäiriössä ja hermolihastaudeissa sekä aikaisin lapsuudessa syntyvä skolioosi synnynnäisistä nikamaepämuodostumista johtuen ovat vaikeahoitaisia tavanomaisilla hoitomenetelmillä. Näissä tilanteissa tarvitaan monesti erikoisleikkausmenetelmiä kuten yhdistettyä etu- ja takakautta tehtävää selkärankakirurgiaa tai selkänikaman poistoja, joihin voi kuitenkin liittyä merkittävimpiä ongelmia leikkauksen aikana ja jälkeen.

Uudet selkärangan virheasentojen korjaukseen käytettävät instrumentaatiot, kokopedikkeliruuvi ja hybridi (pedikkeliruuvi, koukku, lanka yhdistelmä) kiinnityksellä, ovat aikaansaaneet parempia virheasennon korjaustuloksia nuoruusajan idiopaattisessa skolioosissa. Koska kokemus näiden instrumentaatioiden käytöstä on lyhytaikainen, niiden aikaansaamista tuloksista harvinaisemmissa ja vaikeammissa selkärankaepämuodostumissa ei ole tarpeeksi tietoa. Tämänhetkinen uskomus on se, että nämä uudet instrumentaatiot pystyisivät parantamaan leikkaustuloksia myös vaikeammissa tautimuodoissa sekä vähentämään etu- ja takakautta tehtävän kirurgian tarvetta. Tämän tutkimuksen tarkoituksena oli arvioida uusien leikkaustekniikoiden vaikutusta selkärangan virheasentojen hoitotuloksiin lapsilla ja nuorilla. Tavoitteena oli selvittää etu- ja takakautta tehtävän selkäleikkausten tarvetta selkänikaman poistoleikkauksissa synnynnäisessä skolioosissa ja selkärangan luudutuksessa diastrofisisessa dysplasiasta ja hermolihastaudesta johtuvassa skolioosissa sekä istmisessä spondylolisteesissä.

Kokonaisuudessaan 402 potilasta hoidettiin skolioosin (21 synnynnäistä skolioosipotilasta, 17 potilasta jolla oli diastrofinen dysplasia sekä 66 potilasta jolla oli hermolihastauti) tai istmisen spondylolisteesin (n=298) vuoksi Yliopistollisen keskussairaalan Lastenkliniikalla ja Sairaala ORTON:ssa Helsingissä. Tutkimus oli taaksepäin katsova ja siihen anottiin lupa eettiseltä toimikunnalta. Selkärangan virheasentojen hoidon tuloksia arvioitiin läpikäymällä kliiniset potilasasiakirjat, röntgenkuvat sekä yleisesti käytössä olevat oire- ja tyytyväisyyskyselylomakkeet (SRS-24, ODI, VAS).

Pelkästään etukautta tehdyn ja etu- ja takakautta tehdyn selkänikamapoistoleikkauksen jälkeen, synnynnäistä skolioosia sairastavilla potilailla oli yhtäläiset tulokset skolioosikäryyden korjausasteessa, oirekyselylomakkeiden pisteissä sekä leikkauskomplikaatioiden määrässä lyhytaikaisessa seurannassa. Diastrofista dysplasiasta johtuvassa skolioosissa puolet korsettihoitetuista potilaista joutuivat leikkauksen skolioosin pahentumisen takia. Etu- ja takakautta luudutetuilla potilailla oli parempi skolioosikäryyden korjausaste (32 % vs 15 %) sekä ODI tulos pitkäaikaisen seurannan jälkeen kun taas muista oirekyselylomakkeista saadut tulokset ja leikkauskomplikaatioiden määrä oli yhtenäinen eri leikkausmenetelmien välillä diastrofisessa dysplasiassa. Hermolihastaudeista johtuvassa skolioosissa, etu- ja takakautta tehtävien luudutusleikkausten osuus oli suurempi ja fasettivelalueen luukatkaisuiden osuus oli pienempi hybridi-instrumentoiduilla potilailla verrattuna potilaisiin joilla käytettiin kokopedikkeliruuvitekniikkaa. Selkärangan epätasapainon ja lantion virheasennon korjaustulokset sekä leikkauskomplikaatioiden määrät olivat yhtäläisiä eri tekniikkojen välillä, mutta kokopedikkeliruuvi-ryhmässä aikaansaatii lievästi parempi skolioosikäryyden korjausaste lyhytaikaisessa seurannassa (75 % vs 64 %). Istmisen spondylolisteesin luudutusleikkaukset aikaansaiivat yhtäläiset oirekyselylomaketulokset lapsilla ja nuorilla. Lapsilla, joilla oli vaikea-asteinen nikamasiirtymä, todettiin luuston uudelleenmuovautumisesta johtuvaa siirtymän korjaantumista (14 % yksikköä) pitkäaikaisessa seurannassa kun taas nuorilla tätä ei havaittu.

Tässä tutkimuksessa selvisi, että pelkästään takakautta tehtävä selkärankaleikkaus modernilla kokopedikkeliruuvi-instrumentaatiolla näyttäisi aikaansaavan yhtäläisiä tuloksia lyhytaikaisessa seurannassa kuin etu- ja takakautta tehtävä leikkaus hermolihastaudista ja synnynnäisistä nikamaepämuodostumista johtuvassa skolioosissa. Yhdistetyn etu- ja takakautta tehtävän selkäkirurgian osuus oli pienempi hermolihaustiskolioosissa potilailla, jotka oli leikattu kokopedikkeliruuvitekniikalla. Yhdistetyllä etu- ja takakautta tehtävällä selkärangan luudutuksella saadaan hyviä tuloksia diastrofisessa dysplasiassa sekä vaikea-asteisessa istmisessä spondylolisteesissä.

# INTRODUCTION

Scoliosis and spondylolisthesis are common spinal deformities in children and adolescents (Weinstein et al. 2008; Hu & Bradford 2001). The treatment methods of scoliosis are observation, bracing and surgery (Weinstein et al. 2008). In addition to these methods, physical therapy and restriction from sports can be used successfully in isthmic spondylolisthesis (Agabegi & Fischgrund 2010). The efficacy of particular treatment option depends mainly on the underlying cause of the spinal deformity, its severity and the age and growth potential of the patient. Posterior spinal fusion is the most common operative method and sufficient when the scoliosis or spondylolisthesis is moderate. (Weinstein et al. 2008; Seitsalo et al. 1991; Winter et al. 1984; Lonstein & A. Akbarnia 1983; Matsuyama et al. 1999) When the deformity is severe, specialized methods such as the combined anteroposterior spinal fusion or osteotomies, may be necessary to obtain sufficient correction and fusion of the spinal deformity and good clinical and health-related-quality-of-life outcomes (Lenke 2003; Helenius et al. 2006; Suk et al. 2002). With the advent of modern day segmental instrumentations, the total pedicle screw and hybrid constructs, the necessity to perform combined anteroposterior spinal surgery has come under evaluation (Suk et al. 2007; Ruf & Harms 2002).

Congenital hemivertebra can cause severe scoliosis of early onset (M. J. McMaster & Ohtsuka 1982). The surgical hemivertebra excision has been found to be an effective treatment method and avoids the need to perform extensive spinal fusion which might be more harmful for a growing child (Yaszay et al. 2011). Hemivertebra excision can be performed either by combined anteroposterior or more recently by the posterior only approach. It is currently unknown which method is more beneficial.(Hedequist et al. 2005; Ruf & Harms 2002)

Diastrophic dysplasia is a rare skeletal dysplasia that is associated with severe, rigid scoliosis (Walker et al. 1972; Remes et al. 2001). The efficacy of bracing and surgical treatment in this patient population is poorly known (Poussa et al. 1991).

In the recent years, the total pedicle screw construct has achieved better radiologic outcomes in spinal deformity correction in adolescent idiopathic scoliosis than hybrid constructs with combinations of hooks and screws (Kim et al. 2006; Suk et al. 1995). This finding has raised hopes that it could improve the results of surgical treatment in neuromuscular scoliosis, which is associated with severe spinal deformities. The complication rate is known to be high in this patient population and it has been questioned whether the combined anteroposterior approach, which is quite commonly used in neuromuscular scoliosis, would be partly to blame (Reames et al. 2011). It is currently not known whether total pedicle screw constructs can achieve better spinal deformity correction than hybrid constructs in neuromuscular scoliosis and whether the need to perform anteroposterior surgery would decrease.

Isthmic spondylolisthesis is usually benign and can be treated with conservative methods (Hu & Bradford 2001; Agabegi & Fischgrund 2010). Sometimes the symptoms can persist despite of conservative treatment or the deformity can progress so severe that surgical treatment is eventually required (Pizzutillo & Hummer 1989; Seitsalo et al. 1991). Using the posterolateral and combined anteroposterior spinal fusion in situ has given good results in adolescents but there are only sparse reports of their use in children before pre-adolescent growth spurt (Remes et al. 2006; Seitsalo et al. 1990).

## Introduction

---

The aim of this study was to investigate the efficacy of the modern surgical techniques and instrumentations in the treatment of isthmic spondylolisthesis and scoliosis resulting from congenital hemivertebra, diastrophic dysplasia and neuromuscular disease. The necessity of performing combined anteroposterior approach was evaluated.

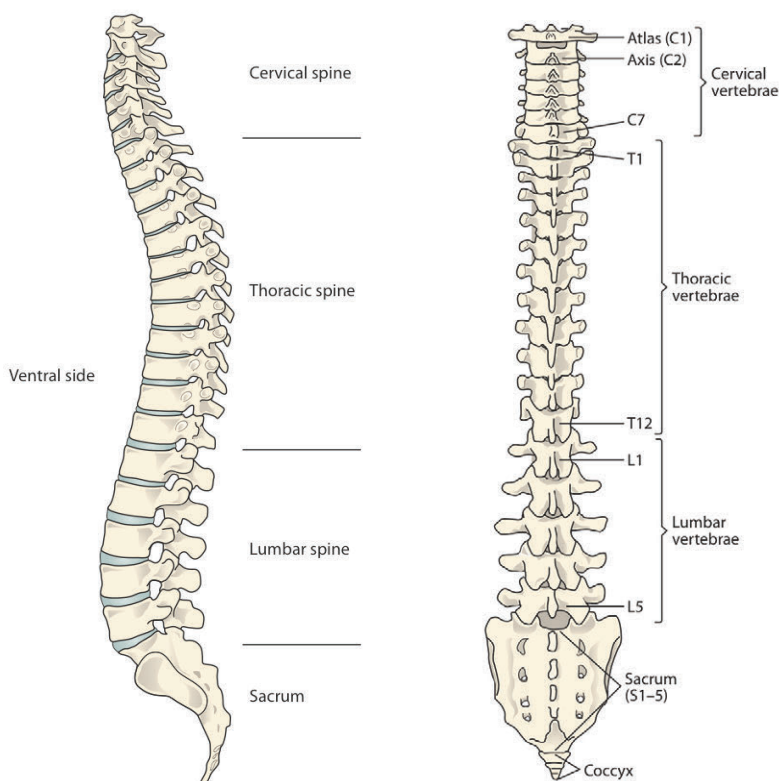
## REVIEW OF LITERATURE

### Spine

#### Function, Anatomy and Development

##### *Function*

The spine is a columnar assemblage of vertebrae from the cranium through the coccyx. In collaboration with adjacent ligamentous structures and musculature, the human spine supports the body's weight, posture and gait, transmits forces through the pelvis to the lower extremities, carries and balances the head and the upper extremities and helps their maneuvering. The spine also contains and protects the spinal cord and proximal parts of the spinal nerves (Figure 1). (Moore & Dalley 2006)

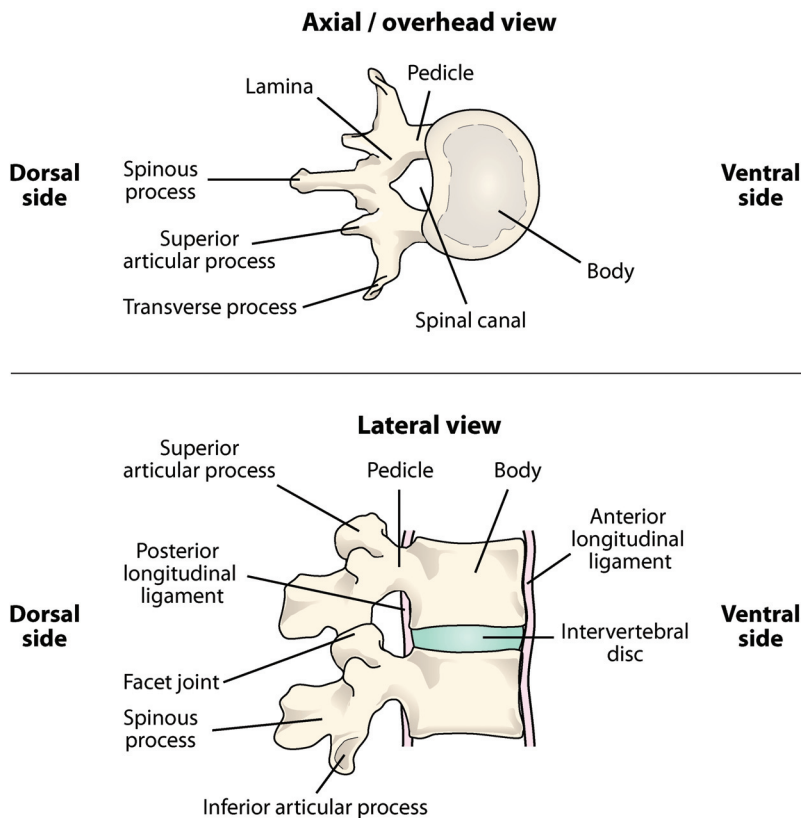


**Figure 1.** The lateral and posterior view of the human spine



### Anatomy

The normal human spine consists of 33 vertebrae, of which seven are cervical, twelve are thoracic, five are lumbar, five are sacral and three to four are coccygeal. The individual vertebrae are referred to by their location and number of order, e.g. the uppermost lumbar vertebra is L1 and the lowermost is L5. The specific characteristics of the vertebrae vary according to their location in the spine. A typical vertebra consists of a vertebral body and the posterior vertebral arch (neural arch). The vertebral arch consists of two pedicles, two laminae, two transverse processes and one spinous process (Figure 2). (O'Brien et al. 2004)



**Figure 2.** Axial and lateral views of a human vertebrae.

Two vertebrae are connected dorsally by two facet joints and ventrally by the intervertebral disc. The anterior longitudinal ligament and the posterior longitudinal ligament support the spinal column by being attached to the vertebral bodies anteriorly and posteriorly, respectively. Other ligamentous structures supporting the spine are the ligamentum flavum passing between adjacent laminae, the interspinous ligament passing between adjacent spinous processes and the supraspinous ligament running along the dorsal border of the spinous processes and the interspinous ligaments. The spinal nerves emerge from the intervertebral foramen, which is surrounded by pedicles, the vertebral body, intervertebral discs and the facet joint. (Moore & Dalley 2006)

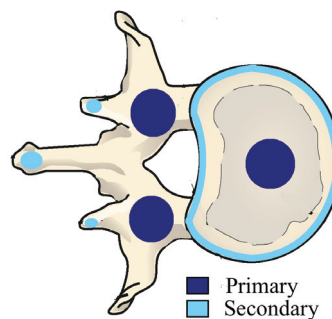
In the normal spine, the vertebrae lie straight in the coronal plane and in the sagittal plane there is a subtle cervical lordosis, thoracic kyphosis and lumbar lordosis. When the spine is balanced, the head

## Review of Literature - Spine

is situated above the center of the sacrum in coronal plane and above the femoral heads in the sagittal plane. (O'Brien et al. 2004)

### **Development**

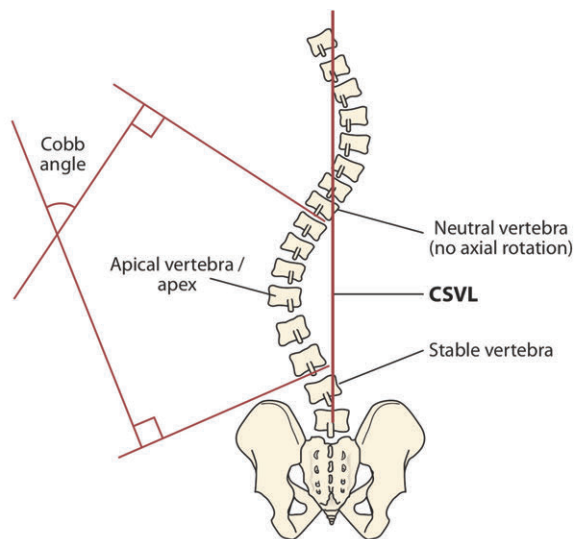
During embryonic period, the typical human vertebrae begin to develop as mesenchymal condensations around the notochord. Later in embryogenesis, around the 8<sup>th</sup> week of gestation, these mesenchymal models of vertebrae begin to ossify in three primary ossification centers. At birth, each vertebra, except the lowermost sacral and coccygeal vertebrae, consist of three bony parts connected by hyaline cartilage. These parts start to fuse during the first year of life and it is not complete until the 6<sup>th</sup> year of life. Five secondary ossification centers develop during puberty (Figure 3). The epiphyseal growth plates bring about vertical growth of the vertebral body. All secondary ossification centers are developed by the age of 25. Exceptions to this typical growth pattern occur in C1, C2, C7 and the sacral and coccygeal vertebrae. The ribs develop from primordial costal elements, which lie in association with the secondary transverse process ossification centers, in the thoracic region. (Ganey 2001)



**Figure 3.** Primary and secondary ossification centers (Moore & Dalley 2006)

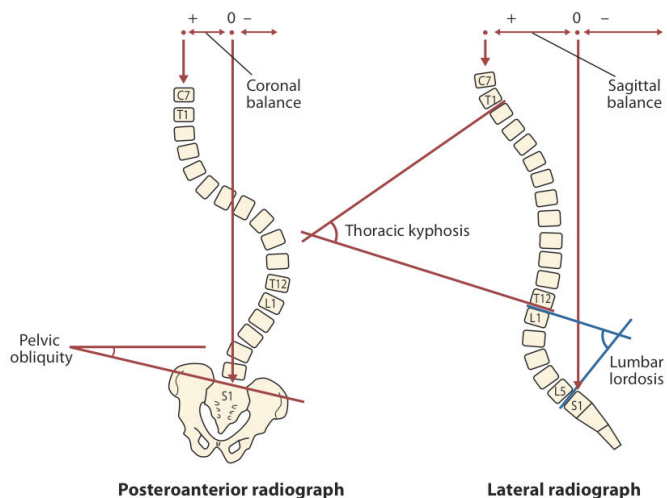
### **Radiography**

When a physician suspects a spinal deformity in a patient, posteroanterior (coronal) and lateral (sagittal) radiographs of the spine are obtained. The proximal (apex T1-T7), mid-thoracic and thoracolumbar (apex T8-L1) and lumbar (apex L2-L5) curves are measured by the Cobb technique in the coronal plane (Cobb 1948). The center Sacral Vertebral Line (CSVL) is a vertical reference line running through the middle of the sacrum in the coronal plane. The apical vertebra of a scoliosis curve is the most laterally deviated vertebra from the CSVL. In structural scoliosis, there is always a rotation around the axis of the vertebrae belonging to the curve, so that the spinous processes rotate towards the concavity. Stable and neutral vertebrae are located on the edges of the curve and do not have axial rotation. (Figure 4)(O'Brien et al. 2004)



**Figure 4.** The Cobb angle, center sacral vertebral line (CSVL), apical, neutral and stable vertebra.

The coronal spinal balance is measured as the horizontal distance (mm) between the centers of the C7 and S1 vertebrae on the coronal plane (normal range -20 - 20 mm). Pelvic obliquity refers to the angle between a horizontal reference line and a line intersecting the superior border of the iliac crests or the upper endplate of S1 vertebra. Sagittal spinal balance is measured as the horizontal distance (mm) between the center of C7 and the posterocranial corner of S1 vertebrae in the sagittal plane (normal range -20 – 20 mm). Thoracic kyphosis is measured between the upper end plate of T2 and lower endplate of T12 (normal range 20-45°) and lumbar lordosis between the upper endplate of L1 and the lower endplate of L5 from the sagittal plane (normal range 20-60°). (Figure 5)(O'Brien et al. 2004)

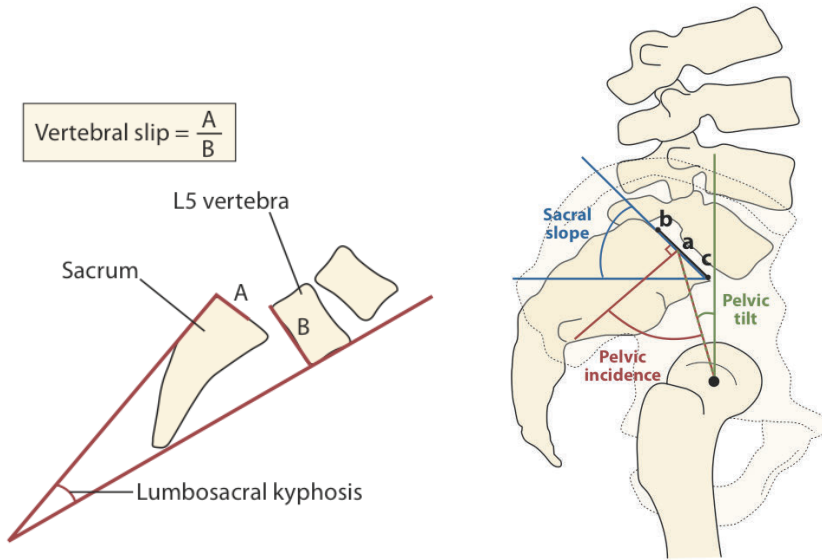


**Figure 5.** Coronal balance, pelvic obliquity, sagittal balance, thoracic kyphosis and lumbar lordosis

Several scoliosis classifications, like the ones by King and Lenke, have been developed to aid the selection of treatment. The Lenke classification is a new system developed for adolescent idiopathic scoliosis and has been found to have better intra- and interobserver reliability than the King classification. It categorizes scoliosis by curve type (1-6), by the lumbar spine modifier (A-C) and by the sagittal thoracic modifier (-, N, +). The curve type is determined by the positions (thoracic T2-T11, thoracolumbar T12-L1, lumbar L2-L5) of the major and minor structural and nonstructural curves. The major curve has the greatest Cobb angle and is always structural. The minor curves are classified into structural ones if the Cobb angle exceeds 25° in a side bending radiograph and/or the kyphosis exceeds 20° at the same level. The lumbar spine modifier is used to assess the extent of lumbar deformity, which has significant effect on spinal balance and proximal curves when an operation is performed. The CSVL determines the lumbar modifier grade (A-C) depending on, how the stable vertebra bisects the CSVL. The sagittal thoracic modifier is also a significant factor affecting operative treatment and states the degree of thoracic kyphosis (T5-T12). (Lenke et al. 2001)

In spondylolisthesis, the degree of vertebral slip and spinopelvic alignment are the most important aspects to evaluate (Figure 6) (Laurent & Einola 1961; Boxall et al. 1979; Seitsalo et al. 1991; Agabegi & Fischgrund 2010). According to Laurent and Einola, the vertebral slip is the percentage of the width of the olisthetic vertebral body (Laurent & Einola 1961). There are several methods to assess spinopelvic alignment. Lumbosacral kyphosis can be measured as the sagittal rotational angle between the posterior border of S1 and the anterior border of L5 (Wiltse & Winter 1983). The pelvic incidence is a constant parameter of spinopelvic alignment and its degree is independent of the position of the body. It is the mathematical sum of sacral slope and pelvic tilt (Figure 6). Sacral slope is the angle between the upper endplate of S1 and a horizontal reference line and pelvic tilt is the angle between a line intersecting the femoral head and the middle of the upper endplate of S1 and a vertical reference line. (Hresko et al. 2007) It is known from previous studies that pelvic incidence remains constant during childhood, increases during normal growth spurt in adolescence and remains constant in adulthood (Descamps et al. 1999). Normally, pelvic incidence ranges between 45-60° (O'Brien et al. 2004).

In spondylolisthesis, an abnormal pelvic incidence is observed quite frequently especially in the high-grade ( $\geq 50\%$  slip) types. The sacropelvic alignment can be regarded as balanced or unbalanced according to pelvic incidence. In a recent classification proposed by Spinal Deformity Study Group, spondylolisthesis is classified into six types according to radiographic slip grade and spinopelvic balance. There are three types of low-grade ( $< 50\%$  slip) and three types of high-grade ( $\geq 50\%$  slip) spondylolisthesis. The low-grade types are differentiated according to pelvic incidence: type I has a "nutcracker" spinopelvic alignment (pelvic incidence  $< 45^\circ$ ), type II has normal pelvic incidence ( $45-60^\circ$ ) and type III has a high pelvic incidence ( $>60^\circ$ ). The high-grade types are differentiated into balanced and unbalanced sacropelvis according to sacral slope and pelvic tilt as follows: type IV has balanced sacropelvis (high sacral slope and low pelvic tilt), type V has unbalanced sacropelvis but balanced sagittal spinal alignment (low sacral slope, high pelvic tilt and C7 plumbline falls onto or behind the hip axis) and type VI has both unbalanced sacropelvis and sagittal spinal alignment (low sacral slope, high pelvic tilt and C7 plumbline falls in front of the hip axis). (Hresko et al. 2007)



**Figure 6.** Vertebral slip, lumbosacral kyphosis, pelvic incidence, sacral slope and pelvic tilt

# **Scoliosis**

## **Historical aspects**

Scoliosis was described first by Hippocrates (460 – 380 BC) (Vasiliadis et al. 2009). The first author to use the word idiopathic scoliosis is thought to be Louis Bauer in the middle of the nineteenth century (Lowe et al. 2000). Cobb introduced the classification and measurement of scoliosis in 1948 (Cobb 1948). The first modern brace, for the treatment of scoliosis, was introduced by Blount in 1958 (Blount 1965). Harrington was the first author to describe an instrumented correction and spinal fusion of scoliosis in the 1960s (Harrington 1962).

## **Nomenclature and Classification of Scoliosis**

Scoliosis is derived from the Greek word for curvature and described as the lateral deviation from the normal straight vertical line of the spine (Anderson et al. 2003). Scoliosis is classified into primary and secondary forms. Primary scoliosis is either idiopathic or congenital. Secondary scoliosis results from neuromuscular, traumatic or other causes like skeletal dysplasia. (Weinstein 2001) (Table 1)

## Review of Literature - Scoliosis

**Table 1.** The classification of scoliosis according to the Scoliosis Research Society. Modified from the table introduced in The Pediatric Spine. (Weinstein 2001)

SCOLIOSIS	
<i>Primary</i>	<i>Secondary</i>
Idiopathic	Neuromuscular
Infantile (0-3 years of age)	Skeletal dysplasia (e.g. Diastrophic dysplasia)
Juvenile (4 years to puberty onset)	Mixed (associated with neural tissue defect)
	Neurofibromatosis
Adolescent (puberty onset to epiphyseal closure)	Mesenchymal (eg. Marfan syndrome)
Adult (after epiphyseal closure)	Traumatic
	Tumor
Congenital	Soft tissue contractures
Failure of formation	Rheumatoid disease
Partial unilateral (wedge vertebra)	Metabolic
Complete unilateral (hemivertebra)	Related to spondylolysis
Failure of segmentation	Thoracogenic
Unilateral (unilateral unsegmented bar)	Functional
Bilateral (bloc vertebra)	Hysterical

## **Primary Scoliosis**

### **Adolescent Idiopathic Scoliosis**

The adolescent idiopathic scoliosis (AIS) is one of the most common spinal deformities observed in humans. It is usually observed for the first time in female patients during the period of rapid growth in puberty. The natural history of this condition is usually benign and when treatment is required, good long-term results can be achieved by bracing and surgery. (Weinstein et al. 2008)

### **Epidemiology**

The prevalence of AIS is 1.5 – 4.1 % (Parent et al. 2005; Kesling & Reinker 1997; Nissinen et al. 1989). AIS develops more commonly in females (incidence 3-9/1000) than in males (0-3/1000). (Riseborough & Wynne-Davies 1973; Wynne-Davies 1968)

### **Etiology & Pathogenesis**

The precise etiopathogenesis of AIS is still unknown, but it is believed to be a complex, multifactorial process (Weinstein et al. 2008; Lowe et al. 2000). According to previous studies, there is a strong genetic component in this disease (Kesling & Reinker 1997; Ogilvie et al. 2006; Lowe et al. 2000). The prevalence of idiopathic scoliosis is higher among first-degree relatives (approximately 11 %) compared to the general population. When investigating the prevalence in first-degree relatives, idiopathic scoliosis is more common in a mother or sister (17-19 %) than in a father or brother (3-4 %) (Riseborough & Wynne-Davies 1973). A meta-analysis made by Kesling and coworkers showed a 73 % concordance among monozygous and 36 % concordance among dizygous twins (Kesling & Reinker 1997). The mode of inheritance has been under debate. Multiple genes and an autosomal dominant inheritance pattern has been associated with this disease (Wynne-Davies 1968; Ogilvie et al. 2006; Lowe et al. 2000; Weinstein et al. 2008). Several candidate genes have been associated with the development of AIS (Miller et al. 1996; Gao et al. 2007; Ward et al. 2010).

Extensive studies have been performed to investigate other possible factors behind AIS. These studies have implicated melatonin, the connective tissue supporting the spinal column, platelet morphology, neurological and biomechanical mechanisms with this disease but they have not been able to prove that these changes are truly primary and not secondary to the spinal deformity. (Beuerlein et al. 2001; Pedrini et al. 1973; Echenne et al. 1988; Herman et al. 1985; Lam et al. 2011; Lowe et al. 2000; Weinstein et al. 2008)



Spinal growth has been associated with progression of AIS in previous studies. The hypothesis is that the anterior parts of vertebrae grow more rapidly in comparison to posterior structures, which leads to forward bending of the vertebral bodies at the apex and these vertebrae tend to move out of the way by rotating to the side. (Lowe et al. 2000) It has been noted that patients with AIS are taller, have higher thoracic vertebrae and greater height-to-width ratio than control patients, but no conclusive data has been presented that it would be an etiological factor (Bjure et al. 1968; Carr et al. 1993). To date, the findings in studies on hormonal control of growth in AIS have not been consistent and the role of growth hormones on the etiopathogenesis of AIS remains inconclusive (Lowe et al. 2000; Weinstein et al. 2008).

### **Natural History**

The natural history of untreated AIS is variable and depends on the scoliosis curve pattern. The most common long-term problems are curve progression, back pain and psychosocial concerns. (Weinstein et al. 2008)

The progression of scoliosis curve tends to continue throughout the patients' entire life, but the progression rate per year depends on several factors. The main predictive factors of progression at the time of diagnosis are skeletal immaturity, larger curve size and thoracic location of the curve apex. (Bunnell 1986) Clear consensus has not been reached on the prevalence of back pain in untreated AIS patients. In the study by Ascani et al., the prevalence of back pain was similar as in the normal population while in the study by Weinstein et al., the prevalence of both acute and chronic back pain was significantly more common in AIS. The severity of pain, however, after a long-term follow-up is considered to be mild in most cases and severe disability has not been found in excessive amounts in patients when compared to healthy controls. (Ascani et al. 1986; Weinstein et al. 2003) Health-related-quality-of-life outcomes have been generally good, but psychosocial disturbance has been observed especially in female patients and in cases of thoracic scoliosis exceeding 40° (Danielsson et al. 2010; Goldberg et al. 1994; Ascani et al. 1986; Weinstein et al. 2003).

Respiratory problems rarely arise in patients with AIS (Weinstein et al. 2008). Decrease in vital capacity has been found to be associated with curve size, a more cranially located main curve, vertebral rotation and thoracic lordosis. However, the spinal deformity in AIS is rarely substantial enough to cause severe pulmonary problems (Barois 1999; Kearon et al. 1993) Cardiopulmonary symptoms have been reported by 22 % of untreated idiopathic scoliosis patients in their 40s (Ascani et al. 1986). In health-related-quality-of-life questionnaires, patients did not report more shortness of breath than control patients after a 50 year follow-up (Weinstein et al. 2003). Problems with pulmonary function have been associated with higher degrees of thoracic scoliosis (Weinstein et al. 1981). The risk for cardiorespiratory failure and death has been found to be elevated in the infantile and juvenile forms of idiopathic scoliosis but not in most of the adolescent forms (Pehrsson et al. 1992; Branthwaite 1986).

## **Clinical picture & Diagnosis**

AIS patients are usually referred to a physician because of cosmetically disturbing body asymmetries(Weinstein 2008). In the clinical examination, patients are screened with the Adam's forward bend test and a scoliometer, in which a tilt of 8° or more warrants further investigation(Adams 1865; Helenius 2009). Definitive diagnosis of AIS is a lateral curvature of the spine with a Cobb angle exceeding 10° observed in posteroanterior radiograph in an otherwise healthy adolescent (Kane 1977).

## **Treatment**

### **Observation & Physical Therapy**

When the main curve is 10 - 25° in a growing patient with AIS, observation is performed by obtaining posteroanterior standing radiographs of the spine regularly until the cessation of growth (Parent et al. 2005). In some countries, physical therapy is used to prevent curve progression and to enhance the effects of bracing and counter-act its side-effects, like hip flexion contractures (Negrini et al. 2012; Weinstein et al. 2008).

The results on the efficacy of physical therapy in preventing progression of AIS have been inconclusive. While some of the newer studies have provided low-quality evidence in favor of physical exercises in AIS, well-designed randomized controlled trials are lacking.(Focarile et al. 1991; Stone et al. 1979; Negrini et al. 2008; Fusco et al. 2011; Weiss et al. 2003)

### **Bracing**

Bracing is commonly used in immature patients (Risser sign 0-1) with major curves between 25° and 45°. The aim is to prevent progression until the patient has reached skeletal maturity and to avoid surgery.(Negrini et al. 2012)

The Milwaukee brace (extending from the cervical to the lumbar spine) was introduced first in 1958 (Blount 1965). Thereafter, the development of scoliosis braces has continued from rigid thoracolumbosacral orthoses (TLSO) to the non-rigid Boston braces with the aim of improving patient comfort (Veldhuizen et al. 2002; Coillard et al. 2003).

In their most recent SOSORT guideline and systematic review, Negrini et al. concluded that there is no single brace significantly better than another in all situations(Negrini et al. 2012). The type and location of the major curve is a significant factor. A low-profile brace can not be expected to be efficient in curves with upper thoracic apexes.(Noonan 2001) The 23-hour per day program has been found to be the most succesfull protocol (Rowe et al. 1997).

Despite the long history of brace treatment, its effectiveness has not been explicitly proven. US Preventive Services Task Force has questioned the efficacy of screening and bracing in the treatment of AIS (Sox et al. 1993). In their prospective study, Peterson and Nachemsson found that bracing can prevent scoliosis progression ( $\geq 6^\circ$ ) before the age of 16 in most of the patients and is more effective than observation or electrical stimulation (Nachemson & Peterson 1995). Rowe et al. and Maruyama et al. concluded bracing to be effective in preventing progression when compared to observation alone in their meta-analyses (Rowe et al. 1997; Maruyama et al. 2011).

In the quality of life (QoL) studies, bracing has not been found to cause substantial long-term negative effects (Maruyama et al. 2011; Danielsson & Nachemson 2003). It is, however, probable that psychological distress, like lower self-esteem and body image, is afflicted on the patient at least at the initiation of bracing (Fällström et al. 1986; Weinstein et al. 2008). Other downsides and complications related to bracing are pain, alterations in renal and pulmonary function, nerve and skin irritation. These problems, however, are usually mild and transient. (Noonan 2001)

### **Surgery**

The indication for surgery in AIS is a Cobb angle exceeding  $45^\circ$  in a growing patient. The aims of surgical treatment are to arrest progression, correct the deformity and improve cosmetic appearance by balancing the trunk while keeping complications at minimum. (Weinstein et al. 2008) The surgical correction of AIS can also be performed in adults, but the indications are somewhat different: back pain related to scoliosis that is unresponsive to conservative treatment and curve progression exacerbating symptoms and leading to disability. (Dickson et al. 1995)

After surgical treatment of AIS, the general complication rate is approximately 6 % and operative mortality 0.02 % (Reames et al. 2011). The long-term results on back pain and functionality are good and comparable with age- and sex-matched controls (Danielsson & Nachemson 2003).

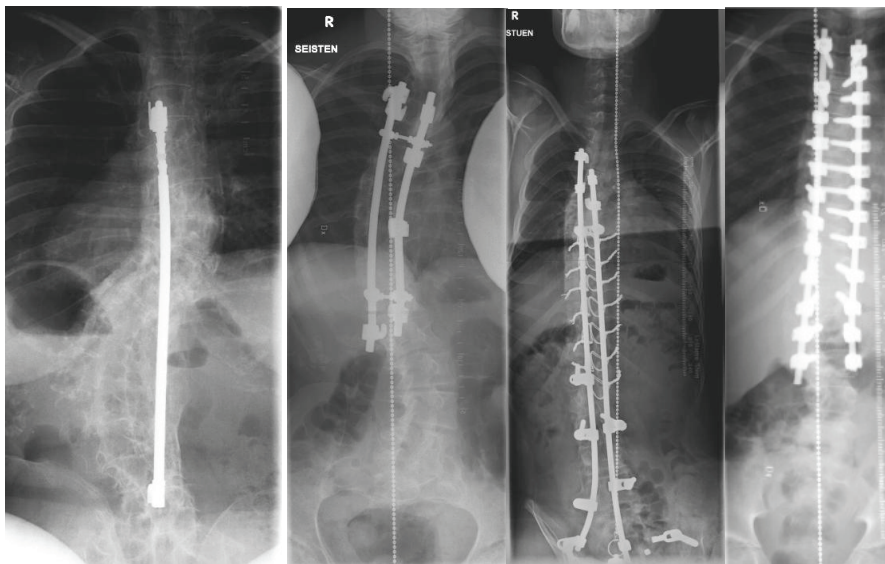
The surgical correction of AIS is performed by instrumented spinal fusion by anterior, posterior or combined anteroposterior approach (Weinstein et al. 2008). The preoperative assessment should exclude all other causes for scoliosis. If the patient has a left-sided thoracic curve or neurological symptoms, an MRI scan should be performed. (Goldberg et al. 1994) In cases of substantial thoracic curves, pulmonary function tests (PFT) may give suggestions whether anterior approach should even be attempted, because these approaches have been associated with worsening of pulmonary function in certain studies (Graham et al. 2000; Gitelman et al. 2011). Standard posteroanterior, lateral and bending radiographs should be obtained in order to assess the structural and nonstructural curves and the flexibility of the deformity. The curve classification models assist in determining the segments that need to be fused. According to the classification by Lenke, the major and minor structural curves should be included in the fusion, but the nonstructural ones should be excluded. The fusion should start proximally from transitional or neutral vertebra and extend distally to the stable vertebra, which is determined by the CSVL (see Spine, Radiography). (Lenke et al. 2001)

### ***Posterior Instrumented Spinal Fusion***

The most common spinal fusion method in AIS is the instrumented posterior spinal fusion (Weinstein et al. 2008). This method is generally recommended in Lenke type 1, 2, 3, 4 and 6 curve patterns, and especially in situations when there are multiple curves requiring treatment (Lowe et al. 2003).

In posterior spinal fusion, the surgical approach is midline over the axis of the spine. The soft tissue structures are dissected from the spinous to the transverse processes subperiostally. Facetectomies are performed at the fusion area. The instrumentation rods are attached by pedicle screws, hooks or wires to the fusion area and the correction is performed. Spinal fusion is enhanced by implanting auto- or allogeneous bone grafts, demineralized bone matrix or the biological bone substitutes over the fusion area. During the operation, the safety of patients is nowadays supervised by neurophysiological monitoring (somatosensory evoked [SSEP] and motor response evoked [MEP] potentials) and blood salvage hardware. (Cotrel et al. 1988; Suk et al. 2001; Weinstein et al. 2008)

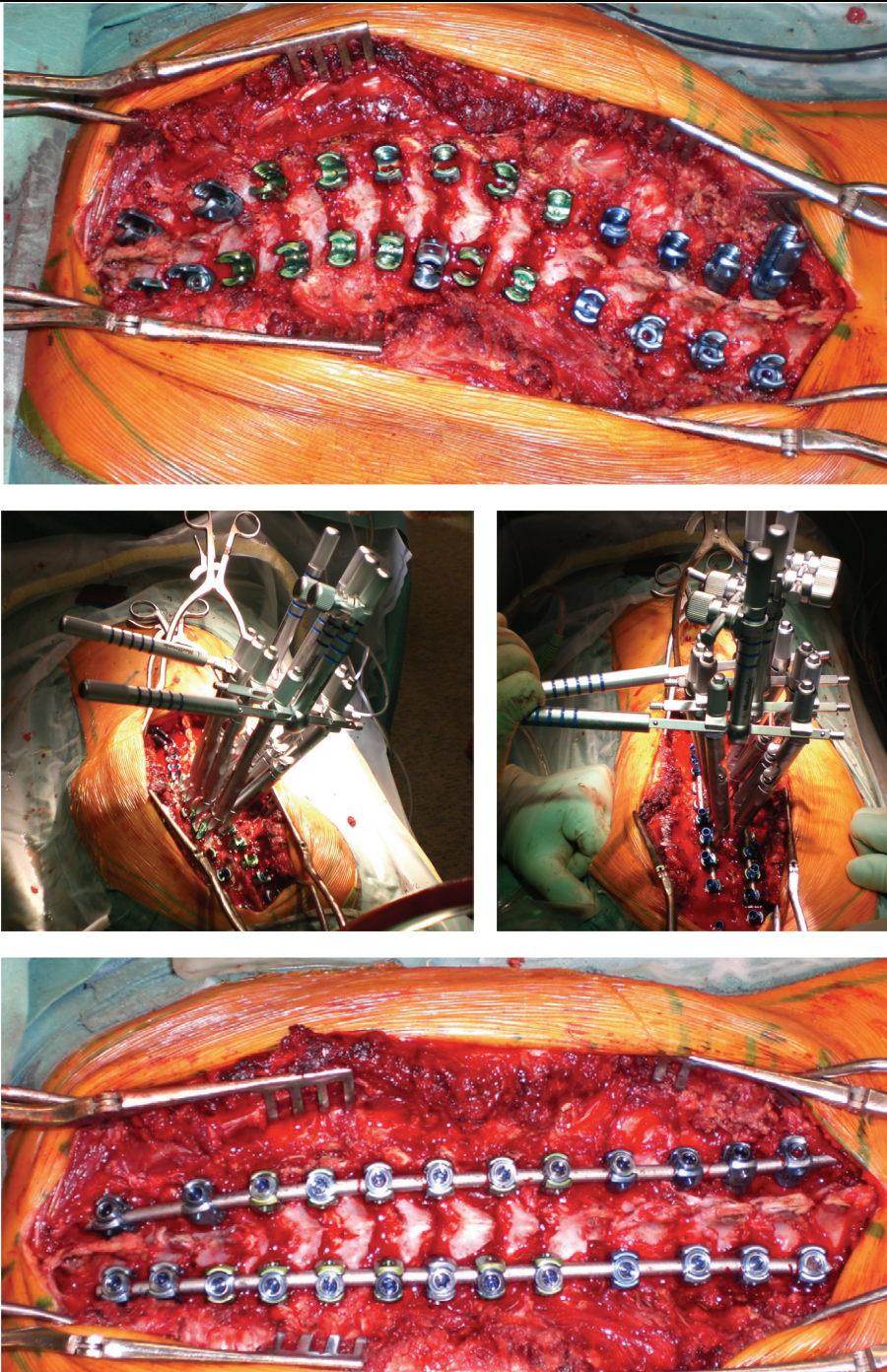
The first type of posterior instrumentation was introduced by Harrington in the 1960s and consisted of a rod holding the corrected scoliosis curve in by place by distraction hooks implanted in the articular processes (Harrington 1962). The next significant evolvement was the system developed by Cotrel-Dubousset (CD), in which two interlocked rods were implanted to the spine by vertebral hooks in the thoracic area and by pedicle screws in the lumbar area. This construct was able to obtain significant three-dimensional correction and derotation of the apical vertebrae without the use of distracting forces. (Cotrel et al. 1988) The modern instrumentations were developed based on the CD system. Nowadays several different hybrid combinations of wires, hooks, and lumbar pedicle screw constructs over contoured interconnected rods have been developed (Weinstein et al. 2008). (Figure 7)



**Figure 7.** Coronal and sagittal radiographs of the Harrington (on the left), Cotrel-Dubousset (CD), hybrid and total pedicle screw (TPS) constructs (on the right).

The hallmark of modern day instrumentation is considered to be the total pedicle screw (TPS) construct, in which pedicle screws are implanted on all fusion segments from the lumbar to the thoracic spine (Figure 8). Before the widespread use of the TPS constructs, pedicle screws were avoided in the thoracic area because of a fear for neurological complications. However, Suk and coworkers showed that this system could achieve a better multiplanar (sagittal, coronal and transverse plane) correction and reduction of the rib prominence without neurological compromise. (Suk et al. 2005; Suk et al. 2001) The average main curve correction after posterior spinal fusion in AIS with TPS constructs have been 62-84 % after a follow-up of a few years (Hee et al. 2007; Geck et al. 2009; Burton et al. 2005; Suk et al. 2007; Potter et al. 2005). The disadvantages of TPS are the increased costs and the steeper learning curve involved in performing the procedure (Weinstein et al. 2008).

Comparative studies have favored the TPS constructs above the hybrids at least in radiographic terms. In preoperative major curves averaging 60 °, the major curve corrections have been superior with the TPS constructs (50 - 65 %) at final follow-up when compared to the hybrids (39 – 46 %). It seems that while the immediate postoperative curve correction is not necessarily better, the ability to maintain the achieved correction has been superior in TPS constructs. (Kim et al. 2006; Liljenqvist et al. 2002; Wu et al. 2010) Nevertheless, it is important to keep in mind that the improvements gained in radiographic parameters have not been shown to enhance functionality and QoL of AIS patients (Lubicky et al. 2011; Kim et al. 2006). The other aspect is the amount of complications. Significant differences have not been noted when comparing the rate of complications in patients operated on with the TPS and hybrid constructs. The operative time and blood loss have not been significantly different between the two instrumentations in any of the studies. (Kim et al. 2006; Liljenqvist et al. 2002; Wu et al. 2010)



**Figure 8.** The posterior spinal fusion with a TPS (total pedicle screw) construct is depicted in these four pictures. **Uppermost:** The pedicle screws have been placed after posterior exposure. **Middle left:** The cantilever correction device is positioned. **Middle right:** The correction is performed. **Lowermost:** The final situation before closure.

### ***Anterior Instrumented Spinal Fusion***

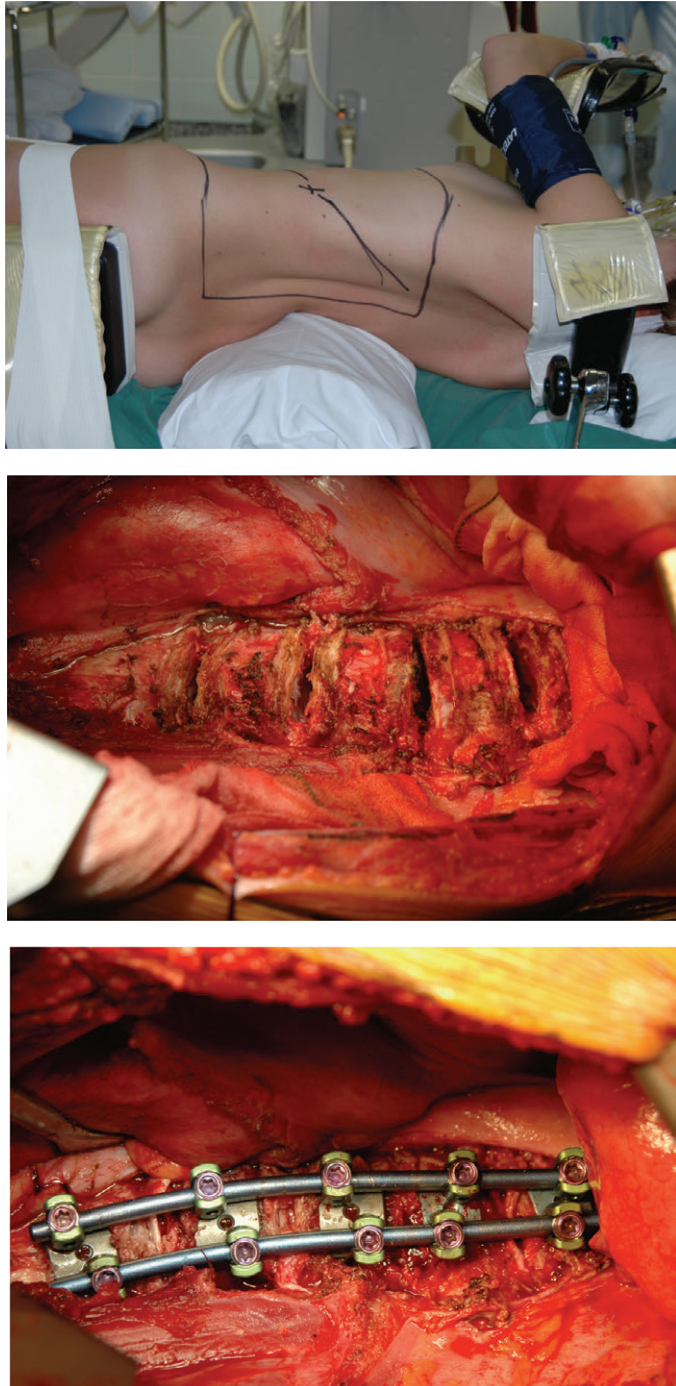
Instrumented anterior spinal fusion without posterior fusion has been used in isolated thoracolumbar and lumbar curves (Weinstein et al. 2008). Anterior systems can achieve good major curve and rib hump correction, restoration of trunk balance and reduction of a few fusion levels (in comparison to posterior spinal fusion) (Turi et al. 1993; Muschik et al. 2006; Lowe et al. 2003).

In anterior instrumented spinal fusion, the patient is placed in a lateral decubitus position with the convex side of the curve positioned upwards. The approach is either open (thoracotomy, thoracolumbotomy or lumbotomy; transpleural, retropleural or retroperitoneal) or endoscopic. The anterior longitudinal ligament and vertebral discs are debrided (anterior release). The bony surfaces are decorticated. Instrumentation and correction is performed. Bone grafts or substitutes are layered onto the decorticated surfaces to promote spinal fusion. (Kaneda et al. 1996) (Figure 9)

After the introduction of the Dwyer cable, several anterior constructs ranging from single-rod to dual-rod systems have been developed (Dwyer & Schafer 1974; Hammerberg et al. 1988; Turi et al. 1993; Bullmann et al. 2003). The most recent studies favor dual-rod constructs, which appear to be more stable and avoid the disadvantages of the older constructs including postoperative deterioration of kyphosis, high amount of implant breakages and the necessity to use postoperative bracing. (Kaneda et al. 1996; Turi et al. 1993; Bullmann et al. 2003; Muschik et al. 2006).

Whether the anterior method should be preferred over the posterior method in some cases, is a difficult question. It has been shown that the anterior method can save approximately 2 fusion levels distally in the lumbar spine when compared to the posterior method and preserve better motion of the lumbar spine. Therefore, this method has been suggested in Lenke 5 type curves. (Figure 10). (Lowe et al. 2003)

In the comparative studies so far, the correction rate of anterior single and dual-rod constructs and posterior hybrid systems have been similar (Muschik et al. 2006; Betz et al. 1999). Posterior TPS constructs on the other hand have achieved better spinal deformity correction in thoracolumbar (Lenke 5C) curves 2 years after surgery with shorter hospitalization time (Geck et al. 2009). In terms of complications, posterior TPS and hybrid constructs appear to fare better when compared with anterior systems in regards of neurological deficits and implant breakages (Weinstein et al. 2008; Reames et al. 2011; Betz et al. 1999).

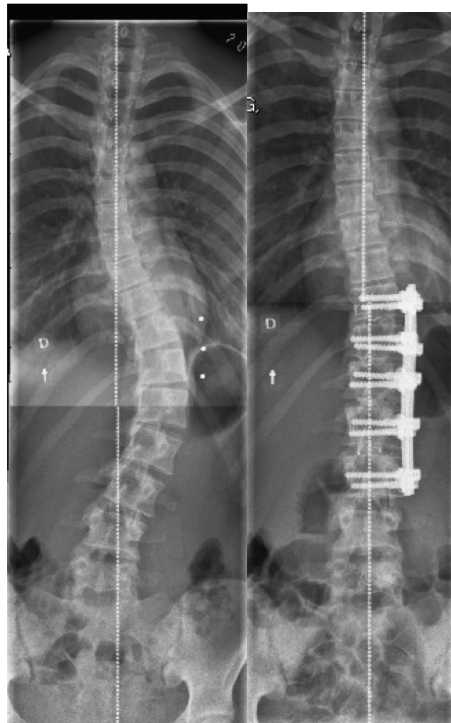


**Figure 9.** The anterior instrumented spinal fusion. **Uppermost:** The patient is placed in a lateral decubitus position. **Center:** The anterior longitudinal ligament, bony surfaces and discs have been debrided in the thoracoabdominal approach. **Lowermost:** The anterior dual-rod instrumentation in place.



The effects of the anterior method on pulmonary function have been conflicting: two studies have shown decreased PFTs at 3 months postoperatively, two studies have shown no impairment or slight improvement after a 2 year follow-up and one study has showed decline in the percent predicted PFTs at 10 years after surgery (Weinstein et al. 2008; Graham et al. 2000; Lenke et al. 2004; Gitelman et al. 2011; Vedantam et al. 2000).

Another debated aspect has been whether an anterior method could control the crankshaft phenomenon (the continued growth in the anterior portions of vertebrae) better in patients with open triradiate cartilage than posterior spinal fusion alone (Betz et al. 1999; Muschik et al. 2006; Dubousset et al. 1989). Recent retrospective study by Sponseller et al. suggested that neither the anterior only nor posterior only method (even with pedicle screw constructs) can prevent modest postoperative progression of spinal deformity in skeletally immature patients while the combined anteroposterior method can do this (Sponseller et al. 2009). Well-designed randomized controlled trials with PFT and HRQoL measurements comparing anterior and posterior method are unfortunately lacking.



**Figure 10.** A Lenke 5C curve operated on by the instrumented anterior spinal fusion

### ***The Combined Anteroposterior Instrumented Spinal Fusion***

The combined anteroposterior instrumented spinal fusion has been used in stiffer curves exceeding 70°, when hyperkyphosis is present and especially in skeletally immature patients (Risser 0) to prevent crankshafting. (Dubousset et al. 1989; Lenke 2003; Weinstein et al. 2008)

The anterior release and non-instrumented spinal fusion is performed by open or endoscopically approach as mentioned in the previous chapter. The posterior instrumented spinal fusion is performed either in the same or in a different stage surgery. (Lenke 2003)

In preoperative major curves averaging 70°, corrections of 47 - 67 % have been achieved with the combined anteroposterior method after a follow-up of few years. Complications (e.g. transient pulmonary and wound healing problems) have occurred in 21 - 22 %. (King et al. 2000; Sucato 2010; Niemeyer et al. 2000; Lenke 2003) Recently, few studies have proposed that instrumented posterior spinal fusion with TPS construct can give comparable results in spinal deformity correction (59 – 68 % in major curve) and QoL in patients with curves exceeding 70°. Clinical neurologic complications have not been observed. Complications, non-unions and implant related problems, have occurred in 3 – 11 % with the use of posterior spinal fusion with TPS constructs alone. (Kuklo et al. 2005; Burton et al. 2005; Suk et al. 2007)

Because anterior approaches appear to have higher rate of complications than the posterior only method, it seems wiser to treat curves of 70 – 90 ° with posterior spinal fusion and TPS instrumentation at least in adolescent patients who are skeletally mature (Burton et al. 2005; Kuklo et al. 2005; Reames et al. 2011; Suk et al. 2007). If combined anteroposterior surgery is selected, the preference over open or endoscopic approach depends on several factors. If there is substantial hyperkyphosis or the deformity lies relatively close to the chest wall, the endoscopic approach should be avoided. Video-assisted thoracoscopy is eligible in situations, when the indications for instrumented anterior spinal fusion or anterior release are met and the surgeon is suitably experienced with this difficult technique (Lenke 2003).

### ***Surgical Methods for Rib Hump Correction***

The rib hump deformity associated mainly with apical vertebral rotation and rib deformation is one of the most dissatisfying factors of AIS that patients have reported (Thulbourne & Gillespie 1976). Unfortunately, the correction of this deformity by bracing or instrumented posterior spinal fusion has been inadequate so far (Thulbourne & Gillespie 1976; Wood et al. 1991; Cui et al. 2012). With Cotrel-Dubousset instrumentation, significant apical vertebral derotation has not been achieved after surgery (Wood et al. 1991). TPS constructs have gained 50 % corrections of apical vertebral rotation immediately postoperatively, but a 20 % loss of correction has occurred with this construct during the follow-up period (Cui et al. 2012).

Thoracoplasty and direct vertebral body derotation have been developed to achieve better rib hump correction. Thoracoplasty is performed from the same posterior incision after instrumented (hook or pedicle screw construct) scoliosis correction has been performed. A few centimeters of the deformed ribs causing rib hump are resected on the convex side of the curve and the remaining ends of the ribs are left intact. In a comparative study by Min et al., rib hump corrections of 50 % and 37 % were

achieved with and without thoracoplasty, respectively, in posterior spinal fusion with TPS instrumentation after a follow-up of two years. (Min et al. 2005)

Direct vertebral body derotation can be performed with TPS instrumentation. The method is simple: instead of a simple rod derotation maneuver during curve correction, the surgeon applies posterior force in the direction opposite to the vertebral rotation. Apical vertebral rotation corrections of 43 % and rib hump corrections of 54 % have been achieved with the direct vertebral body derotation after a few year follow-up, and these results have been significantly better than using simple derotation alone. (Lee et al. 2004; Hwang et al. 2012)

### ***Spinal Osteotomies for The Correction of Severe Sagittal Deformity***

In addition to the curvature observed in the coronal plane, scoliosis patients can have a significant sagittal deformities as well. Smith-Petersen osteotomy (SPO) was introduced in the 1945 and thereafter several modifications, like the Ponte procedure, have been developed to treat hyperkyphotic deformities. SPO was mainly used in ankylosing spondylitis but has been introduced in the treatment of kyphoscoliosis as well. (Kim et al. 2009)

The basic principle of SPO is to resect the spinous process, laminae and facet joints at the affected segment from the posterior approach after the implantation of pedicle screws. Also portions of the spinous processes adjacent to this segment are usually excised. (Kim et al. 2009) SPO can be performed at multiple levels and a correction of 10° per segment can be expected (Burton 2006). This procedure has been associated with an increased risk for complications (Reames et al. 2011)

When a more profound correction of the sagittal deformity is required, pedicle subtraction osteotomy or vertebral column resection (VCR) may be necessary. These methods are usually not necessary in AIS and are more commonly needed in the treatment of congenital scoliosis and kyphosis. (Kim et al. 2009)

## **Congenital scoliosis**

Congenital scoliosis is caused by developmental vertebral anomalies, which result in a growing imbalance of the spine. Congenital vertebral anomalies are present at birth, but the curvature usually becomes observable later in childhood. All of the anomalies do not lead to scoliosis, and therefore it is important to identify the type and know which of them are likely to lead to scoliosis. (McMaster & Ohtsuka 1982)

## **Epidemiology**

The incidence of congenital scoliosis is approximately 1 per 1000 (Wynne-Davies 1975). The incidence of congenital vertebral anomalies is not known because some of the malformations do not cause significant deformity and may remain undetected (McMaster & Ohtsuka 1982).

## **Etiology & Pathogenesis**

While some controversy still exists, current results suggest that both genetic and environmental factors are likely to contribute to the development of congenital spinal anomalies (Kaspiris et al. 2008; Pool 1986; Pourquié 2011). Environmental factors are believed to occur in utero (Pool 1986). Genetic mutations which have been related to congenital scoliosis so far are found in genes which are part of an oscillating segmentation mechanism, which controls the formation of the early spinal column (Pourquié 2011).

Single, isolated vertebral anomalies can occur sporadically but several malformations of the spine are believed to have hereditary origin in addition to environmental factors (Wynne-Davies 1975). Congenital vertebral anomalies and scoliosis have also been observed in hereditary diseases, like the spondylothoracic (Jarcho-Levin syndrome) and spondylocostal dystosis, which lead to the development of multiple vertebral and rib deformities (Roberts et al. 1988).

The pathogenesis of vertebral anomalies (defects of formation or segmentation of the primitive vertebrae) is believed to occur during the first 6 weeks of intrauterine life, which is the time needed for the anatomic pattern of the spine to develop in the mesenchyma. After the formation of this abnormal primitive spine, the cartilaginous and bony stages of development follow and lead to fully established vertebral anomalies at birth. (McMaster & Ohtsuka 1982)

Congenital vertebral malformations cause growth imbalance in the spine (McMaster & Ohtsuka 1982). The type of spinal deformity that develops is related to the location of the vertebral anomaly and whether it lies unilaterally producing scoliosis, anterolaterally resulting in kyphoscoliosis or anteriorly, which leads to pure kyphosis (McMaster & Singh 1999). Neural (spinal cord) anomalies

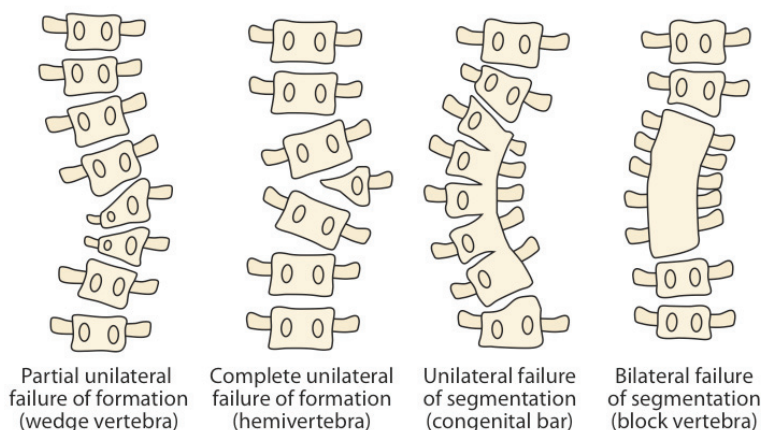
are often seen in association with vertebral malformations (spinal dysraphism) and also spina bifida (Wynne-Davies 1975; Rajasekaran et al. 2010).

## Natural history

### *Spinal Deformity*

Congenital scoliosis is significantly more common than kyphoscoliosis or pure kyphosis (McMaster & Singh 1999). The deterioration rate of congenital scoliosis is proportional to the degree of growth imbalance resulting from the vertebral anomalies (McMaster & Ohtsuka 1982). The progression continues until skeletal maturity. Rapid growth periods during childhood and before adolescence are also the times of most rapid progression of congenital scoliosis. Marked curve progression appears to occur in half of the patients who are referred to a specialist clinic. (McMaster & Ohtsuka 1982; Winter et al. 1968)

To better understand the progression of congenital scoliosis, a classification system of vertebral malformations has been devised. The main division is into defects of formation and segmentation of the spine (Figure 11). Some of the deformities are so complex that they are classified as unidentifiable. (McMaster & Ohtsuka 1982) Rib anomalies can also be present, but they are disregarded because they have not been found to cause scoliosis in of themselves (Tsirikos & McMaster 2005).



**Figure 11.** The basic types of vertebral anomalies.

Defects of vertebral formation vary from a mild wedge shaped vertebra to a complete hemivertebra. A wedge vertebra is caused by a partial unilateral failure of formation. It has wedge shaped vertebral body and a full neural arch. This anomaly is not a common cause of congenital scoliosis. (McMaster & Ohutsuka)

A hemivertebra is a common cause of congenital scoliosis and results from a complete unilateral failure of formation. It is triangular in shape, consisting of half a vertebral body, one pedicle and a hemilamina. A hemivertebra may be fully segmented (non-incarcerated), semi-segmented, non-segmented or incarcerated, the former being more common and the latter more rare. A fully segmented hemivertebra is surrounded by normal intervertebral disc spaces and completely separated from the adjacent vertebrae. As the hemivertebra grows it acts as an enlarging wedge on the spine producing scoliosis. A single fully segmented hemivertebra lies on the apex of the curve and tends to protrude laterally as the curve grows (Figure 12). Lower thoracic and thoracolumbar fully segmented hemivertebrae appear to cause the most marked curve progression when compared to other types of hemivertebrae and they result in curves that can exceed 45° by the end of skeletal maturity. (Winter et al. 1968; McMaster & Ohtsuka 1982)

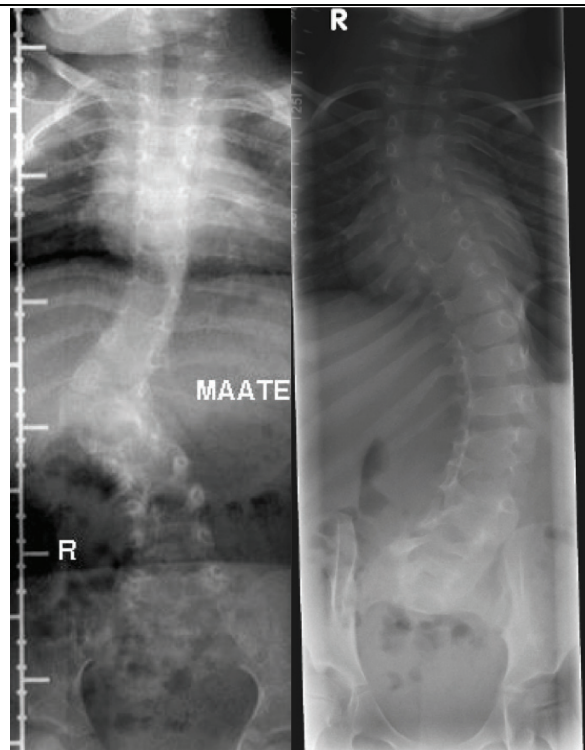
Two or more hemivertebrae on the same side are rare, but they can result in more severe curves than a single hemivertebra due to greater growth imbalance. Two fully segmented hemivertebrae on the opposite sides adjacent to each usually balance themselves, so significant scoliosis does not occur but if they are on different regions of the spine, they can produce two different scoliosis curves. (McMaster & Ohtsuka 1982)

A semi-segmented hemivertebra is attached to its adjacent vertebra on the other side and has a normal disc space on the other side. Spinal growth is more balanced than in fully segmented hemivertebra but some tilting can occur, which results in a slowly progressing scoliosis. Non-segmented and incarcerated hemivertebrae are balanced and do not seem cause significant scoliosis. (McMaster & Ohtsuka 1982)

The most common cause of significant congenital scoliosis appears to be a unilateral failure of segmentation of two or more vertebrae leading to a unilateral unsegmented bar. This malformation consists of a bar of bone fusing the disc spaces and facet joints on one side of the spine while the other side is left unaffected. The bar cannot grow in length, but the other side of the spine has growth potential and therefore this anomaly causes marked progressive scoliosis that will exceed 40°. (McMaster & Ohtsuka 1982; Winter et al. 1968)

The most severe and rapidly progressive scoliosis occurs in patients with a unilateral unsegmented bar on the concave side and a hemivertebra on the convex side of the curve. These curves can exceed 60° during infancy. Usually there is also associated severe vertebral rotation and distortion of the rib cage. (McMaster 1998)

A bilateral failure of segmentation of several adjacent vertebrae results in a block vertebra. Longitudinal growth is impaired in both sides of the spine and therefore this segment of spine is shortened and rarely causes extensive scoliosis requiring treatment. (McMaster & Ohtsuka 1982; Winter et al. 1968)



**Figure 12.** A patient with two adjacent thoracolumbar hemivertebrae on the left and a patient with lumbar unilateral bar on the right.

The location of the curve plays significant role in the severity of the spinal deformity. Upper thoracic curves are quite common, and can result in marked cosmetic deformity due to the elevation of shoulder line. Midthoracic curves are frequently associated with long, opposite, compensatory thoracolumbar curves especially if the primary curve is caused by a unilateral unsegmented bar. Lower thoracic, thoracolumbar and lumbar congenital scoliosis curves often fail to develop compensatory curves, which can lead to a severe imbalance of the trunk and pelvis. (McMaster & Ohtsuka 1982; Winter et al. 1968)

While the classical natural history studies by Winter, McMaster and their coworkers (Winter et al. 1968; McMaster & Ohtsuka 1982) have provided valuable information on the prognosis of this disease, a significant amount of vertebral malformations can be so complex and severe that their structure and prognosis cannot be predicted by plain radiographs alone. In recent years, this problem has been evaluated by CT imaging, which may produce a more accurate, revised version of the earlier two-dimensional classification systems in the following years. (Kawakami et al. 2009)

### ***Congenital Kyphosis and Kyphoscoliosis***

Congenital kyphosis develops by same mechanisms (failure of formation and segmentation) as scoliosis with the addition of rotatory dislocation of the spine. Congenital kyphosis is commonly progressive and poses a risk for spinal cord injury. As in scoliosis, mixed multiple level and complex

---

unidentifiable malformations are frequently associated with the most severe deformities. (Winter et al. 1973; McMaster & Singh 1999; Dubousset 2001)

Partial anterior, symmetrical failure of formation leads to angular kyphosis with strong neural arch. In partial anterolateral failure of formation, the result is kyphoscoliosis (with mostly preserved neural arch) due to hemivertebra that develops posterolaterally. (McMaster & Singh 1999; Winter et al. 1973) In some cases, partial failure of formation leads to dislocated spinal canal (congenital dislocation of the spine). The neural arch is defective and this malformation is associated with instability that usually arises after minor or marked trauma, and can lead to sudden neurologic injury. Progression is always eminent. (Dubousset 2001)

Total anterior failure of formation of the vertebral bodies leads to agenesis of one or more vertebral bodies while the neural arches are preserved. This type of congenital kyphosis has a high risk for paraplegia with additional urinary problems. (Winter et al. 1973; McMaster & Singh 1999; Dubousset 2001)

Anterior or anterolateral failure of segmentation leads to bar formation that causes smooth contoured kyphosis or kyphoscoliosis, in which the risk for neurologic damage is small (McMaster & Singh 1999). A special type of anterior bar can develop by a delayed ossification of disc spaces during the ages of 8-10 years. This type of potentially markedly progressive congenital kyphosis can be misinterpreted as Scheuermann's disease. (Dubousset 2001)

Rotatory dislocation of the spine is caused by the sudden presence of kyphotic area between two scoliotic regions. This type of kyphosis is angular, usually located on the thoracic or thoracolumbar area, and leads to considerable collapsing of the spine. Neurologic defects are common, because the spinal cord is twisted. The progression is variable and depends on the associated scoliotic deformities. (Dubousset 2001)

### ***Congenital Lordosis and Lordoscoliosis***

Congenital lordosis is the least common of congenital spinal deformities (Lonstein 1999). Posterior failure of segmentation causes bar formation that leads to lordosis or lordoscoliosis whether it is symmetrical or not (Lonstein 1999; Dubousset 2001). This deformity can become severe and hard to treat especially in the thoracic area, when adjacent ribs are absent. In the thoracolumbar area the impairment is mainly postural. (Dubousset 2001) Posterior failure of formation leads to an absence of posterior arch structures. This deformity is extremely rare and occurs predominantly in myelomeningocele patients. (Lonstein 1999; Dubousset 2001) Congenital lordosis can also develop secondarily due to congenital kyphosis below. (Dubousset 2001)

### ***Pulmonary Function***

In the study by Pehrsson and coworkers, mortality was increased in untreated scoliosis of infantile onset. The cause of death was respiratory failure in 40 % of patients who were in their 50s. (Pehrsson et al. 1992) It is known that significant respiratory impairment can take place in congenital scoliosis when severe distortion of the rib cage occurs before the age of 8 years and especially when fused ribs are present. This progressive pulmonary impairment and/or loss of lung growth is called thoracic insufficiency syndrome. (Campbell et al. 2003) Progressive congenital thoracic kyphosis,



kyphoscoliosis, lordosis and lordoscoliosis are especially prone to cause problems with pulmonary function and may lead to cor pulmonale and death (McMaster et al. 2007; Dubousset 2001).

## **Clinical Picture & Diagnosis**

Congenital scoliosis usually causes an observable spinal deformity during the first 10 years of life. The diagnosis of congenital scoliosis is made in a posteroanterior radiograph. The lateral radiograph is examined for sagittal deformities. (Winter et al. 1973; McMaster & Ohtsuka 1982) A CT scan should be obtained to define the vertebral anomaly further and an MRI should be performed to identify possible intraspinal anomalies (Kawakami et al. 2009; Hedequist 2009).

### ***Associated Neural Anomalies***

Because the development of the spinal cord is closely associated with the development of the vertebral column, it is not surprising that 32 - 38 % of patients with congenital vertebral anomalies have associated intraspinal malformations (Bradford et al. 1991; Suh et al. 2001; Rajasekaran et al. 2010). Intraspinal anomalies are more commonly seen in association with multiple level vertebral anomalies than with single, isolated vertebral malformations. (Rajasekaran et al. 2010) Neural malformations can be seen in conjunction with abnormalities of the skin (dimple, nevus, hairy patch, lipoma) overlying the spine or lower extremity deformities and neurological findings (Winter et al. 1968).

Tethered spinal cord, by an abnormally low-lying conus medullaris (below L2 vertebra), thick or tight filum terminale or dorsally displaced spinal cord, appears to be the most common intraspinal anomaly in congenital scoliosis (Bradford et al. 1991; Rajasekaran et al. 2010). Other common intraspinal anomalies are diastematomyelia (a localized vertical split in the spinal cord or cauda equine), syringomyelia (a cavitation in the central segment of the spinal cord), diplomyelia (a lengthwise fissure in the spinal cord), lipomas and teratomas (Bradford et al. 1991; Suh et al. 2001; Rajasekaran et al. 2010). It is common to perform neurosurgical untethering before spinal deformity correction (Murans et al. 2010). However, it has been recently suggested that (in the presence of diastematomyelia) separate untethering operation may not always be necessary because spinal deformity correction shortens the spine (Leung & Buxton 2005).

### ***Other Congenital Anomalies***

A significant amount (approximately one-third) of patients with congenital vertebral anomalies have associated developmental malformations in other systems as well. The most common associated anomalies are found in the urinary tract (e.g. unilateral kidney, duplicated kidney) and heart. (Louis et al. 2010) Also, Sprengel deformity (congenital elevation of the scapula) and underlying syndromic diseases (e.g. Klippel-Feil or Goldenhaar) may be present. (Louis et al. 2010; Winter et al. 1968)

## Treatment

The type and location of the vertebral anomaly, the degree of growth imbalance, and the age of the patient are the determining factors for the method of treatment (Table 2) (Winter et al. 1968; McMaster & Ohtsuka 1982; Louis et al. 2010). The prognosis of congenital scoliosis is hard to predict and in some forms of complex or unclassifiable malformations, it may be impossible (Louis et al. 2010; Kawakami et al. 2009).

**Table 2.** The necessity of performing spinal surgery according to the site of the curve and type of vertebral anomaly. Unknown means that there is not enough knowledge to make estimations or there are no such scoliosis. Modified from the table presented by McMaster and Ohtsuka in 1982.

Curve site	Type of vertebral anomaly					
	Block Vertebra	Wedge Vertebra	Hemivertebra		Unilateral Unsegmented Bar	
			Single	Double	Alone	With Contralateral Hemivertebra
Upper thoracic	No	No	Possibly	Yes	Yes	Yes
Lower thoracic	No	Possibly	Possibly	Yes	Yes	Yes
Thoracolumbar	No	No	Possibly	Yes	Yes	Yes
Lumbar	No	No	Possibly	Unknown	Yes	Unknown
Lumbosacral	Unknown	Unknown	Yes	Unknown	Unknown	Unknown

## Observation

Careful observation can and should be performed on all types of mild congenital scolioses with the exception of unilateral unsegmented bar with or without a contralateral hemivertebra. If progression is observed, other treatment methods are indicated. (McMaster & Ohtsuka 1982; Louis et al. 2010)

## **Brace treatment**

The effectiveness of bracing in congenital scoliosis is uncertain. Bracing should not be attempted for in anomalies with severe growth imbalance, like those seen in failures of segmentation. Certain forms of congenital scoliosis, like long flexible thoracic or thoracolumbar curves with a short anomalous segment due to failure of formation, can be managed at least for some time with a brace. If progression takes place, surgery is indicated. (Winter et al. 1968; Kaspiris et al. 2011) Primary congenital kyphosis and lordosis do not benefit from bracing treatment (Dubousset 2001).

## **Surgical Treatment**

Operative treatment is indicated in progressive congenital scoliosis, which cannot be controlled by conservative treatment methods (Louis et al. 2010). The surgical treatment methods are divided into prophylactic, including hemiepiphysiodesis and early spinal fusion in situ, and corrective, including instrumented spinal deformity correction without fusion, hemivertebra resection, posterior instrumented spinal fusion and combined anteroposterior spinal fusion and correction with VCR (Thompson et al. 1995; McMaster 1998; Akbarnia et al. 2005; Suk et al. 2002, Ruf et al. 2003). The use of instrumentation may be difficult in some patients because of abnormal vertebral anatomy and requires experience with both hooks and pedicle screws (Hedequist 2009).

### ***Hemiepiphysiodesis***

A hemiepiphysiodesis is a convex growth arrest procedure, which is an early prophylactic surgical method for young patients (< 6 years old) with a short, mild curve that is caused by unilateral failure of formation (hemivertebra) (Thompson et al. 1995). Hemiepiphysiodesis works by halting growth on the convex side of the curve (Roaf 1963).

Hemiepiphysiodesis is performed either by posterior only or combined anteroposterior approach in a single-stage. Anterior approach is retroperitoneal to the convex side of the curve. The lateral half of the intervertebral discs and adjacent end plates are removed at the site of the hemivertebra and one-level above and below the hemivertebra. Bone grafts are implanted to the excised intervertebral disc spaces to cause spinal fusion on the anterior convex side of the curve. The posterior approach is midline to the convexity of the curve. The convex facet joints are resected, posterior elements of the hemivertebra and adjacent vertebrae are decorticated and finally bone grafts are implanted to the fusion area. (Thompson et al. 1995)

Posterior only hemiepiphysiodesis is performed by a similar approach as mentioned above. The anterior convex growth arrest is performed transpedicularly. Posterior convex fusion is performed as mentioned above. The advantage of this procedure is obviously the avoidance of anterior approach. Postoperative immobilization in an orthosis is recommended in the above procedures. (McMaster 2001)

In previous literature, the progression of most of the curves treated by hemiepiphysiodesis will cease, and in some patients, minor correction can be achieved. Correction appears to be more likely in

younger patients. Approximately 10 % major curve correction has been reported. Non-union rate has varied between 3-8 %. (Thompson et al. 1995; Roaf 1963; Winter et al. 1988)

### ***Early Spinal Fusion In Situ***

Early spinal fusion in situ has been used as a prophylactic treatment for congenital scoliosis caused mainly by a unilateral failure of segmentation. The principle is to prevent further growth imbalance by creating a solid fusion. Early spinal fusion in situ should be used immediately when the unilateral bar and scoliosis has been diagnosed and preferably before the age of 2 years. Fusion area should also include normal vertebrae, which are tilted above and below the unsegmented part, so that postoperative deterioration in the scoliosis could be avoided. (McMaster 1998)

When growth imbalance and spinal deformity are not severe, posterior only spinal fusion is sufficient (McMaster 1998). The crankshaft phenomenon is usually not a problem in congenital scoliosis because the anterior growth plates are abnormal in the anomalous segment. However, in cases of more severe major curve and vertebral rotation, crankshaft can occur. (Lopez-Sosa et al. 1995) Therefore, it seems to be wise to perform a combined anteroposterior fusion when significant growth imbalance is present, like in the case of unilateral unsegmented bar and contralateral hemivertebra. (McMaster 1998)

Reoperation rate of congenital scoliosis patients treated by early in situ spinal fusion has been high, varying between 24-39 % (Goldberg et al. 2002; Vitale et al. 2008; Karol et al. 2008; McMaster 1998). In unilateral failure of formation the halting of curve progression can be achieved in majority of patients, but no correction can be expected (McMaster 1998; Goldberg et al. 2002).

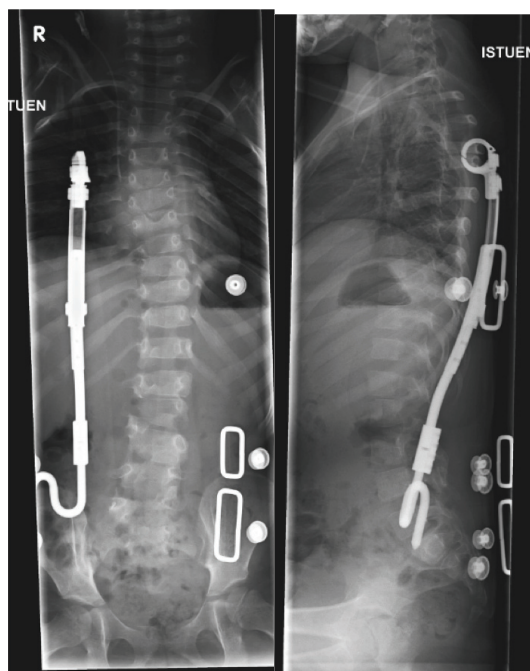
Other problems related to early spinal fusion are postoperative loss of spinal growth and deterioration of pulmonary function. In theory, it can be estimated that a full thoracic fusion at the age of 5 years will result in a 10 cm loss of thoracic growth in an adult male. (Karol 2011) Respiratory impairment in the form of restrictive lung disease has been observed in patients undergoing early thoracic spinal fusion and associated with the shortened height of the thoracic spine. It seems that approximately 43-60 % of patients undergoing early thoracic spinal fusion develop restrictive lung disease (FVC < 50 %) at an age of 15-20 years. Especially harmful appears to be fusion to the upper thoracic ( $\geq$  T6) spine. An adequate length of the thoracic spine ( $>$  18 cm) should be achieved at adulthood. It is unknown, however, what is the effect of the operation itself on the natural history of pulmonary function in early onset scoliosis, because if nothing is done, the pulmonary function will deteriorate in any case due to the spinal deformity. (Karol et al. 2008)

Primary mid-thoracic curves can cause secondary structural thoracolumbar curves, which also have to be operated on. Early, extensive spinal fusion of this type of curve pattern has not been recommended. A viable option in these cases may be to perform instrumented spinal surgery without fusion. (McMaster 1998)

***Instrumented Spinal Correction Without Fusion in Early-onset Congenital Scoliosis***

The principle of pediatric spinal instrumentation without fusion is to preserve spinal growth until skeletal maturity and prevent progression of the early onset spinal deformity. When skeletal maturity has been reached, a definitive spinal fusion can be performed. (Akbarnia et al. 2005)

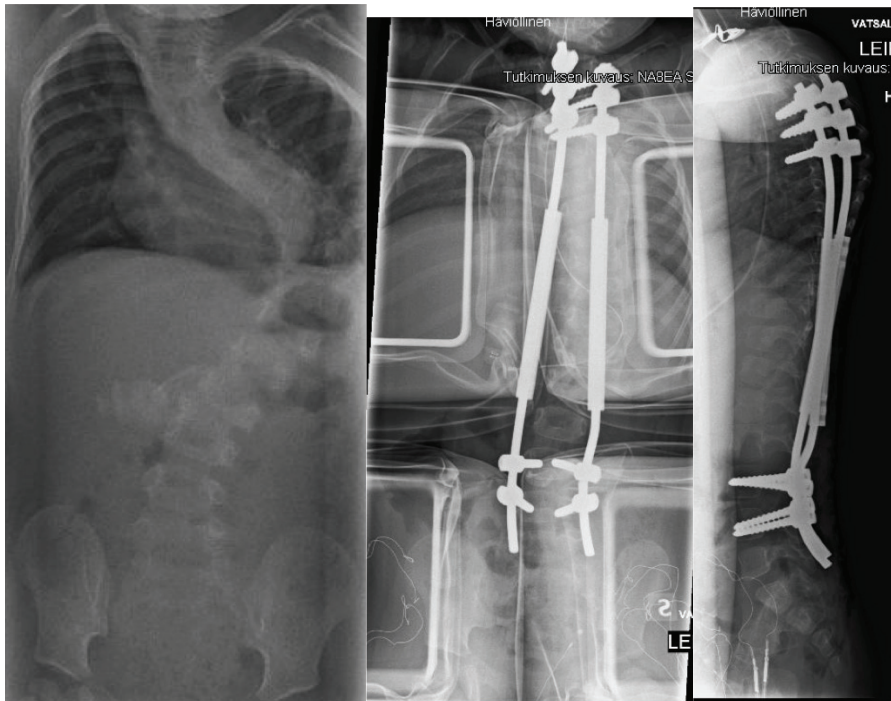
The vertical Expandable Prosthetic Titanium Rib (VEPTR) was developed to treat thoracic insufficiency syndrome resulting from progressive thoracic spinal deformity with fused or absent ribs. This device is implanted by cradles to the ribs on the concave side of curve adjacent to the transverse processes. It is extended from the cranial (T2 onwards) to the cephalad part of the curve (Figure 13) (Campbell et al. 2004). As the patient grows, VEPTR is lengthened approximately every 6 months. This method can achieve major curve correction of 11-59 % in curves of 59-65° during a follow-up of a few years. Complications have occurred in 35-61 % and have been mainly wound infections and implant related problems stemming from the intermittent lengthening operations. (Ramirez et al. 2009; Gadepalli et al. 2011) To date, PFTs have not revealed significant improvement in respiratory function after VEPTR operation at a mean age of 7 years (Gadepalli et al. 2011). Although thoracic cage and spinal deformity become radiologically better looking, it is possible that VEPTR insertion could decrease rib cage compliance (Mayer & Redding 2009). More studies are required to evaluate the effect of VEPTR on pulmonary function especially in younger patients.



**Figure 13.** Vertical expandable prosthetic titanium rib (VEPTR) -instrumentation in a 3-year old girl with a unilateral bar.

Growing rod instrumentation is an extending construct with spine-to-spine anchorage. Earlier single growing rod technique had significant complication rates, which has led to the development of dual growing rod constructs (Bess et al. 2010; Akbarnia et al. 2005). The approach is posterior by one or two skin incisions depending on the length of the child. The dual rods are interconnected at the proximal and distal ends of the construct (Figure 14). Postoperative orthosis is commonly used for the

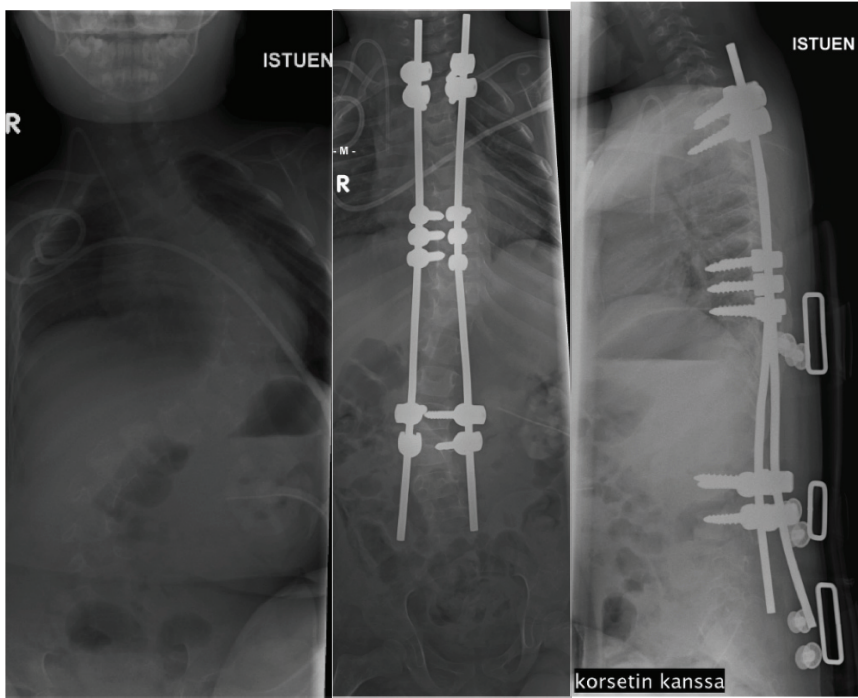
first 6 months to aid fusion of the anchor sites. The rods are lengthened every six months in an inpatient or outpatient procedure as the patient grows. (Akbarnia et al. 2005) The earlier studies on this technique have reported results on cohorts consisting mainly of idiopathic and neuromuscular patients so the use of these constructs in congenital scoliosis is still controversial. Recently, Elsebai et al. reported major curve correction of 29 % in 19 congenital scoliosis patients who had a preoperative curve averaging 66°. Majority of these patients had not undergone final spinal fusion so long-term results are unknown. (Elsebai et al. 2011) Complication rate of growing rods has been 48-58 % in mixed patient populations and consisted mainly of implant related problems. (Bess et al. 2010; Akbarnia et al. 2005)



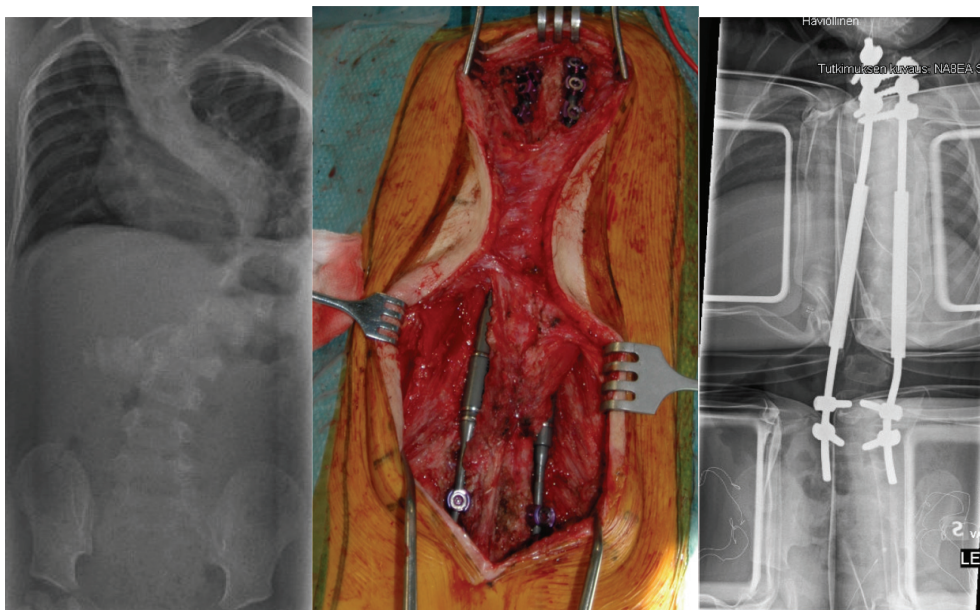
**Figure 14.** Growing rods.

The Shilla growth guidance rod construct is a recently introduced system, which uses two overlong rods that are implanted by non-locking pedicle screws to the spine. The pedicle screws move across the rods as the spine grows in length (Figure 15). This system eradicates the need for intermittent lengthening operations, but extensive clinical results on human subjects are yet to be published. (McCarthy et al. 2010)

Another extending construct not requiring multiple surgeries has been introduced recently. The magnetically controlled growing rod instrumentation can be lengthened without anesthesia or analgesics by an external magnet that is placed above the skin at regular (1-3 month) intervals (Figure 16). In preliminary reports, this construct has been promising, but due to the short-term follow-definitive conclusions cannot be made. (Akbarnia et al. 2011)



**Figure 15.** Shilla growth guidance system



**Figure 16.** Magnetic growing rods.

### ***Hemivertebra Resection***

Hemivertebra excision is recommended in more severe curves with spinal imbalance. Patients are usually 1-6 years of age at the time of surgery. It achieves more controllable correction than hemiepiphysiodesis but is technically more demanding. The approach is a combined anteroposterior or posterior only. (Hedequist et al. 2005; Ruf & Harms 2003)

In the anterior procedure the body of the hemivertebra and the anterior part of the pedicle with the intervertebral discs are excised so that the dura becomes visible. Bone grafts are then implanted to the excised bony surfaces. In the posterior approach, the remaining hemivertebra is removed and posterior fusion is promoted by implanting bone grafts to decorticated spinal surfaces. The use of instrumentation is recommended to stabilize the fusion area. The rods are anchored to the spine by pedicle screws or laminar hooks, which extend from one segment above the hemivertebra to one segment below it. A cast immobilization is used for a few months postoperatively to aid in spinal fusion. (Hedequist et al. 2005)

In major curves averaging 28-40° before surgery, curve corrections of 35-71% have been achieved with the combined anteroposterior hemivertebra resection in a mid-term follow-up. Complication rate has been 0-38 % with a risk of 0-6% for permanent neurological deficit and 0-8 % for non-union. Revision surgeries have been required in 0-18 % of patients. (King & Lowery 1991; Holte et al. 1995; Klemme et al. 2001; Hedequist et al. 2005; Bollini et al. 2006)

The posterior only procedure is performed by similar approach as mentioned above. Posterior and anterior structures of the hemivertebra are carefully removed avoiding the neural structures. Instrumentation is implanted by placing pedicle screws or hooks as mentioned above. Bone grafts are implanted to promote spinal fusion and brace or cast immobilization has been used for few months after surgery. (Ruf & Harms 2003)

With the posterior only method, corrections of 54-82 % have been achieved in 33-49° major curves after a mid- to long-term follow-up. Complication rate has varied between 0 and 29 %. The most common complications have been implant failures (0-18 %) and postoperative deterioration of spinal deformity (0-20%). Permanent neurologic deficits have not been reported. Revision rates have varied from 0 to 29 %. (Shono et al. 2001; Nakamura et al. 2002; Ruf & Harms 2003; Hedequist et al. 2009; Aydogan et al. 2008)

### ***Posterior Spinal Fusion***

A posterior instrumented spinal fusion can be performed in older children with a moderate congenital scoliosis (Hall et al. 1981; Winter et al. 1984; Hedequist 2009; Karol 2011). A moderate correction of the whole curve can be achieved with modern surgical instrumentation. This also diminishes the need to use plaster cast immobilization after surgery. Spinal dyspharism should be addressed adequately before instrumented posterior spinal fusion, because it may increase neurological complications. Also, intraoperative MEP and SSEP measurements should be undertaken to avoid neurological deficits. (Hedequist 2009; Ayvaz et al. 2007)

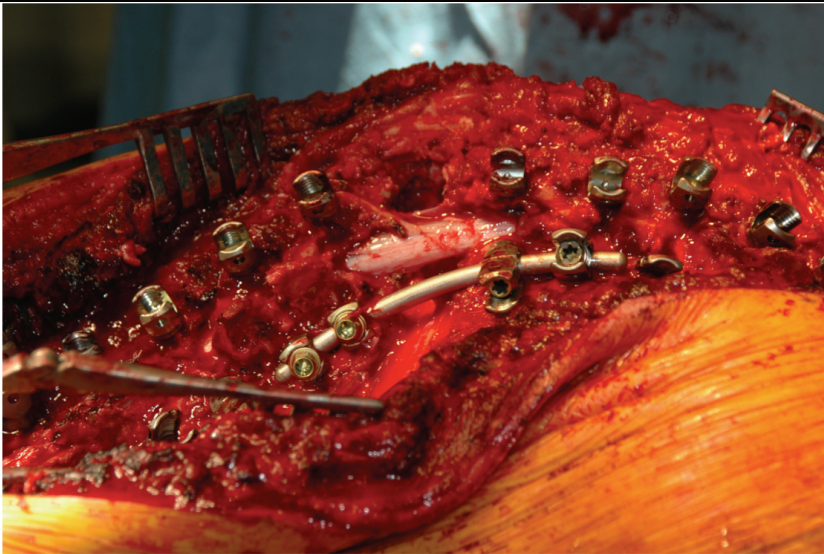


### ***Vertebral Column Resection***

The necessity of using extensive spinal osteotomies should never arise in congenital scoliosis, when it is appropriately diagnosed and treated at an early stage (McMaster 1998). The indication for vertebral column resection is a severe rigid spinal deformity ( $> 80^\circ$ ) with fixed spinal and/or pelvic imbalance (Bradford & Tribus 1997). This situation arises most commonly in congenital scoliosis patients with unilateral unsegmented bar with a contralateral hemivertebra (McMaster 1998). The objective of spinal osteotomy is to create mobility in the deformity, so that the curve can be corrected without marked distraction of the spine (Bradford & Tribus 1997).

The anterior approach is performed to the convexity of the curve. The intervertebral discs and associated end plates are resected back to the posterior longitudinal ligament. The vertebrae are then excised in piecemeal fashion. The underlying dura can be protected by using Gelfoam. The excised bone material is morcelized and placed into the resected area. If the blood loss and operative time has not been extensive, the posterior procedure can be continued in the same stage. If not, the patient is placed on total parenteral nutrition and the second-stage procedure can be undertaken usually after a week. Osteotomies of the posterior elements are performed to same levels as in the anterior procedure. Correction is then applied by using segmental instrumentation, which is first implanted to the convex side to close the osteotomy and then to the concave side to gain support and maintain correction over the whole length of the deformity. Finally, a posterior spinal fusion is performed with bone grafts implanted over the whole deformity. Postoperatively, a thoracolumbar orthosis is recommended to gain more solid fusion. (Bradford & Tribus 1997)

Suk et. al introduced a VCR technique by posterior only approach (P-VCR) in 2002 (Figure 17). The aim was to reduce operative time, blood loss and complications. After a posterior midline incision and exposure of the spine, facetectomies are performed to those segments, in which facet joints are not ankylosed or fused posteriorly. Several pedicle screws are inserted on both sides of the VCR area. A contoured rod is anchored by the pedicle screws to the concave side to provide support. Posterior spinal structures and intervertebral discs are resected from convexity to the concavity of the curve. Another temporary rod is anchored on the convexity. The first rod is removed and the vertebral body and disc resection is continued on the concave side to complete the resection. The removed concave side rod is reattached. Curve correction is performed, bone grafts or titanium mesh cage are implanted into the resected area and finally posterior fusion promoted by implanting bone grafts upon the whole instrumented area. After the operation, a plaster jacket is worn for 3-4 months and thereafter a custom made orthosis for another 3 months. (Suk et al. 2002)



**Figure 17.** Posterior vertebral column resection. The dura is seen in the middle, adjacent to the concave supporting rod.

In mixed cohorts, major curve corrections of 52-66 % and coronal imbalance corrections of 72-84 % have been achieved in preoperative major curves of 57-103° and coronal imbalance of 3-8 cm. Complication rate has varied between 8 - 34 % with a 2-8 % incidence of transient neurologic complications. (Bradford & Tribus 1997; Suk et al. 2002; Lenke et al. 2009; Hamzaoglu et al. 2011) The selection between posterior only or anteroposterior VCR has not been resolved, but it appears that equal results can be achieved by both methods in the hands of an experienced surgeon.

### ***Congenital Kyphosis & Lordosis***

Congenital kyphosis and lordosis are deformities that respond poorly to conservative methods (Dubousset 2001). Early posterior spinal fusion (< 3-5 years of age) has been recommended in the earlier studies to prevent the development of severe (> 45°) deformity, that causes spinal cord impingement. (Winter et al. 1973; McMaster & Singh 1999; Kim et al. 2001) It is believed that the anterior longitudinal growth leads to curve correction in a young patient when congenital kyphosis is caused by posterolateral quadrant or posterior hemivertebra. The studies so far have showed that this growth potential is unpredictable. When neurological symptoms are present, anterior decompression and fusion is required. (Kim et al. 2001)

In kyphotic curves exceeding 60°, anteroposterior spinal fusion has been advocated (Winter et al. 1973; Kim et al. 2001). Instrumented posterior or posterolateral hemivertebra excision may also be performed (Ruf & Harms 2003). In younger patients (< 3 years of age), anteroposterior surgery appears to be safer than in older patients who seem to be at a higher risk of developing neurologic complication. (Kim et al. 2001)

In older patients with recent mild neurologic deficit due to flexible kyphosis and kyphoscoliosis, a distraction cast in addition to halo traction can be used (See Neuromuscular scoliosis, Surgical Treatment of Severe Scoliosis). After the recovery of neurologic function, a combined anteroposterior

spinal fusion is recommended. In rigid deformities when symptoms persist or progress, an anterior decompression is required in addition to the anteroposterior fusion. (Lonstein 1999; Dubousset 2001) In pure kyphosis, this can be achieved by P-VCR. When kyphoscoliosis is present, decompression can be performed by a costal transectomy approach on the concave side. (Dubousset 2001)

Lordotic congenital deformities that are diagnosed at an early stage can be treated by anterior spinal fusion. In the more severe cases when correction needs to be performed, anterior closing wedges and a posterior osteotomy of the bar is necessary. (Lonstein 1999) When an anterior hemivertebra causes airway constriction anterior hemivertebra resection has been recommended (Dubousset 2001). Lordoscoliosis resulting from asymmetrical failure of segmentation with absent ribs can be treated by progressive rib distractor. (Dubousset 2001)

## Secondary Scoliosis

### Skeletal Dysplasia

Skeletal dysplasia results from several different disorders causing a systemic defect in the formation of the skeleton. Most commonly the cartilage matrix or endochondrial ossification are affected. (Sponseller 2001) Skeletal dysplasias are clinically characterized by a variable degree of skeletal deformities and dwarfism (Sillence et al. 1979). Despite the wide range of diseases that cause skeletal dysplasia, certain spinal problems are common: instability, deformity and stenosis (Table 3). (Sponseller 2001)

**Table 3.** Skeletal dysplasia and spinal disorders. Modified form the table presented in the Pediatric Spine (Sponseller 2001).

<b>Condition</b>	<b>Common spinal disorders</b>
Achondroplasia	Thoracolumbar kyphosis, spinal stenosis
Diastrophic dysplasia	Cervical kyphosis, scoliosis, kyphosis, spinal stenosis
Metatropic dysplasia	Cervical instability, scoliosis, kyphosis
Kneist	Cervical instability, scoliosis, kyphosis
Spondyloepiphyseal dysplasia	Cervical instability, scoliosis, kyphosis
Larsen Syndrome	Cervical kyphosis, scoliosis, kyphosis
Stickler Syndrome	Scoliosis, kyphosis

Spinal instability is most commonly seen in the atlantoaxial level. It is recommended to investigate this matter clinically and radiologically before school age or especially if operative treatment is planned for some reason or another. Atlantoaxial spinal fusion may be necessary if there is considerable translation between the vertebrae, neurologic deficits or risk for the development of spinal cord impingement. (Sponseller 2001)

Cervical spinal deformity in skeletal dysplasia is usually kyphosis that is mainly seen in diastrophic dysplasia and Larsen's syndrome. In contrast to Larsen's syndrome, cervical kyphosis in diastrophic dysplasia usually resolves with growth. Bracing has not been used in the treatment of this deformity. If neurologic defects occur due to cervical kyphosis, a decompression procedure is indicated. (Remes et al. 1999)

Thoracic and thoracolumbar kyphosis are the most common spinal deformities in skeletal dysplasia (Sponseller 2001). The effectiveness of brace treatment has not been proven. In a young patient with a flexible curve, treatment with a Milwaukee brace has been proposed. Spinal fusion has been recommended in severe, progressive curves exceeding 60-70°. (Bethem et al. 1981)

Scoliosis is most commonly seen in diastrophic, spondyloepiphyseal, Kneist and metatropic dysplasia. The efficacy of bracing is poorly understood. Surgery has been recommended if the curve is severe (>50-69°), unbalanced or associated with marked kyphosis. (Sponseller 2001)

Spinal stenosis is most often seen in achondroplasia. Frequent claudication or neurologic deficits are indications for surgical decompression. (Ain et al. 2006)

The surgical treatment and postoperative management of patients with skeletal dysplasia is difficult. The anesthesia is complicated due to abnormal oropharyngeal anatomy, cervical instability, mandible and neck stiffness and in some instances by a difficult intravenous access. Patients with skeletal dysplasia often have coexisting disabilities, like hip contractures, which complicate postoperative care and rehabilitation, and should be taken into account whenever spinal deformity correction is planned for. (Sponseller 2001)

## **Diastrophic Dysplasia**

Diastrophic dysplasia was first recognized as a separate entity by Lamy and Maroteaux in 1960, while previous reports of the disease can be found as early as 1910 (Lamy & Maroteaux 1960; Walker et al. 1972). Although rare in most of the world, diastrophic dysplasia is the most common form of skeletal dysplasia in Finland (Kaitila 1980). Pathognomonic clinical findings of this disease include short-limbed short stature, multiple joint contractures, early degeneration of joints and spinal deformities (Walker et al. 1972; Poussa et al. 1991).

### **Epidemiology**

The incidence of diastrophic dysplasia is 1 per 33 000 in Finland (Kaitila et al. 1989). The prevalence of scoliosis has varied between 37-88 % (Poussa et al. 1991; Tolo & Kopits 1989; Walker et al. 1972; Remes, Poussa, et al. 2001a). Cervical kyphosis is seen in one-third of patients (Poussa et al. 1991; Remes et al. 1999). Exaggerated lumbar lordosis has been observed in 41 % (Walker et al. 1972).

### **Etiology & Pathogenesis**

Diastrophic dysplasia is caused by mutations in the gene encoding a sulfate transporter membrane protein. A defect in the function of this protein is believed to cause reduced sulfate content of proteoglycans in the cartilage matrix, which leads to structural and functional defects in the cartilage. The exact pathogenesis is not fully understood. (Hästbacka et al. 1994) Morphologic studies have revealed alterations in several different cartilaginous structures like the intervertebral discs and growth plates (Stanescu et al. 1984; Remes et al. 2001)

### **Natural History**

#### ***Spinal Deformity***

The most common types of spinal deformity in diastrophic dysplasia are cervical kyphosis, thoracic, thoracolumbar and lumbar kyphoscoliosis and lumbar lordosis (Walker et al. 1972; Poussa et al. 1991).

The natural history of scoliosis in diastrophic dysplasia is variable and has been divided into three categories in a recent study on Finnish diastrophic dysplasia patients: early-progressive, idiopathic-like and mild, non-progressive. Approximately 13 % of diastrophic dysplasia related scoliosis is early-progressive, 48 % is idiopathic-like and 39 % is mild, non-progressive. (Remes et al. 2001)

In the early-progressive form, the age of onset is before the age of three and the curve magnitude exceeds 100° at skeletal maturity. Curve type is usually low thoracic or thoracolumbar and associated with severe vertebral rotation and kyphosis. The idiopathic-like scoliosis begins to develop before the age of ten and often exceeds 30° at skeletal maturity. The curve patterns are similar to AIS. Mild non-progressive scoliosis in diastrophic dysplasia begins to develop typically in adolescence and rarely exceeds 30° at skeletal maturity. (Remes et al. 2001)

In previous studies by other authors, spinal deformities in diastrophic dysplasia have been found to arise in childhood and to be progressive in most of the cases (Walker et al. 1972; Bethem et al. 1981; Tolo & Kopits 1989; Herring 1978). This raises the question, whether diastrophic dysplasia phenotype is milder in Finnish population or whether the patient enrollment in other studies has been biased towards patients with more severe spinal deformities.

Cervical kyphosis is usually evident in early childhood, but usually resolves spontaneously by growth and rarely necessitates treatment. In rare cases this deformity can progress to an extreme degree and cause quadriplegia and death. (Remes et al. 1999) Cervical spina bifida has also been observed in diastrophic dysplasia but its association with cervical kyphosis has not been established (Bethem et al. 1981).

Lumbar hyperlordosis has been found to be associated with a decreased lumbosacral angle. It has been suggested that this deformity would develop secondary to hip flexion contracture. (Poussa et al. 1991)

The spinal canal has been found to be narrowed in diastrophic dysplasia, but severe symptomatic spinal stenosis is uncommon (Remes et al. 2001). Narrowing of the spinal canal is most common in the cervical and lumbar spine (Remes 2001; Poussa et al. 1991).

### ***Other Associated Skeletal Deformities***

Hip joint contracture is common in diastrophic dysplasia (approximate prevalence 93 %) and usually progressive (Vaara et al. 1998). It is not found at birth, but becomes evident as the patient starts to walk (Kopits 1976; Vaara et al. 1998). The range of movements diminishes with age (Vaara et al. 1998). Premature hip joint arthritis is common and the alteration of its natural history is difficult with early surgical intervention like interthrocantalic valgus-extension osteotomy. Total hip replacement has been proposed to be the method of choice in adulthood. (Kopits 1976; Helenius et al. 2003)

Knee joint instability, flexion contractures, valgus deformity and hyperextension are found in diastrophic dysplasia patients (Stover et al. 1963; Peltonen et al. 1999). The range of movement in the knee typically starts to diminish before the age of five years (Peltonen et al. 1999). The development of knee joint arthritis is common and surgical intervention by total knee arthroplasty has been found to be effective treatment method (Helenius et al. 2003).

Foot deformities are common and include metatarsus adductus with or without tarsal valgus, equinovarus adductus and equinus deformities (Ryöppy et al. 1992).

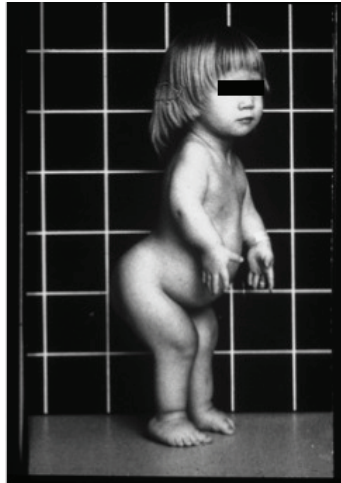### ***Pulmonary Function***

Remes and coworkers studied pulmonary function in diastrophic dysplasia. Most of the patients had normal lung volumes, but none of the patients had an early progressive type of spinal deformity in this study. PFT results (especially total lung capacity) were inversely correlated with the degree of scoliosis and age of the patient. (Remes et al. 2002)

### ***Life Expectancy***

Diastrophic dysplasia is associated with increased mortality in early life, but those surviving childhood have a reasonably good prognosis. In a study by Walker et al. from 1972, 4 out of 51 (8 %) patients died in infancy. (Walker et al. 1972) Tracheo- and bronchomalasia as well as severe cervical kyphosis have been reported as likely causes of death in some patients, but there has not been extensive studies on this matter (Walker et al. 1972; Remes et al. 1999).

## **Clinical picture & Diagnosis**



**Figure 18.** A girl with diastrophic dysplasia.

Common clinical features of diastrophic dysplasia include short-limbed dwarfism, “hitch-hiker” thumb, foot deformities, multiple joint contracture and subluxation tendency, cleft palate, deformed ear pinnae and spinal deformity (Figure 18)(Walker et al. 1972). Cervical kyphosis develops at early infancy, but usually resolves spontaneously (Remes et al. 1999). Other spinal deformities, like scoliosis, kyphosis and hyperlordosis, develop most commonly in later childhood (Poussa et al. 1991; Tolo & Kopits 1989). The diagnosis of spinal deformities is made from the posteroanterior and lateral radiographs of the spine. Radiographs of the cervical spine need to be performed to assess the degree of atlantoaxial instability and cervical kyphosis, especially if surgical treatment is considered. (Sponseller 2001) The extent of associated skeletal deformities, like hip and knee joint contracture,



should be evaluated to gain a clear picture of the orthopaedic problems associated with each individual patient and determine the best methods of treatment.

## **Treatment**

The treatment methods of spinal deformities in diastrophic dysplasia are similar to AIS: observation, bracing and surgery. The determining factors of treatment method are the age of the patient, the degree and progression rate of the deformity and symptoms. The studies regarding treatment of spinal deformities in diastrophic dysplasia are sparse and therefore general guidelines are lacking (Remes et al. 2001).

### **Observation**

It seems that most of the spinal deformities in diastrophic dysplasia (at least in the Finnish population) can be managed by observation (Poussa et al. 1991). Mild, non-progressive forms of scoliosis and most of the cases of cervical kyphosis do not seem to require additional treatment (Remes et al. 1999; Remes et al. 2001).

### **Bracing**

The success of brace treatment in diastrophic dysplasia has been controversial. Bethem et al. found the Milwaukee brace to be effective in preventing progression in two patients (Bethem et al. 1981). The bracing results of Herring and Poussa and their coworkers were not successful in one and three patients, respectively, but the treatment was started relatively late when the curves already exceeded 50° (Herring 1978; Poussa et al. 1991). Early-progressive type of scoliosis is not believed to benefit from bracing (Remes 2001).

### **Surgery**

The indications for surgical treatment in diastrophic dysplasia are not established. Poussa et al. recommended treating asymmetrical hip flexion contracture before spinal surgery so that trunk balance could be better preserved (Poussa et al. 1991). It seems that early-progressive scoliosis can only be controlled by surgical treatment (Remes et al. 2001). Posterior only spinal fusion with instrumentation and combined anteroposterior spinal fusion with posterior instrumentation have been used in the past (Herring 1978; Poussa et al. 1991; Matsuyama et al. 1999). The efficacy of pediatric non-fusion techniques, VCR and halo-traction has not been reported in this patient population.

***Posterior Spinal Fusion with Instrumentation***

In the study by Herring et al., two patients operated on by posterior spinal fusion and Harrington instrumentation had a moderate correction of 56° and 80° major curves at the age of 10 years (Herring 1978). Three patients with thoracolumbar curves underwent primary posterior spinal fusion in the study by Matsuyama et al. but only one of them was regarded as a success (Matsuyama et al. 1999).

***Combined Anteroposterior Spinal Fusion with Instrumentation***

Poussa et al. reported a successful anteroposterior spinal fusion in a patient with a 70° thoracolumbar curve. Major curve correction was 57 %. (Poussa et al. 1991) Matsuyama and coworkers reported results on 17 patients undergoing anteroposterior spinal fusion with major curves of 79-90°. They were able to prevent the progression of the curves (without correction). Complication rate was 33 % after a follow-up of two years. (Matsuyama et al. 1999) Long-term clinical, radiographic and HRQoL results of surgical treatment of scoliosis and kyphosis are lacking.

## **Neuromuscular scoliosis**

Neuromuscular spinal deformities develop from a diverse group of diseases and conditions that affect the neuromuscular system. Neuromuscular scoliosis (NMS) patients are afflicted by other problems in addition to scoliosis such as joint contractures, dislocated hips, epilepsy, mental retardation and difficulties with nutrition and respiration. (Lonstein 2001)

## **Epidemiology**

The prevalence of spinal deformities in neuromuscular disease is variable ranging from 8 % in total cerebral palsy (CP) population to 77 % in non-ambulatory Duchenne muscular dystrophy (DMD) population. (Persson-Bunke et al. 2012; Kinali et al. 2006)

## **Etiology & Pathogenesis**

The etiopathogenesis of NMS is linked to the underlying neuromuscular disease. A classification proposed by the Scoliosis Research Society divides NMS according to etiology and neuromuscular disease. The main division is between neuropathic and myopathic diseases. Neuropathic diseases are divided into upper (e.g. CP, syringomyelia and spinal cord trauma) and lower motor neuron lesions (e.g. poliomyelitis, spinal muscular atrophy). Some conditions like myelomeningocele (MMC) and spinal cord trauma can involve both upper and lower motor neuron lesions. Myopathic diseases include Duchenne muscular dystrophy, arthrogryposis and other forms of myopathy among others. In some cases the underlying disease or location of the lesion that causes the spinal deformity may be unknown. (Table 4) (Bradford 1987; Lonstein 2001)

**Table 4.** The classification of neuromuscular scoliosis according to the Scoliosis Research Society with some common examples. (Bradford 1987)

Classification		Disease
Neuropathic	Upper motor neuron	Cerebral Palsy (CP)
		Friedreich’s ataxia
		Charcot-Marie-Tooth disease
		Syringomyelia
		Spinal cord tumor
		Spinal cord injury
		-----
	Lower motor neuron	Spinal muscular atrophy (SMA)
		Poliomyelitis
		Other viral myelitides
		Traumatic
Myopathic		Arthrogryposis
		Duchenne muscular dystrophy (DMD)
		Myotonia dystrophica
		Congenital hypotonia

While the diseases behind NMS are variable, they share common features. The ultimate functional path in the abnormal neuromuscular system causing the spinal deformity is the motor unit, which manifests dysfunction through decreased (flaccid), increased (spastic) or out-of-sequence (dyskinetic) motor activity. (McCarthy 1999)

## Natural History

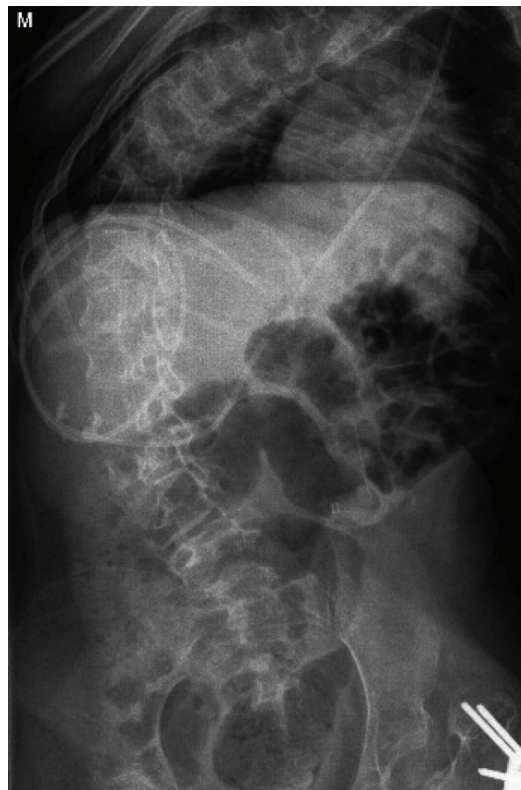In NMS, curve progression can occur earlier, faster and more often than in AIS. Also, the long-term effects of NMS are more disabling (McCarthy 1999). The progressive spinal deformity causes loss of sitting balance and hinders the functional ability. The effects on pulmonary function are believed to be more devastating because of abnormally functioning trunk muscles. (Lonstein 2001)

---

***Spinal Deformity***

It has been observed that the earlier the neuromuscular disease develops and the more severe the condition, the earlier and greater is the likelihood of the development of severe spinal deformity (James 1956). Other general factors behind the development of severe scoliosis in neuromuscular disease are motor involvement, non-ambulatory status and rapid periods of growth (Persson-Bunke et al. 2012; Saito et al. 1998; McDonald et al. 1995; Piggott 1980; Merlini et al. 1989). While some of the NMS curve patterns resemble those of idiopathic scoliosis, many (especially non-ambulatory) patients develop long collapsing C-shaped curves that include the sacrum as a part of the curve (Lonstein & Akbarnia 1983; McCarthy 1999). A significant kyphosis may also be observed (McCarthy 1999). Poor pelvic obliquity is commonly associated with NMS and may be related to contractures of the muscles above or below the pelvis (Winter & Pinto 1986; McCarthy 1999).

In the CP patient population in general, scoliosis is most commonly diagnosed after the age of eight (Persson-Bunke et al. 2012). In spastic CP, significant scoliosis is usually present before the age of ten, progresses rapidly soon after onset and continues beyond skeletal maturity (Saito et al. 1998). Curve types in CP can be divided into group I, consisting of single and double curves found mainly in ambulatory patients, and group II, in which long C-shaped curves with a thoracolumbar or lumbar apex are present in non-ambulatory patients (Figure 19) (Lonstein & Akbarnia 1983). The curves can reach magnitudes of 140° in severe spastic CP (Saito et al. 1998).



**Figure 19.** Long C shaped scoliosis in a CP patient.

In DMD, loss of ambulation and age appear to be significantly associated with the development of scoliosis (McDonald et al. 1995). As progression continues, the spine usually collapses into a long C-shaped curve with significant pelvic obliquity (Galasko et al. 1992).

In SMA, spinal deformity is usually progressive and diagnosed at the age of 6-10 years. Factors that have been associated with curve progression are the level of motor function, type of SMA, age of onset and the severity of scoliosis. (Granata et al. 1989; Merlini et al. 1989; Bowen & Lipton 2001) Contractures in the pelvis and lower limbs as well as hip dislocation may also be contributing factors. In non-ambulatory patients scoliosis type is usually C-shaped and the apex located at the thoracolumbar region. Double curves can be present in ambulatory SMA patients. (Bowen & Lipton 2001) Curves can reach extreme sizes of 165° (Granata et al. 1989).

Spinal deformities that are typical to MMC differ somewhat from other types of NMS. Common types are scoliosis in association with marked lordosis, congenital spinal malformations (See Congenital Scoliosis) and lumbar kyphosis (Lindseth 2001). The incidence of scoliosis is 100 % in high-level thoracic paraplegia and 70 % in low-level, lumbar paraplegia (Mackel & Lindseth 1975; Piggott 1980). Scoliosis usually presents in the first decade of life (Mackel & Lindseth 1975). High-level spina bifida has been associated with the development of a long C-shaped scoliosis. This type of curve can also be associated with asymmetric levels of paralysis and/or spastic hemiplegia resulting from hydrocephalus. The deformity is present at a young age in infancy and almost always progressive. (Lindseth 2001) Uncompensated hydrocephalus and hydromyelia can cause S-type scoliosis usually on the thoracic or thoracolumbar spine resembling AIS (Hall et al. 1979; Lindseth 2001). Scoliosis caused by tethered cord has been associated with lumbar curves and lordosis (Lindseth 2001). Lumbar kyphosis occurs in approximately 12-18 % (Piggott 1980; Shurtleff et al. 1976). The kyphosis exceeds 65° in 10 % of these kyphotic patients already at birth. Most of the cases are progressive. (Shurtleff et al. 1976) Three types of kyphosis patterns have been recognized: collapsing C-shaped, rigid S-shaped and a rarer aplastic type (Lindseth 2001).

### ***Pulmonary Function***

In idiopathic scoliosis, decreased pulmonary function is known to be associated with the severity of scoliosis (Barois 1999; Kearon et al. 1993). Some neuromuscular diseases (e.g. DMD) impair pulmonary function independently of scoliosis (Hsu 1983; Inal-Ince et al. 2009). In DMD and SMA impairment is progressive and associated mainly with increasing age and in some studies with scoliosis as well (McDonald et al. 1995; Kurz et al. 1983; Inal-Ince et al. 2009). In addition to restrictive lung disease, NMS patients have impaired pulmonary function and increased amounts of respiratory infections due to muscular weakness and poor cough and impaired airway protective reflexes (Kang et al. 2011). In patients with early-onset scoliosis or kyphosis (diagnosed during the first decade of life), there is a risk of developing restrictive pulmonary insufficiency, because the maturation of lungs continues until the age of eight years (Davies & Reid 1971; Pehrsson et al. 1992).

### ***Cardiac Function***

Certain neuromuscular diseases like DMD affect myocardial function and cause heart failure. This cardiac dysfunction has been related to the progressive nature of the disease and increasing age. (Roberto et al. 2011)

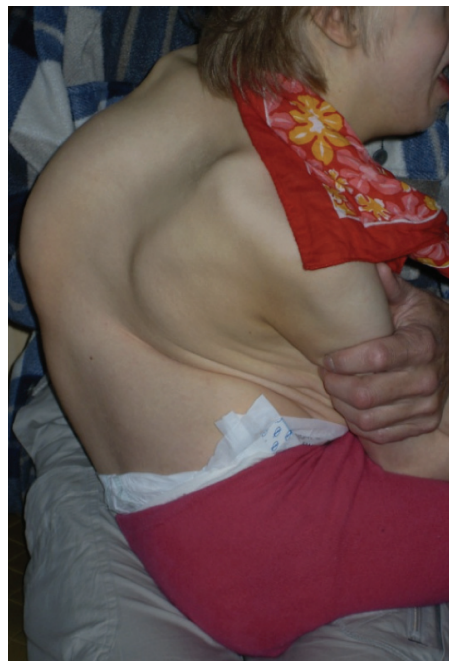### ***Gastrointestinal Function***

Gastrointestinal disorders are common in patients with neuromuscular scoliosis. Common symptoms in cerebral palsy include dysphagia, constipation and gastroesophageal reflux associated with impaired gastric emptying and motility. In some NMS patients gastrostomy tube insertion is required to prevent excessive weight loss due to oral-motor dysfunction. (Sullivan 2008)

### **Clinical picture & Diagnosis**

Worsening spinal and sitting balance are the most common findings in NMS (Figure 20). The collapsed spinal deformity found in non-ambulatory patients can significantly hinder functional ability and poor pelvic obliquity can lead to pressure sores. In ambulatory patients the symptoms are similar to AIS. (McCarthy 1999; Lonstein 2001)

The definitive neuromuscular diagnosis is important when deciding the course of treatment. A multidisciplinary team should assess all the systems affected by the neuromuscular disease. Especially important is to evaluate the patient's functional ability (hand usage, assistance in daily activities, intelligence, vision, hearing), neurological and nutritional status (weight changes, gastrointestinal symptoms), growth and pulmonary function (respiratory infections, pneumonias). (McCarthy 1999)



**Figure 20.** Severe kyphoscoliosis seen in a patient with CP.

In the orthopedic evaluation, attention should be paid to the spinal balance, pelvic obliquity, flexibility of the spine, hip joint contractures and dislocations, upper and lower extremity joint contractures and spasticity, hand function and skin sensation. (Winter & Pinto 1986; McCarthy 1999; Lonstein 2001)

Posteroanterior and lateral radiographs of the spine should be obtained with minimal support to get an accurate appreciation of the spinal deformity and balance under the effect of gravity and pelvic obliquity. Traction radiographs are obtained to assess the rigidity of the spine. (Lonstein 2001)

In MMC, it is recommended to obtain annual radiographs early on from age one onwards, and if a progressive scoliosis is observed, MRI is indicated to reveal associated deformities like Arnold-Chiari, hydrocephalus, syrinx or hydromyelia and spinal cord tumors. The MRI findings should be interpreted together with clinical findings to assess the cause of scoliosis. (Lindseth 2001)

### **Treatment**

The treatment options for NMS are observation, seating support, bracing and surgery. The main determining factors of treatment are curve size, sitting ability, pressure sores and sexual maturity. (Lonstein 2001)

In MMC, the treatment of the spinal deformity depends on the associated neurological and congenital deformities, the level and type of curve, the extent of paralysis and the age and ambulatory status of the patient. It is recommended to address intraspinal anomalies before spinal deformity correction takes place. (Osebold et al. 1982; Lindseth 2001) Most commonly, spina bifida is surgically closed after birth, but recently a method for prenatal closure of spina bifida has been introduced. This method has been found to decrease the need for shunting and improve motor function results at the age of 2-3 years. However, the complication rate is still high with a 38 % incidence of preterm birth and the effects on the development of spinal deformity are still unknown. (Adzick et al. 2011)

### **Observation**

When the curve size is mild in an ambulatory or non-ambulatory patient and there is no loss of spinal and sitting balance or significant progression in a non-ambulatory patient, close observation can be undertaken (McCarthy 1999; Lonstein 2001).



## **Seating support**

Seating systems are used for NMS patients, who cannot sit on their own. The principle is to implement progressive support according to the severity of the sitting inability: first the pelvis, then the anterior and lateral thorax and finally the head is supported. (Lonstein 2001)

## **Bracing**

In NMS, the aim of bracing is to control the curve during growth and delay the need for scoliosis surgery. Brace treatment is more demanding in NMS than in AIS with a higher frequency of complications, like skin problems. (McCarthy 1999; Lonstein 2001) The efficacy of bracing in this patient population has been controversial (Miller et al. 1996; McMaster & Clayton 1980; McCarthy 1999). For some patients, curve control by bracing is possible into the juvenile years, but with the onset of the pubertal growth spurt, this control is usually lost and surgical correction is unavoidable especially in non-ambulatory patients. (Lonstein 2001)

In DMD, bracing may slow curve progression (Kinali et al. 2006). It is still considered to be inappropriate because cardiac and pulmonary function continues to deteriorate and this can lead to problems with potential subsequent surgical treatment. The spinal deformity will eventually progress rapidly despite of brace treatment. (Cambridge & Drennan 1987) SMA patients with milder type of the disease may benefit from brace treatment but iatrogenic respiratory problems are quite common and bracing does not seem to halt progression in the long run (Aprin et al. 1982; Sucato 2007). In MMC, bracing is indicated in patients younger than 7 years of age with mild scoliosis curves. In lumbar kyphosis bracing is usually futile. (Lindseth 2001)

## **Surgery**

In contrary to AIS, scoliosis surgery may be required at a younger age and the fusion area is often long extending from the upper thoracic area to the pelvis (Cambridge & Drennan 1987; Aprin et al. 1982; Galasko et al. 1992; McCarthy 1999; Lonstein & Akbarnia 1983). The general indications for surgical correction of neuromuscular scoliosis (NMSC) in a severely disabled non-ambulatory patient are a progressive curve and poor, deteriorating sitting balance and loss of functional level in some other form. (McCarthy 1999; Lonstein & Akbarnia 1983)

Some disease-related rules exist in NMSC. In ambulatory CP patients without significant mental retardation, operative treatment is performed when the curve exceeds 45-50°, or when there is marked progression in a growing patient. (Lonstein 2001) In DMD, it has been common to perform surgery when the curve exceeds 20°, but variable practices still exists in different medical centers (Galasko et al. 1992; Kinali et al. 2006). Patients with SMA usually undergo NMSC after the curve has exceeded 50-60° (Aprin et al. 1982; Sucato 2007).

The preoperative evaluation needs to be thorough. The assessment of pulmonary function is important in regards of anesthesia, the possibility of using an anterior approach and for anticipating possible

---

postoperative complications (Jenkins et al. 1982; Vedantam et al. 2000; McCarthy 1999). Nutritional status needs to be evaluated and improved before surgery if the patient fails to thrive. Poor nutritional status has been linked to increased amount of infections and lengthened recovery period after surgery. (Jevsevar & Karlin 1993) The current functional ability and recent changes in it should be documented. Deterioration of functional ability is not necessarily caused by the spinal deformity but by the progressive nature of the underlying disease. (Lonstein 2001)

The surgical procedure itself and the postoperative care are demanding. Intraoperative bleeding is commonly more profuse because of osteopenia, weak muscles and longer operative times. Cell-saving device is recommended to lessen the need to use blood transfusion. (McCarthy 1999) Because of long fusion areas, pelvic fixation and poor bone quality, autogenous bone grafts are usually not sufficient enough to achieve solid fusion and allografts as well as bone substitutes are often necessary (Lonstein 2001). Mobilization should be started as soon as possible to achieve the preoperative ambulatory status and the best possible functional ability. (McCarthy 1999; Lonstein 2001)

### ***Operative Methods***

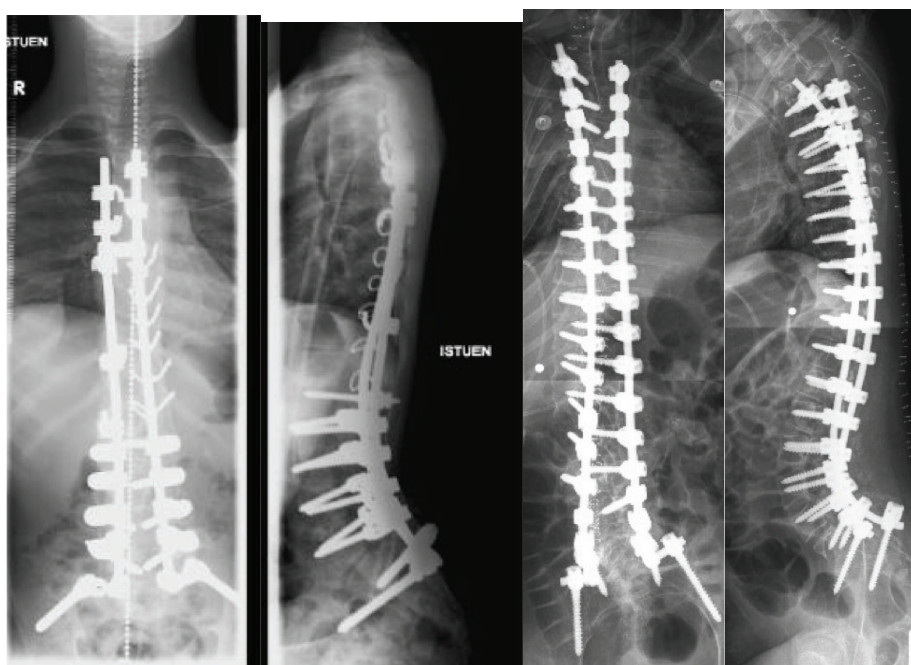
There are several difficulties in surgical correction of NMS, which have driven the development of new spinal fusion instrumentation and methods in this patient group. It is important to achieve a balanced spine over a level pelvis in patients with NMS. The instrumented posterior and combined anteroposterior instrumented spinal fusion have been the mainstays of treatment. (Lonstein & Akbarnia 1983) In flexible smaller curves and in DMD, instrumented posterior spinal fusion is sufficient (Lonstein & Akbarnia 1983; Galasko et al. 1992). The combined approach has been used in rigid, large curves and in patients, whose posterior bone structures of the spine are absent (Lonstein & Akbarnia 1983; Osebold et al. 1982). The anterior approach also addresses the problem of crankshafting in younger NMS patients (Dubousset et al. 1989). The use of the combined approach, however, may pose more risks to the patient than posterior only approach and therefore its use should be carefully considered. The positive results gained in appearance and correction should be weighed against the longer operative time, more significant blood loss, the possible negative effects on pulmonary function and higher rate of complications associated with anterior fusion procedures (Gitelman et al. 2011; Reames et al. 2011; Lonstein 2001).

### ***Instrumentation***

As in AIS, the Harrington instrumentation was the first type of construct to be used in NMS patients. Non-union and curve deterioration rate after surgery was found to be significant, which led to the development of other instrumentations (Bonnert et al. 1976). Luque introduced a construct with segmental spinal fixation, which applied translational corrective forces by using sublaminar wires and 2 unconnected rods, but it failed to address the problem of high non-union rate (Allen & Ferguson 1982). The next phase of evolution was the introduction of pelvic fixation in the Luque-Galvestone construct (Gau et al. 1991). The problem with two separate rods was noted to be swiveling that led to rod translation and loss of fixation after surgery. The Unit rod, consisting of a single stiff precontoured U-shaped rod, was developed to address this problem, but the disadvantage of this system has been its poor suitability to patients with hyperlordosis. (Bell et al. 1989; Tsirikos et al. 2008) Because in some situations, the preservation of lumbosacral movement is beneficial, the Unit rod was modified to end in the lower lumbar vertebrae by pedicle screws. This system was called the

U-rod. After the Unit rod and U-rod, third-generation instrumentations (hybrid and TPS) have been introduced for the operative treatment of NMS patients (Piazzolla et al. 2011; Modi et al. 2008).

The selection of modern day instrumentation for NMS is between the Unit rod, U-rod, hybrid and TPS construct (Figure 21). The main curve (45-75 %) and pelvic obliquity (43-78 %) correction rates of these methods have been comparable with similar amount of complications (12-32 %)(Bell et al. 1989; Tsirikos et al. 2008; McCall & Hayes 2005; Modi et al. 2009a; Tsirikos & Mains 2011; Piazzolla et al. 2011) Matched comparative studies and randomized clinical trials are lacking on this regard and clear guidelines on the selection of instrumentation cannot be made.



**Figure 21.** Hybrid (two pictures on the left) and TPS (total pedicle screw) instrumentations (two pictures on the right) with pelvic fixation in NMS patients.

### ***Spinal Fusion Area***

The extent of spinal fusion depends on the curve pattern and ambulatory status. In walking patients, the guidelines for fusion area are similar to AIS (McCarthy 1999). In non-ambulatory patients with typical large C-shaped curves, spinal fusion is generally extended to the lower lumbar vertebrae, sacrum or iliac bone depending on the extent of spinal imbalance or pelvic obliquity (Lonstein & Akbarnia 1983; Gau et al. 1991; McCall & Hayes 2005). The extension of instrumentation to the pelvis has been debated because it is associated with higher complication rate and destruction of lumbosacral movement (Islam et al. 2001). Latest studies have shown that pelvic fixation is recommended when pelvic obliquity exceeds approximately 15°, because in those cases, ending the fusion to lower lumbar vertebrae poses a risk for deterioration in pelvic obliquity after surgery (Modi et al. 2010; Takaso et al. 2010). In MMC, a significant lumbar lordosis may be present. If this deformity is overcorrected, the underlying hip contractures may prevent the patient from standing and

walking (Lindseth 2001). The proximal end of fusion is usually at the upper thoracic area (T2-T3). A fusion that is too short proximally can lead to junctional kyphosis above the instrumentation. (Lonstein & Akbarnia 1983; Gau et al. 1991)

### ***Complications***

The complication rate after NMSC is high (18-28%) (Reames et al. 2011; Master et al. 2011) Operative mortality occurs in 0.34 %. More severe major curve, non-ambulatory status and anterior spinal surgery has been associated with increased frequency of complications (Reames et al. 2011; Master et al. 2011).

Pulmonary complications are common and occur in 2-18 % of patients (Reames et al. 2011; Modi et al. 2009; Master et al. 2011). Earlier studies have proposed that poor PFT results before spinal surgery carry a higher risk for postoperative respiratory problems (Padman & McNamara 1990; Anderson et al. 1985). It was therefore thought that severe restrictive lung disease (FVC < 30 %) is a contraindication for NMSC. More recently, however, many investigators have come to the conclusion that even NMS patients with severe restrictive lung disease can undergo modern day NMSC without significantly increased morbidity and mortality. (Rawlins et al. 1996; Chong et al. 2011)

Gastrointestinal complications include prolonged paralytic ileus, swallowing difficulties, superior mesenteric artery syndrome and pancreatitis among others. The extent of and the underlying mechanisms behind these problems are poorly understood. (Master et al. 2011; Vande Velde et al. 2010)

The incidence of wound infection is 5-12 % following NMSC (Sponseller et al. 2000; Master et al. 2011). The majority of these infections are deep, inflicting the spinal fusion area and instrumentation and have been associated with the development of non-unions (Master et al. 2011).

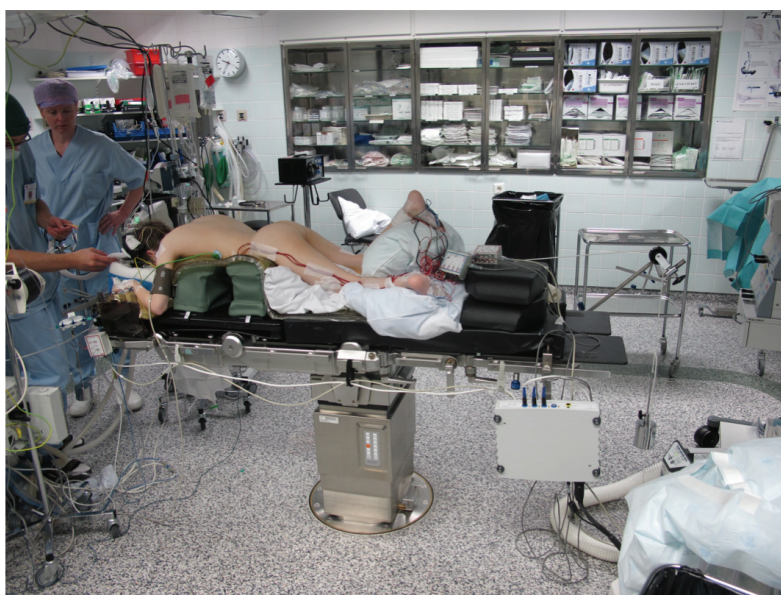Postoperative hip subluxation, dislocation and contracture are common problems in non-ambulatory NMS patients. Whether hip problems like joint contractures should be operated on before or after spinal deformity correction is debated (Cooke et al. 1989; Lonstein 2001). It has been suggested that the assessment of hip contractures is best made after spinal deformity operation because spinal compensation of the contractures can not be made due to fixed pelvis. After spinal surgery, hip contractures are initially treated by pillow support to prevent windswept abduction and adduction contractures from worsening. It is recommended to increase range of motion stepwise during the following 4-6 months until the fusion has become solid so that excessive torque does not break the instrumentation. (Lonstein 2001)

### ***Severe Scoliosis (> 80°)***

The good correction rates of posterior spinal fusion with TPS constructs in AIS have raised hopes that it could substitute the combined anteroposterior approach in NMS. Tsirikos and Modi and their coworkers found that posterior spinal fusion with TPS constructs can achieve comparable corrections with combined anteroposterior approach with low amount of complications in curves averaging approximately 80°(Tsirikos & Mains 2011; Modi et al. 2009). These studies, however, did not have matched comparison and the results cannot be generalized without reservation to curves of extreme

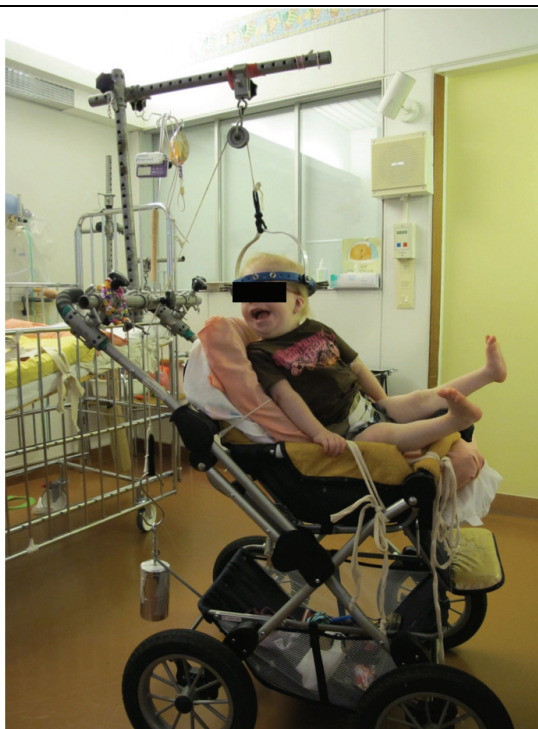size ( $> 100^\circ$ ). In the most severe cases of NMS, the combined anteroposterior spinal fusion with or without halo-traction and/or VCR has to be considered.

The role of traction in NMS surgery is to improve preoperative pulmonary status in severe chest wall and thoracic spine deformity, to gain more curve flexibility, correction and to decrease neurological complications during surgery (Sucato 2010; Koller et al. 2012) Traction is applied by halo-femoral, halo-pelvic or halo-gravity method. Halo-femoral and –pelvic tractions can be used preoperatively or intraoperatively. (Kalamchi et al. 1976; Keeler et al. 2010) Preoperative halo-femoral and –pelvic tractions require extended bed rest of several weeks and have been associated with significant amount of complications, like paraplegia, in the past (Kalamchi et al. 1976; Watanabe et al. 2010). Also the efficacy of preoperative traction has been questioned (Lonstein & Akbarnia 1983). Intraoperative halo-femoral traction has achieved comparable major curve correction (81 %) without significant traction related complications in NMS undergoing posterior spinal fusion procedure when compared to the combined anteroposterior fusion (Keeler et al. 2010).(Figure 22)



**Figure 22.** Intraoperative halo-femoral traction.

The halo-gravity traction can be used preoperatively and staged in between the anterior and posterior approaches (Figure 23). This device is applied to the patient only cranially and enables its use in the bed, a walking/standing apparatus or a wheelchair. (Watanabe et al. 2010) It seems to be well tolerated by the patient and family (Sucato 2010). The preoperative major curve correction has been 16-28 %, staged correction 37 % and the ultimate postoperative correction 21-51 % in patients with extreme curves (Watanabe et al. 2010; Sponseller et al. 2008; Koller et al. 2012). The main advantage of using halo-traction has been thought to be the possibility of avoiding the anterior approach, but this remains to be shown (Keeler et al. 2010; Watanabe et al. 2010; Koller et al. 2012). It has been proposed by Sponseller et al. that halo-gravity traction can possibly diminish the need for VCR in some cases (Sponseller et al. 2008).



**Figure 23.** Halo-gravity traction.

VCR is recommended in severe, rigid, angular scoliosis and kyphosis. Several techniques have been introduced either by anterior and posterior or posterior only approach (Boachie-Adjei & Bradford 1991; Bradford & Tribus 1997; Suk et al. 2002; Sponseller et al. 2009; Suh et al. 2009). VCR has not been recommended in patients who cannot withstand segmental pedicle screw instrumentation (Sucato 2010). VCR correction rates have been 59-66 % for major curves and 46-67 % for pelvic obliquity with an overall complication rate of 8-34 % and neurological complication rate of 0-9 % (Sponseller et al. 2011; Suh et al. 2009; Hamzaoglu et al. 2011; Lenke et al. 2009; Suk et al. 2002). The P-VCR has been found to have good results when compared to anteroposterior VCR and the combined anteroposterior spinal fusion. The blood loss in anteroposterior NMSC is substantial and therefore a recent study preferred using P-VCR in NMS. (Sponseller et al. 2011) It is good to notice, however, that there are no matched comparative studies or randomized clinical trials regarding the use of VCR and many studies have been conducted with heterogenic patient cohorts.

### ***Early-onset Neuromuscular Scoliosis***

Early-onset NMS, presenting itself on the first decade of life, is a problematic condition to treat. Progressive thoracic spinal deformity can lead to the development of thoracic insufficiency as mentioned before (Davies & Reid 1971; Akbarnia et al. 2005; White et al. 2011). More significant growth potential can also lead to crankshafting if only instrumented posterior spinal fusion is performed (Dubousset et al. 1989). The combined anteroposterior approach has therefore been the earlier mainstay of treatment in these patients (Lonstein & Akbarnia 1983). Early spinal fusion,

however, halts further spinal growth and has not been found to improve worsened pulmonary function (Goldberg et al. 2003; Karol 2011).

Several non-fusion constructs have been developed (See Congenital Scoliosis -chapter). VEPTR, in addition to rib-to-rib anchorage, can be implemented by spine-to-spine anchorage (White et al. 2011). This type of VEPTR based system and dual growing rods can achieve corrections of 30-52 % with complication rates of 43-48 %. (White et al. 2011; Akbarnia et al. 2005) The Shilla growth guidance rod construct and the magnetic growing rods can also be considered in NMS (McCarthy et al. 2010; Akbarnia et al. 2011)

### ***Surgical Treatment vs. Natural history in Neuromuscular Scoliosis***

NMSC appears to provide significant benefit in improving functionality and activity of the patients even in long-term (Lonstein & Akbarnia 1983; Larsson et al. 2005). The quality of life results of SMA and DMD patients, who have underwent NMSC, have been good (Takayama et al. 2009; Aprin et al. 1982). DMD patients have subjectively assessed their pulmonary function to be better after surgery, while there has been deterioration in PFT measurements (Takayama et al. 2009). The long-term effects of NMSC on pulmonary function are debated. Currently it seems, that scoliosis correction doesn't significantly alter the natural history of pulmonary function at least in myopathic NMS (Roberto et al. 2011).

## Spondylolisthesis

### Historical aspects

In 1782, a Belgian obstetrician called Herbineaux was the first to describe a lumbosacral deformity in a human that could be regarded as spondylolisthesis (Herbineaux 1782). The word, spondylolisthesis, was used in the literature for the first time by Kilian in 1854 (Kilian 1854). Isthmic spondylolisthesis caused by the defect in the pars interarticularis was recognized by Robert and Lambl in the 1850s (Robert 1855; Lambl 1858).

### Classification of spondylolisthesis

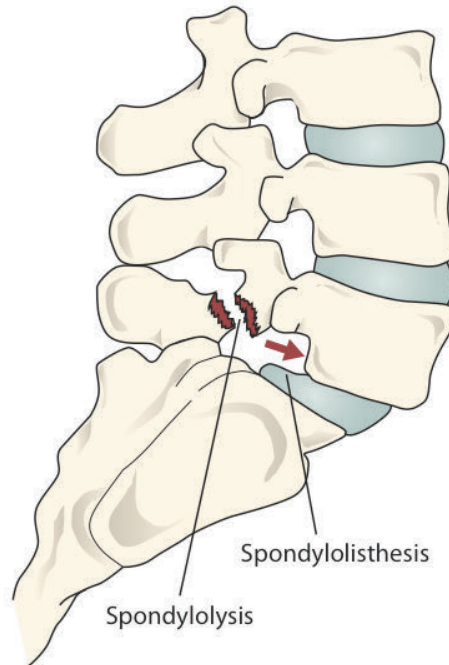
In the classic model by Newman and Wiltse, spondylolisthesis is classified according to aetiopathogenesis (Table 5) (Wiltse et al. 1976).

**Table 5.** The Newman and Wiltse spondylolisthesis classification.(Wiltse et al. 1976)

Classification of Spondylolisthesis	
I Dysplastic type	III Degenerative type
II Isthmic type:	a) Lytic
	b) Dysplastic
	IV Traumatic olisthesis
	V Pathological type

In the dysplastic type, a congenital dysplasia of the arch of L5 vertebrae and/or the upper portion of sacrum causes spondylolisthesis. Pars interarticularis can be elongated or intact. In the isthmic type, spondylolisthesis is caused by a fatigue fracture (lytic) or elongation of the pars interarticularis (Figure 24). Degenerative spondylolisthesis occurs in elderly people and is caused by the degeneration of intervertebral discs and facet joints. Traumatic olisthesis is caused by fractures or dislocations in parts of a vertebra other than the pars interarticularis. Pathological spondylolisthesis results from infectious or neoplastic diseases. (Wiltse et al. 1976)





**Figure 24.** Isthmic spondylolisthesis

In children, spondylolisthesis is mainly of isthmic or dysplastic type. Sometimes it is impossible to differentiate between lytic, elongated and dysplastic types if there is a lumbosacral deformity, like spina bifida, and pars interarticularis lysis simultaneously (Wiltse et al. 1976). True dysplastic type without spondylolysis is rare in Finland (Laurent & Einola 1961).

The degree of vertebral slip itself can be divided according to Meyerding spondylolisthesis grade: grade I is a 0-25% slip, grade II is a 26-50% slip, grade III is a 51-75 % slip, grade IV is a 76-100% and grade V is spondyloptosis, which means that the vertebra has fell over the S1 vertebra. (Meyerding 1932)

Other types of classifications have also been introduced. In a recent classification proposed by Spinal Deformity Study Group, spondylolisthesis is classified into six types according to radiographic slip grade (high vs. low grade) and spinopelvic balance (balanced vs unbalanced) (Hresko et al. 2007). See Spine, Radiography for more details.

## **Isthmic Spondylolisthesis**

### **Epidemiology**

The incidence of spondylolysis is approximately 4 % in children at the age of 6 and increases to 6 % in adulthood (Fredrickson et al. 1984). Some ethnic variation occurs with a higher incidence of this condition in American Eskimos for example (Stewart 1953). There have been no reports of spondylolysis or –listhesis occurring before birth (Rowe 1953; Fredrickson et al. 1984). Spondylolisthesis has been observed in approximately two-thirds of patients with spondylolysis (Fredrickson et al. 1984). The location of the lesion is most commonly seen in the L5 vertebra in children and adolescents and it is usually bilateral (Laurent & Osterman 1969; Beutler et al. 2003). Male predominance (2:1) has been observed, but severe spondylolisthesis seems to be more frequent in females (Roche 1951; Fredrickson et al. 1984; Boxall et al. 1979; Seitsalo et al. 1991).

### **Etiology & Pathogenesis**

The etiology and pathogenesis of spondylolysis and isthmic spondylolisthesis have been debated in the literature. These conditions have not been observed in newborn babies. In fetal cadaveric studies, there have been no reports of a separate ossification center or a congenital defect in the pars interarticularis (Rowe 1953). Single fracture of the pars interarticularis during birth or post-natal life have not been shown to be likely causes of spondylolysis (Wiltse 1962). Isthmic spondylolisthesis has been found to be more common in first-degree relatives than in the normal population. Spina bifida occulta and other lumbosacral segmental defects have been found in association with spondylolysis, while neural tube defects (e.g. anencephaly) have not (Wynne-Davies & Scott 1979; Albanese & Pizzutillo 1982; Seitsalo et al. 1991). Also, the higher incidence of spondylolysis in certain ethnic groups favors the likelihood of a hereditary component behind isthmic spondylolisthesis (Stewart 1953).

Upright posture and ambulation seem to be essential in the development of spondylolysis and –olisthesis, because it hasn't been observed in non-ambulatory humans or animals (Wiltse 1962; Laurent & Einola 1961). Isthmic spondylolisthesis is frequently seen in persons, like gymnasts, who perform strenuous exercises and repetitive flexion, extension and rotation movements of the lumbar spine particularly during pre-adolescent growth spurt (Libson et al. 1982; Goldstein et al. 1991; Rossi 1978). The reason why lysis of pars interarticularis is seen most commonly in the L5 vertebra has been explained by its subjection to the greatest amount of stress during daily activities. Currently the most popular explanation for the development of spondylolysis is that recurrent micro-trauma to a congenitally weak pars interarticularis results in a stress fracture. (Leone et al. 2011)

Spondylolisthesis is usually observable already at the time when spondylolysis is seen for the first time in radiographs. Progression is quite rare and usually occurs before the age of 16 years and has been associated with the period of rapid growth in puberty. (Laurent & Einola 1961; Fredrickson et al. 1984; Seitsalo et al. 1991) The mechanisms leading from spondylolysis to spondylolisthesis, are unclear (Leone et al. 2011). A bilateral spondylolytic defect seems to be a requirement however (Beutler et al. 2003). Farfan et al. and several other investigators have proposed that the location at which the slipping occurs, is between the epiphyseal growth plate and the vertebral bony endplate. Anteroposterior shearing forces that are exerted to this site (the weakest location in a spondylolytic lumbar spine) during daily activities are thought to be behind the development of spondylolisthesis in growing children (Farfan et al. 1976; Sairyo et al. 1998; Kajiura et al. 2001). Rounding off on the upper portion of the sacrum, wedging of the L5 vertebra, lumbosacral kyphosis and lumbar lordosis were considered to be possible risk factors for the development and progression of isthmic spondylolisthesis in the past, but are presently thought to be secondary or compensatory factors. The significance of female gender and spina bifida occulta in the pathogenesis of this condition is unknown. (Boxall et al. 1979; Wiltse 1962; Laurent & Einola 1961)

## **Natural History**

### ***Spinal Deformity***

The natural history of spondylolysis is generally benign. Unilateral defects have not been found to cause spondylolisthesis (Beutler et al. 2003). Bilateral spondylolysis, however, usually leads to spondylolisthesis (Laurent & Einola 1961; Seitsalo et al. 1991; Beutler et al. 2003). Beutler et al. conducted a prospective study on 500 asymptomatic school children and noticed that in persons (n=30) with spondylolysis observed for the first time in childhood or adolescence, the vertebral slip averaged 10 % after a 30-year follow-up (Beutler et al. 2003).

Isthmic spondylolisthesis is usually progressive in children and adolescents and it occurs mainly before the age of 16 years during periods of rapid growth (Laurent & Osterman 1969; Fredrickson et al. 1984; Seitsalo et al. 1991). The rate of progression, however, is normally mild after the first admission to doctor's practice and most of the progression seems to have already occurred (Seitsalo et al. 1991; Saraste 1987) In approximately 33-56 % of patients, who are referred to a specialist with isthmic spondylolisthesis, the vertebral slip exceeds to grade II or more (> 25 %) (Laurent & Osterman 1969; Seitsalo et al. 1991; Saraste 1987). Vertebral slips of grade II or greater have been found to have more slip progression during follow-up than grade I slips (Seitsalo et al. 1991). L4 vertebral slips have been found to progress more than L5 slips (Saraste 1987). It has been approximated that after adolescence, 5 % of patients could have slip progression in adulthood (Beutler et al. 2003). While some controversy exists, the progression of originally isthmic spondylolisthesis in adulthood has been attributed to intervertebral disc degeneration. (Floman 2000)

Progressive spondylolisthesis has been associated with the concomitant deterioration of lumbosacral kyphosis, sacral rounding, wedging of the olithetic vertebral body and lumbar lordosis. Female gender is more common in severe spondylolisthesis patients, but results on the incidence of spina bifida in these patients have been variable (Seitsalo et al. 1991; Boxall et al. 1979). In MRI studies, the degree of vertebral slip has been associated with the extent of intervertebral disc degeneration in

the olisthetic area in adulthood (Beutler et al. 2003). During recent years, radiographic spinopelvic parameters have gained interest in evaluating the progression of isthmic spondylolisthesis. It seems that spondylolisthesis patients have increased sacral slope and/or pelvic tilt, which results in increased pelvic incidence (See Spine, Radiography). The deterioration of lumbar lordosis is believed to be a compensatory mechanism against the increasing pelvic incidence, and an attempt to prevent the trunk from falling forwards and maintaining it above the femoral heads (Vialle et al. 2007; Labelle et al. 2004).

Risk factors for spondylolisthesis progression have been widely studied. Female gender, spina bifida, lumbosacral kyphosis, wedge-shaped olisthetic vertebra or sacral rounding have not been found to have predictive value for slip progression. Currently, the most significant predictors of progression are the initial vertebral slip and patient age. (Laurent & Osterman 1969; Seitsalo et al. 1991; Boxall et al. 1979) The significance of pelvic incidence as a pathogenic or prognostic factor has not been clearly established (Labelle et al. 2004; Vialle et al. 2007).

### ***Symptoms***

Prospective natural history studies on initially asymptomatic spondylolysis and –listhesis are sparse. Most of the studies are performed to persons who have sought doctor's appointment for one reason or another. It seems that the general nature of this disease is benign also in terms of symptoms. (Beutler et al. 2003) In the long-term study by Fredricksson and Beutler and coworkers, symptoms were not present during childhood and adolescence in patients with spondylolysis with or without –olisthesis (Fredrickson et al. 1984; Beutler et al. 2003). Patients with non-operated isthmic spondylolysis didn't have significant symptoms after a follow-up of 45 years (Beutler et al. 2003).

When the patients are referred to a specialist because of spondylolysis or isthmic spondylolisthesis, the prevalence of low back pain has been 50-73 %. Radiculopathy to lower extremities occurs in 28-55 % and seems to be more common in adolescence. Approximately 22 % of patients do not report low back pain in childhood or adolescence. (Laurent & Einola 1961; Laurent & Osterman 1969) Clinically abnormal trunk (hyperlordosis or –kyphosis) and secondary scoliosis has been observed in 42 % and 36 %, respectively (Laurent & Einola 1961; Saraste 1987). Significant neurologic defects (paralysis or paresis) are rare in general, occurring in approximately 2-3 %, and associated more with the dysplastic type (Saraste 1987). Mild symptoms without neurologic deficits have been noticed to resolve in most of the cases (Turner & Bianco 1971). Secondary scoliosis is believed to result from painful muscle spasms or asymmetrical slip of the olisthetic vertebra (Seitsalo et al. 1988).

Of patients with high-grade spondylolisthesis, only 5 % do not report significant symptoms regarding low back pain, radiculopathy, hamstring tightness or gait disturbance in childhood and adolescence. Low back pain has been observed in 50-79 % and radiculopathy in 30-62 % of patients with high-grade spondylolisthesis. Hamstring tightness is another common symptom and present in 50-65 %. Gait disturbances are observed in 20 %. Neurologic abnormalities in the lower extremities have been found in 35 %. Most of these findings are mild. Bladder and bowel dysfunction have not been reported. (Seitsalo et al. 1990; Boxall et al. 1979)

More severe slip, lumbosacral kyphosis, disc degeneration and wedging of the olisthetic vertebral body of have been associated with more severe low back pain, while in some studies radiographic parameters have not been consistent with the extent of symptoms (Saraste 1987; Boxall et al. 1979; Österman et al. 1993).

---

Vertebral slip progression of originally isthmic spondylolisthesis in adulthood can be accompanied by significant back pain. This condition, as mentioned above, seems to be associated with disc degeneration. (Floman 2000) In general the HRQoL results of patients with spondylolysis with or without spondylolisthesis have been good and comparable with the normal population after a follow-up of 45 years (Beutler et al. 2003).

## Clinical picture & Diagnosis

Most patients with spondylolysis are asymptomatic (Leone et al. 2011). When the patient is referred to a physician, low back pain is one of the most common symptoms present (Saraste 1987; Laurent & Einola 1961). Other symptoms are listed in Table 6. Objective lower extremity motor weakness is rare, but should always be clinically examined (Agabegi & Fischgrund 2010). The extent of symptoms may not correlate with the severity of the spinal deformity (Österman et al. 1993). Secondary lumbar scoliosis is present in fairly large amount of patients with symptomatic spondylolisthesis (Seitsalo, Osterman & Poussa 1988).

**Table 6.** Typical symptoms in isthmic spondylolisthesis.(Hu & Bradford 2001; Turner & Bianco 1971; Phalen & Dickson 1961; Laurent & Einola 1961; Seitsalo et al. 1988; Agabegi & Fischgrund 2010)

---

Low back pain

Hamstring tightness & Phalen-Dickson (hips and knees flexed) sign

Palpable step-off deformity along the spinous processes in the lower back

Hyperlordotic posture

Radiculopathy to lower extremities

Lumbar scoliosis

---

When spondylolytic defect is suspected, posteroanterior, lateral and oblique 45° right and left radiographs of the spine are obtained. A collimated lateral radiograph can also be performed to achieve better view of the spondylolytic defect. Spondylolysis can be diagnosed when a radiolucent defect is observed in the pars interarticularis. The classic sign of spondylolysis in the oblique radiographs is the “Scotty dog” finding, in which the defect resembles as a collar in a dog’s neck. (Leone et al. 2011)

Spondylolisthesis is easily observable in the lateral radiographs. In symptomatic spondylolisthesis, lateral flexion-extension radiographs can be used to assess the vertebral instability resulting from the pars interarticularis defect. The lateral radiograph should include the whole spine, so that the sagittal spinal balance can be measured. Nowadays it has also been recommended to extend the radiograph to

include femoral heads so that pelvic incidence can be measured (Labelle et al. 2004). Some investigators, however, prefer lumbosacral kyphosis to be superior to pelvic incidence and state that it correlates more markedly with the severity of spondylolisthesis especially in high-grade slips (Vialle et al. 2007).

Obtaining CT or MRI scans of the spondylolytic area is believed to help in treatment decision making so that lengthy, futile conservative treatment periods could be avoided. Many investigators have observed that that chronic, terminal-stage defects have poorer change of healing with conservative treatment methods (e.g. bracing) than acute lesions. (Leone et al. 2011; Morita et al. 1995; Standaert & Herring 2000; Fujii et al. 2004)

The usefulness of CT scans in children and adolescents with isthmic spondylolisthesis is debated, because it cannot reliably distinguish acute fractures and chronic non-unions in all patients and the radiation hazards are more substantial than in MRI. An MRI scan can accurately differentiate acute, early-stage and chronic, terminal-stage pars defects in isthmic spondylolisthesis. The use of single-photon emission computed tomography (SPECT) is not recommended in children due to its radiation hazards and high false-positive and –negative results. (Leone et al. 2011)

## **Treatment**

The main treatment options for isthmic spondylolisthesis are observation, activity modification, physical therapy with or without bracing and surgery. Substantial amount of patients with isthmic spondylolisthesis become symptomatic after adolescence. (Agabegi & Fischgrund 2010) This thesis concentrates on the treatment of isthmic spondylolisthesis in childhood and adolescence.

## **Conservative Methods**

Asymptomatic low-grade slip can be observed (Agabegi & Fischgrund 2010). Symptomatic low-grade slips should be treated by modification of daily activities and physiotherapy (Österman et al. 1993). Activity modification is mainly restriction from sport activities, especially those in which rigorous flexion, extension and rotation movements of the lumbar spine are performed. Proper lifting techniques and posture are important things to emphasize. Physical therapy consists of hamstring and hip flexor stretching, abdominal strengthening and trunk stabilization. Aerobic conditioning is also recommended. (Agabegi & Fischgrund 2010)

Bracing can be used in addition to physical therapy, if activity modification and physical therapy has not achieved good results or if the pars lesion diagnosed to be acute on an MRI or CT scan (Standaert & Herring 2000; Fujii et al. 2004; Agabegi & Fischgrund 2010). A customary 23 hour per day bracing treatment protocol is continued for 6 six months and after that the brace is gradually omitted during the next six months (Steiner & Micheli 1985).

Analgesic injections to pars or facet joints, selective nerve root blocks and epidural steroid injections can be considered in patients whose symptoms have not relieved by the methods described above and per oral pain medication isn't sufficient. It is recommended to continue conservative methods for at least six months before operative treatment is considered. (Agabegi & Fischgrund 2010)

In low-grade isthmic spondylolisthesis, the results of conservative treatment are usually good. These methods have been found to be effective in 68 - 92 % of cases while 8 - 20 % require surgical treatment due to persisting symptoms. (Pizzutillo & Hummer 1989; Steiner & Micheli 1985; Turner & Bianco 1971; Morita et al. 1995) Best bracing results have been achieved in male patients with acute unilateral spondylolytic defects (Steiner & Micheli 1985; Standaert & S. A. Herring 2000; Fujii et al. 2004). Surgical treatment seems to be rarely required in patients with spondylolysis and mild low-grade isthmic spondylolisthesis (Wiltse & Jackson 1976). Conservative treatment is most effective in early-stage pars lesions while in the terminal-stage lesions the success rate much poorer (Morita et al. 1995; Standaert & Herring 2000; Fujii et al. 2004).

Conservative treatment has not been effective in symptomatic high-grade isthmic spondylolisthesis. In the study by Harris and Weinstein, symptoms were better relieved by surgery (57 %) when compared to bracing (36 %). However, only one high-grade patient out nine suffered from extensive symptoms after conservative treatment. (Harris & Weinstein 1987) Pizzutillo et al. observed only 9 % of symptomatic high-grade patients to respond well to conservative treatment after a long-term follow-up (Pizzutillo & Hummer 1989). In asymptomatic high-grade patients, observation seems to be sufficient if performed carefully, and if symptoms do turn up, surgical treatment is preferred (Agabegi & Fischgrund 2010).

## **Surgical Methods**

Several surgical methods have been devised to treat spondylolysis and isthmic spondylolisthesis. These include the direct repair of the pars defect, posterior and posterolateral spinal fusion in situ, circumferential spinal fusion, reduction and spinal fusion, transsacral interbody fusion and posterolateral instrumented spinal fusion and spondylectomy. The main things to consider, when selecting the operative method, are the severity of slip (low vs. high grade) and spinopelvic balance. (Agabegi & Fischgrund 2010)

### ***Direct Repair***

Direct repair is indicated in patients with spondylolysis that causes low back pain, which does not respond to conservative treatment methods. Concomitant spondylolisthesis should be non-existent or grade I at most. In an optimal patient, radiculopathy or neurologic deficits are not found. (Agabegi & Fischgrund 2010)

Several techniques for direct repair have been introduced. The classical Buck's method was introduced in 1970 and it consisted of posterior decortication and debridement of the pars interarticularis defect and the implantation of iliac crest bone grafts and screw across the defect (Buck 1970). A postoperative cast or brace is used for few months. Successful healing rate has been

observed in 83-93 % with a complication rate of 13 %. (Buck 1970; Pedersen & Hagen 1988) Symptoms have been noted to cease completely in 56 % and partly in 28 % (Pedersen & Hagen 1988).

The Scott's direct repair method was introduced in 1980s and promoted by its easiness in comparison to the Buck method, in which the screw placement can be difficult (Johnson & Thompson 1992). In Scott's technique iliac crest bone grafts are implanted around the spondylolytic defect, and stabilization is achieved by wires that extend from the transverse to spinous process (Nicol & Scott 1986). A postoperative brace is worn for 3 months. Healing rates of 94 % in patients younger than 25 years have been reported with a minor complication rate of 40 %. Significant pain relief has been observed in most of the patients and the results have been termed excellent in 89 %. (Johnson & Thompson 1992). Bradford and Iza and Roca have recently introduced slightly modified versions of Scott's original technique, in which wiring and pedicle screws are combined. In their studies, excellent or good results were found in 87-90 % (Bradford & Iza 1985; Roca et al. 1989).

The newest method for direct repair uses pedicle screws and sublaminar hooks that are interconnected by rods in several different manners. Spondylolysis segment is revealed and debrided and bone grafting of the decorticated bony surfaces is performed. The screw-rod or screw-rod-hook construct is thereafter implanted. (Agabegi & Fischgrund 2010) Postoperative brace is not necessary. Excellent or good results have been gained in 60-81 % and 10-20 %, respectively. Complications have been encountered in 0-20 %. Non-unions have been encountered in 0-10 %. (Kakiuchi 1997; Tokuhashi & Matsuzaki 1996; Gillet & Petit 1999; Fan et al. 2010)

The screw-rod-hook construct and Buck's original screw technique have been found to be most successful in stabilizing the defect in biomechanical studies (Deguchi et al. 1999; Fan et al. 2010) In a comparative, long-term retrospective study by Giudici et al., the modified Scott's technique was deemed superior to the original Scott's technique and Buck's method. Excellent results were obtained in 83 %, 63 % and 29 %, respectively, and complications and/or reoperations were encountered in 11 %, 25 %, 57 % respectively. (Giudici et al. 2011) The groups were somewhat unequal, with an overrepresentation of the modified Scott's technique and the screw-rod-hook was not included. When comparing direct repair to posterolateral spinal fusion, the long-term HRQoL results and the extent of adjacent disc degeneration have been inferior with direct repair (Scott's technique) (Schlenzka et al. 2006).

### ***Posterior or Posterolateral In Situ Spinal Fusion***

Nowadays, posterolateral spinal fusion in situ is the golden standard in low-grade isthmic spondylolisthesis that is resistant to conservative treatment methods or direct repair. The need for instrumentation and decompression laminectomies is debated. (Agabegi & Fischgrund 2010)

Posterior spinal fusion in situ was performed earlier, but it was shown to be unable to control slip progression and have a significant non-union rate (Seitsalo et al. 1992). In this method, only the area around spinous processes is exposed, decorticated and fused (Seitsalo et al. 1991; Österman et al. 1993).

In the posterolateral spinal fusion in situ, the spine is exposed, decorticated and layered with bone grafts from the spinous to the transverse processes and sacral alae. The instrumentation, if used, consists of pedicle screws and/or hooks that are interconnected by two rods. In grade I-II slips, an L5-



S1 fusion has been advocated and in grade III slips it seems beneficial to extend it to L4. Extension to L4 should also be considered in cases of significant L4-L5 instability or degenerative changes or if the L5 transverse processes are considerably small. (Agabegi & Fischgrund 2010)

The clinical outcome is satisfactory in most of the patients (> 80 %) and subjective evaluations by the patients themselves have been positive (in 67-88% patients) after non-instrumented posterolateral spinal fusion in situ for low-grade spondylolisthesis (Frennered et al. 1991; Lenke et al. 1992). Postoperative slip progression occurs in 1-6 % of patients (Pizzutillo et al. 1986; Lenke et al. 1992; Frennered et al. 1991). Non-union is observed in 6-30 % (Lenke et al. 1992; Frennered et al. 1991). HRQoL results in adulthood after a long-term follow-up have been acceptable (Helenius et al. 2008).

The question of, whether instrumentation should be used, is unresolved (Agabegi & Fischgrund 2010). In randomized clinical trials conducted with adult patients, pedicle screw instrumentation did not improve fusion rates or clinical and functional outcomes when compared to non-instrumented fusion after an average follow-up of few years. Instrumented fusion had longer operative times and more blood loss, but postoperative bracing was not necessary. (Thomsen et al. 1997; Möller & Hedlund 2000).

In adolescent patients with radiculopathy and/or neurologic deficits, the use of decompression laminectomies has not been established. Good results have been achieved without laminectomies. Apparently, stabilization of the slipped segment by posterolateral in situ fusion is sufficient in many cases to relief nerve root irritation. (Wiltse & Jackson 1976; Monticelli & Ascani 1975; Pizzutillo et al. 1986) In non-instrumented posterolateral spinal fusion and decompression, the risk of slip progression is increased in children and adolescents. Earlier type of instrumentation has not been shown to improve the situation, but the effects of modern day pedicle screw constructs are unknown (McGuire & Amundson 1993). It nevertheless seems that decompression is rarely indicated in children or adolescents if reduction is not performed.(Agabegi & Fischgrund 2010)

In high-grade spondylolisthesis, posterolateral spinal fusion in situ has yielded nearly comparable results as circumferential fusion. Non-unions have been observed in 0 - 44 % and complications in 13 - 24 %. Postoperative progression occurs in 10 - 26%. Many patients require revision surgeries for symptomatic non-union. (Boxall et al. 1979; Seitsalo et al. 1990; Grzegorzewski & Kumar 2000) Even in the presence of solid union, high-grade spondylolisthesis slip and lumbosacral kyphosis can progress after posterolateral spinal fusion. (Boxall et al. 1979; Seitsalo et al. 1990). Extensive postoperative immobilization in a leg-extension (closed-reduction) cast for several months have been shown to decrease postoperative progression and even lead to reduction in some younger patients (Burkus et al. 1992; Grzegorzewski & Kumar 2000). Deterioration in radiographic parameters after surgery, however, has not correlated with clinical or subjective patient outcomes. Relief of low back pain has been noted in 90 %. In subjective evaluation, patients have reported satisfaction in 89 % of cases, and 88 % have achieved normal functional ability. Clinical outcomes have been better in males. (Boxall et al. 1979; Seitsalo et al. 1990) It should be noted that while long-term results are good, pain, functionality and patient satisfaction in shorter term are better in patients with solid fusion (Seitsalo et al. 1992; Molinari et al. 2002).

### ***Circumferential Spinal Fusion In Situ by Anterior and Posterior Approaches***

Circumferential, anteroposterior spinal fusion in situ is used mainly in symptomatic high-grade spondylolisthesis in childhood and adolescence. High pelvic incidence is thought to cause increased

shear stress to the lumbosacral junction and several investigators have reported significant non-union and slip progression rates after posterolateral spinal fusion in situ. Therefore, more extensive fusion has been recommended to achieve a solid union. (Frennered et al. 1991; Boxall et al. 1979; Burkus et al. 1992; Poussa et al. 1993) Circumferential spinal fusion can be performed by the staged anterior and posterior approaches, by posterior lumbar or transforaminal interbody fusion or by posterior transsacral method (Agabegi & Fischgrund 2010).

In the classic staged circumferential spinal fusion in situ, the anterior approach to the lumbosacral area is transperitoneal. Anterior L5-S1 ligaments and intervertebral discs are resected, bony surfaces are decorticated and bone grafts are implanted. Posterolateral fusion is performed, as mentioned above, with or without instrumentation. Postoperative immobilization in a brace or cast should be used in non-instrumented fusion. (Helenius et al. 2008)

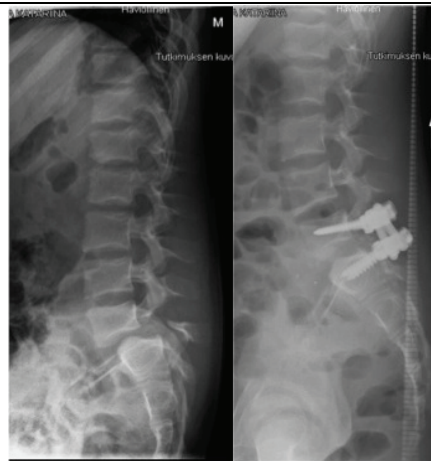
Non-union rate after circumferential spinal fusion without instrumentation has been 0 - 4 %. Slip progression has been noted in 3 - 12 %. Complications have occurred in 4 % and consisted of non-unions requiring revision surgery and transient neurologic deficits. (Lamberg et al. 2007; Frennered et al. 1991). In the comparative, retrospective study by Lamberg et al., high-grade isthmic spondylolisthesis patients operated on by non-instrumented circumferential spinal fusion had better Oswestry and SRS-24 scores after a long-term follow-up than patients operated on by posterolateral spinal fusion (Lamberg et al. 2007). Circumferential non-instrumented spinal fusion provides good long-term HRQoL results in adulthood (Helenius et al. 2008).

Nowadays, it has been common to include instrumentation in circumferential spinal fusion in situ in high-grade spondylolisthesis. Some investigators have found adolescents to poorly tolerate long cast-and brace-treatment associated with non-instrumented fusion (Boachie-Adjei et al. 2002).

### ***Instrumented Reduction and Spinal Fusion***

Patients with high-grade isthmic spondylolisthesis and marked lumbosacral kyphosis can have significant spinopelvic imbalance and difficulties standing upright. Instrumented partial reduction of the spondylolisthesis has been recommended in these cases to restore the balance of the pelvis and trunk.(Agabegi & Fischgrund 2010) Circumferential spinal fusion by staged approaches, posterior lumbar interbody fusion or posterior transsacral interbody fusion is preferred, because posterolateral spinal fusion only can result in high non-union and implant breakage rates(Boos et al. 1993; Molinari et al. 2002; Boxall et al. 1979).

The reduction procedure introduced by Ruf et al. can be performed by posterior only or combined anteroposterior approach (Figure 25). The L4-S1 vertebrae are exposed from the spinous to the transverse processes and sacral alae. After L5-S1 facetectomy, L5 laminectomy and resection of L5-S1 intervertebral disc and end plates, two rods are anchored in place by pedicle screws from L4-S1. The reduction of L5 vertebra is achieved by using distraction between L4 and sacrum and the reduction of lumbosacral kyphosis by using compression via the rods against L5-S1 intervertebral disc spacers. (Ruf et al. 2006)



**Figure 25.** High-grade spondylolisthesis treated with instrumented reduction.

By instrumented reduction, lumbosacral kyphosis averaging 19 - 36° before surgery has been corrected to -8 - 20° at the latest follow-up. Vertebral slips of 74 - 93 % have been corrected to 10 - 57 %. Non-union rate has been 0 - 10 % after a 2-15 years follow-up period. Complications have occurred in 11-33 % and been predominantly neurologic deficits (0 - 21 % transient and 0 - 5 % permanent). Total low back pain relief has been observed in 57 - 87 %. (Ruf et al. 2006; Shufflebarger & Geck 2005; Muschik et al. 1997; Poussa et al. 2006; Molinari et al. 1999)

Only partial reduction of the slip itself should be attempted for, because severe neurologic deficits have been reported in too vicious reduction maneuvers (Bartolozzi et al. 2003; Ruf et al. 2006). The main aim should be to improve lumbosacral kyphosis. Because the incidence of non-union following posterolateral spinal fusion in situ has been associated with more severe lumbosacral kyphosis, it has been proposed that correction of lumbosacral kyphosis would improve the fusion rate in addition to improving spinopelvic alignment. (Boxall et al. 1979; Agabegi & Fischgrund 2010)

The controversy surrounding instrumented reduction still remains. Comparative studies investigating the pros and cons of reduction and circumferential spinal fusion have not found any significant clinical, HRQoL or radiographic results to show that reduction is more beneficial in high-grade isthmic spondylolisthesis than circumferential spinal fusion in situ. (Burkus et al. 1992; Muschik et al. 1997; Molinari et al. 1999; Poussa et al. 2006)

### ***Posterior Lumbar and Transforaminal Interbody Fusion***

Posterior lumbar and transforaminal interbody fusions are techniques for performing circumferential fusion by posterior only approach. In these methods the aim is to debride the spondylolisthesis intervertebral disc space and fill the remaining void with bone grafts and a disc spacer (e.g. a titanium mesh cage). Pedicle screws are used in adjacent segments to give support. In the posterior lumbar method the approach is bilaterally around the spinal cord or cauda equina and in the transforaminal method the approach is unilateral. The supposed advantages of transforaminal approach are the preservation of most of the posterior structures for a better fusion and less complications due to smaller surgical trauma. (Madan & Boeree 2002; Potter 2005)

These methods have been mainly used in adult patients in many different indications in addition to isthmic spondylolisthesis. Their effectiveness in children and adolescents is unknown. (Agabegi & Fischgrund 2010; Madan & Boeree 2002)

### ***Posterior Transsacral Interbody Fusion***

Posterior lumbar or transforaminal interbody fusion can be difficult to achieve in high-grade spondylolisthesis because of the reduced contact between the L5 and S1 vertebrae. Therefore the transsacral approach has been recommended. (Agabegi & Fischgrund 2010) Bohlman and Cook introduced the posterior transsacral interbody fusion by fibular dovel graft in the 1980s. After L5 laminectomy, the upper posterior bony prominence of S1 is resected. The fibular dovel grafts are implanted bilaterally above the S1 nerve roots through S1 into the L5. Finally, a posterolateral spinal fusion from L4 to S1 is performed. (Bohlman & Cook 1982)

Modifications to Bohlman's original concept have been introduced recently. Boachie-Adjei and coworkers performed partial lumbosacral kyphosis reduction by an instrumented transsacral interbody fusion and posterolateral spinal fusion with screws (Boachie-Adjei et al. 2002). Another method reported in adults, has used a transsacral titanium-mesh cage in a similar fashion (Bartolozzi et al. 2003).

The transsacral interbody fusion procedures have yielded good results in relieving low back pain and radiculopathy in most of the patients. The extent of lumbosacral kyphosis can be halved by partial reduction. Low non-union rates of 0 - 14 % have been observed. Significant complications have occurred in 9 - 19 %, being mostly transient neurologic deficits (Boachie-Adjei et al. 2002; Bartolozzi et al. 2003; Smith et al. 2001; Roca et al. 1999).

### ***Spondyloptosis***

The adequate treatment of spondyloptosis is difficult. These patients are usually presented with severe symptoms including low back pain, radiculopathy and neurologic deficits. (Agabegi & Fischgrund 2010) The cosmetic deformity that remains after posterolateral spinal fusion can cause significant subjective disturbance in female patients with spondyloptosis while the functional and symptomatic outcome would be bearable (Seitsalo et al. 1990). Nowadays, the most common treatment methods for the treatment of spondyloptosis are the transsacral interbody fusion (see above) and L5 spondylectomy by the Gaines method. (Agabegi & Fischgrund 2010; Bohlman & Cook 1982; Gaines & Nichols 1985)

In the Gaines method, the L5 spondylectomy is started via an anterior approach. The body and adjacent intervertebral discs are removed. The loose posterior structures of L5 are removed thereafter via a posterior approach. Finally, the L4 is reduced onto the sacrum. (Gaines & Nichols 1985) Some modification to the original technique has been recently proposed, like performing only a partial resection of the L5 (Kalra et al. 2010).

The transsacral interbody fusion does not correct the spinal deformity to significant extent but has a relatively low neurologic complication rate (see above) (Bohlman & Cook 1982; Boachie-Adjei et al. 2002). In the Gaines method, significant amount of postoperative neurologic complications is to be expected. However, postoperative resolution of preoperative cauda equina and neurologic deficits has

been good at one year after surgery and subjective patient satisfaction seems to be excellent regardless of early complications. (Lehmer et al. 1994)

### ***Secondary Scoliosis***

The secondary scoliosis resulting from isthmic spondylolisthesis is apparently lumbar and resolves after the treatment of the spondylolisthesis. Thoracic or thoracolumbar scoliosis curves are usually of idiopathic origin and cannot be corrected by the treatment of spondylolisthesis. Patients with residual lumbar scoliosis after surgical treatment of isthmic spondylolisthesis seem to have more low back pain after a long-term follow-up.(Seitsalo et al. 1988)

## **AIMS OF THE PRESENT STUDY**

The aim of the present study was to evaluate the efficacy of surgical treatment of scoliosis caused by congenital hemivertebra, skeletal dysplasia and neuromuscular disease as well as isthmic spondylolisthesis. The effectiveness of bracing in diastrophic dysplasia was assessed. A special emphasis was placed on evaluating the necessity to perform combined anterior and posterior spinal surgery with the modern day surgical techniques. The clinical, radiographic and quality of life outcomes were evaluated in the following fields:

- I. Hemivertebra resection in congenital scoliosis in young children.
- II. Brace and surgical treatment of scoliosis in patients with diastrophic dysplasia.
- III. Spinal fusion with total pedicle screw and hybrid instrumentation in neuromuscular scoliosis.
- IV. Non-instrumented spinal fusion in situ in isthmic spondylolisthesis before and after pubertal growth spurt.

## MATERIALS AND METHODS

### Patients & Treatment Methods

The patient population of this study consisted of 402 children and adolescents who were treated for scoliosis (n=104) or isthmic spondylolisthesis (n=298). The etiology of scoliosis was congenital hemivertebra in 21 (20 %), diastrophic dysplasia in 17 (16 %) and neuromuscular disease in 66 (64 %). Ninety-eight patients were treated at the Children's Hospital of Helsinki University Central Hospital and the remaining 304 patients were treated at the ORTON Orthopedic Hospital in Helsinki.

### Congenital Scoliosis

#### *Patient Characteristics*

All 21 congenital scoliosis patients (15 males; 6 females) who had consecutively undergone a single-staged combined anteroposterior (n=12; AP) or a posterolateral (n=10; PL) hemivertebra excision at our institution (Children's hospital, Helsinki University Central Hospital) between 2002 and 2009 were included in this study. Single progressive hemivertebra was observed in 12 patients, single progressive hemivertebra with a contralateral bar in 5, two progressive hemivertebrae in 3 and 1 patient (#19) had four hemivertebrae. In all, 27 hemivertebrae were operated on, of which 19 were fully segmented and 8 were semi-segmented. There were 6 thoracic hemivertebrae (T1-T9), 10 in the thoracolumbar region (T10-L2) and 11 in the lumbar region (L3-L6). (Table 7)

#### *Operative Treatment*

The indication for operative treatment was progressive scoliosis, neurological deficits (n=4) and/or back pain (n=2). MRI and CT scans of the spinal column and intrathecal structures were obtained. Renal and cardiovascular systems were investigated for associated anomalies and syndromes. Spinal cord monitoring (MEP, SSEP, lumbar nerve root EMG) was performed during every operation. The surgical approach was selected according to the progression of surgical methods and skills at our institution. The AP method was used in patients operated on earlier, and the PL method in patients operated on more recently.

## Materials and Methods

**Table 7.** Characteristics of the congenital scoliosis patients. VATER=Vertebrae, Anus, Trachea, Esophagus and Renal; VSD=Ventricular septal defect; TOF=Tetralogy of Fallot; ASD= Atrial septal defect

Patient #	Sex	Age at Surgery	Op. Method	Hemivertebra	Bar	Segmentation	Associated anomalies
1	M	2.0	AP	T13		Fully	Sdr Goldenhaar. Hemivertebra T4
3	M	2.6	AP	L5		Fully	Mesenterium's lymphangioma at jejunal region.
6	M	5.1	AP	L2 & L6		Fully	<b>Tethered cord.</b> Sdr Klippel-Feil
10	M	3.0	AP	L6	+	Semi	Sdr. VATER. Lipoma of the filum. 6 lumbar vertebrae
11	M	3.2	AP	T8	+	Semi	Hemivertebra T2 (incarcerated)
12	F	2.0	AP	T9		Fully	VSD
13	M	1.7	AP	T3	+	Fully	Hemivertebrae T6,7,8. Butterfly vertebrae
14	F	2.0	AP	L3	+	Semi	Sdr. VATER. Two uppermost ribs fused
15	M	4.5	AP	L4		Semi	L3 & L6 vertebrae wedged
16	F	3.1	AP	T13		Fully	Operated TOF. Small residual VSD. Fused upper ribs
17	M	4.3	AP	T11		Fully	Hemivertebra T3
18	F	5.3	AP	L4		Semi	<b>Tethered cord.</b> Hemivertebra T6. All lumbosacral vertebrae deformed. Spondylolisthesis L5-L6
1	M	3.2	PL	T4		Fully	Sdr Goldenhaar
2	M	5.5	PL	T12 & L4		Fully	Several other vertebral anomalies
4	M	5.9	PL	L4		Fully	Lipoma of the Filum. Hydromyelia. Several other vertebral anomalies
5	M	8.5	PL	L1		Fully	-
7	F	3.6	PL	L2		Fully	Thickened fatty filum. Paraparesis.
8	M	2.4	PL	T8	+	Semi	VSD. ASD.
9	F	3.5	PL	L2		Fully	<b>Tethered cord</b>
19	M	1.2	PL	L2 & L5		Fully	Hemivertebrae T8 & T10. Butterfly vertebrae T5 & T12
	M	1.9	PL	T8 & T10		Fully	
20	M	11.4	PL	L4		Semi	No lamina in L2. L4 & L5 laminae fused
21	M	2.2	PL	L3		Semi	VSD. 6 lumbar vertebrae

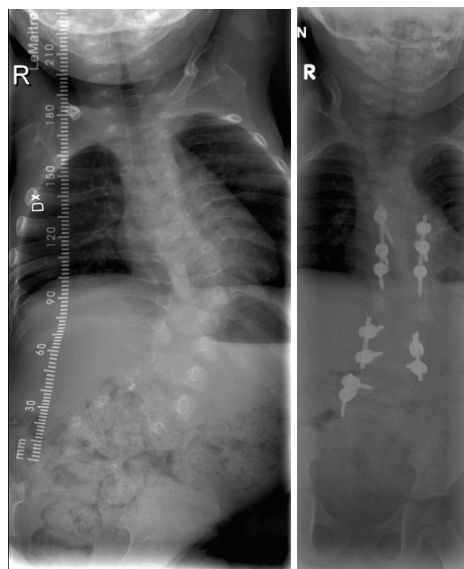
Twelve patients underwent AP hemivertebra excision. The anterior approach consisted of sternotomy for the upper thoracic hemivertebrae (n=1), thoracotomy for the lower thoracic (n=5), lumbotomy for the L1-L5 hemivertebrae (n=6) and transperitoneal for the L6 hemivertebra (n=1). In the anterior approach the patient was laid in lateral decubitus (except for sternotomy). The hemivertebra was first identified and its corpus, pedicle and upper and lower discs were resected. The posterior approach incision was made with the patient still in the same position and then the corresponding hemilamina and processus transversus were excised. Pedicle screws (n=7) or lamina hooks (n=5) were implanted



## Materials and Methods

to the convex side of the upper and lower vertebrae. Deformity correction was obtained by compressing the pedicle screws or the laminar hooks. Local bone from the wedge resection was applied circumferentially to promote fusion.

Ten patients were operated on by the PL approach. Patient # 1 underwent two operations for his two hemivertebrae, first by the AP method and a year after that for the second hemivertebra by the PL method. Patient # 19 had one hemivertebra (L5) on the right side and three hemivertebrae (T8, T10, L2) on the left side, which caused a pre-operative major curve of 87°. He underwent two PL hemivertebra excision procedures, first for L2 and L5 hemivertebrae and 8 months later for T8 and T10 (Figure 26). Patient # 2 underwent a single PL operation for his T12 and L4 hemivertebrae.



**Figure 26.** A one-year old boy with four hemivertebra was treated with several hemivertebra resections.

In the PL approach, patient was lying prone on a four-poster frame. The posterior elements were explored and the hemilamina of the hemivertebra identified. Pedicle screws were inserted into the normal upper and lower vertebrae and their positions were checked with fluoroscopy. The hemilamina and its corresponding facet joints were resected. A safety rod was applied on the concave side and the transverse process was resected. The subperiosteal plane was identified on the lateral pedicle wall. Within this plane the pedicle, hemicorpus and adjacent disc spaces were identified and resected up to the concave side. In the thoracic spine a costotransversectomy was required to obtain sufficient view to enable work under the spinal cord. Manipulation of the medullae was limited to a minimum. The posterior vertebral body wall was finally displaced anteriorly with appropriate width and impactor. Correction was obtained by compressing the pedicle screws on the convex side. Autogenous bone grafts from the wedge resection were applied circumferentially.

All patients were mobilized within the first postoperative week. For 8 patients, postoperative treatment included a spica cast for 6 to 8 weeks followed by a further 4 months of bracing after that. Twelve patients only wore a brace for 4 to 6 months, and one patient wore a halo-vest for three months postoperatively. Patient # 15's, 17's and 18's instrumentation were removed two years after

the index surgery, because the corrected area had fused sufficiently and at that time it was believed that if the pedicle screws were left intact, it would result in spinal stenosis in later life.

### **Diastrophic Dysplasia**

#### *Patient Characteristics*

We identified all patients with diastrophic dysplasia and scoliosis who had undergone bracing or surgical treatment with a minimum of two years follow-up at our institutions. The patients were diagnosed with diastrophic dysplasia by a clinical geneticist.

In all, 18 patients had undergone bracing and/or surgical treatment between 1960 and 2005. Fifteen of them had an idiopathic-like type of scoliosis and two had early-progressive according to the classification introduced by Remes et al. (Remes, Poussa, et al. 2001a). Eight patients had undergone a formal brace treatment and of these patients three had progressed to surgical treatment and one was on a waiting list. A total of 13 patients were operated on. One patient had undergone surgery for lumbar spinal stenosis only and was therefore excluded. The remaining 17 (2 early-progressive, 15 idiopathic-like; 8 braced, 12 surgically treated) patients were contacted and invited to participate in this study. All except two patients accepted this invitation. For patient # 7 the reason for refusing to participate was lack of interest. Radiographic follow-up was available up to 10 years postoperatively also on that patient. Patient # 17 did not take part in the clinical examination at final follow-up because of difficulties in mobilization and excessive travelling distance. However, she filled up the questionnaires and had a radiographic follow-up of five years. Eleven patients had been treated at the Children's Hospital of Helsinki University Central Hospital while six patients had been treated at the ORTON Orthopaedic Hospital in Helsinki.

#### *Brace Treatment*

Seven patients were braced with a custom-made Boston (thoracolumbosacral) and one with Milwaukee (cervicothoracolumbosacral) brace. The indication for brace treatment was a progressive spinal deformity of 25° or more in a growing child. Radiographs were obtained before and immediately after the beginning of brace treatment and thereafter at six months intervals up to two years and thereafter at one-year periods until cessation of brace treatment.

#### *Operative Treatment*

The operations were performed by four senior orthopaedic surgeons. Five patients underwent posterior surgery: one without instrumentation, two with Harrington rods, one with Cotrel-Dubousset (all hooks) and one with Colorado instrumentation (hooks and pedicle screws). The patient without instrumentation used a Milwaukee brace for one year postoperatively. Patients with Harrington distraction rods wore a Milwaukee brace for six months and the patients with CD or Colorado instrumentation were mobilized on the 3<sup>rd</sup> postoperative day. One patient (#16) underwent posterior

decancellation osteotomy of the fifth thoracic vertebra and a partial correction of the kyphoscoliosis due to preoperative paraparetic symptoms.

One patient (#6), a 20-year old female, had an anterior instrumented fusion. She underwent left thoracoabdominal approach, anterior discectomies, anterior spinal fusion with an autologous rib graft, and an anterior Zielke instrumentation (Th11-L3). Postoperatively, she was immobilized in a Boston brace.

Six patients underwent instrumented anteroposterior spinal fusion. Anterior approach consisted of a thoracotomy (thoracoscopic for one patient) for midthoracic curves and thoracolumbotomy for the lower ones. Anterior discectomies of the apex of the curve were performed. Autologous bone grafting from one harvested rib was utilised for the anterior spinal fusion. Two patients had CD instrumentation (all hooks), two had hybrid constructs (upper thoracic area claw with hooks, apical wires and pedicle screws at distal level) and one patient had a CD-Horizon construct with hooks and pedicle screws. None of these patients had postoperative immobilization. One early progressive scoliosis type patient (#7) underwent spinal deformity correction with subcutaneous Harrington rods at the age of four years. She underwent final spinal fusion at the age of eight by the anteroposterior method using Harrington instrumentation.

## Neuromuscular Scoliosis

### *Patient Characteristics*

We identified all patients who had undergone surgical correction for neuromuscular scoliosis with a TPS-instrumentation and a minimum of two-year follow-up at our institution. A total of 37 consecutive patients who were operated on between 2006-2009 met this criteria. For each of these patients, we selected a control patient who had undergone surgical correction of neuromuscular scoliosis with hybrid instrumentation. Since a total of 33 consecutive patients were operated on using a hybrid construct during similar time period (2003-2006), we were not able to match four patients (four males) operated on by TPS instrumentation. Therefore, our study population (n=66) consisted of two groups of 33 patients, who were best matched for age at surgery ( $\pm 1$  year), gender, curve size ( $\pm 10$  degrees), and basic underlying neuromuscular condition (spastic/flaccid, ambulatory status). (Table 8)

### *Operative Treatment*

The indication for scoliosis surgery was a progressive neuromuscular scoliosis  $\geq 50^\circ$  with poor sitting or standing balance except in patients with Duchenne muscular dystrophy, in whom  $\geq 25^\circ$  major curve was regarded as an indication for surgery. Pelvic fixation was performed when L5 tilt over S1 endplate exceeded  $10^\circ$ .

Anteroposterior surgery was performed in the hybrid instrumentation group when the curve magnitude exceeded  $70^\circ$  or in the immature patient to prevent crankshaft. Anteroposterior surgery in the pedicle screw instrumentation group was performed in extreme curves of  $100^\circ$  or more and in

---

none for the prevention of crankshaft phenomenon. Anteroposterior surgery was performed in 13 (39%) patients of the hybrid group (nine of them staged surgeries) and in four (12%) of the TPS group ( $p=0.011$ ).

The anterior approach consisted of a thoracotomy for the lower thoracic spine and of a thoracolumbotomy for the T12-L2 area. The patient was laid in a lateral decubitus position. Segmental vessels in the anterior fusion area were ligated unilaterally to allow wide and safe exposure of the spine including anterior longitudinal ligament. Multilevel discectomies were performed to release of the rigid spinal deformity. Anterior spinal fusion was promoted by autologous rib grafting of the disc spaces. In the posterior approach, the patient was turned prone and posterior elements of the spine were exposed carefully with electrocautery. Nine (27%) patients in the hybrid and twenty-one (64%) patients in the pedicle screw group underwent apical Smith-Petersen osteotomies (Ponte procedure) ( $p=0.003$ ). All patients received morsellized allogenic bone grafting when iliac fixation was performed.

Hybrid construct included an upper thoracic hook claw on both sides, sublaminar wires on the concave side and mid-thoracic hooks on the convex thoracic spine as well as lumbar pedicle screws. Iliac fixation ( $n=10$ ) was performed with long iliac screws and connectors.

Pedicle screws were inserted with the free hand technique according to Kim et al. (Kim et al. 2004). Multi-axial reduction screws were used at the apical concave side. Iliac fixation ( $n=21$ ) was performed with long iliac screws and connectors. Epidural bleeding was controlled using bipolar cauterization and hemostatic agents such as human thrombin with gelatine. Spinal deformity correction was obtained by the double rod cantilever maneuver or by concave rod derotation.

Spinal cord monitoring (MEP, SSEP, lumbar nerve root EMG) was performed in all of the operations. All patients were carefully followed up at the pediatric intensive care unit with a mean arterial pressure of 70 mmHg or more during the first 24 hours. Lower leg movement was checked every four hours. All patients were mobilized within the first post-operative week.

## Materials and Methods

**Table 8.** The characteristics of the neuromuscular scoliosis study population. Values are mean (SD = standard deviation) or patient number (percentage). CP = cerebral palsy MMC = myelomeningocele.

Characteristic	TPS	Hybrid	P
<b>Patients</b>	33	33	NS
<b>Gender (Male/Female)</b>	15 / 18	15 / 18	NS
<b>Age at Surgery (years)</b>	14.7 (SD 2.5)	15.8 (SD 3.0)	NS
<b>Follow-up time (years)</b>	2.8 (SD 0.3)	2.8 (SD 1.2)	NS
<b>Main Curve</b>	81° (SD 18°)	87° (SD 29°)	NS
<b>Neuromuscular disease</b>			
CP	17 (52 %)	14 (42 %)	NS
Spastic/dystonic tetraplegic	15 (45 %)	11 (33 %)	NS
Diplegic	2 (6 %)	2 (6 %)	NS
Hemiplegic	0	1 (3 %)	NS
MMC	3 (9 %)	1 (3 %)	NS
Spinal cord injury	0	1 (3 %)	NS
Syndromic	7 (21 %)	10 (30 %)	NS
Polyneuropathy	3 (9 %)	3 (9 %)	NS
Duchenne	3 (9 %)	4 (12 %)	NS
<b>Neuromuscular condition</b>			
Spastic	15 (45 %)	15 (45 %)	NS
Flaccid	18 (55 %)	18 (55 %)	NS
Non-ambulatory	25 (76 %)	24 (73 %)	NS

## Isthmic Spondylolisthesis

### *Patient Characteristics*

Between 1977 and 1991, 351 consecutive patients with isthmic spondylolisthesis (72 % low-grade, 28 % high-grade) under the age of 20 years were operated on at our institution (ORTON Orthopaedic Hospital). Two patients had deceased for reasons unrelated to surgery. Of the remaining 349 patients, 298 (85 %) agreed to participate in the spondylolisthesis study. Reasons for refusing to participate

---

(n=51) were: lack of interest (n=20; 39 %); excessive travelling distances (9; 18 %); pregnancy, recent delivery or difficulties with childcare (3; 6%); unknown address or abroad (11; 22%); business commitments (4; 8%); other disease (4; 8%). The clinical and radiographic results of the whole study population have been partially published previously (Helenius et al. 2005; Helenius et al. 2006; Remes et al. 2006; Poussa et al. 1993).

We aimed to assess the effect of pubertal growth spurt on the outcomes of surgical treatment of isthmic spondylolisthesis. The period of rapid growth in puberty begins in Finnish girls and boys on average at the age of 12 and 14 years, respectively (Sorva et al. 1990). Therefore, the threshold between children and adolescents was selected to be twelve (<12.5) years for females and fourteen (<14.5) years for males in this study. Fifty-five (18%) patients of the study group (n=298) were children. To further scrutinize the results and evaluate the effects of age and growth as reliably as possible, we formed two matched cohorts. For every child (females  $\leq 12$  yrs; males  $\leq 14$  yrs at the time of surgery; n=55) an adolescent control patient (females >12 yrs; males > 14 yrs), who best matched for gender, operative method, severity of slip and age at the time of final follow-up was selected from the rest of the original study population (n=243). Age at final follow-up was chosen as one criterion to discard the effect of age related spinal degeneration for back pain, spinal mobility and trunk strength. Fourteen children could not be matched and they had to be excluded (Table 9). In the end, our study population (n=82) consisted of two matched cohorts of 41 patients.

### ***Operative Treatment***

There were 22 (54 %) patients with low-grade and 19 (46 %) patients with high-grade slips in both of the matched cohort groups (children and adolescents). Low-grade spondylolisthesis patients (n=44) were treated with non-instrumented posterior (n=11) or posterolateral fusion in situ (n=29) or direct repair (n=4). In patients with high-grade spondylolisthesis (n=38) the selection between three operative techniques represents an evolution in the operative strategy at the institution. Posterolateral fusions were performed at an earlier time period and anterior spine surgery was introduced later. Thereafter, non-instrumented anterior and circumferential in situ fusions and instrumented reductions were performed depending on the preference of the operating surgeon. Decompressions were performed primarily in 7 patients (3 children and 4 adolescents; all high grade). The details of the operative techniques are described in the review of literature of this thesis. Pedicle screw construct was used in reduction procedures.

**Table 9.** Preoperative data of the children excluded from the matched cohorts. SRS 24 = Scoliosis Research Society 24 -questionnaire; VAS = Visual analog score; ODI = Oswestry Disability Index.

Characteristic	Excluded patients
<b>Patients</b>	14
<b>Gender (Males / Females)</b>	5 (36 %) / 8 (64 %)
<b>Age at surgery (years)</b>	12.1 (6.9 -14.3)
<b>Follow-up time (years)</b>	16.2 (10.8 - 23,6)
<b>Age at follow-up (years)</b>	28.3 (20.9 – 37.2)
<b>Severity of slip</b>	
Low Grade (< 50 % slip)	6 (43 %)
High Grade ( $\geq$ 50 % slip)	8 (57 %)
<b>Preoperative vertebral slip</b>	45 % (10 - 100 %)
<b>Preoperative lumbosacral kyphosis</b>	-2.1° (-42 – 18°)
<b>SRS 24 total score</b>	98.6 (87 – 112)
<b>ODI</b>	4.4 % (0 % - 12 %)
<b>VAS</b>	
Low Back Pain	10.5 (0 – 33)
<b>Operative methods</b>	
Direct Repair	3 (21 %)
Posterior/Posterolateral	5 (36 %)
Anterior	4 (29 %)
Circumferential	1 (7 %)
Reduction	1 (7 %)
<b>Reasons for exclusion</b>	
No control with similar age at FFU	5 (36 %)
No control with similar slip (LG or HG)	2 (14 %)
No control with similar operative method	3 (21 %)
No sufficient preoperative data	3 (21 %)
L4 olisthesis & therefore no control	1 (7 %)

### Study design

The study design was a clinical retrospective cohort study. In congenital scoliosis patients, two non-matched groups of patients treated consecutively by different operative methods (AP or PL) were compared. In diastrophic dysplasia, the effects of bracing and operative treatment were evaluated in one cohort of patients (5 patients with brace, 3 patients with brace and surgery and 9 patients with surgery alone). In neuromuscular scoliosis, two matched groups of patients operated on with different instrumentations (TPS or hybrid) were compared. In isthmic spondylolisthesis, two matched groups of patients operated on at different ages (before or after the age at which growth spurt typically begins) were compared. The outcomes of the matched groups were evaluated after the match up was made.

An independent observer (the author) evaluated pre- and postoperative clinical medical records and HRQoL-questionnaires (Scoliosis Research Society 24, Oswestry Disability Index), and two independent observers (the author included) evaluated radiographs, all of which were obtained as a part of normal follow-up protocol. Diastrophic dysplasia and isthmic spondylolisthesis patients were invited to take part in additional long-term final follow-up examinations, which consisted of a clinical examination by an orthopaedic surgeon, radiographs of the spine, HRQoL questionnaires and functional tests.

The treatment was given in congenital scoliosis between 2002 – 2009, in diastrophic dysplasia between 1960 - 2005, in neuromuscular scoliosis between 2003 – 2009 and in isthmic spondylolisthesis between 1977 – 1991. The additional final follow-up examinations were conducted in diastrophic dysplasia in between 2007 – 2008 and in isthmic spondylolisthesis in between 2002 – 2004. The results were evaluated by the author and coworkers between 2007 - 2012.

### Clinical evaluation

Medical records were available of each patient from the time of diagnosis to the present. The patients underwent a systematic physical examination of the spine before and after surgery and at the follow-up visit by an orthopaedic surgeon. The examination included a complete neurological testing of the lower extremities, straight leg raising test and evaluation of ambulatory status, hip and knee flexion contractures and sitting and standing spinal balance. All symptoms were recorded.

In spondylolisthesis patients, spinal mobility and non-dynamometric trunk performance tests were performed at FFU. Spinal mobility was determined by measuring lumbar flexion and extension in degrees with a goniometer. Trunk side-bending was measured with a tape measure from the fingertips on the thigh to the knee joint in centimetres.(Alaranta et al. 1994) Non-dynamometric trunk strength was evaluated by repetitive sit-up, arch-up, and squatting tests. The trunk strength results were scored from 1 (poor;  $-1$  SD) to 5 (excellent;  $+1$  SD).(Alaranta et al. 1994)



## **Radiographic evaluation**

Standard standing posteroanterior and lateral radiographs of the whole spine were obtained in scoliosis patients. In patients with spondylolisthesis, posteroanterior and lateral standing radiographs of the thoracolumbar and lumbar spine were obtained. These radiographs were taken immediately before and after surgery and at the final follow-up visit.

### ***Scoliosis***

All of the scoliosis curves (main, proximal thoracic, mid-thoracic, thoracolumbar, lumbar), thoracic kyphosis, lumbar lordosis and coronal and sagittal balances were measured according to the methods described in the Spine, Radiography section. The status of the instrumentation was also evaluated (in place and stable, loose or removed). (O'Brien et al. 2004)

### ***Congenital Scoliosis Patients***

Standard preoperative imaging and testing included MRI and CT scans of the spinal column and intrathecal structures. From the posteroanterior radiograph, the distance from the pedicle one segment above the hemivertebra to the pedicle one segment below was measured in millimetres in the concave and convex sides of the scoliosis. The shortening of the spinal column (mm), which resulted from the hemivertebra resection, was measured as the difference between the pre- and postoperative distances (mm). (O'Brien et al. 2004)

### ***Diastrophic Dysplasia Patients***

The scoliosis curve patterns were classified preoperatively into early-progressive, idiopathic-like and mild, non-progressive according to the classification introduced by Remes et al. (Remes et al. 2001). Cervical kyphosis was evaluated preoperatively by obtaining lateral radiographs of the cervical spine. MRI scans were obtained to evaluate cervical myelopathy.

### ***Neuromuscular Scoliosis Patients***

Pelvic obliquity was measured according to the technique as described in the section of this dissertation entitled Spine, Radiography. Traction radiographs were obtained preoperatively to assess the rigidity of the main scoliosis curve. More rigid scoliosis curves had less main curve correction in the traction radiographs when compared with curves that were less rigid. The proximal junctional kyphosis was evaluated at final follow-up. (O'Brien et al. 2004) The proximal junctional kyphosis was measured from the caudal endplate of the upper instrumented vertebra to the cephalad endplate of the vertebra adjacent to the upper instrumented vertebra. A kyphosis of 15° was regarded to be abnormal. (Helgeson et al. 2010)

### *Isthmic Spondylolisthesis Patients*

Vertebral slip, lumbosacral kyphosis (sagittal rotational angle), lumbar lordosis (L1-L5) and disc height reduction were measured (Laurent & Einola 1961; Wiltse & Winter 1983). Spondylolistheses were divided radiographically into low-grade (< 50 % slip) and high-grade ( $\geq$  50 % slip). The S1-L3 horizontal distance was measured to evaluate spinal balance, because standard sagittal balance measurements were not available due to short radiographs. Disc height above the fusion area was assessed according to Saraste et al. as a semi-quantitative comparison of the disc height at the operated level to the disc at L2-3, which was considered to be normal (Saraste et al. 1984). Lateral flexion-extension radiographs of the lumbar spine were obtained to assess radiographic union of the fusion area. More than three degrees of angular motion in the fusion area in the flexion-extension radiograph was considered to represent a non-union.

### **Health-related-quality-of- life Questionnaires**

Patients or their closest relatives (if the patient was not capable due to young age or mental retardation) were asked to fill in the Finnish versions of Scoliosis Research Society 24 (SRS-24) and Oswestry Disability Index (ODI) questionnaires at final follow-up (Haher et al. 1999; Fairbank et al. 1980). The SRS-24 questionnaire was used in all patients of this study. ODI was used in adult patients with diastrophic dysplasia and isthmic spondylolisthesis. In isthmic spondylolisthesis, patients were also asked to evaluate separately their low back pain and radiating pain to lower extremities by using visual analogue scale (VAS). The answers were verified during the physical examination.

The SRS-24 –questionnaire was developed for AIS and contains 24 questions, which give a maximum score of 120, meaning a highly satisfied and asymptomatic patient (Haher et al. 1999). The SRS-24 scores are further divided into seven domains (pain, general self-image, post-operative self-image, general function, overall level of activity, postoperative function, satisfaction). The Finnish version of SRS-24 has been developed by direct translation of the English version. It has not been validated to the same extent as the English version, but due to the simplicity of the questions, the direct Finnish translation of this questionnaire has been found to be useful in several studies on AIS so far (Helenius et al. 2002; Helenius et al. 2008). SRS-24 has not been validated in spondylolisthesis, scoliosis related to skeletal dysplasia, congenital and neuromuscular disease. In spondylolisthesis, the Finnish version of SRS-24 has been used in several earlier studies (Helenius et al. 2006; Helenius et al. 2005; Helenius et al. 2008b). SRS-24 was used in this study in diastrophic dysplasia, neuromuscular scoliosis and congenital scoliosis to evaluate its usefulness in these types of spinal deformity. The results on these fields should therefore be interpreted with caution. The median Finnish SRS-24 total score in AIS has been reported to be 102 (range 63 – 118) (Helenius et al. 2008).

The ODI evaluates subjective back disability. The ODI questionnaire produces a score ranging 0 - 100 %. The scores can be grouped into different degrees of disability: minimal disability (0 - 20 %), moderate disability (20 – 40 %), severe disability (40 – 60 %), crippled (60 – 80 %) and bed-bound or exaggeration of disability (80 – 100 %). (Fairbank et al. 1980)

### **Statistical Methods**

Median (range) values were used in studies I and II due to small cohorts, because they had an asymmetrical data distribution. Mean (standard deviation) values were used in studies III and IV which had bigger cohorts and normally distributed data. In the study IV, median (range) values were used in the sub-group analysis of low-grade children who did not have preoperative pain due to small patient amount. Statistical comparisons for quantitative non-continuous data were performed by the Mann-Whitney U-test and by the Wilcoxon signed rank test for the matched cohorts. A two-tailed independent T test was used to calculate the level of significance for continuous variables.  $\chi^2$ - test or Fisher's exact test were used in categorical data depending on the cell frequency. P values equal to or below 0.05 were considered statistically significant.

### **Ethical Considerations**

The authors obtained permission to perform this study from the Ethics Committee of the hospital where the study was conducted (162/13/03/03/2008; 151/E7/2007 15.5.2007 [project code T140S23]; 362/E6/2001). All patients taking part in the additional long-term final follow-up examinations in diastrophic dysplasia and isthmia spondylolisthesis gave a written informed consent.

### **Financial Support**

This study was supported by the Finnish Paediatric Research Foundation, Rinnekoti Research Foundation, Research Foundation of Orthopaedics and Traumatology, EVO (Helsinki University Central Hospital, ORTON Orthopaedic Hospital & ORTON Foundation, Turku University Central Hospital), Medtronic and Baxter. The Funds from Industry were used to cover the salary of a part-time research nurse and author's travel expenses to international scientific congresses (SRS 43<sup>rd</sup> Annual Meeting, Salt Lake City, Utah, 2008; 17<sup>th</sup> International Meeting on Advanced Spine Techniques, Toronto, Canada 2010). None of the study funders played a role in writing or other editorial work for this dissertation or the articles and presentations related to this dissertation.

## RESULTS

### **Surgical Treatment of Congenital Scoliosis by Hemivertebra Resection**

#### **Operative Results**

Hemivertebra excision was conducted in ten patients by the PL approach and in twelve patients by the AP approach. The median age at the time of hemivertebra resection was 3.5 years (range, 1.7 - 5.3 years) and 3.1 years (range, 1.2 - 11.4 years), respectively (p=NS). The median follow-up time after surgery was 1.9 years (2.0 - 7.0 years) in the PL group and 2.4 years (1 - 2.5 years) in the AP group (p=0.002).

The median intraoperative blood loss was 400 mL (90-1000 mL) in the PL group and 260 mL (35-650 mL) in the AP (p=NS). The operative times were hours 3.8 hours (2.3 - 5.5) and 4.3 hours (2.5 - 7.8) respectively (NS). The hospitalization time was 12 days (8-16 days) and there were no significant differences between the surgical groups. The time spent in the intensive care unit after surgery was on median 1.9 (1-5) days in the PL group and 1.3 (1- 3) days in the AP group (p=NS).

#### **Radiological Outcomes**

The median preoperative main curve was 39° (26 - 87°) in the PL-group and 30° (25 - 49°) in the AP-group (p=0.037). The median main curve corrections were 64 % (33 - 81 %) in the PL-group and 76 % (44 - 93 %) in the AP postoperatively, and 62 % (18 - 93 %) and 63 % (27 - 92 %) at the final follow-up, respectively (p=NS). Only three patients (hypokyphosis in one patient in the AP and in two patients in the PL group) had radiologically abnormal thoracic kyphosis preoperatively, but at the final follow-up visit all patients ended up with normal kyphosis. Hyperlordosis was found in one patient (65° in the AP-group) preoperatively but in none post-operatively. Radiographic spinal fusion was evident in all patients at the final follow-up. (Table 10)

## Results

**Table 10.** Radiographic results. Values are median (range). NS = Non-significant, FFU = Final follow-up.

	Anteroposterior	Posterolateral	P
<b>Patients</b>	12	10	
<b>Age at surgery (years)</b>	3.1 (1.7-5.3)	3.5 (1.2-11.4)	NS
<b>Follow-up time (years)</b>	2.4 (2.0-7.0)	1.9 (1.0-2.5)	NS
<b>Main Curve (°)</b>			
Pre-Op	30.0 (25-49)	39.0 (26-87)	0.037
FFU	12.0 (2-27)	17.0 (2-27)	NS
<b>Kyphosis (°)</b>			
Pre-Op	29.0 (8-36)	31.0 (8-48)	NS
FFU	32.0 (21-41)	26.0 (22-36)	NS
<b>Lordosis (°)</b>			
Pre-Op	38.0 (13 - 65)	36.0 (16 - 47)	NS
FFU	43.0 (27 - 65)	35.0 (22 - 56)	NS
<b>Coronal balance (mm)</b>			
Pre-Op	10.0 (2-30)	17.5 (1-30)	NS
FFU	9.9 (0-38)	13.0 (0-37)	NS
<b>Complications</b>			
	Superficial wound infection (# 11)	Intrapleural effusion & superficial wound infection (# 2)	
	Minor arterial lesion during central venous catheter insertion (# 15)	Hemothorax (# 19)	
		L3 radiculopathy (# 20)	
		Urinary retention (# 21)	

---

### Clinical Outcomes

Four patients (# 2, 7, 9 in the PL & # 6 in the AP group) had neurological symptoms before surgery. Patient # 2 had mild unilateral quadriceps weakness. Patient # 7 had pain and tiredness in her lower extremities and urinary incontinence. After surgery both patients have been symptomless. Patients # 6 and 9 had symptomatic tethered cords, which were not untethered before hemivertebra excision. Patient #6 had preoperative lower extremity tiredness and calf muscle tightness, and these symptoms disappeared shortly after surgery. Patient #9 had right leg L5 radiculopathy. Postoperatively her radiculopathy resolved within 9 months from surgery, but one year after surgery the symptom reappeared. The symptom has persisted to this day, but resolves with mild pain medication.

In patients with tethered cord, hemivertebra resection resulted in 25 and 20 mm shortenings in the convexity and concavity of the vertebral column in patient #6 and in 15 and 1 mm shortenings, respectively, in patient #9.

### Health-related-quality-of-life

The median total SRS-24 score in the whole group was 103 (85-109) at the final follow-up ( $p=0.002$ ). In the PL- and AP-groups, the median total scores were 102 (range, 85-106) and 104 (range, 89-101) at final follow-up, respectively ( $p=NS$ ). The results in the seven main domains of the SRS-24-questionnaire were similar in both groups.

### Complications

The overall complication rates were 40 % (4/10) in the PL-group and 17 % (2/12) in the AP-group ( $p=NS$ ). After PL hemivertebra excision, there was one patient with intrapleural effusion and superficial wound infection, one with hemothorax, one patient with temporary L3 radiculopathy (#20), which included numbness of the right thigh and atrophy of the right quadriceps muscle, and one with temporary urinary retention (# 21). The intrapleural effusion and hemothorax resolved uneventfully with drains, and the superficial wound infection with antibiotics. The L3 nerve root irritation has resolved spontaneously, and the patient is currently fully relieved of his symptoms. Patient # 21 needed intermittent urinary catheterization for six months postoperatively and antibiotics for several urinary tract infections, but nowadays his bladder function has normalized and he is asymptomatic.

After AP surgery, there was one superficial wound infection (# 11) in the anterior exposure wound and one minor arterial lesion (# 15) occurred during the insertion of a central venous catheter. The anterior wound infection resolved with intravenous antibiotics without sequelae and the arterial puncture with compression. No serious or permanent neurological complications occurred in either of the groups. No implant failures were observed.

## Treatment of Scoliosis in Diastrophic Dysplasia

### Brace treatment

Eight patients were braced. Two patients had an early progressive and six patients had an idiopathic-like scoliosis. Before bracing, the median Cobb angle of the major curve was 38 (range, 25-80)<sup>o</sup> (Table 11). The age at the beginning of bracing was 6.9 (0.9 – 13) years. The median percentage correction in the brace was 6 (-31 - 28) %. The bracing time lasted a median of 3.2 (1.0 - 5.6) years, and the major curve progressed (> 10 °) during bracing in 5/8 patients. The median major curve progression after bracing was 25 (-43 – 53) %.

Three of these eight patients progressed to surgery, and one is on a waiting list. Two of these patients were operated on immediately after bracing and one patient (#17) was operated on one year after the cessation of brace treatment. Follow-up time after bracing was 12 (6.6 – 44) years. The median progression of the major curve was 75 (25 – 127) % during the whole follow-up period. In the five braced patients, who were not operated on, the total SRS-24 questionnaire total score was 90 (79–103) and the ODI was 30 (2–40) % at the final follow-up visit. The median visual analogue score for low back pain was 14 (0–47) mm.

**Table 11.** Brace treatment results. Time is represented in years and main curve in degrees. MT = Main thoracic. L = Lumbar. EP = Early Progressive. I = Idiopathic-like

#	Age at the Beginning of Brace Treatment	Bracing Time	Follow-up time	Curve type	Brace type	Main Curve					Surgery
						Apex	Pre-Bracing	In Brace	Post-Bracing	Final Follow-up	
1	2.8	3.6	20.3	EP	Boston Low	MT	61	80 (-37 %)	85 (-39 %)	85 (-39 %)	Yes
3	12.7	2.7	23.3	I	Boston Low	MT	44	40 (9 %)	46 (-5 %)	88 (-100 %)	No
7	1.4	3.3	12.8	EP	Boston High	MT	80	70 (13 %)	100 (-25 %)	100 (-25 %)	Yes
9	11.4	2.0	9.8	I	Milwaukee	L	30	30 (0 %)	38 (-27 %)	50 (-67 %)	No
10	12.0	3.0	44.3	I	Boston High	MT	51	59 (-16 %)	64 (-25 %)	91 (-78 %)	No
11	6.4	1.0	10.2	I	Boston High	MT	30	29 (3 %)	17 (43 %)	68 (-127 %)	Waiting
13	0.9	4.0	8.6	I	Boston High	MT	25	18 (28 %)	17 (32 %)	43 (-72 %)	No
17	7.3	5.6	6.6	I	Boston High	MT	32	25 (22 %)	49 (-53 %)	59 (-84 %)	Yes
<b>Median</b>	<b>6.9</b>	<b>3.2</b>	<b>12</b>				<b>38</b>	<b>35</b>	<b>48</b>	<b>77</b>	
Range	0.9 – 13	1.0 – 5.6	6.6 – 44				25 - 80	18 – 80	17 - 100	43 – 100	

## Operative Treatment

### Operative Data

Five patients underwent posterior spinal fusion with instrumentation in four patients. Six patients underwent instrumented anteroposterior spinal fusion. One patient was operated on by anterior spinal fusion with the Zielke instrumentation. The median age at surgery was 13.4 (6.5 – 20) years and follow-up time 14 (2.1-37.2) years.

### Radiologic Outcomes

Eight major curves were located in the mid-thoracic area and four in the lumbar area. The median Cobb angle of the major curve was 69 (53 – 100) ° preoperatively (Table 12). At final follow-up, a median correction of 25 (-6.0 – 76) % was obtained. Standing sagittal balance was positive ( $\geq 30$  mm) in 6 patients preoperatively and in 7 patients at final follow-up visit. The reason for sagittal imbalance was regarded to be a severe bilateral flexion contracture of the hip joints (mean flexion contracture 30 [10-90]°).

The median major curve correction was 15 (-6 – 31) % in the posterior and 32 (13 – 76) % in the anteroposterior group at the final follow-up visit ( $p=0.017$ ). There was no statistically significant differences in the thoracic kyphosis, lumbar lordosis or spinal balance in the coronal or sagittal planes between the groups before or after surgery (Table 12).

**Table 12.** Radiologic outcomes in surgical treatment of diastrophic dysplasia. Values are median (range).

	Preoperative	Postoperative	Final follow-up
<b>Major curve (°)</b>	69 (53 – 100)	40 (17 – 76)	49 (20 – 78)
<b>Thoracic kyphosis (°)</b>	52 (8 – 96)	51 (13 – 70)	70 (20 – 105)
<b>Lumbar lordosis (°)</b>	55 (40 – 85)	43 (33 – 83)	65 (22 – 97)
<b>Coronal balance (mm)</b>	15 (1 – 85)	11 (2 – 64)	16 (1 – 78)
<b>Sagittal balance (mm)</b>	48 (26 – 144)	28 (12 – 109)	80 (24 – 179)



---

### Clinical Outcomes

Ten out of twelve patients were fully ambulatory before the surgery. Patient # 16 had a walking ability of short distance before her surgery. Patient #1 was pre-operatively unable to walk because of difficult hip joint problems (severe degeneration and flexion contracture). Post-operatively three patients were in wheelchair (# 1, 7, 16). Patient #16 developed a total paraplegia after her deformity correction (see Complications). Patient #7's walking ability started to deteriorate during the first year after her index surgery with a subcutaneous Harrington rod instrumentation. During that year she underwent multiple revisions of the subcutaneous distraction rod.

### Health-related-quality-of-life Outcomes

The median total SRS-24 questionnaire score was 91 (68 – 114) and ODI was 20 (0 – 60) % at the final follow-up visit. The SRS median total scores were 96 (86 - 98) in the anteroposterior group and 83 (68–98) in the posterior group (p=NS). Similarly, the ODI was 11 (0–14) % in the anteroposterior and 30 (20–60) % in the posterior group (p=0.025). The median visual analogue score for low back pain was 3 (0-6) mm in the anteroposterior and 22 (0-76) mm in the posterior group (p=NS). According to ODI, two patients, who were operated on by posterior spinal fusion, had a severe disability.

### Complications

Complications occurred in five out of twelve patients (42 %). One patient (#7) underwent five revision surgeries after her anteroposterior index surgery with Harrington subcutaneous distraction rod. The upper hook was noted to be displaced on three occasions and during one of the revisions an infection was found so the apparatus had to be removed temporarily. Finally, a permanent anteroposterior spinal fusion with Harrington instrumentation was performed four years after the index surgery. She later developed a proximal junctional kyphosis of 90 degrees cranially to the instrumentation. An in situ strut graft operation and extended posterior instrumentation to prevent progression of kyphosis was recommended nine years after the anteroposterior spinal fusion, but the patient refused.

One patient (#16) developed a total motor paraplegia with mild sensory function left in the lower extremities. The patient had a kyphosis of 80° with severe local spinal stenosis and paraparetic symptoms preoperatively and underwent a posterior spinal fusion with five thoracic vertebral decancellation osteotomies. The paraplegia was observed immediately after surgery. A re-decompression of the posterior elements as well as removal of the posterior vertebral wall was performed eight hours after the end of the index surgery. The cause for post-operative paraplegia appeared to be a piece of posterior vertebral wall, which was left behind during the decancellation procedure at the index surgery. The total motor dysfunction has remained unchanged but she has recovered some sensory function of the lower extremities.

## Results

---

Patient #17 developed a proximal junctional kyphosis of 91 degrees. An anterior in situ fibular strut graft was placed across the deformity five years after the index procedure and this has stabilized the progression of the kyphosis.

Other complications were a transient sensorical neurologic deficit of the lower extremity (# 14) and an implant breakage without the need for revision surgeries (# 1). (Table 13)

## Results

**Table 13.** Comparison between the operative methods in diastrophic dysplasia patients. Values are median (range) or amounts. NS = non significant; CD = Cotrel-Dubousset

	Posterior	Anteroposterior	Anterior	P
<b>Patients</b>	5	6	1	NS
<b>Males / Females</b>	1 / 4	3 / 3		NS
<b>Age at surgery (years)</b>	12.5 (12 – 16)	13.6 (6.5 – 15)	20	NS
<b>Follow-up time (years)</b>	16.4 (7.8 – 37)	7.3 (2.1 – 20)	16	NS
<b>Age at follow-up (years)</b>	31.8 (19 – 50)	18.5 (15 – 33)	36	NS
<b>Scoliosis type</b>	5 Idiopathic-like	4 Idiopathic-like 2 Early progressive	Idiopathic-like	
<b>Main curve location</b>	1 Proximal thoracic 4 Main thoracic	1 Proximal thoracic 4 Main thoracic 1 Lumbar	Lumbar	
<b>Main curve (°)</b>				
<b>Preoperative</b>	66 (53 – 87)	82 (55 – 100)	67	NS
<b>Final follow-up</b>	60 (45 – 74)	49 (20 – 78)	38	NS
<b>Kyphosis (°)</b>				
<b>Preoperative</b>	50 (40 – 96)	64 (25 – 75)	8	NS
<b>Final follow-up</b>	65 (33 – 82)	71 (20 – 105)		NS
<b>Sagittal balance</b>				
<b>Preoperative</b>	48 (26 – 144)	113 (42 – 118)	40	NS
<b>Final follow-up</b>	45 (24 – 86)	110 (59 – 179)		NS
<b>Fusion levels</b>	10 (8 – 13)	11 (7 – 15)	5	NS
<b>Instrumentations</b>	1 Harrington 1 Harrington-Wisconsin 1 CD 1 Colorado 1 no instr.	1 Harrington 2 CD 1 CD – Horizon 1 Isola 1 USS 2	Zielke	
<b>Complications</b>	1 Permanent paraplegia 1 Implant breakage	1 Transient neurologic deficit 1 Implant breakage 2 Proximal junctional kyphosis		

## Surgical Treatment of Neuromuscular Scoliosis with the Total Pedicle Screw and Hybrid Constructs

### Operative Results

The mean age at operation was 16 years (SD 3.0 years; range 9.1-20) in the hybrid group and 15 years (SD 2.5 years; range 7.0-21) in the pedicle screw group ( $p=NS$ ). There were 15 boys and 18 girls in both groups. Mean operative times were 7.45 hours (SD 2.18 hours) in the hybrid group and 6.0 hours (SD 1.71 hours) in the pedicle screw group ( $p=0.001$ ) and mean intra operative blood loss 3760 mL (SD 2.79 mL) and 1785 mL (SD 1.11 mL), respectively ( $p=0.002$ ). When blood losses were evaluated relative to the estimated blood volumes of the patients, the blood losses averaged 170 % (SD 130 %) in the hybrid and 82 % (SD 49 %) in the pedicle screw group, respectively ( $p=0.007$ ). In the posterior part of the combined anteroposterior surgery, the operative time was also significantly shorter and intraoperative blood loss was significantly smaller in the TPS group when compared with the hybrid ( $p=0.011$  and  $p=0.006$ , respectively). Fixation was extended to iliac bone more often in the pedicle screw group ( $p=0.007$ ). There were no differences in the amounts of fused vertebral segments. All ambulatory patients maintained their walking ability.(Table 14)

**Table 14.** The operative results in neuromuscular scoliosis patients. Values are mean (SD = standard deviation) or amounts. TPS = Total pedicle screw; NS = Non-significant

	Hybrid (n=33)	TPS (n=33)	P
<b>Fused segments</b>	16 (SD 1.2)	15 (SD 1.6)	NS
<b>Iliac fixation</b>	10 (30 %)	21 (64 %)	0.007
<b>Operative time (hours)</b>	7.5 (SD 2.2)	6.0 (SD 1.7)	0.001
<b>Anteroposterior surgery</b>	13 (40 %)	4 (12 %)	0.011
<b>Intraoperative blood loss (mL)</b>	3800 (SD 2800)	1800 (SD 1100)	0.002

### **Radiological Outcomes**

The mean preoperative Cobb angle of the major curve was 87° (SD 29; range 25-141) in the hybrid group and 80° (SD 17; range 47-116) in the pedicle screw group (p=NS) (Table 15). The preoperative flexibility of the major curve in traction radiograph was similar in the study groups (36 % [SD 22 %] in the hybrid vs. 37 % [SD 14 %] in the pedicle screw group). The major curve correction at final follow-up was 59 % (SD 19 %) in the hybrid group and 75 % (SD 15 %) in the TPS group. The magnitude and correction of major curve was significantly better in the pedicle screw group as compared with the hybrid group at immediate postoperative (p=0.003 and p<0.001, respectively) and final follow-up radiographs (p=0.002 and p=0.001, respectively) (Table 15). Average major curve corrections at two years were 59 % (SD 19 %) in the hybrid and 75 % (SD 15 %) in the pedicle screw group, respectively (p=0.001). There were no statistically significant differences in the mean thoracic kyphosis and lumbar lordosis, sagittal and coronal balances or pelvic obliquity pre- and postoperatively between the study groups (Table 15). Radiographic evidence of a non-union at final follow-up was not found in any patient. Proximal junctional kyphosis (>15°) was found in 13 patients in the hybrid and in 6 patients in the pedicle screw group (p=NS). None of our patients had undergone revision surgery for proximal junctional kyphosis.

### **The Health-related-quality-of-life Outcomes**

The SRS-24 questionnaires were available at final follow-up in 18 (55 %) of patients in the hybrid group and in 23 (70 %) patients in the TPS group. SRS-24 total scores were 97 (SD 8) in the hybrid and 95 (SD 11) in the pedicle screw group at final follow-up (p=0.41).

## Results

**Table 15.** The radiologic outcomes of neuromuscular scoliosis patients operated on by the TPS (total pedicle screw) or hybrid constructs. The values are represented as mean (SD = standard deviation). Coronal balance and pelvic obliquity results are absolute values.

	Hybrid (n=33)	TPS (n=33)	P
<b>Major curve (°)</b>			
<b>Preoperative</b>	87 (SD 29)	81 (SD 18)	NS
<b>Preoperatively in traction</b>	63 (SD 21)	57 (SD 16)	NS
<b>Postoperatively</b>	32 (SD 20)	19 (SD 12)	0.0028
<b>Final follow-up</b>	33 (SD 20)	20 (SD 12)	0.0016
<b>Thoracic kyphosis (°)</b>			
<b>Preoperative</b>	48 (SD 34)	37 (SD 19)	NS
<b>Final follow-up</b>	36 (SD 14)	30 (SD 14)	NS
<b>Lumbar lordosis (°)</b>			
<b>Preoperative</b>	50 (SD 20)	49 (SD 19)	NS
<b>Final follow-up</b>	40 (SD 19)	48 (SD 15)	NS
<b>Sagittal balance (mm)</b>			
<b>Preoperative</b>	43 (SD 81)	52 (SD 33)	NS
<b>Final follow-up</b>	46 (SD 30)	37 (SD 22)	NS
<b>Coronal balance (mm)</b>			
<b>Preoperative</b>	39 (SD 35)	48 (SD 25)	NS
<b>Final follow-up</b>	20 (SD 17)	30 (SD 30)	NS
<b>Pelvic obliquity (°)</b>			
<b>Preoperative</b>	17 (SD 14)	14 (SD 10)	NS
<b>Postoperative</b>	7 (SD 7)	3 (SD 5)	NS
<b>Final follow-up</b>	7 (SD 8)	4 (SD 4)	NS

---

### Complications

No operative mortality was encountered. Significant complications occurred in 33 % (11/33) in the hybrid group and in 21 % (7/33) in the TPS group (p=NS) (Table 16). One transient neurologic deficit occurred in each group. In the hybrid group, two dural lesions, three pleural lesions, three deep wound infections, three implant failures, seven gastrointestinal complications, one pneumonia and one syndrome of inappropriate antidiuretic hormone (SIADH). The complications in the pedicle screw group consisted of two dura lesions, one deep wound infection, two implant failures, one superior gluteal arterial lesion, one positive sagittal balance due to lumbosacral junctional kyphosis causing walking difficulties after instrumentation to L5, three gastrointestinal complications and one pneumonia.

An L3 pedicle subtraction osteotomy and pelvic fixation was performed to the patient with lumbosacral junctional kyphosis and this solved the issue. Dura lesions occurred during posterior spinal surgery when inserting sublaminar wires, pedicle preparation or during Ponte procedure. Gluteal artery lesion occurred in the ischiadicum notch during posterior exposure of the iliac wing. One patient experienced transient loss of MEP signals during scoliosis surgery because of a high thoracic pedicle screw was inserted into the spinal canal. After screw removal, MEP signals came back and the patient recovered uneventfully.

Two early deep wound infections (within 6 weeks) were treated with irrigation and debridement and long antibiotic treatment. Both cases resolved. One early and one late infection required repeated irrigation and debridement and implant removal as well as immediate re-instrumentation using titanium implants (both in the hybrid group). Implant breakages consisted of three rod breakages, one iliac connector breakage, one hook claw cutting through the laminae. Only one of these patients (hybrid group) required revision surgery. Altogether, four patients in the hybrid and one in the pedicle screw group required revision surgery.

One patient with ventricle retention was treated with jejunal feeding catheter for 6 weeks. Three patients with dysphagia required temporary gastrostomas and one patient was re-hospitalized for the same problem, but the situation resolved with conservative method. Prolonged paralytic ileuses (2 weeks) resolved with nasogastric tube decompression. The patient with gastroenteritis was treated with antibiotics.

## Results

**Table 16.** Complications in the neuromuscular scoliosis patients operated on either with a TPS (total pedicle screw) or hybrid construct. SIADH = Syndrome of inappropriate antidiuretic hormone.

	<b>Hybrid</b>	<b>TPS</b>
<b>Complications</b>	<b>11 patients</b>	<b>7 patients</b>
<b>Transient neurologic deficit</b>	1	1
<b>Dura lesion</b>	2	2
<b>Pleura lesion</b>	3	0
<b>Pneumonia</b>	1	1
<b>Ventricle retention</b>	1	0
<b>Dysphagia</b>	2	2
<b>Paralytic ileus</b>	3	1
<b>Gastroenteritis</b>	1	0
<b>Implant breakages</b>	3	2
<b>Deep wound infections</b>	3	1
<b>SIADH</b>	1	0
<b>Arterial lesion</b>	0	1
<b>Poor sagittal spinal balance</b>	0	1
<b>Revision surgeries</b>	4	1



## **Surgical Treatment of Isthmic Spondylolisthesis in Children and Adolescents**

### **The Whole Study Population**

Of 298 operated on isthmic spondylolisthesis patients, 214 (72 %) were low-grade and 84 (28 %) were high-grade. The characteristics of the study population can be seen in Tables 19 and 20. The mean follow-up time was 17 (SD 13) years. Twenty-nine females were  $\leq 12$  years and 26 males  $\leq 14$  years at the time of surgery. Patients with high-grade slips were encountered relatively more often in children when compared to adolescents (51 % vs. 23 %;  $p=0.0009$ ). Circumferential or anterior method was, therefore, relatively more often used in children than adolescents (16/55, 29 % vs. 35/243, 14 %) ( $p=0.016$ ). There were 8 non-unions (15 %; 3 reoperations) in children and 16 non-unions (7 %; 9 reoperations) in adolescents. Complication rates were 7.3 % and 7.8 %, respectively. (Table 17 & 18)

In the patients with low-grade slips, the mean SRS-24 total score was 95.9 (SD 10) for the children and 92.0 (SD 15) for the adolescents ( $p=NS$ ) at final follow-up. The ODI were 5.2 (SD 2.6) % and 7.5 (SD 5.8) % ( $p=NS$ ) and VAS (low back pain) 18.9 (SD 21) mm and 21.2 (SD 27) mm, respectively ( $p=NS$ ). In the patients with high-grade slips, the mean SRS-24 total score was 95.6 (SD 10) and 90.6 (SD 15) ( $p=NS$ ), ODI 3.4 (SD 2.6) % and 6.9 (SD 5.8) % ( $p=0.035$ ) and VAS (low back pain) 10.5 (SD 21) mm in the children and 22.1 (SD 27) mm in the adolescents ( $p=0.042$ ).

## Results

**Table 17.** The characteristics of the low-grade (< 50 % slip) isthmic spondylolisthesis patients. Time is represented in years, lumbosacral kyphosis in degrees. Values are mean (SD = standard deviation) or amount (percentage). NS = Non-significant.

Low Grade (n=214)				
	Children	Adolescents		P
<b>Number of pts</b>	27 (13 %)	188 (87 %)		
<b>Sex</b>				
Males	13 (48 %)	81 (43 %)		NS
Females	14 (52 %)	107 (57 %)		NS
<b>Age at surgery (years)</b>	11.8 (SD 2.0)	16.5 (SD 1.7)		0.0001
<b>Follow-up time (years)</b>	18.6 (SD 3.5)	19.9 (SD 3.2)		
<b>Age at follow-up (years)</b>	30,4 (SD 4.1)	36.5 (SD 3.5)		
<b>Preoperative slip</b>	27.8 % (SD 13 %)	33.8 % (SD 14 %)		
<b>Preoperative lumbosacral kyphosis (°)</b>	-18.9 (SD 18)	-12,4 (SD 19)		
<b>Operative methods</b>				
Direct Repair	5 (19%)	12 (6%)		0.033
Posterior	10 (37%)	43 (23%)		NS
Posterolateral	11 (41%)	133 (71%)		NS
Anterior	0 (0%)	0 (0%)		NS
Circumferential	1 (4%)	0 (0%)		NS
Reduction	0 (0%)	0 (0%)		NS

## Results

**Table 18.** The characteristics of the high-grade ( $\geq 50\%$  slip) isthmic spondylolisthesis patients. Values are mean (SD = standard deviation) or amount (percentage). NS = Non-significant.

	High Grade (n=84)		
	Children	Adolescents	P
<b>Number of pts</b>	28 (33 %)	56 (67 %)	
<b>Sex</b>			
Males	13 (46%)	20 (36%)	NS
Females	15 (54%)	36 (64%)	NS
<b>Age at surgery (years)</b>	12.0 (SD 1.7)	15.6 (SD 1.7)	0.0001
<b>Follow-up time (years)</b>	17.6 (SD 4.4)	16.5 (SD 4.4)	
<b>Age at follow-up (years)</b>	29.7 (SD 4.8)	32.1 (SD 4.9)	
<b>Preoperative slip (years)</b>	67.0 % (SD 17)	70.5 % (SD 16)	
<b>Preoperative lumbosacral kyphosis (°)</b>	16.8° (SD 20)	16.6° (SD 15)	
<b>Operative methods</b>			
Direct Repair	0 (0%)	0 (0%)	NS
Posterior	0 (0%)	0 (0%)	NS
Posterolateral	10 (36%)	13 (23%)	NS
Anterior	9 (32%)	17 (30%)	NS
Circumferential	6 (21%)	18 (32%)	NS
Reduction	3 (11%)	8 (14%)	NS

## The Matched Cohorts

### Operative Results

In this study, there were 22 matched pairs of patients with low-grade slips and 19 pairs of patients with high-grade slips. Low-grade spondylolisthesis patients (n=44) were treated with non-instrumented posterior (n=11) or posterolateral fusion in situ (n=29) or direct repair (n=4). Patients with high-grade slips were operated on by the non-instrumented posterolateral (n=5), anterior (n=6) or circumferential anteroposterior (n=6) spinal fusion in situ or by instrumented reduction (n=2). Decompressions were performed primarily in 7 patients (3 Children and 4 Adolescents; all high grade).

## Results

In children, the age at surgery was 11.9 (SD 1.6) years and in adolescents 16.4 (SD 1.6) years ( $p < 0.05$ ). The mean follow-up time was 18.7 (SD 3.6) years and 15.5 (SD 3.4) years ( $P < 0.05$ ), respectively, and age at final-follow-up 30.6 (SD 4.0) years and 31.9 (SD 4.0) years, respectively ( $P = NS$ ). (Table 19 & 20)

**Table 19.** The characteristics of the low-grade (< 50 % slip) patients in the matched cohorts. Values are mean (SD = standard deviation) or amount (percentage). NS = Non-significant.

Low Grade (n= 44)				
		Children	Adolescents	p value
<b>Number of pts</b>		22	22	
<b>Sex</b>	Males	11 (50 %)	11 (50 %)	NS
	Females	11 (50 %)	11 (50 %)	NS
<b>Age at surgery (years)</b>		12.0 (SD 1.6)	16.8 (SD 1.6)	0.0001
	Males	13.1 (SD 0.8)	17.4 (SD 1.6)	0.003
	Females	10.9 (SD 1.4)	16.2 (SD 1.6)	0.003
		(a)	(b)	
<b>Follow-up time (years)</b>		19.2 (SD 3.4)	16.0 (SD 2.4)	0.0001
<b>Age at follow-up (years)</b>		31.2 (SD 3.5)	32.8 (SD 3.0)	0.0001
<b>Preoperative clinical findings</b>				
	Postural and/or gait abnormality	4 (18 %)	0 (0 %)	NS
	SRA positive	2 (9 %)	0 (0 %)	NS
	Scoliosis	6 (27 %)	0 (0 %)	0.021
<b>Operative methods</b>				
	Direct repair	2 (9 %)	2 (9 %)	NS
	Posterior	8 (36 %)	3 (14 %)	NS
	Posterolateral	12 (55 %)	17 (77 %)	NS
	Anterior	0 (0 %)	0 (0 %)	NS
	Circumferential	0 (0 %)	0 (0 %)	NS
	Reduction	0 (0 %)	0 (0 %)	NS

## Results

**Table 20.** The characteristics of the high-grade ( $\geq 50\%$  slip) patients in the matched cohorts. Values are mean (SD = standard deviation). NS = Non-significant.

		High Grade (n = 38)		
		Children	Adolescents	p value
<b>Number of pts</b>		19	19	
<b>Sex</b>	Males	6 (32 %)	6 (32 %)	NS
	Females	13 (68 %)	13 (68 %)	NS
<b>Age at surgery (years)</b>		11.8 (SD 1.7)	16.0 (SD 1.5)	0.0001
	Males	13.6 (SD 0.8)	16.7 (SD 1.1)	0.028
	Females	10.9 (SD 1.3)	15.7 (SD 1.6)	0.001
		(c)	(d)	
<b>Follow-up time (years)</b>		18.2 (SD 3.9)	14.9 (SD 4.3)	0.0001
<b>Age at follow-up (years)</b>		30.0 (SD 4.5)	30.9 (SD 4.7)	0.076
<b>Preoperative clinical findings</b>				
	Postural and/or gait abnormality	10 (53 %)	1 (5 %)	0.019
	SRA positive	14 (74 %)	5 (26 %)	0.009
	Scoliosis	8 (42 %)	4 (22 %)	NS
<b>Operative methods</b>				
	Direct repair	0 (0 %)	0 (0 %)	NS
	Posterior	0 (0 %)	0 (0 %)	NS
	Posterolateral	5 (26 %)	5 (26 %)	NS
	Anterior	6 (32 %)	6 (32 %)	NS
	Circumferential	6 (32 %)	6 (32 %)	NS
	Reduction	2 (11 %)	2 (11 %)	NS

---

### Radiological Outcomes

In patients with low-grade spondylolisthesis, the vertebral slip averaged preoperatively 29 (SD 13) % in the children and 26 (SD 11) % in the adolescents. The vertebral slip improved postoperatively on average 5 (SD 10) % points in the children, and it remained unchanged in the adolescents, improving 0.2 (SD 6) % points ( $p=NS$ ). Lumbosacral kyphosis and lumbar lordosis increased in low-grade children while in adolescents it did not ( $p<0.05$ ). S1-L3 distance was increased at final follow-up without marked differences between the children and adolescents ( $p<0.05$ ). According to flexion-extension radiographs, 3 (15 %; direct repair pts excluded) children and 7 (35 %) adolescents had a non-union at the FFU ( $p=NS$ ). (Table 21) The mobility of the spinal segment above the fusion area averaged 16 (SD 5.9) ° and 15 (SD 5.7) °, respectively.

The mean preoperative vertebral slip in patients with high-grade spondylolisthesis was 70 (SD 16) % in the children and 67 (SD 12) % in the adolescents. The vertebral slip improved postoperatively on average 14 (SD 13) % points and 2 (SD 11) % points, respectively ( $p=0.009$ ). Lumbosacral kyphosis did not change significantly after surgery in high-grade children or adolescents. Lumbar lordosis in children increased after surgery, while in the adolescents it did not ( $p<0.05$ ). S1-L3 distance in children and adolescents was increased at final follow-up without marked differences between the children and adolescents. Radiographic non-union was observed at FFU in 5 (26 %) children and 3 (16 %) adolescents with high-grade slips. (Table 22) The mobility of the spinal segment above the fusion area averaged 15 (SD 7.5) ° and 14 (SD 6.8) ° degrees, respectively.

## Results

**Table 21.** Radiological outcomes of low-grade (< 50 % slip) patients in the matched cohorts. Values are mean (SD = standard deviation) or amount (percentage). NS = Non-significant.

		Low Grade		
		Children (n=22)	Adolescents (n=22)	p
<b>Vertebral slip (%)</b>				
	<b>Preoperative</b>	29.0 (SD 13)	26.0 (SD 11)	NS
	<b>Final follow-up</b>	24.4 (SD 14)	25.7 (SD 12)	NS
<b>Lumbosacral kyphosis (°)</b>				
	<b>Preoperative</b>	-20.0 (SD 17)	-15.6 (SD 11)	0.085
	<b>Final follow-up</b>	-12.6 (SD 14)	-12.7 (SD 8.1)	NS
<b>Lumbar lordosis (°)</b>				
	<b>Preoperative</b>	48.2 (SD 14)	50.9 (SD 11)	NS
	<b>Final follow-up</b>	62.9 (SD 14)	59.5 (SD 13)	NS
<b>S1 – L3 horizontal distance (mm)</b>				
	<b>Preoperative</b>	18.0 (SD 16)	24.4 (SD 11)	NS
	<b>Final follow-up</b>	24.0 (SD 22)	30.4 (SD 15)	NS
<b>Non-unions at follow-up</b>				
		3 (14 %)	7 (32 %)	NS
<b>Disc degeneration above the desis area</b>				
	None	13 (59 %)	11 (50 %)	NS
	Less than 50 %	9 (41 %)	11 (50 %)	NS
	More than 50 %	0 (0 %)	0 (0 %)	NS

## Results

**Table 22.** The radiologic outcomes of high-grade ( $\geq 50$  % slip) patients in the matched cohorts. Values are mean (SD = standard deviation) or amount (percentage). NS = Non-significant.

		High Grade		
		Children	Adolescents	
		n = 19	n = 19	p
<b>Vertebral slip (%)</b>				
	<b>Preoperative</b>	69.5 (SD 16)	66.7 (SD 12)	NS
	<b>Final follow-up</b>	55.6 (SD 18)	65.2 (SD 12)	0.043
<b>Lumbosacral kyphosis (°)</b>				
	<b>Preoperative</b>	19.4 (SD 19)	14.3 (SD 13)	NS
	<b>Final follow-up</b>	21.5 (SD 15)	11.6 (SD 14)	0.028
<b>Lumbar lordosis (°)</b>				
	<b>Preoperative</b>	60.7 (SD 16)	66.2 (SD 14)	NS
	<b>Final follow-up</b>	72.9 (SD 12)	69.6 (SD 13)	NS
<b>S1 – L3 horizontal distance (mm)</b>				
	<b>Preoperative</b>	49.1 (SD 16)	53.2 (SD 13)	NS
	<b>Final follow-up</b>	58.9 (SD 19)	60.2 (SD 16)	NS
<b>Non-unions at follow-up</b>		5 (26 %)	3 (16 %)	NS
<b>Disc degeneration above the desis area</b>				
	None	9 (47 %)	11 (58 %)	NS
	Less than 50 %	8 (42 %)	7 (37 %)	NS
	More than 50 %	2 (11 %)	1 (5 %)	NS



---

### Clinical Outcomes

#### *Symptoms Before Surgery*

In children with low-grade slips, the main symptom and indication for operative treatment was low back pain interfering with daily activities and not resolving after 6 months of conservative treatment in 15 (68%; one with radiculopathy). Of the remaining seven patients (four females, three males), five did not have pain at all, one had insignificant occasional low-back pain, the other had mild radiating pain. Their median age at operation was 11.4 (8 - 14) years. These operations were performed because of high risk of slip progression in six patients (median slip 41 %, range 25 – 46 %) and in one patient because of significant postural abnormalities, which did not resolve after 9 months of conservative treatment. A documented slip progression > 10 % points was observed in three. Additional preoperative symptoms in these patients were stiff spine (n=4), hamstring tightness (n=5), scoliosis (n=2), paresthesia (n=1) and limp (n=1). The patients were operated on after a median outpatient follow-up of 14 (6-24) months. Only one of these patients, a 12-year-old female, was operated on without further observation. She had a 40 % slip at admission with bilateral hamstring tightness and a secondary scoliosis. In adolescents with low-grade slips, the indication for operative treatment was low back pain, not responding to conservative treatment, in all 22 patients (100 %; 1 with radiculating pain).

In children with high-grade slips the preoperative symptoms were low back pain in 12 (63 %; 8 with radiculating pain) and abnormal posture and/or gait in 10 (53 %). Five (26 %; 1 with radiculating pain) of these patients had both of the symptoms, posture anomaly and low back pain. In adolescents with high-grade slips, the symptoms were low back pain in all 19 (100 %; 6 with radiculating pain) patients and abnormal posture and/or gait in 1 (5 %).

#### *Clinical and Functional Tests*

Of patients with low-grade slips, one child had a preoperative S1 nerve root motor deficit, but it resolved after surgery. Scoliosis was noted preoperatively in 6 (27 %) children and in none of the adolescents ( $p=0.021$ ) (Table 19). Scoliosis surgeries were not performed to any patient during follow-up. One patient from the children's group had a scoliosis at the final follow-up. Gait and/or postural abnormalities were not observed in any patient at the final follow-up. The functional test results did not differ between children and adolescents (Table 23).

In patients with high-grade spondylolisthesis, a positive SLR was observed in 14 (74 %; 9 due to hamstring tightness) children and in 5 (all due to hamstring tightness) adolescents preoperatively ( $p=0.009$ ) and in none of the patients at the FFU (Table 20). Scoliosis was noted preoperatively in 8 (42 %) children and 4 (22 %) adolescents ( $p=NS$ ). Two children underwent operative scoliosis correction during follow-up. At FFU 3 patients from the children's group and 1 patient from the adolescents' group had a mild scoliosis. Significant gait and/or postural abnormalities were not observed in any patient at the final follow-up. The functional test results did not differ between children and adolescents (Table 24).

## Results

**Table 23.** Functional test results of the low-grade (< 50 % slip) patients in the matched cohorts at the final follow-up. Spinal mobility measurements (lumbar flexion, extension and trunk sidebending) were regarded abnormal when below the mean–2SD of the age- and sex-adjusted normal population values. Values are mean (SD = standard deviation) or amount (percentage). NS = non-significant.

Characteristic	Low-Grade		p value
	Children (n=22)	Adolescents (n=22)	
Sit-up score	3.8 (SD 1.1)	3.8 (SD 0.9)	NS
Arch-up score	4.4 (SD 0.7)	4.6 (SD 0.5)	NS
Squatting score	4.4 (SD 0.8)	4.8 (SD 0.6)	NS
Abnormal lumbar flexion	4 (18 %)	5 (23 %)	NS
Abnormal lumbar extension	5 (23 %)	1 (5 %)	NS
Abnormal trunk sidebending	0 (0 %)	0 (0 %)	NS

**Table 24.** Functional test results of the high-grade ( $\geq$  50 % slip) patients in the matched cohorts at final follow-up. Spinal mobility measurements (lumbar flexion, extension and trunk sidebending) were regarded abnormal when below the mean–2SD of the age- and sex-adjusted normal population values. Values are mean (SD = standard deviation). NS = non-significant.

Characteristic	High-Grade		p value
	Children (n=19)	Adolescents (n=19)	
Sit-up score	3.2 (SD 1.3)	3.6 (SD 1.5)	NS
Arch-up score	3.7 (SD 1.4)	4.2 (SD 0.7)	NS
Squatting score	3.9 (SD 1.3)	4.1 (SD 1.1)	NS
Abnormal lumbar flexion	10 (53 %)	14 (74 %)	NS
Abnormal lumbar extension	7 (37 %)	7 (37 %)	NS
Abnormal trunk sidebending	0 (0 %)	0 (0 %)	NS

### **Health-Related-Quality-of-Life Outcomes**

The SRS-24 total score averaged 97.1 (SD 8.1) in the children and 91.7 (SD 9.0) in the adolescents with low-grade slips at final follow-up ( $p=0.046$ ). The mean ODI was 4.4 (SD 6.1) % and 4.3 (SD 4.4) %, respectively. The VAS for low back pain averaged 15.4 (SD 21) mm in the children and 21.0 (SD 20) mm in the adolescents ( $p=NS$ ).

In the high-grade spondylolisthesis patients the SRS-24 total score averaged 92.3 (SD 13) in children and 93.9 (SD 11) in adolescents at final follow-up ( $p=NS$ ). Mean ODI was 4.5 (SD 6.5) % and 8.7 (SD 9.0) %, respectively ( $p=NS$ ). VAS (low back pain) mean scores were 9.0 (SD 12) mm in children and 25.1 (SD 30) mm in adolescents ( $p=0.009$ ).

### **Complications**

The overall complication rates were 5 % and 9 % in low-grade spondylolisthesis children and adolescents, respectively. There was one revision surgery in children with low-grade slips due to symptomatic non-union after the index surgery. Postoperative complications in adolescents with low-grade slips included one revision due to non-union and one temporary quadriceps muscle weakness, which resolved spontaneously.

Complication rate was 21 % in both children and adolescents with high-grade slips. In the children's group there were 3 later revision surgeries due to symptomatic non-union and one transient L5 paresis, which resolved spontaneously without sequelae. In adolescents, one revision surgery was performed for a non-union, two later surgical decompressions for S1 root compressions and one superficial wound infection.

### **Outcome of the Children with Low-grade Slips without Significant Preoperative Pain**

At final follow-up, all seven patients had a normal posture and none had a scoliosis. One patient had mild residual bilateral hamstring tightness of 75 degrees. The median SRS-24 score was 95.0 (78-104), ODI 0 (0-22) and VAS for low-back pain 0 mm (0-67). On radiographs, there was a median slip improvement of 3 % (-7 – 28 %) points. One patient had an asymptomatic radiographic non-union. There was no correlation between the radiographic result and the clinical outcome in this subgroup.

## DISCUSSION

### **Surgical Treatment of Congenital Scoliosis by Hemivertebra Resection**

The results of this study indicate that hemivertebra resection can be performed with similar clinical, radiographic, and health-related-quality-of-life results by the posterior only or combined anteroposterior method. The incidence of complications was not statistically different, but there tended to be more transient neurologic complications in patients operated on by the posterior approach.

#### *Validity of the Data*

Patients were operated on consecutively. Radiographic follow-up rate was 100%. The study was retrospective and without matched comparison. The patient groups were heterogenic and small. The mean preoperative curves were more severe in the PL group and the age at the time of surgery was older than in the AP group. There tended to be more fully segmented hemivertebrae, double hemivertebra resections, neurologic symptoms and associated anomalies in the PL group as well. The AP approach is an older method, and therefore pedicle screw fixation was less often used in that group. Follow-up time was statistically longer in the AP group, but whether this creates any bias is unknown. Follow-up time in both of the groups was short. A direct Finnish translation of a validated patient outcome tool (SRS-24) was used for the HRQoL evaluation, but should be noted that SRS-24 was initially designed for AIS patients. Because of the young age of the patients they were not able to fill-in the questionnaires by themselves and required assistance of their closest relatives. In AIS, patients' parents have been observed to give higher scores in SRS-24 total score, satisfaction and self-image when compared to patients (Rinella et al. 2004). Because of the downsides mentioned above, this study should be evaluated as a descriptive series.

#### *Comparison with Previous Data*

Hemivertebra resection has been the predominant form of treatment for progressive congenital scoliosis resulting from hemivertebrae during the past decade (Shono et al. 2001; Ruf & Harms 2003; Nakamura et al. 2002). This method appears to provide better spinal deformity correction with shorter fusions than hemiepiphysiodesis, in situ fusion or instrumented spinal fusion (Yaszay et al. 2011). The current debate is whether this procedure is better when performed by posterior only or by the combined anteroposterior method.

The mean short to mid-term main curve correction after the combined anterior and posterior method has varied between 35 - 71 % in the previous studies (Callahan et al. 1997; Lazar & Hall 1999; Klemme et al. 2001; Hedequist et al. 2005; Bollini et al. 2006). Our median main curve correction in

---

the anteroposterior group (63 %) falls into that range. Also in the posterior hemivertebra resection group, our main curve correction at final follow-up (62 %) was similar as that achieved by other authors. Shono et al. and Nakamura et al. had mid-term corrections of 64 % and 54 %, respectively, with significantly older patients and longer instrumentations than in our study (Shono et al. 2001; Nakamura et al. 2002). Other authors, with short instrumentations and fusions similar to our technique, have achieved corrections between 72 – 82 % (Ruf & Harms 2003; Aydogan et al. 2008; Hedequist et al. 2009).

Compensatory curve corrections of 30 - 78 % have been reported in the cranial curves and approximately 60 % corrections in the caudal curves (Nakamura et al. 2002; Ruf & Harms 2003). Our caudal compensatory curve correction after posterior hemivertebra resection was similar (59 %) but the cranial curves did not change significantly. Our aim was to perform hemivertebra resection before the development of caudal and cranial structural curves.

Minor thoracic kyphosis correction have been achieved with the anteroposterior and the posterior only method without significant differences between the two methods in the literature (Lazar & Hall 1999; Hedequist et al. 2005; Shono et al. 2001; Ruf & Harms 2003; Nakamura et al. 2002; Aydogan et al. 2008; Hedequist et al. 2009). In our study, severe preoperative thoracic hyperkyphosis was not observed and significant kyphosis correction was therefore not achieved for. Lumbar lordosis has remained unaffected or progressed during follow-up in previous studies and this is in concordance with our findings (Hedequist et al. 2005; Bollini et al. 2006; Ruf & Harms 2002a).

Operative times were somewhat shorter in our study (4 hours in both methods) when compared to the previous studies, in which anteroposterior method lasted from 5 to 7 hours and in the posterior method from 4 to 6 hours (Klemme et al. 2001; Hedequist et al. 2005; Shono et al. 2001; Ruf & Harms 2003). Intraoperative blood loss has been higher in the posterior method (approximately 600 mL) when compared to the combined anteroposterior technique (150 – 360 mL) (Klemme et al. 2001; Hedequist et al. 2005; Shono et al. 2001; Ruf & Harms 2003; Nakamura et al. 2002; Aydogan et al. 2008; Hedequist et al. 2009). The findings in our current study were not contradictory. The higher blood loss during posterior only approach is probably related to poorer visibility of the operative area. The duration of postoperative hospitalization in the intensive care unit and in general were not significantly different between the two methods in our study. In contrast, the comparative study by Mladenov et al. reported the length of stay in intensive care and total hospitalization time to be substantially shorter in patients, who underwent posterior only hemivertebra excision (Mladenov et al. 2012).

Instrumentation removal does not seem to be necessary in congenital scoliosis patients, who have undergone hemivertebra excision at a young age at least according to our findings. It has been previously reported in mid-term studies that pedicle screws can be safely used in young children without interfering in the growth of the neurocentral synchondrosis, ie. causing spinal stenosis (Ruf & Harms 2002; Olgun et al. 2012).

In the most recent studies, the complication rate has been slightly smaller after the combined anteroposterior method (approximately 9 %) when compared to the posterolateral technique (14 %) (Callahan et al. 1997; Lazar & Hall 1999; Bollini et al. 2006; Klemme et al. 2001; Ruf & Harms 2003; Aydogan et al. 2008; Hedequist et al. 2009; Nakamura et al. 2002; Holte et al. 1995). Complications have ranged from non-unions and wound infections to nerve root lesions in the studies on the anteroposterior method and from infections to implant failures and revisions in the studies on the posterior technique. The posterior only method has been fairly safe regarding temporary or

## Discussion

---

permanent neurological deficits in the past and this holds true for the combined anteroposterior method in most of the studies (Boachie-Adjei & Bradford 1991; Bradford & Boachie-Adjei 1990; Callahan et al. 1997; Lazar & Hall 1999; Klemme et al. 2001; Hedequist et al. 2005; Bollini et al. 2006; Shono et al. 2001; Ruf & Harms 2003; Nakamura et al. 2002; Aydogan et al. 2008; Hedequist et al. 2009). Only Holte et al. reported a high incidence of neurological complications (22 %) after anteroposterior hemivertebra excision (Holte et al. 1995).

In our study, two patients had temporary neurological complications after posterior hemivertebra resection. Hemivertebra excision requires slight handling of the spinal cord structures during the posterior only approach. In a recent comparative study by Mladenov et al., neurologic deficits were not observed more commonly after posterior surgery, and it seemed that the combined method carried a higher risk for complications in general (Mladenov et al. 2012). In light of these variable findings in small patient cohorts, definitive conclusions cannot be made on which of these methods is safer. These results may reflect each institution's familiarity and experience with the particular technique.

Implant failure was observed rather frequently after segmental instrumentation by pedicle screws in the study by Ruf and coworkers, while this was not so in the comparative study by Mladenov et al. In the current study, we did not encounter any implant failures. The postoperative immobilization in a cast or brace was shorter in the study by Ruf et al. when compared to our study and the one conducted by Mladenov et al., which could explain the difference in outcomes.(Mladenov et al. 2012; Ruf & Harms 2003) It seems to be beneficial to continue bracing for up to 4 - 6 months after posterior only procedure. Alternatively, the three-rod technique (two rods with pedicle screw and one rod with laminar hook anchorage), which seems to have a low rate of implant breakages, could be used (Hedequist et al. 2009). Laminar hooks involve a cortical purchase, which may endure larger resistance. However, laminar hooks alone do not address the translational forces, which occur after spinal column resection.

It may not always be necessary to perform untethering of the tethered cord (low lying conus) before hemivertebra resection. Leung and Buxton suggested that patients with hemivertebra and diasthematomyelia can undergo hemivertebrectomy without untethering as surgery will shorten the spine and thus the length of the medulla. (Leung & Buxton 2005) Two of our three tethered cord patients (#6, 9) had preoperative neurologic symptoms. Patient #6's symptoms were instantly relieved after surgery but patient # 9's radiculopathy resolved more slowly, and to this day she continues to have occasional lower extremity pain. The explanation for this difference in postoperative condition might be, that patient # 6 received more spinal column shortening during vertebral column resection than # 9. The current golden standard in most institutions is to perform neurosurgical untethering before spinal deformity correction. This procedure can also be performed in the same stage as spinal deformity correction without increased risk for complications when compared to a separate untethering operation (Murans et al. 2010). It is too early to say whether spinal deformity correction without untethering can give comparable results with a combination of untethering and spinal deformity correction.

---

## Treatment of Scoliosis in Diastrophic Dysplasia

Brace treatment could not prevent progression of early progressive scoliosis in diastrophic dysplasia, but may postpone or prevent the need for perform surgical treatment in the idiopathic-like scoliosis. Reasonable correction of the spinal deformity can be obtained by anteroposterior spinal surgery before the curves exceed 100°. In the idiopathic-like type deformity posterior spinal fusion appears to be a sufficient method of surgical treatment if bracing cannot prevent progression. The sagittal balance of the trunk seems to be closely associated with hip and knee flexion contractures and therefore avoiding excessive correction of the lumbar hyperlordosis is important.

### *Validity of the Data*

We identified all available patients, who had either undergone brace or surgical treatment with a minimum of two years follow-up. The radiologic follow-up rate was 100%. The selection between the methods of treatment represents the development of surgical techniques in our units. The patients in the anteroposterior group received more modern instrumentation and one patient in the posterior group was left without instrumentation. All early-progressive patients were operated on by anteroposterior method. The comparison between posterior and anteroposterior surgery should be performed with caution. The follow-up time in this study was long, but the patient population was small. However, diastrophic dysplasia is a rare condition and this study population is one of the biggest in the literature concerning the treatment of spinal deformities in diastrophic dysplasia. Validated patient outcome tools (SRS-24 and Oswestry disability Index) were translated directly to Finnish and used in the evaluation of HRQoL. SRS-24 and ODI were originally designed for AIS. Because patients with diastrophic dysplasia have multiple skeletal problems, their SRS-24 and ODI scores should be interpreted with caution.

### *Comparison with Previous Data*

Diastrophic dysplasia is a rare skeletal dysplasia characterized by short-limbed short stature, multiple joint contractures and a frequent occurrence of spinal deformities that cause severe disability (Walker et al. 1972; Poussa et al. 1991). In addition to the adequate treatment of hip and knee problems, the maintenance of good spinal balance is of great importance in keeping these patients ambulatory and achieving a better quality of life. The treatment of spinal deformities in diastrophic dysplasia is poorly understood and without clear guidelines.

The incidence of diastrophic dysplasia is very low. This condition is more prevalent in Finland than in other countries. (Kaitila 1980) The number of patients undergoing surgery for spinal deformities in diastrophic dysplasia has been rather low. Based on a natural history study in our country, an estimated fifty patients (approximately 35 %) with diastrophic dysplasia have a spinal deformity, which is in the surgical indication area (> 45° major curve) according to the guidelines of idiopathic scoliosis (Remes et al. 2001a; Poussa et al. 1991). Many of these patients were born before the 1970s when surgical techniques as well as the instruments for severe spinal deformities did not exist. In addition, some patients had progressed to catastrophic end-stage with no surgical options left (curves exceeding well beyond 100°). To prevent these severe end results, we suggest close follow-up (every six months) at an early age (below the age of five years) to distinguish the early progressive and

---

idiopathic-like types of scoliosis. Follow-up after the age of five years can be performed annually for the rest of the patients.

Only few case reports exist on the outcomes of brace treatment of scoliosis in patients with diastrophic dysplasia. Herring and Poussa have reported unsuccessful bracing results in one and three patients, respectively, in whom the curves progressed despite of the treatment. Bethem et al. in the other hand found bracing to be effective in preventing curve progression in two patients. In the studies by Herring and Poussa and coworkers, bracing was began somewhat later (curves exceeded 50° and the patients were older) than in the study by Bethem and his coworkers. (Herring 1978; Bethem et al. 1981; Poussa et al. 1991) In our study, both early progressive patients and 2 out of 6 idiopathic-like patients who were braced progressed to the stage at which surgical treatment was performed or planned. The immediate correction of the deformity in the brace appeared to be lower than that obtained for patients with idiopathic scoliosis (Negri et al. 2012). In patients (n=4), who were not operated on or on a waiting list for surgery after bracing, the major curve curves progressed well beyond 50° in all but one patient. The health-related-quality-of-life results of these patients were comparable to patients who were operated on in this study and the radiographic deformity at final follow-up (median major curve 59°) was not statistically significantly different. The spinal deformities are very rigid in diastrophic dysplasia because of the abnormal structure of the cartilage which may be the explanation behind poor bracing results. In the early progressive type bracing does not appear to be effective, but in the idiopathic-like type it may postpone or prevent the need to perform surgical treatment in some of the patients.

Matsuyama et al. evaluated with short-term follow-up (mean 3.7 years) their experience with surgical treatment of scoliosis and kyphosis in patients with diastrophic dysplasia. Fifteen of their twenty-one patients had had a primary spinal deformity correction. Most of their patients underwent anteroposterior surgery. However, the correction of both thoracic and thoracolumbar / lumbar curves remained low with mean final corrections of 3 and 9 degrees. They concluded that early surgical treatment is indicated in this patient group. (Matsuyama et al. 1999) In the current study, patients undergoing anteroposterior surgery had a reasonable major curve correction of 32 % while the patients undergoing posterior only surgery had a correction of 15 %. The final outcome in this study was obviously influenced by different treatment methods and instrumentations. The effectiveness of TPS construct in this patient population is not yet known.

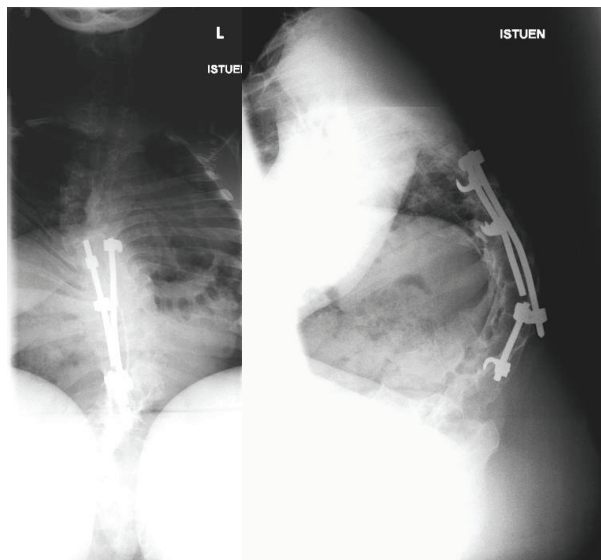
The ideal age for spinal deformity correction depends on the type of scoliosis. Early progressive type of scoliosis is usually evident during the first years of life and patients will need surgical treatment at an early age to maintain spinal balance, help preserve ambulatory status and pulmonary function. While the development of restrictive pulmonary disease or thoracic insufficiency has not been studied in diastrophic dysplasia patients with early progressive scoliosis, it has been observed that poorer PFT results correlate inversely with the severity of scoliosis in this disease (Remes et al. 2002).

Patients with idiopathic-like type of scoliosis, which progresses despite conservative treatment methods, are likely to need surgery after 10 years of age when curves exceed 50 degrees. Type of scoliosis can usually be defined very early based on initiation of deformity and curve type (Remes et al. 2001). There has not been correlations between the genotype and the development of spinal deformity and, thus, the genotype cannot be used in the prediction of spinal deformity progression (Remes et al. 2002b).

Early progressive type of scoliosis in diastrophic dysplasia presents as an extremely difficult condition to treat (Figure 27). In their natural history study, Remes et al. showed that without treatment the



Cobb angle at final follow-up visit averaged 134° with a range from 88° to 188° (Remes et al. 2001a). Two early progressive patients were included in the current study. The major curve had progressed significantly (exceeding 60°) before the age of three years in both. Boston type of brace was used in both to postpone the definitive spinal surgery for later age with unsatisfactory results. The first patient underwent anteroposterior surgery at the age of 6.5 years and the second patient had a subcutaneous Harrington rod at the age of four years. The latter patient underwent later definitive anteroposterior spinal fusion. At the final follow-up visit both were non-ambulatory but had a quite well controlled scoliosis and sitting balance. The latter patient, however, had developed proximal junctional kyphosis. By using combined anteroposterior spinal fusion we were able to avoid a catastrophically severe deformity in these patients. Currently, we might also use the classical growing rods, Shilla or the newer growing magnetic rods technique in order to postpone the final anteroposterior surgery for later age, although the growth potential in patients with diastrophic dysplasia is limited (Lenke & Dobbs 2007; Thompson et al. 2007; Akbarnia et al. 2011).



**Figure 27.** A girl with diastrophic dysplasia and early-progressive type scoliosis. An implant breakage was observed at final follow-up

Multiple joint contractures are common in diastrophic dysplasia. The etiology of hyperlordosis is believed to be multifactorial and hip joint flexion contracture appears to be associated with it (Poussa et al. 1991). Correction of lumbar hyperlordosis should at maximum be moderate, because losing the lumbar hyperlordosis may prevent standing in the upright position. In this study, most patients operated on showed positive standing sagittal balance, while sitting balance was good in all patients. Based on the current data and our previous findings it seems that patients with diastrophic dysplasia lose their ambulation mostly because of severe lower extremity problems, and only sometimes due severe spinal deformity associated with neurologic compromise (Remes 2001; Helenius, Remes, Tallroth, et al. 2003; Helenius, Remes, Lohman, et al. 2003).

The frequency of complications in our study was high (42 %) and rather similar to that of the study by Matsuyama et al (Matsuyama et al. 1999). Both series included a patient with central stenosis and neurologic compromise after correction of kyphoscoliosis. Our patient did not recover despite of decompressive procedures. The eight-hour treatment delay after the index surgery was probably one

---

reason for this (MacEwen et al. 1975). Implant breakages occurred in two patients (CD and Harrington instrumentations) (Figure 27). Proximal junctional kyphosis was observed in two patients with thoracic kyphoscoliosis. It seems that proximal thoracic instrumentation should be long enough, ending at the first or second thoracic vertebra to prevent this complication.

Health-related-quality-of-life outcomes at final follow-up were comparable in patients who were braced or operated on by the posterior or anteroposterior spinal fusion. While in the other fields of scoliosis surgery, the use of combined anteroposterior spinal fusion has decreased, it still holds a place in the treatment of severe, early progressive deformities in diastrophic dysplasia at least until the effectiveness of posterior spinal fusion with newer segmental constructs (like the hybrid and TPS) has been established.

### **Surgical Treatment of Neuromuscular Scoliosis with the Total Pedicle Screw and Hybrid Constructs**

This study indicates that posterior spinal fusion with TPS instrumentation and Ponte osteotomies can achieve better short-term major curve correction than hybrid instrumentation in NMS. Correction of spinopelvic balance appears to be similar with both methods. The necessity to perform combined anteroposterior approach was decreased in patients in whom TPS and Ponte osteotomies were used. The clinical outcomes and the amount and severity of complications were comparable at final follow-up.

#### ***Validity of the Data***

The current study represents a comparative clinical follow-up study in a consecutive series of matched patient groups undergoing surgery for neuromuscular scoliosis with either hybrid or TPS instrumentation. The data presented here has been collected via prospective systematic data collection system, although the study design was retrospective in nature. The postoperative outcomes were evaluated after the two matching groups had been formed. Radiographic follow-up rate was 100 %.

Selection between hybrid and TPS instrumentation as well as between anteroposterior and posterior only surgery represents development in the current surgical techniques with a tendency to perform as much surgery via posterior only approach as possible due to the fear of complications resulting from the additional surgical approach. This may have influenced spinal deformity correction and operative outcomes in the pedicle screw fixation group. Position of the pedicle screws was not routinely checked with CT scans. Thus, only complications caused by malposition of pedicle screws can be reported in the present study. The question of when to include pelvic fixation in the correction of neuromuscular scoliosis remains somewhat controversial. More patients received pelvic fixation in the pedicle screw group as compared with the hybrid group. None of the patients in the hybrid group underwent re-operation and pelvic fixation during the 2 years follow-up. Ponte osteotomies were also used more often in the TPS group, which may have an effect on the spinal deformity correction results and in the amount of complications. The indication for anterior surgery was different in patients with TPS instrumentation. No patient was lost during the minimum two-year follow-up.

---

SRS-24 is not designed for patients with neuromuscular scoliosis, but it includes also relevant questions for this patient group, such as those concerning satisfaction. SRS-24 was used in this study to evaluate its usefulness in NMS. Due to the low response rate (55 % in hybrid group and 70 % in the TPS group) its use in this patient group remains controversial.

### ***Comparison with Previous Findings***

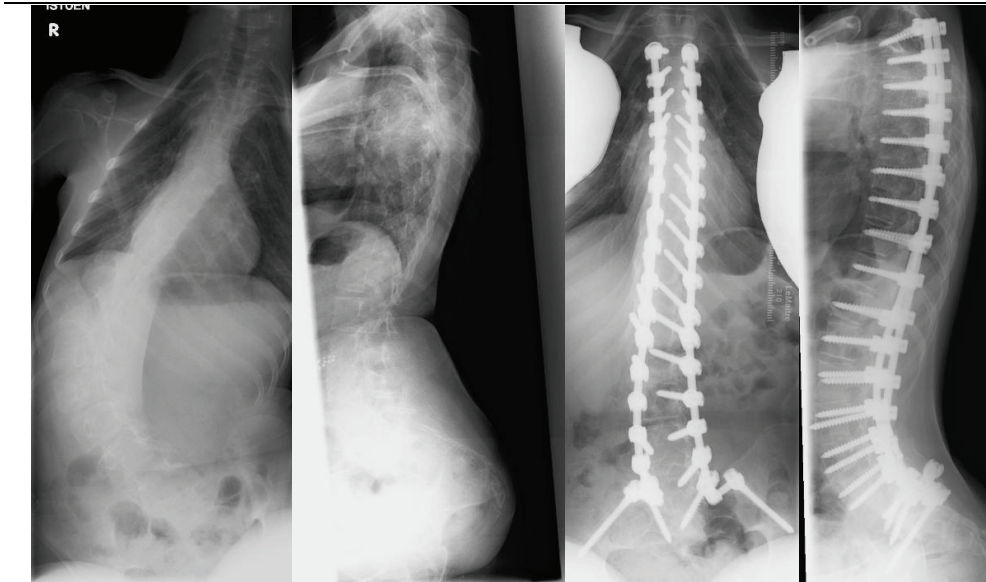
Better spinal deformity correction has been achieved by using TPS instrumentation in posterior spinal fusion for AIS when compared to the hybrid constructs (Wu et al. 2010; Kim et al. 2006; Liljenqvist et al. 2002; Suk et al. 2001). These results have raised hopes that TPS constructs could also provide better spinal deformity correction in NMS and decrease the need to perform anteroposterior surgery.

Modi et al. and Tsirikos et al. have reported satisfactory short-term correction of scoliosis (59 % & 73 % major curve corrections, respectively) in CP patients with the total pedicle screw construct in posterior spinal fusion (Modi et al. 2009a; Tsirikos & Mains 2011). With hybrid constructs, Teli and coworkers were able to achieve mid-term major curve correction of 55 % in posterior only fusion in CP (Teli et al. 2006). These findings reflect the results seen in our study.

Only few comparative studies exist between the TPS and hybrid instrumentation in NMS. Arun et al. reported the results of different instrumentation techniques (sublaminar instrumentation vs. hybrid vs. TPS) in 43 patients with DMD. Small number of incident cases in the pedicle screw group (11) and hybrid group (13) were a limitation of that study. Less blood loss and shorter operative time was observed in TPS instrumentation group compared to hybrid constructs and this is in concordance with our results. Furthermore, Arun et al. observed marginally better major curve correction after immediate post-operative correction was subtracted with flexibility index and that curve correction was slightly better maintained with pedicle screw constructs than with hybrids. (Arun et al. 2010)

In our study, patients with TPS constructs (and more Ponte osteotomies) achieved marginally better major curve correction than patients with hybrid constructs. It is important to notice, however, that the better radiographic major curve correction in our study is not necessarily clinically significant.

In NMS spinopelvic balance is regarded as being one of the most important aspects to address. The ability to correct spinal imbalance and pelvic obliquity was similar in both of the groups in our study and comparable with previous studies. Approximately 50 % correction can be achieved by TPS and hybrid constructs in pelvic obliquity ranging 14 - 21° before surgery (Arun et al. 2010; Modi et al. 2009a; Tsirikos & Mains 2011; Teli et al. 2006). (Figure 28)



**Figure 28.** A CP patient with poor spinal and pelvic balance before surgery. At final follow-up, a straight spine with good spinal balance and reasonable pelvic obliquity was achieved with a TPS (total pedicle screw) construct and pelvic fixation.

Positive sagittal balance in ambulatory neuromuscular patients is a common finding based on our clinical experience. One of the reasons for this finding are tight hip flexors and limited muscle balance. Postoperatively, one of our ambulatory patients developed a clinically significant positive sagittal balance due to both tight hip flexors and lumbosacral junctional kyphosis after instrumentation to L5. To solve this issue, an L3 pedicle subtraction osteotomy and pelvic fixation were carried out with good clinical outcome.

Major blood loss and associated coagulopathy are believed to be major risk factors for severe complications and mortality in patients undergoing surgery for NMS. Therefore, the limited blood loss in TPS constructs is an advantage over hybrid or Luque-Galvestone instrumentation. Passing a sublaminar wire or hook into the epidural space may start epidural venous bleeding, which can be difficult to stop and can re-start at every level of instrumentation. In contrast, a pedicle screw is an implant, which when optimally placed, does not violate the spinal canal. If bleeding starts from the cancellous bone of the vertebral body, it usually stops after screw insertion. Additionally, while pedicle screws may sometimes take a longer time to insert than hybrid anchors, many anterior approaches were avoided in our study. When only posterior approaches were compared, intraoperative blood loss was more limited in the pedicle screw than in the hybrid group. In the current series, average blood loss of 1785 mL in the pedicle screw group and 3760 mL in the hybrid group are within the previously reported blood loss ranges (Suk et al. 1995; Piazzolla et al. 2011).

The complication rate in surgical correction of NMS has been 18-32% in the literature and of the same magnitude as in our study (Modi et al. 2009; Master et al. 2011; Reames et al. 2011). The anterior instrumented spinal fusion has been associated with a higher number of complications than the posterior spinal fusion in the study by Reames et al., but the combined anteroposterior spinal fusion has not been associated with more severe complications than posterior only fusion in all of the studies in the past (Reames et al. 2011; Master et al. 2011). In our study, there tended to be more

---

complications in the hybrid group (33 % vs. 21 %), in which combined anteroposterior method was significantly more often used, but this finding did not reach statistical significance. It is also important to notice that Ponte osteotomies and iliac fixations, which have been associated with increased amounts of complications, were used more often in the TPS group in this study (Reames et al. 2011).

The question of whether TPS constructs could decrease the necessity of performing combined anteroposterior spinal fusion in NMS is not known. It has been proposed that the use of TPS instrumentation may provide better control of the crankshaft phenomenon in skeletally immature patients (with open triradiate cartilage), that are the usual candidates for the anteroposterior fusion. The few existing retrospective studies performed on idiopathic scoliosis patients have not proven this matter (Sponseller et al. 2009). In our study, combined anteroposterior spinal fusion was performed less often in the TPS group with similar spinal deformity correction, health-related-quality-of-life results and number of complications than hybrid group. Orthopaedic surgeons performing spinal deformity surgery should evaluate whether the benefits of total pedicle screw instrumentation are of value given the increased expenses as compared with hybrid instrumentation. Also long-term the effects of TPS construct on the spine and quality of life are yet unknown.

## **Surgical Treatment of Isthmic Spondylolisthesis in Children and Adolescents**

The outcome of surgical treatment of isthmic spondylolisthesis was very satisfactory in both children and adolescents before and after pubertal growth spurt. These findings held true for both the matched cohorts and whole study population. Clinically or functionally important differences in the outcome between the groups were not found. Children operated on at or before the pubertal growth spurt had statistically better outcomes in low back pain scores when compared to adolescents at final follow-up. However, these differences in HRQoL were small and not necessarily clinically important at this point of time.

### ***Validity of the Data***

This was a matched comparison of two groups of patients operated on at different ages. The results of the matched comparison were evaluated against the original study population. The outcomes were evaluated after the matching was performed.

As a retrospective analysis, this study has several shortcomings. The preoperative symptoms, status and indications for operative treatment were gathered from patients' medical records. Therefore, incomplete notes may create bias. SRS-24 has not been validated in isthmic spondylolisthesis. ODI, VAS and SRS-24 were not in use at the time when the patients were operated on. This makes the exact evaluation of the development of symptoms impossible. Furthermore, there was no control group of untreated patients available. Final follow-up assessment and data analysis were performed by independent observers. The two cohorts were carefully matched for gender, severity of the slip, operative method and age at final follow-up. Because patients were of similar age at final follow-up but of different age at surgery, the children had a significantly longer follow-up time. The surgical

---

method was matched to prevent the bias that advanced surgical technique would explain possible differences. Age and gender adjusted reference values were used in the spinal mobility and trunk strength measurements.

### *Comparison with Previous Studies*

The outcomes of surgical treatment of isthmic spondylolisthesis children before pubertal growth spurt are poorly known. To the best of our knowledge, this is the first long-term study attempting to analyze the long-term outcome of surgical treatment of isthmic spondylolisthesis in a significant number of patients operated on before the growth spurt in comparison to patients operated on during adolescence. Only 55 (18%) out of 298 patients were operated on before the pubertal growth spurt indicates that the need for surgical treatment is more rare in children than in adolescents. The pubertal growth spurt may play role in the development of symptoms in isthmic spondylolisthesis, but it is not possible to say whether this is a consequence of the growth itself or due to changes in lifestyle during puberty. In non-olistic youngsters, the incidence of low-back pain also increases significantly during puberty(Taimela et al. 1997).

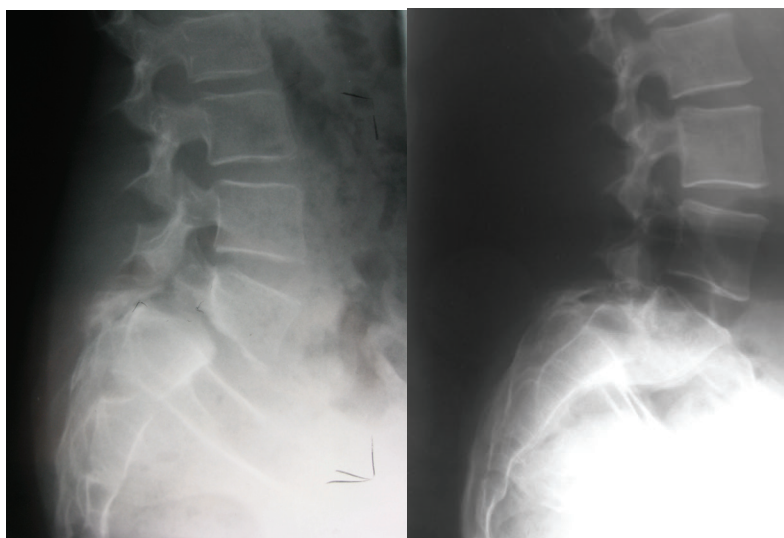
In the whole study population, the gender distribution and mean vertebral slip were relatively equal in children and adolescents. However, more high-grade slips were observed in the children and due to that, there were significantly more patients treated by anterior or combined anteroposterior fusion. The prevalence and type of symptoms were different between the groups. Adolescents had significantly more pain than children before surgery. The indication for operative treatment was low-back pain in all of the adolescents but in the children, approximately one-third (7/22) had no significant pain. They were operated on for postural anomalies and muscle tightness in combination with a grade II slip, which was considered higher risk of slip progression at that time. In the authors' opinion their clinical symptoms were an expression of root irritation and/or certain instability during slip progression when the pelvis is realigned to maintain sagittal balance and to relieve root compression/tension. This finding of higher prevalence of postural anomalies and less low-back pain in children has also been observed by other authors(Bell et al. 1988; Beguiristáin & Díaz-de-Rada 2004; Taillard 1954; Laurent 1958; Remes et al. 2006).

Taillard and Laurent have found preoperative low-back pain in only 32 – 37 % of child patients aged 5 to 15 years and in 56 – 68 % of adolescent patients(Taillard 1954; Laurent 1958). Bell et al. analyzed 28 low-grade patients, whose age averaged 11.4 (5.7-15.2) years. Of them, 17 (61%) had low-back pain and in 8 (29%) patients, the leading symptom was scoliosis and or poor posture. Clinically, 53% had hamstring tightness, 25% increased lumbar lordosis, and 14% had a scoliosis.(Bell et al. 1988)

The question arises of whether one should operate on pain-free patients with low-grade isthmic spondylolisthesis. In our opinion, a long lasting postural anomaly and hamstring tightness resistant to conservative measures is a significant disability. It bears also the risk of developing into a fixed deformity. We see that the operation was justified especially when, as in our cases, the slip was 25% or more which meant a considerable risk of further progression in patients before the pubertal growth spurt(Seitsalo et al. 1991). The patients' outcomes in this subgroup were very satisfactory and comparable to the remaining patients, but the authors must admit that their symptoms might have resolved spontaneously as well.

## Discussion

In the literature, sparse studies exist on the outcome of surgery in patients operated on before the growth spurt. Seitsalo et al analyzed retrospectively patients with isthmic spondylolisthesis whose age averaged ten years (range 1 - 11 years) at the time of admission. Operative treatment was performed in 32 / 56 patients (average slip 39 %) at a mean age of 12 years and 24 were treated by conservative methods (average slip 16 %). After a mean follow-up time of 15 years (range, 5 to 30 years), the clinical results were judged excellent in 68%, good in 11%, fair in 19% and poor in 2%. No difference in outcome could be found if comparing operatively and conservatively treated patients.(Seitsalo, Osterman, Poussa, et al. 1988b) A direct comparison with the results of the present study is not possible as different outcome measures were used. The current findings suggest that there are no reasons to postpone surgery for later age if the indications are met. Significant remaining spinal growth is not a risk factor for progression of the slip after non-instrumented spinal fusion. In the opposite, it seems that the slip decreases after fusion due to lumbosacral bony remodeling and this effect seems to be more profound in high-grade spondylolisthesis (Figure 29). Similar finding has been made in the study by Boxall et al(Boxall et al. 1979).



**Figure 29.** Preoperative (left) and long-term final follow-up (right) radiographs of a patient with high-grade slip, who underwent circumferential spinal fusion. Bony remodeling has improved the slip.

Lumbosacral kyphosis was observed to increase in low-grade children after non-instrumented posterolateral spinal fusion while in adolescents this did not occur. The significance of this finding is not clear. It may be a result of normal growth or bony remodeling. In high-grade children lumbosacral kyphosis did not increase after surgery. Most of these patients underwent circumferential or anterior fusion in situ, which may be able to withstand changes related to growth. Lumbar lordosis was observed to increase in children after surgery in both low- and high-grade children and it is possibly related to normal development and growth. The horizontal distance between the anterior corners of S1 and L3 increased in all patients and its meaning remains elusive. This finding did not coexist with the deterioration of lumbosacral kyphosis, so the authors believe that it is not directly related to worsening of spinopelvic alignment. Unfortunately radiographs were not obtained of the whole spine, so we were not able to reliably measure sagittal spinal balance. At final follow-up, however, significant clinical spinopelvic imbalance was not observed.

## Discussion

---

The non-union rate was high both in adolescents with low-grade slips (32%) and in children with high-grade slips (26 %). There might be some over diagnosis because the criterion for radiographic non-union (segmental flexion-extension motion of three degrees or more) is strict. However, the presence of non-union did not have significant negative effects on the patients' outcome in long-term, which has been observed by other authors as well (Seitsalo et al. 1992). There are several possible explanations for this. A non-union may stabilize the olisthetic segment to a certain degree. Posterolateral spinal fusion may denervate the isthmus area, which is considered to be one possible source of pain. The natural history of spondylolisthesis is benign and untreated young patients usually become symptom-free with time. The duration of symptoms, however, is shorter in operated patients (Seitsalo et al. 1990). This does not mean that the operation was not necessary in the given cases. The patients had disturbing symptoms for a significant period of time and were not motivated to continue conservative treatment further. Also, non-instrumented posterolateral fusion is known to be a low-risk procedure with a predictable clinical outcome (Frennered et al. 1991; Lenke et al. 1992).

In this study, six patients underwent revision surgeries for non-union after the index surgery, and even one of those had a non-union still at FFU. Circumferential in situ fusion is recommended for high-grade spondylolisthesis to increase the chance of spinal fusion (Frennered et al. 1991; Boxall et al. 1979). Whether instrumentation would increase spinal fusion rate in children has not been systematically studied with controlled prospective trials. In adults, instrumentation has not been found to provide significant benefit in preventing non-union when compared to non-instrumented fusion (Thomsen et al. 1997; Möller & Hedlund 2000). According to several studies in the literature, however, instrumented reduction in high-grade children and adolescents has provided better non-union rates (0-10 %) than what was observed in our study with non-instrumented circumferential fusion (26 %)(Ruf et al. 2006; Shufflebarger & Geck 2005; Muschik et al. 1997; Poussa et al. 2006; Molinari et al. 2002). In low-grade children and adolescents, the results with non-instrumented posterolateral in situ fusion have been excellent and therefore we do not see instrumentation to be mandatory in that patient population (Frennered et al. 1991; Lenke et al. 1992).



## CONCLUSIONS

Hemivertebra excision in congenital scoliosis can be performed with the modern surgical techniques and instrumentations by the posterior approach only. Posterior hemivertebra excision, while technically more demanding and possibly associated with more transient neurologic deficits appears to provide short-term results comparable to the combined anteroposterior hemivertebra excision.<sup>I</sup>

Bracing cannot prevent progression in early-progressive scoliosis in diastrophic dysplasia, but may slow progression and prevent the need to perform spinal surgery in idiopathic-like type scoliosis. Combined anteroposterior surgery achieves reasonable correction in progressive, rigid scoliosis in diastrophic dysplasia. Posterior spinal fusion appears to be adequate surgical treatment in idiopathic-like type scoliosis. Complication rate is high in the surgical treatment of spinal deformities in diastrophic dysplasia.<sup>II</sup>

In neuromuscular scoliosis, spinal fusion with TPS construct and Ponte osteotomies achieves similar clinical and radiographic outcomes as the hybrid construct with less need to perform anteroposterior surgery. The incidence of complications was not significantly different between patients operated on with TPS or hybrid constructs.<sup>III</sup>

The non-instrumented combined anteroposterior spinal fusion in situ achieves good and comparable results in high-grade isthmic spondylolisthesis in both children and adolescents before and after pubertal growth spurt. Posterolateral spinal fusion in situ is an effective and safe method in symptomatic low-grade isthmic spondylolisthesis if conservative treatment methods fail. Bony remodeling improved slip after surgery in high-grade children. Non-union rate was substantial in both children and adolescents, but it did not have significant negative effects on the clinical, radiographic and health-related-quality-of-life results after a long-term follow-up.<sup>IV</sup>

## SUMMARY

Isthmic spondylolisthesis and scoliosis are common spinal deformities in children and adolescents. While most of these conditions can be treated successfully with conservative treatment methods, surgical treatment is validated when the spinal deformity is progressive and causes disabling symptoms, spinopelvic imbalance or impairment of pulmonary function. The golden standard in spinal deformity surgery is posterior spinal fusion. Large, rigid curves seen in non-idiopathic scoliosis are difficult conditions to manage. Conservative treatment methods are usually not effective and it may be warranted to use specialized surgical methods (e.g. combined anteroposterior approach or spinal osteotomies).

The combined anteroposterior approach in spinal surgery has been used in severe deformities, which are either too rigid or displaced that the posterior approach cannot achieve sufficient correction or fusion to prevent progression after surgery. The new segmental instrumentation systems, the total pedicle screw and hybrid (hook and screw) constructs, have improved spinal deformity correction outcomes in AIS. However, these improvements have not necessarily improved quality of life results. Also, due to the short-term experience, the use of these systems has not been fully established in non-idiopathic scoliosis. It is believed that these new segmental spinal instrumentations would decrease the need to perform combined anteroposterior spinal surgery and therefore improve patient safety and postoperative healing time.

The aim of this dissertation was to evaluate modern day surgical treatment methods of spinal deformities and the need to perform the more extensive combined anteroposterior approach in several different fields of spinal surgery in children and adolescents: hemivertebra excision in congenital scoliosis and spinal fusion in diastrophic dysplasia, neuromuscular scoliosis and isthmic spondylolisthesis.

In total, 402 patients were treated for scoliosis or spondylolisthesis at our institutions and included in a retrospective study. The outcomes of treatment were evaluated by examining clinical medical records, radiographs and validated health-related-quality-of-life questionnaires.

This study indicates that posterior spinal surgery with modern techniques and total pedicle screw instrumentation achieves comparable results with the combined anteroposterior approach in patients, who underwent surgical treatment of neuromuscular scoliosis or congenital scoliosis due to hemivertebra. To obtain the best possible outcome, it seems that the combined anteroposterior approach still holds a place in the treatment of severe scoliosis resulting from diastrophic dysplasia and high-grade isthmic spondylolisthesis in children and adolescents. Bracing appears to have little effect in preventing progression of early progressive scoliosis in skeletal dysplasia.

## ACKNOWLEDGEMENTS

This study was conducted mainly in two institutions, at the Children's Hospital, Helsinki University Central Hospital and at ORTON Orthopedic Hospital. My compliments go to all the staff who took part in the treatment and follow-up of the patients of this study. Without your precious work and help, I would not have been able to gather the information needed to conduct this study.

I would like to thank all the foundations, which have granted financial support for this study: The Finnish Paediatric Research Foundation, Rinnekoti Research Foundation, Research Foundation of Orthopaedics and Traumatology and EVO (Helsinki University Central Hospital, ORTON Orthopaedic Hospital & ORTON Foundation, Turku University Central Hospital). Also, Medtronic has provided important financial support to our research group so that we have been able to have a skilled research nurse, Katariina Kauste in our ranks. Baxter has provided me with travel grants for international congresses for several years now and therefore I am deeply grateful for their contribution in this study.

There are some individuals, who have been especially important to this study and for myself. My deepest gratitude goes to Ilkka Helenius, my supervisor. You have always made yourself available even when working 180 km away from Helsinki at Turku University Hospital. Your wisdom and sense in scientific matters as well as your friendliness has made my work environment extremely enjoyable. You have been the driving force of this study.

I want to thank Helena Saraste and Seppo Seitsalo for reviewing my dissertation thesis. Your advices and knowledge have been valuable to me during the final stages of this thesis. The discussions we held over the Internet and at restaurant Salve, respectively, were memorable. Risto Rintala deserves special gratitude for accepting to be my kustos and for being in my follow-up committee and my co-author.

I am immensely grateful to Benny Dahl for accepting the role as opponent in my thesis. I'm truly honored.

An important mentor for me during this study has been Dietrich Schlenzka. You are truly a wise man in both science and life. Thank you. I also would like to thank my other co-authors, who have contributed significantly to our studies: Jari Peltonen, Mikko Poussa, Ville Remes, Ville Puisto, Tommi Lamberg, Pekka Tervahartiala, Timo Yrjönen, Olli Pajulo and Mikko Mattila. I like to thank Markku Heikinheimo for being on my follow-up committee. Special thanks goes to Antti Koivusalo and Mikko Pakarinen, from whom I have received enormous knowledge on scientific matters and especially on what truly counts.

My scientific work would not have been possible without Ella Haaranen and the people at the patient record and radiograph archive of Children's Hospital. Helena Schmidt, thank you for your beautiful pictures in this thesis.

I would also like to thank all my dear friends outside of my scientific work. You have kept me happy in times of the good and the stressful. All the journeys we have made together have been important to me. Also, an extra gratitude goes to my good fellow and colleague Jussi Naukkarinen who in addition to providing scientific advice has also worked as a language consultant for this thesis.

## Acknowledgements

---

Last but not least, I am deeply grateful to my family. Brother, your wisdom is truly beyond your years and I have enjoyed the conversations and moments we have had. I like to thank you also for your remarkable cover picture. Mother and father, what can I say, because of you I am here. You have always supported me in all the possible ways and I cannot be thankful enough. I love you.

Thank you all once again,

Tuomas

## REFERENCES

- Adams, W., 1865. *Lecture on the Pathology and Treatment of Lateral and Other Forms of Curvature of The Spine*, London: Churchill and Sons.
- Adzick, N.S. et al., 2011. A randomized trial of prenatal versus postnatal repair of myelomeningocele. *The New England Journal of Medicine*, 364(11), pp.993–1004.
- Agabegi, S.S. & Fischgrund, J.S., 2010. Contemporary management of isthmic spondylolisthesis: pediatric and adult. *The Spine Journal*, 10(6), pp.530–543.
- Ain, M.C. et al., 2006. Postlaminectomy kyphosis in the skeletally immature achondroplast. *Spine*, 31(2), pp.197–201.
- Akbarnia, B.A. et al., 2011. Next Generation of Growth-Sparing Techniques: Preliminary Clinical Results of a Magnetically Controlled Growing Rod in 14 Patients. In 18th International Meeting on Advanced Spine Techniques.
- Akbarnia, B.A. et al., 2005. Dual growing rod technique for the treatment of progressive early-onset scoliosis: a multicenter study. *Spine*, 30(17 Suppl), pp.S46–57.
- Alaranta, H., Hurri, H., Heliövaara, M., Soukka, A. & Harju, R., 1994. Flexibility of the spine: normative values of goniometric and tape measurements. *Scandinavian Journal of Rehabilitation Medicine*, 26(3), pp.147–154.
- Alaranta, H., Hurri, H., Heliövaara, M., Soukka, A. & Harju, R., 1994. Non-dynamometric trunk performance tests: reliability and normative data. *Scandinavian Journal of Rehabilitation Medicine*, 26(4), pp.211–215.
- Albanese, M. & Pizzutillo, P.D., 1982. Family study of spondylolysis and spondylolisthesis. *Journal of Pediatric Orthopedics*, 2(5), pp.496–499.
- Allen, B.L. & Ferguson, R.L., 1982. L-rod instrumentation for scoliosis in cerebral palsy. *Journal of Pediatric Orthopedics*, 2(1), pp.87–96.
- Anderson, D. et al. eds., 2003. *Dorland's illustrated medical dictionary. 30th edition. Over 100 years in print*, Philadelphia: Saunders.
- Anderson, P.R. et al., 1985. Postoperative respiratory complications in non-idiopathic scoliosis. *Acta Anaesthesiologica Scandinavica*, 29(2), pp.186–192.
- Aprin, H. et al., 1982. Spine fusion in patients with spinal muscular atrophy. *The Journal of Bone and Joint Surgery. American volume*, 64(8), pp.1179–1187.
- Arun, R., Srinivas, S. & Mehdian, S.M.H., 2010. Scoliosis in Duchenne's muscular dystrophy: a changing trend in surgical management : a historical surgical outcome study comparing sublaminar, hybrid and pedicle screw instrumentation systems. *European Spine Journal*, 19(3), pp.376–383.
- Ascani, E. et al., 1986. Natural history of untreated idiopathic scoliosis after skeletal maturity. *Spine*, 11(8), pp.784–789.
- Aydogan, M. et al., 2008. Posterior vertebrectomy in kyphosis, scoliosis and kyphoscoliosis due to hemivertebra. *Journal of Pediatric Orthopaedics. Part B*, 17(1), pp.33–37.
- Ayvaz, M. et al., 2007. Safety and efficacy of posterior instrumentation for patients with congenital scoliosis and spinal dysraphism. *Journal of Pediatric Orthopedics*, 27(4), pp.380–386.
-

## References

---

- Barois, A., 1999. [Respiratory problems in severe scoliosis]. *Bulletin de l'Académie nationale de médecine*, 183(4), pp.721–730.
- Bartolozzi, P. et al., 2003. One-stage posterior decompression-stabilization and trans-sacral interbody fusion after partial reduction for severe L5-S1 spondylolisthesis. *Spine*, 28(11), pp.1135–1141.
- Beguiristáin, J.L. & Díaz-de-Rada, P., 2004. Spondylolisthesis in pre-school children. *Journal of Pediatric Orthopaedics. Part B*, 13(4), pp.225–230.
- Bell, D.F., Ehrlich, M.G. & Zaleske, D.J., 1988. Brace treatment for symptomatic spondylolisthesis. *Clinical Orthopaedics and Related Research*, (236), pp.192–198.
- Bell, D.F., Moseley, C.F. & Koreska, J., 1989. Unit rod segmental spinal instrumentation in the management of patients with progressive neuromuscular spinal deformity. *Spine*, 14(12), pp.1301–1307.
- Bess, S. et al., 2010. Complications of growing-rod treatment for early-onset scoliosis: analysis of one hundred and forty patients. *The Journal of Bone and Joint Surgery, American volume*, 92(15), pp.2533–2543.
- Bethem, D. et al., 1981. Spinal disorders of dwarfism. Review of the literature and report of eighty cases. *The Journal of Bone and Joint Surgery. American volume*, 63(9), pp.1412–1425.
- Betz, R.R. et al., 1999. Comparison of anterior and posterior instrumentation for correction of adolescent thoracic idiopathic scoliosis. *Spine*, 24(3), pp.225–239.
- Buerlein, M. et al., 2001. The critical stage of pinealectomy surgery after which scoliosis is produced in young chickens. *Spine*, 26(3), pp.237–240.
- Beutler, W.J. et al., 2003. The natural history of spondylolysis and spondylolisthesis: 45-year follow-up evaluation. *Spine*, 28(10), pp.1027–35; discussion 1035.
- Bjure, J., Grimby, G. & Nachemson, A., 1968. Correction of body height in predicting spirometric values in scoliotic patients. *Scandinavian Journal of Clinical and Laboratory Investigation*, 21(2), pp.191–192.
- Blount, W.P., 1965. Non-operative treatment of scoliosis with the Milwaukee brace. *Manitoba Medical Review*, 45(8), pp.478–480.
- Boachie-Adjei, O. & Bradford, D.S., 1991. Vertebral column resection and arthrodesis for complex spinal deformities. *Journal of Spinal Disorders*, 4(2), pp.193–202.
- Boachie-Adjei, O., Do, T. & Rawlins, B.A., 2002. Partial lumbosacral kyphosis reduction, decompression, and posterior lumbosacral transfixation in high-grade isthmic spondylolisthesis: clinical and radiographic results in six patients. *Spine*, 27(6), pp.E161–8.
- Bohlman, H.H. & Cook, S.S., 1982. One-stage decompression and posterolateral and interbody fusion for lumbosacral spondyloptosis through a posterior approach. Report of two cases. *The Journal of Bone and Joint Surgery, American volume*, 64(3), pp.415–418.
- Bollini, G. et al., 2006. Lumbosacral hemivertebrae resection by combined approach: medium- and long-term follow-up. *Spine*, 31(11), pp.1232–1239.
- Bonnett, C., Brown, J.C. & Grow, T., 1976. Thoracolumbar scoliosis in cerebral palsy. Results of surgical treatment. *The Journal of bone and joint surgery. American volume*, 58(3), pp.328–336.
- Boos, N. et al., 1993. Treatment of severe spondylolisthesis by reduction and pedicular fixation. A 4–6-year follow-up study. *Spine*, 18(12), pp.1655–1661.
- Bowen, J. & Lipton, G., 2001. *The Pediatric Spine* S. Weinstein, ed., Philadelphia: Lippincott Williams & Wilkins.
-

## References

---

- Boxall, D. et al., 1979. Management of severe spondylolisthesis in children and adolescents. *The Journal of bone and joint surgery. American volume*, 61(4), pp.479–495.
- Bradford, D.S., 1987. *Moe's Textbook of Scoliosis and Other Spinal Deformities* D. S. Bradford, J. E. Lonstein, & J. H. Moe, eds., Philadelphia: W.B. Saunders Company.
- Bradford, D.S. & Boachie-Adjei, O., 1990. One-stage anterior and posterior hemivertebral resection and arthrodesis for congenital scoliosis. *The Journal of bone and joint surgery. American volume*, 72(4), pp.536–540.
- Bradford, D.S. & Iza, J., 1985. Repair of the defect in spondylolysis or minimal degrees of spondylolisthesis by segmental wire fixation and bone grafting. *Spine*, 10(7), pp.673–679.
- Bradford, D.S. & Tribus, C.B., 1997. Vertebral column resection for the treatment of rigid coronal decompensation. *Spine*, 22(14), pp.1590–1599.
- Bradford, D.S., Heithoff, K.B. & Cohen, M., 1991. Intraspinal abnormalities and congenital spine deformities: a radiographic and MRI study. *Journal of pediatric orthopedics*, 11(1), pp.36–41.
- Branthwaite, M.A., 1986. Cardiorespiratory consequences of unfused idiopathic scoliosis. *British journal of diseases of the chest*, 80(4), pp.360–369.
- Buck, J.E., 1970. Direct repair of the defect in spondylolisthesis. Preliminary report. *The Journal of bone and joint surgery. British volume*, 52(3), pp.432–437.
- Bullmann, V. et al., 2003. Dual-rod correction and instrumentation of idiopathic scoliosis with the Halm-Zielke instrumentation. *Spine*, 28(12), pp.1306–1313.
- Bunnell, W.P., 1986. The natural history of idiopathic scoliosis before skeletal maturity. *Spine*, 11 (8), pp. 773-776
- Burkus, J.K. et al., 1992. Long-term evaluation of adolescents treated operatively for spondylolisthesis. A comparison of in situ arthrodesis only with in situ arthrodesis and reduction followed by immobilization in a cast. *The Journal of bone and joint surgery. American volume*, 74(5), pp.693–704.
- Burton, D.C., 2006. Smith-Petersen osteotomy of the spine. *Instructional course lectures*, 55, pp.577–582.
- Burton, D.C. et al., 2005. The treatment of large (>70 degrees) thoracic idiopathic scoliosis curves with posterior instrumentation and arthrodesis: when is anterior release indicated? *Spine*, 30(17), pp.1979–1984.
- Callahan, B.C., Georgopoulos, G. & Eilert, R.E., 1997. Hemivertebral excision for congenital scoliosis. *Journal of pediatric orthopedics*, 17(1), pp.96–99.
- Cambridge, W. & Drennan, J.C., 1987. Scoliosis associated with Duchenne muscular dystrophy. *Journal of pediatric orthopedics*, 7(4), pp.436–440.
- Campbell, R.M. et al., 2003. The characteristics of thoracic insufficiency syndrome associated with fused ribs and congenital scoliosis. *The Journal of bone and joint surgery. American volume*, 85-A(3), pp.399–408.
- Campbell, R.M., Smith, M.D. & Hell-Vocke, A.K., 2004. Expansion thoracoplasty: the surgical technique of opening-wedge thoracostomy. Surgical technique. *The Journal of bone and joint surgery. American volume*, 86-A Suppl 1, pp.51–64.
- Carr, A.J., Jefferson, R.J. & Turner-Smith, A.R., 1993. Family stature in idiopathic scoliosis. *Spine*, 18(1), pp.20–23.
- Chong, H.S. et al., 2011. Value of preoperative pulmonary function test in flaccid neuromuscular scoliosis surgery. *Spine*, 36(21), pp.E1391–4.
-

## References

---

- Cobb, J., 1948. Outline for the study of scoliosis. *Instr Course Lect AAOS*, pp.261–275.
- Coillard, C. et al., 2003. SpineCor—a non-rigid brace for the treatment of idiopathic scoliosis: post-treatment results. *European spine journal*, 12(2), pp.141–148.
- Cooke, P.H., Cole, W.G. & Carey, R.P., 1989. Dislocation of the hip in cerebral palsy. Natural history and predictability. *The Journal of bone and joint surgery. British volume*, 71(3), pp.441–446.
- Cotrel, Y., Dubousset, J. & Guillaumat, M., 1988. New universal instrumentation in spinal surgery. *Clinical orthopaedics and related research*, 227, pp.10–23.
- Cui, G. et al., 2012. Loss of apical vertebral derotation in adolescent idiopathic scoliosis: 2-year follow-up using multi-planar reconstruction computed tomography. *European spine journal, Epub*.
- Danielsson, A.J. & Nachemson, A.L., 2003a. Back pain and function 22 years after brace treatment for adolescent idiopathic scoliosis: a case-control study-part I. *Spine*, 28(18), pp.2078–85; discussion 2086.
- Danielsson, A.J. & Nachemson, A.L., 2003b. Back pain and function 23 years after fusion for adolescent idiopathic scoliosis: a case-control study-part II. *Spine*, 28(18), pp.E373–83.
- Danielsson, A.J. et al., 2010. Health-related quality of life in untreated versus brace-treated patients with adolescent idiopathic scoliosis: a long-term follow-up. *Spine*, 35(2), pp.199–205.
- Davies, G. & Reid, L., 1971. Effect of scoliosis on growth of alveoli and pulmonary arteries and on right ventricle. *Archives of disease in childhood*, 46(249), pp.623–632.
- Deguchi, M., Rapoff, A.J. & Zdeblick, T.A., 1999. Biomechanical comparison of spondylolysis fixation techniques. *Spine*, 24(4), pp.328–333.
- Descamps, H. et al., 1999. Modification of pelvic angle during the human growth [in French]. *Biom Hum Anthropol*, pp.59–63.
- Dickson, J.H. et al., 1995. Results of operative treatment of idiopathic scoliosis in adults. *The Journal of bone and joint surgery. American volume*, 77(4), pp.513–523.
- Dubousset, J., 2001. Congenital kyphosis and lordosis. In *The Pediatric Spine* S. Weinstein, ed., Philadelphia: Lippincott Williams & Wilkins, pp 179-191
- Dubousset, J., Herring, J.A. & Shufflebarger, H., 1989. The crankshaft phenomenon. *Journal of pediatric orthopedics*, 9(5), pp.541–550.
- Dwyer, A.F. & Schafer, M.F., 1974. Anterior approach to scoliosis. Results of treatment in fifty-one cases. *The Journal of bone and joint surgery. British volume*, 56(2), pp.218–224.
- Echenne, B. et al., 1988. Skin elastic fiber pathology and idiopathic scoliosis. *Journal of pediatric orthopedics*, 8(5), pp.522–528.
- Elsebai, H. B. et al., 2011. Safety and efficacy of growing rod technique for pediatric congenital spinal deformities. *Journal of pediatric orthopaedics*, 31(1), pp. 1-5.
- Fairbank, J.C. et al., 1980. The Oswestry low back pain disability questionnaire. *Physiotherapy*, 66(8), pp.271–273.
- Fan, J. et al., 2010. Direct repair of spondylolysis by TSRH's hook plus screw fixation and bone grafting: biomechanical study and clinical report. *Archives of orthopaedic and trauma surgery*, 130(2), pp.209–215.
- Farfan, H.F., Osteria, V. & Lamy, C., 1976. The mechanical etiology of spondylolysis and spondylolisthesis. *Clinical orthopaedics and related research*, (117), pp.40–55.
-



## References

---

- Fällström, K., Cochran, T. & Nachemson, A., 1986. Long-term effects on personality development in patients with adolescent idiopathic scoliosis. Influence of type of treatment. *Spine*, 11(7), pp.756–758.
- Floman, Y., 2000. Progression of lumbosacral isthmic spondylolisthesis in adults. *Spine*, 25(3), pp.342–347.
- Focarile, F.A. et al., 1991. Effectiveness of nonsurgical treatment for idiopathic scoliosis. Overview of available evidence. *Spine*, 16(4), pp.395–401.
- Fredrickson, B.E. et al., 1984. The natural history of spondylolysis and spondylolisthesis. *The Journal of bone and joint surgery. American volume*, 66(5), pp.699–707.
- Frennered, A.K. et al., 1991. Midterm follow-up of young patients fused in situ for spondylolisthesis. *Spine*, 16(4), pp.409–416.
- Fujii, K. et al., 2004. Union of defects in the pars interarticularis of the lumbar spine in children and adolescents. The radiological outcome after conservative treatment. *The Journal of bone and joint surgery. British volume*, 86(2), pp.225–231.
- Fusco, C. et al., 2011. Physical exercises in the treatment of adolescent idiopathic scoliosis: an updated systematic review. *Physiotherapy theory and practice*, 27(1), pp.80–114.
- Gadepalli, S.K. et al., 2011. Vertical expandable prosthetic titanium rib device insertion: does it improve pulmonary function? *Journal of pediatric surgery*, 46(1), pp.77–80.
- Gaines, R.W. & Nichols, W.K., 1985. Treatment of spondyloptosis by two stage L5 vertebrectomy and reduction of L4 onto S1. *Spine*, 10(7), pp.680–686.
- Galasko, C.S., Delaney, C. & Morris, P., 1992. Spinal stabilisation in Duchenne muscular dystrophy. *The Journal of bone and joint surgery. British volume*, 74(2), pp.210–214.
- Ganey, T.M., 2001. Development and Maturation of the Axial Skeleton. In S. L. Weinstein, ed. *The Pediatric Spine. Principles and Practice. Second Edition*. Philadelphia: Lippincott Williams & Wilkins, pp. 3–54.
- Gao, X. et al., 2007. CHD7 gene polymorphisms are associated with susceptibility to idiopathic scoliosis. *American journal of human genetics*, 80(5), pp.957–965.
- Gau, Y.L. et al., 1991. Luque-Galveston procedure for correction and stabilization of neuromuscular scoliosis and pelvic obliquity: a review of 68 patients. *Journal of spinal disorders*, 4(4), pp.399–410.
- Geck, M.J. et al., 2009. Comparison of surgical treatment in Lenke 5C adolescent idiopathic scoliosis: anterior dual rod versus posterior pedicle fixation surgery: a comparison of two practices. *Spine*, 34(18), pp.1942–1951.
- Gillet, P. & Petit, M., 1999. Direct repair of spondylolysis without spondylolisthesis, using a rod-screw construct and bone grafting of the pars defect. *Spine*, 24(12), pp.1252–1256.
- Gitelman, Y. et al., 2011. Pulmonary function in adolescent idiopathic scoliosis relative to the surgical procedure: a 10-year follow-up analysis. *Spine*, 36(20), pp.1665–1672.
- Giudici, F. et al., 2011. Long-term results of the direct repair of spondylolisthesis. *European spine journal*, 20 Suppl 1, pp.S115–20.
- Goldberg, C.J. et al., 2002. Long-term results from in situ fusion for congenital vertebral deformity. *Spine*, 27(6), pp.619–628.
- Goldberg, C.J. et al., 2003. Respiratory function and cosmesis at maturity in infantile-onset scoliosis. *Spine*, 28(20), pp.2397–2406.
- Goldberg, C.J., Dowling, F.E. & Fogarty, E.E., 1994a. Left thoracic scoliosis configurations. Why so different? *Spine*, 19(12), pp.1385–1389.
-

## References

- 
- Goldberg, M.S. et al., 1994b. The Ste-Justine Adolescent Idiopathic Scoliosis Cohort Study. Part II: Perception of health, self and body image, and participation in physical activities. *Spine*, 19(14), pp.1562–1572.
- Goldstein, J.D. et al., 1991. Spine injuries in gymnasts and swimmers. An epidemiologic investigation. *The American journal of sports medicine*, 19(5), pp.463–468.
- Graham, E.J. et al., 2000. Prospective pulmonary function evaluation following open thoracotomy for anterior spinal fusion in adolescent idiopathic scoliosis. *Spine*, 25(18), pp.2319–2325.
- Granata, C. et al., 1989. Spinal muscular atrophy: natural history and orthopaedic treatment of scoliosis. *Spine*, 14(7), pp.760–762.
- Grzegorzewski, A. & Kumar, S.J., 2000. In situ posterolateral spine arthrodesis for grades III, IV, and V spondylolisthesis in children and adolescents. *Journal of pediatric orthopedics*, 20(4), pp.506–511.
- Haheer, T.R. et al., 1999. Results of the Scoliosis Research Society instrument for evaluation of surgical outcome in adolescent idiopathic scoliosis. A multicenter study of 244 patients. *Spine*, 24(14), pp.1435–1440.
- Hall, J.E., Herndon, W.A. & Levine, C.R., 1981. Surgical treatment of congenital scoliosis with or without Harrington instrumentation. *The Journal of bone and joint surgery. American volume*, 63(4), pp.608–619.
- Hall, P. et al., 1979. Scoliosis and hydrocephalus in myelocle patients. The effects of ventricular shunting. *Journal of neurosurgery*, 50(2), pp.174–178.
- Hammerberg, K.W., Rodts, M.F. & DeWald, R.L., 1988. Zielke instrumentation. *Orthopedics*, 11(10), pp.1365–1371.
- Hamzaoglu, A. et al., 2011. Posterior vertebral column resection in severe spinal deformities: a total of 102 cases. *Spine*, 36(5), pp.E340–4.
- Harrington, P.R., 1962. Treatment of scoliosis. Correction and internal fixation by spine instrumentation. *The Journal of bone and joint surgery. American volume*, 44-A, pp.591–610.
- Harris, I.E. & Weinstein, S.L., 1987. Long-term follow-up of patients with grade-III and IV spondylolisthesis. Treatment with and without posterior fusion. *The Journal of bone and joint surgery. American volume*, 69(7), pp.960–969.
- Hästbacka, J. et al., 1994. The diastrophic dysplasia gene encodes a novel sulfate transporter: positional cloning by fine-structure linkage disequilibrium mapping. *Cell*, 78(6), pp.1073–1087.
- Hedequist, D., Emans, J. & Proctor, M., 2009. Three rod technique facilitates hemivertebra wedge excision in young children through a posterior only approach. *Spine*, 34(6), pp.E225–9.
- Hedequist, D.J., 2009. Instrumentation and fusion for congenital spine deformities. *Spine*, 34(17), pp.1783–1790.
- Hedequist, D.J., Hall, J.E. & Emans, J.B., 2005. Hemivertebra excision in children via simultaneous anterior and posterior exposures. *Journal of pediatric orthopedics*, 25(1), pp.60–63.
- Hee, H.-T., Yu, Z.-R. & Wong, H.-K., 2007. Comparison of segmental pedicle screw instrumentation versus anterior instrumentation in adolescent idiopathic thoracolumbar and lumbar scoliosis. *Spine*, 32(14), pp.1533–1542.
- Helenius, I., 2009. [Surgical treatment of back problems of a growing child]. *Duodecim; lääketieteellinen aikakauskirja*, 125(11), pp.1168–1175.
- Helenius, I. et al., 2002. Comparison of long-term functional and radiologic outcomes after Harrington instrumentation and spondylodesis in adolescent idiopathic scoliosis: a review of 78 patients. *Spine*, 27(2), pp.176–180.
-

## References

---

- Helenius, I. et al., 2006. Posterolateral, anterior, or circumferential fusion in situ for high-grade spondylolisthesis in young patients: a long-term evaluation using the Scoliosis Research Society questionnaire. *Spine*, 31(2), pp.190–196.
- Helenius, I. et al., 2005. Scoliosis research society outcome instrument in evaluation of long-term surgical results in spondylolysis and low-grade isthmic spondylolisthesis in young patients. *Spine*, 30(3), pp.336–341.
- Helenius, I., Remes, V. & Poussa, M., 2008a. Uninstrumented in situ fusion for high-grade childhood and adolescent isthmic spondylolisthesis: long-term outcome. Surgical technique. *The Journal of bone and joint surgery. American volume*, 90 Suppl 2 Pt 1, pp.145–152.
- Helenius, I., Remes, V., Lamberg, T., et al., 2008b. Long-term health-related quality of life after surgery for adolescent idiopathic scoliosis and spondylolisthesis. *The Journal of Bone and Joint Surgery*, 90(6), pp.1231–1239.
- Helenius, I., Remes, V., Lohman, M., et al., 2003a. Total knee arthroplasty in patients with diastrophic dysplasia. *The Journal of bone and joint surgery. American volume*, 85-A(11), pp.2097–2102.
- Helenius, I., Remes, V., Tallroth, K., et al., 2003b. Total hip arthroplasty in diastrophic dysplasia. *The Journal of bone and joint surgery. American volume*, 85-A(3), pp.441–447.
- Helgeson, M.D. et al., 2010. Evaluation of proximal junctional kyphosis in adolescent idiopathic scoliosis following pedicle screw, hook, or hybrid instrumentation. *Spine*, 35(2), pp.177–181.
- Herbinaux, G., 1782. *Traite sur diverses accouchements laborieux, et sur les polypes de la matrice*, Bruxelles: JL De Boubiers.
- Herman, R. et al., 1985. Idiopathic scoliosis and the central nervous system: a motor control problem. The Harrington lecture, 1983. Scoliosis Research Society. *Spine*, 10(1), pp.1–14.
- Herring, J.A., 1978. The spinal disorders in diastrophic dwarfism. *The Journal of bone and joint surgery. American volume*, 60(2), pp.177–182.
- Holte, D.C. et al., 1995. Excision of hemivertebrae and wedge resection in the treatment of congenital scoliosis. *The Journal of bone and joint surgery. American volume*, 77(2), pp.159–171.
- Hresko, M.T. et al., 2007. Classification of high-grade spondylolistheses based on pelvic version and spine balance: possible rationale for reduction. *Spine*, 32(20), pp.2208–2213.
- Hsu, J.D., 1983. The natural history of spine curvature progression in the nonambulatory Duchenne muscular dystrophy patient. *Spine*, 8(7), pp.771–775.
- Hu, S. & Bradford, D., 2001. *The Pediatric Spine* S. Weinstein, ed., Philadelphia: Lippincott Williams & Wilkins.
- Hwang, S.W. et al., 2012. Impact of direct vertebral body derotation on rib prominence: are preoperative factors predictive of changes in rib prominence? *Spine*, 37(2), pp.E86–9.
- Inal-Ince, D. et al., 2009. Effects of scoliosis on respiratory muscle strength in patients with neuromuscular disorders. *The spine journal : official journal of the North American Spine Society*, 9(12), pp.981–986.
- Islam, N.C. et al., 2001. Extension of fusions to the pelvis in idiopathic scoliosis. *Spine*, 26(2), pp.166–173.
- James, J.I.P., 1956. Paralytic scoliosis. *The Journal of bone and joint surgery. British volume*, 38-B(3), pp.660–685.
- Jenkins, J.G. et al., 1982. Evaluation of pulmonary function in muscular dystrophy patients requiring spinal surgery. *Critical care medicine*, 10(10), pp.645–649.
-

## References

---

- Jevsevar, D.S. & Karlin, L.I., 1993. The relationship between preoperative nutritional status and complications after an operation for scoliosis in patients who have cerebral palsy. *The Journal of bone and joint surgery. American volume*, 75(6), pp.880–884.
- Johnson, G.V. & Thompson, A.G., 1992. The Scott wiring technique for direct repair of lumbar spondylolysis. *The Journal of bone and joint surgery. British volume*, 74(3), pp.426–430.
- Kaitila, I., 1980. Diastrophic dysplasia. In A. Eriksson et al., eds. *Population structure and genetic disorders*. London: Academic Press, pp. 610–613.
- Kaitila, I. et al., 1989. Clinical expression and course of diastrophic dysplasia. *American journal of medical genetics*, p.141.
- Kajiura, K. et al., 2001. Slippage mechanism of pediatric spondylolysis: biomechanical study using immature calf spines. *Spine*, 26(20), pp.2208–12; discussion 2212–3.
- Kakiuchi, M., 1997. Repair of the defect in spondylolysis. Durable fixation with pedicle screws and laminar hooks. *The Journal of bone and joint surgery. American volume*, 79(6), pp.818–825.
- Kalamchi, A. et al., 1976. Halo-pelvic distraction apparatus. An analysis of one hundred and fifty consecutive patients. *The Journal of bone and joint surgery. American volume*, 58(8), pp.1119–1125.
- Kalra, K., Kohli, S. & Dhar, S., 2010. A modified Gaines procedure for spondyloptosis. *The Journal of bone and joint surgery. British volume*, 92(11), pp.1589–1591.
- Kane, W.J., 1977. Scoliosis prevalence: a call for a statement of terms. *Clinical orthopaedics and related research*, (126), pp.43–46.
- Kaneda, K. et al., 1996. New anterior instrumentation for the management of thoracolumbar and lumbar scoliosis. Application of the Kaneda two-rod system. *Spine*, 21(10), pp.1250–61; discussion 1261–2.
- Kang, G.-R., Suh, S.-W. & Lee, I.-O., 2011. Preoperative predictors of postoperative pulmonary complications in neuromuscular scoliosis. *Journal of orthopaedic science : official journal of the Japanese Orthopaedic Association*, 16(2), pp.139–147.
- Karol, L.A., 2011. Early definitive spinal fusion in young children: what we have learned. *Clinical orthopaedics and related research*, 469(5), pp.1323–1329.
- Karol, L.A. et al., 2008. Pulmonary function following early thoracic fusion in non-neuromuscular scoliosis. *The Journal of bone and joint surgery. American volume*, 90(6), pp.1272–1281.
- Kaspiris, A. et al., 2011. Surgical and conservative treatment of patients with congenital scoliosis: a search for long-term results. *Scoliosis*, 6, p.12.
- Kaspiris, A., Grivas, T.B. & Weiss, H.-R., 2008. Congenital scoliosis in monozygotic twins: case report and review of possible factors contributing to its development. *Scoliosis*, 3, p.17.
- Kawakami, N. et al., 2009. Classification of congenital scoliosis and kyphosis: a new approach to the three-dimensional classification for progressive vertebral anomalies requiring operative treatment. *Spine*, 34(17), pp.1756–1765.
- Kearon, C. et al., 1993. Factors determining pulmonary function in adolescent idiopathic thoracic scoliosis. *The American review of respiratory disease*, 148(2), pp.288–294.
- Keeler, K.A. et al., 2010. Spinal fusion for spastic neuromuscular scoliosis: is anterior releasing necessary when intraoperative halo-femoral traction is used? *Spine*, 35(10), pp.E427–33.
- Kesling, K.L. & Reinker, K.A., 1997. Scoliosis in twins. A meta-analysis of the literature and report of six cases. *Spine*, 22(17), pp.2009–14; discussion 2015.
-

## References

---

- Kilian, H., 1854. *Schilderungen neuer Beckenformen und ihres Verhaltens im Leben*, Mannheim: Bassenman und Mathy.
- Kim, K.-T., Park, K.-J. & Lee, J.-H., 2009. Osteotomy of the spine to correct the spinal deformity. *Asian spine journal*, 3(2), pp.113–123.
- Kim, Y.J. et al., 2006. Comparative analysis of pedicle screw versus hybrid instrumentation in posterior spinal fusion of adolescent idiopathic scoliosis. *Spine*, 31(3), pp.291–298.
- Kim, Y.J. et al., 2004. Free hand pedicle screw placement in the thoracic spine: is it safe? *Spine*, 29(3), pp.333–42; discussion 342.
- Kim, Y.J. et al., 2001. Surgical treatment of congenital kyphosis. *Spine*, 26(20), pp.2251–2257.
- Kinali, M. et al., 2006. Management of scoliosis in Duchenne muscular dystrophy: a large 10-year retrospective study. *Developmental medicine and child neurology*, 48(6), pp.513–518.
- King, A.G. et al., 2000. Video-assisted thoracoscopic surgery in the prone position. *Spine*, 25(18), pp.2403–2406.
- King, J.D. & Lowery, G.L., 1991. Results of lumbar hemivertebral excision for congenital scoliosis. *Spine*, 16(7), pp.778–782.
- Klemme, W.R., Polly, D.W. & Orchowski, J.R., 2001. Hemivertebral excision for congenital scoliosis in very young children. *Journal of pediatric orthopedics*, 21(6), pp.761–764.
- Koller, H. et al., 2012. The impact of halo-gravity traction on curve rigidity and pulmonary function in the treatment of severe and rigid scoliosis and kyphoscoliosis: a clinical study and narrative review of the literature. *European spine journal*, 21(3), pp.514–529.
- Kopits, S.E., 1976. Orthopedic complications of dwarfism. *Clinical orthopaedics and related research*, (114), pp.153–179.
- Kuklo, T.R. et al., 2005. Accuracy and efficacy of thoracic pedicle screws in curves more than 90 degrees. *Spine*, 30(2), pp.222–226.
- Kurz, L.T. et al., 1983. Correlation of scoliosis and pulmonary function in Duchenne muscular dystrophy. *Journal of pediatric orthopedics*, 3(3), pp.347–353.
- Labelle, H. et al., 2004. Spondylolisthesis, pelvic incidence, and spinopelvic balance: a correlation study. *Spine*, 29(18), pp.2049–2054.
- Lam, T.P. et al., 2011. Abnormal bone quality in adolescent idiopathic scoliosis: a case-control study on 635 subjects and 269 normal controls with bone densitometry and quantitative ultrasound. *Spine*, 36(15), pp.1211–1217.
- Lamberg, T. et al., 2007. Uninstrumented in situ fusion for high-grade childhood and adolescent isthmic spondylolisthesis: long-term outcome. *The Journal of bone and joint surgery. American volume*, 89(3), pp.512–518.
- Lambl, D., 1858. Das Wesen und die Entstehung der Spondylolisthesis. *Beitr Geburtsh Gyn*, p.179.
- Lamy, M. & Maroteaux, P., 1960. Le nanisme diastrophique. *Presse Med*, 68, p.1978.
- Larsson, E.-L.C. et al., 2005. Long-term follow-up of functioning after spinal surgery in patients with neuromuscular scoliosis. *Spine*, 30(19), pp.2145–2152.
- Laurent, L.E., 1958. Spondylolithesis a study of 53 cases treated by spine fusion and 32 cases treated by laminectomy. *Acta orthopaedica Scandinavica. Supplementum*, 35, pp.1–45.
-

## References

---

- Laurent, L.E. & Einola, S., 1961. Spondylolisthesis in children and adolescents. *Acta orthopaedica Scandinavica*, 31, pp.45–64.
- Laurent, L.E. & Osterman, K., 1969. Spondylolisthesis in children and adolescents: a study of 173 cases. *Acta orthopaedica Belgica*, 35(3), pp.717–727.
- Lazar, R.D. & Hall, J.E., 1999. Simultaneous anterior and posterior hemivertebra excision. *Clinical orthopaedics and related research*, (364), pp.76–84.
- Lee, S.-M., Suk, S.-I. & Chung, E.-R., 2004. Direct vertebral rotation: a new technique of three-dimensional deformity correction with segmental pedicle screw fixation in adolescent idiopathic scoliosis. *Spine*, 29(3), pp.343–349.
- Lehmer, S.M., Steffee, A.D. & Gaines, R.W., 1994. Treatment of L5-S1 spondyloptosis by staged L5 resection with reduction and fusion of L4 onto S1 (Gaines procedure). *Spine*, 19(17), pp.1916–1925.
- Lenke, L.G., 2003. Anterior endoscopic discectomy and fusion for adolescent idiopathic scoliosis. *Spine*, 28(15 Suppl), pp.S36–43.
- Lenke, L.G. & Dobbs, M.B., 2007. Management of juvenile idiopathic scoliosis. *The Journal of bone and joint surgery. American volume*, 89 Suppl 1, pp.55–63.
- Lenke, L.G. et al., 2001. Adolescent idiopathic scoliosis: a new classification to determine extent of spinal arthrodesis. *The Journal of bone and joint surgery. American volume*, 83-A(8), pp.1169–1181.
- Lenke, L.G. et al., 2009. Posterior vertebral column resection for severe pediatric deformity: minimum two-year follow-up of thirty-five consecutive patients. *Spine*, 34(20), pp.2213–2221.
- Lenke, L.G. et al., 2004. Prospective pulmonary function comparison of open versus endoscopic anterior fusion combined with posterior fusion in adolescent idiopathic scoliosis. *Spine*, 29(18), pp.2055–2060.
- Lenke, L.G. et al., 1992. Results of in situ fusion for isthmic spondylolisthesis. *Journal of spinal disorders*, 5(4), pp.433–442.
- Leone, A. et al., 2011. Lumbar spondylolysis: a review. *Skeletal radiology*, 40(6), pp.683–700.
- Leung, Y.L. & Buxton, N., 2005. Combined diastematomyelia and hemivertebra: a review of the management at a single centre. *The Journal of bone and joint surgery. British volume*, 87(10), pp.1380–1384.
- Libson, E., Bloom, R.A. & Dinari, G., 1982. Symptomatic and asymptomatic spondylolysis and spondylolisthesis in young adults. *International orthopaedics*, 6(4), pp.259–261.
- Liljenqvist, U. et al., 2002. Comparative analysis of pedicle screw and hook instrumentation in posterior correction and fusion of idiopathic thoracic scoliosis. *European spine journal*, 11(4), pp.336–343.
- Lindseth, R., 2001. Myelomeningocele. In *The Pediatric Spine* S. Weinstein, ed., Philadelphia: Lippincott Williams & Wilkins, pp. 845-868
- Lonstein, J., 2001. Neuromuscular scoliosis. In *The Pediatric Spine* S. Weinstein, ed., Lippincott Williams & Wilkins, pp. 789-807
- Lonstein, J.E., 1999. Congenital spine deformities: scoliosis, kyphosis, and lordosis. *The Orthopedic clinics of North America*, 30(3), pp.387–405– viii.
- Lonstein, J.E. & Akbarnia, A., 1983. Operative treatment of spinal deformities in patients with cerebral palsy or mental retardation. An analysis of one hundred and seven cases. *The Journal of bone and joint surgery. American volume*, 65(1), pp.43–55.
- Lopez-Sosa, F., Guille, J.T. & Bowen, J.R., 1995. Rotation of the spine in congenital scoliosis. *Journal of*
-

## References

---

*pediatric orthopedics*, 15(4), pp.528–534.

Louis, M.-L. et al., 2010. Congenital scoliosis: a frontal plane evaluation of 251 operated patients 14 years old or older at follow-up. *Orthopaedics & traumatology, surgery & research : OTSR*, 96(7), pp.741–747.

Lowe, T.G. et al., 2003. Anterior single-rod instrumentation of the thoracic and lumbar spine: saving levels. *Spine*, 28(20), pp.S208–16.

Lowe, T.G. et al., 2000. Etiology of idiopathic scoliosis: current trends in research. *The Journal of bone and joint surgery. American volume*, 82-A(8), pp.1157–1168.

Lubicky, J.P. et al., 2011. Instrumentation constructs in pediatric patients undergoing deformity correction correlated with scoliosis research society scores. *Spine*, 36(20), pp.1692–1700.

MacEwen, G.D., Bunnell, W.P. & Sriram, K., 1975. Acute neurological complications in the treatment of scoliosis. A report of the Scoliosis Research Society. *The Journal of bone and joint surgery. American volume*, 57(3), pp.404–408.

Mackel, J. & Lindseth, R., 1975. Scoliosis in Myelodysplasia. *The Journal of bone and joint surgery. American volume*, 57-A(7), p.1031.

Madan, S. & Boeree, N.R., 2002. Outcome of posterior lumbar interbody fusion versus posterolateral fusion for spondylytic spondylolisthesis. *Spine*, 27(14), pp.1536–1542.

Maruyama, T., Grivas, T.B. & Kaspiris, A., 2011. Effectiveness and outcomes of brace treatment: a systematic review. *Physiotherapy theory and practice*, 27(1), pp.26–42.

Master, D.L., Connie, P.-K., et al., 2011a. Wound infections after surgery for neuromuscular scoliosis: risk factors and treatment outcomes. *Spine*, 36(3), pp.E179–85.

Master, D.L., Son-Hing, J.P., et al., 2011b. Risk factors for major complications after surgery for neuromuscular scoliosis. *Spine*, 36(7), pp.564–571.

Matsuyama, Y., Winter, R.B. & Lonstein, J.E., 1999. The spine in diastrophic dysplasia. The surgical arthrodesis of thoracic and lumbar deformities in 21 patients. *Spine*, 24(22), pp.2325–2331.

Mayer, O.H. & Redding, G., 2009. Early changes in pulmonary function after vertical expandable prosthetic titanium rib insertion in children with thoracic insufficiency syndrome. *Journal of pediatric orthopedics*, 29(1), pp.35–38.

McCall, R.E. & Hayes, B., 2005. Long-term outcome in neuromuscular scoliosis fused only to lumbar 5. *Spine*, 30(18), pp.2056–2060.

McCarthy, R.E., 1999. Management of neuromuscular scoliosis. *The Orthopedic clinics of North America*, 30(3), pp.435–49, viii.

McCarthy, R.E. et al., 2010. Shilla growing rods in a caprine animal model: a pilot study. *Clinical orthopaedics and related research*, 468(3), pp.705–710.

McDonald, C.M. et al., 1995. Profiles of neuromuscular diseases. Duchenne muscular dystrophy. *American journal of physical medicine & rehabilitation / Association of Academic Physiatrists*, 74(5 Suppl), pp.S70–92.

McGuire, R.A. & Amundson, G.M., 1993. The use of primary internal fixation in spondylolisthesis. *Spine*, 18(12), pp.1662–1672.

McMaster, M., 2001. Congenital scoliosis. In *The Pediatric Spine* S. Weinstein, ed., Philadelphia: Lippincott Williams & Wilkins, pp. 161-177

McMaster, M.J., 1998. Congenital scoliosis caused by a unilateral failure of vertebral segmentation with

---

## References

---

contralateral hemivertebrae. *Spine*, 23(9), pp.998–1005.

McMaster, M.J. & Ohtsuka, K., 1982. The natural history of congenital scoliosis. A study of two hundred and fifty-one patients. *The Journal of bone and joint surgery. American volume*, 64(8), pp.1128–1147.

McMaster, M.J. & Singh, H., 1999. Natural history of congenital kyphosis and kyphoscoliosis. A study of one hundred and twelve patients. *The Journal of bone and joint surgery. American volume*, 81(10), pp.1367–1383.

McMaster, M.J. et al., 2007. Lung function in congenital kyphosis and kyphoscoliosis. *Journal of spinal disorders & techniques*, 20(3), pp.203–208.

McMaster, W.C. & Clayton, K., 1980. Spinal bracing in the institutionalized person with scoliosis. *Spine*, 5(5), pp.459–462.

Merlini, L. et al., 1989. Scoliosis in spinal muscular atrophy: natural history and management. *Developmental medicine and child neurology*, 31(4), pp.501–508.

Meyerding, H., 1932. Spondylolisthesis. *Surg Gynec Obstetr*, pp.371–377.

Miller, A., Temple, T. & Miller, F., 1996a. Impact of orthoses on the rate of scoliosis progression in children with cerebral palsy. *Journal of pediatric orthopedics*, 16(3), pp.332–335.

Miller, N.H. et al., 1996b. Genetic analysis of structural elastic fiber and collagen genes in familial adolescent idiopathic scoliosis. *Journal of orthopaedic research*, 14(6), pp.994–999.

Min, K., Waelchli, B. & Hahn, F., 2005. Primary thoracoplasty and pedicle screw instrumentation in thoracic idiopathic scoliosis. *European spine journal*, 14(8), pp.777–782.

Mladenov, K., Kunkel, P. & Stuecker, R., 2012. Hemivertebra resection in children, results after single posterior approach and after combined anterior and posterior approach: a comparative study. *European spine journal*, 21(3), pp.506–513.

Modi, H.N. et al., 2010. Evaluation of pelvic fixation in neuromuscular scoliosis: a retrospective study in 55 patients. *International orthopaedics*, 34(1), pp.89–96.

Modi, H.N. et al., 2008. Treatment of neuromuscular scoliosis with posterior-only pedicle screw fixation. *Journal of orthopaedic surgery and research*, 3, p.23.

Modi, H.N., Hong, J.-Y., et al., 2009a. Surgical correction and fusion using posterior-only pedicle screw construct for neuropathic scoliosis in patients with cerebral palsy: a three-year follow-up study. *Spine*, 34(11), pp.1167–1175.

Modi, H.N., Suh, S.-W., et al., 2009b. Surgical complications in neuromuscular scoliosis operated with posterior- only approach using pedicle screw fixation. *Scoliosis*, 4, p.11.

Molinari, R.W. et al., 2002. Anterior column support in surgery for high-grade, isthmic spondylolisthesis. *Clinical orthopaedics and related research*, (394), pp.109–120.

Molinari, R.W. et al., 1999. Complications in the surgical treatment of pediatric high-grade, isthmic dysplastic spondylolisthesis. A comparison of three surgical approaches. *Spine*, 24(16), pp.1701–1711.

Monticelli, G. & Ascani, E., 1975. Spondylolysis and spondylolysthesis. *Acta orthopaedica Scandinavica*, 46(3), pp.498–506.

Moore, K. & Dalley, A. eds., 2006. *Clinically oriented anatomy. Fifth Edition*, Philadelphia: Lippincott Williams & Wilkins.

Morita, T. et al., 1995. Lumbar spondylolysis in children and adolescents. *The Journal of bone and joint surgery. British volume*, 77(4), pp.620–625.

---



## References

---

- Möller, H. & Hedlund, R., 2000. Instrumented and noninstrumented posterolateral fusion in adult spondylolisthesis--a prospective randomized study: part 2. *Spine*, 25(13), pp.1716–1721.
- Murans, G., Gustavsson, B. & Saraste, H., 2010. One-stage major spine deformity correction surgery: comparison between groups with and without additional neurosurgical intervention, with more than 24 months of follow-up. Clinical article. *Journal of neurosurgery*. *Spine*, 13(6), pp.666–671.
- Muschik, M., Zippel, H. & Perka, C., 1997. Surgical management of severe spondylolisthesis in children and adolescents. Anterior fusion in situ versus anterior spondylodesis with posterior transpedicular instrumentation and reduction. *Spine*, 22(17), pp.2036–42; discussion 2043.
- Muschik, M.T., Kimmich, H. & Demmel, T., 2006. Comparison of anterior and posterior double-rod instrumentation for thoracic idiopathic scoliosis: results of 141 patients. *European spine journal*, 15(7), pp.1128–1138.
- Nachemson, A.L. & Peterson, L.E., 1995. Effectiveness of treatment with a brace in girls who have adolescent idiopathic scoliosis. A prospective, controlled study based on data from the Brace Study of the Scoliosis Research Society. *The Journal of bone and joint surgery. American volume*, 77(6), pp.815–822.
- Nakamura, H. et al., 2002. Single-stage excision of hemivertebrae via the posterior approach alone for congenital spine deformity: follow-up period longer than ten years. *Spine*, 27(1), pp.110–115.
- Negrini, S. et al., 2012. 2011 SOSORT Guidelines: Orthopaedic and Rehabilitation Treatment of Idiopathic Scoliosis During Growth. *Scoliosis*, 7(1), p.3.
- Negrini, S. et al., 2008. Specific exercises reduce brace prescription in adolescent idiopathic scoliosis: a prospective controlled cohort study with worst-case analysis. *Journal of rehabilitation medicine*, 40(6), pp.451–455.
- Nicol, R.O. & Scott, J.H., 1986. Lytic spondylolysis. Repair by wiring. *Spine*, 11(10), pp.1027–1030.
- Niemeyer, T. et al., 2000. Anterior thoracoscopic surgery followed by posterior instrumentation and fusion in spinal deformity. *European spine journal*, 9(6), pp.499–504.
- Nissinen, M. et al., 1989. Trunk asymmetry and scoliosis, Anthropometric measurements in prepuberal school children. *Acta paediatrica Scandinavica*, 78(5), pp.747–753.
- Noonan, K.J., 2001. Nonsurgical techniques of AIS. In S. L. Weinstein, ed. *Pediatric Spine. Principles and Practice. Second Edition*. Philadelphia: Lippincott Williams and Wilkins.
- O'Brien, M., Kuklo, T. & Blanke, K. eds., 2004. *Spinal Deformity Study Group. Radiographic Measurement Manual*, Memphis: Medtronic Sofamor Danek Inc.
- Ogilvie, J.W. et al., 2006. The search for idiopathic scoliosis genes. *Spine*, 31(6), pp.679–681.
- Olgun, Z.D. et al., 2012. The Effect of Pedicle Screw Insertion at a Young Age on Pedicle and Canal Development. *Spine*.
- Osebold, W.R. et al., 1982. Surgical treatment of paralytic scoliosis associated with myelomeningocele. *The Journal of bone and joint surgery. American volume*, 64(6), pp.841–856.
- Osterman, K. et al., 1993. Isthmic spondylolisthesis in symptomatic and asymptomatic subjects, epidemiology, and natural history with special reference to disk abnormality and mode of treatment. *Clinical orthopaedics and related research*, (297), pp.65–70.
- Padman, R. & McNamara, R., 1990. Postoperative pulmonary complications in children with neuromuscular scoliosis who underwent posterior spinal fusion. *Delaware medical journal*, 62(5), pp.999–1003.
- Parent, S., Newton, P.O. & Wenger, D.R., 2005. Adolescent idiopathic scoliosis: etiology, anatomy, natural
-

## References

---

history, and bracing. *Instructional course lectures*, 54, pp.529–536.

Pedersen, A.K. & Hagen, R., 1988. Spondylolysis and spondylolisthesis. Treatment by internal fixation and bone-grafting of the defect. *The Journal of bone and joint surgery. American volume*, 70(1), pp.15–24.

Pedrini, V.A., Ponseti, I.V. & Dohrman, S.C., 1973. Glycosaminoglycans of intervertebral disc in idiopathic scoliosis. *The Journal of laboratory and clinical medicine*, 82(6), pp.938–950.

Pehrsson, K. et al., 1992. Long-term follow-up of patients with untreated scoliosis. A study of mortality, causes of death, and symptoms. *Spine*, 17(9), pp.1091–1096.

Peltonen, J. et al., 1999. The knee joint in diastrophic dysplasia. A clinical and radiological study. *The Journal of bone and joint surgery. British volume*, 81(4), pp.625–631.

Persson-Bunke, M. et al., 2012. Scoliosis in a total population of children with cerebral palsy. *Spine*, 37(12), pp.E708–13.

Phalen, G. & Dickson, J., 1961. Spondylolisthesis and tight hamstrings. *The Journal of bone and joint surgery. American volume*, pp.505–512.

Piazzolla, A. et al., 2011. Cotrel-Dubousset instrumentation in neuromuscular scoliosis. *European spine journal*, 20 Suppl 1, pp.S75–84.

Piggott, H., 1980. The natural history of scoliosis in myelodysplasia. *The Journal of bone and joint surgery. British volume*, 62-B(1), pp.54–58.

Pizzutillo, P.D. & Hummer, C.D., 1989. Nonoperative treatment for painful adolescent spondylolysis or spondylolisthesis. *Journal of pediatric orthopedics*, 9(5), pp.538–540.

Pizzutillo, P.D., Mirenda, W. & MacEwen, G.D., 1986. Posterolateral fusion for spondylolisthesis in adolescence. *Journal of pediatric orthopedics*, 6(3), pp.311–316.

Pool, R.D., 1986. Congenital scoliosis in monozygotic twins. Genetically determined or acquired in utero? *The Journal of bone and joint surgery. British volume*, 68(2), pp.194–196.

Potter, B.K., Freedman, B.A., et al., 2005. Transforaminal lumbar interbody fusion: clinical and radiographic results and complications in 100 consecutive patients. *Journal of spinal disorders & techniques*, 18(4), pp.337–346.

Pourquié, O., 2011. Vertebrate segmentation: from cyclic gene networks to scoliosis. *Cell*, 145(5), pp.650–663.

Poussa, M. et al., 1993. Surgical treatment of severe isthmic spondylolisthesis in adolescents. Reduction or fusion in situ. *Spine*, 18(7), pp.894–901.

Poussa, M. et al., 1991. The spine in diastrophic dysplasia. *Spine*, 16(8), pp.881–887.

Poussa, M. et al., 2006. Treatment of severe spondylolisthesis in adolescence with reduction or fusion in situ: long-term clinical, radiologic, and functional outcome. *Spine*, 31(5), pp.583–90; discussion 591–2.

Rajasekaran, S. et al., 2010. Intraspinous anomalies in scoliosis: An MRI analysis of 177 consecutive scoliosis patients. *Indian journal of orthopaedics*, 44(1), pp.57–63.

Ramirez, N. et al., 2009. The Vertical Expandable Prosthetic Titanium Rib in the treatment of spinal deformity due to progressive early onset scoliosis. *Journal of pediatric orthopaedics. Part B*, 18(4), pp.197–203.

Rawlins, B.A. et al., 1996. Reconstructive spine surgery in pediatric patients with major loss in vital capacity. *Journal of pediatric orthopedics*, 16(3), pp.284–292.

Reames, D.L. et al., 2011. Complications in the surgical treatment of 19,360 cases of pediatric scoliosis: a

---

## References

---

- review of the Scoliosis Research Society Morbidity and Mortality database. *Spine*, 36(18), pp.1484–1491.
- Remes, V. et al., 1999. Cervical kyphosis in diastrophic dysplasia. *Spine*, 24(19), pp.1990–1995.
- Remes, V. et al., 2006. Long-term outcome after posterolateral, anterior, and circumferential fusion for high-grade isthmic spondylolisthesis in children and adolescents: magnetic resonance imaging findings after average of 17-year follow-up. *Spine*, 31(21), pp.2491–2499.
- Remes, V., Helenius, I., et al., 2002a. Lung function in diastrophic dysplasia. *Pediatric pulmonology*, 33(4), pp.277–282.
- Remes, V., Poussa, M. & Peltonen, J., 2001a. Scoliosis in patients with diastrophic dysplasia: a new classification. *Spine*, 26(15), pp.1689–1697.
- Remes, V., Tervahartiala, P., et al., 2001b. Thoracic and lumbar spine in diastrophic dysplasia: a clinical and magnetic resonance imaging analysis. *Spine*, 26(2), pp.187–195.
- Remes, V.M., Hästbacka, J.R., et al., 2002b. Does genotype predict development of the spinal deformity in patients with diastrophic dysplasia? *European spine journal*, 11(4), pp.327–331.
- Rinella, A. et al., 2004. Comparison of SRS questionnaire results submitted by both parents and patients in the operative treatment of idiopathic scoliosis. *Spine*, 29(3), pp.303–310.
- Riseborough, E.J. & Wynne-Davies, R., 1973. A genetic survey of idiopathic scoliosis in Boston, Massachusetts. *The Journal of bone and joint surgery. American volume*, 55(5), pp.974–982.
- Roaf, R., 1963. The Treatment of Progressive Scoliosis By Unilateral Growth-Arrest. *The Journal of bone and joint surgery. British volume*, 45, pp.637–651.
- Robert, H., 1855. Eine eigentümliche angeborene Lordose, wahrscheinlich bedingt durch eine Verschiebung des Körpers des letzten Lendenwirbels auf die vordere Fläche des ersten Kreuzbeinwirbels (Spondylolisthesis Kilian) nebst Bemerkungen über die Mechanik dieser Beckenformation. *Monatsschrift für Geburtskunde und Erkrankungen*, pp.81–94.
- Roberto, R. et al., 2011. The natural history of cardiac and pulmonary function decline in patients with duchenne muscular dystrophy. *Spine*, 36(15), pp.E1009–17.
- Roberts, A.P. et al., 1988. Spondylothoracic and spondylocostal dysostosis. Hereditary forms of spinal deformity. *The Journal of bone and joint surgery. British volume*, 70(1), pp.123–126.
- Roca, J. et al., 1989. Direct repair of spondylolysis. *Clinical orthopaedics and related research*, (246), pp.86–91.
- Roca, J. et al., 1999. One-stage decompression and posterolateral and interbody fusion for severe spondylolisthesis. An analysis of 14 patients. *Spine*, 24(7), pp.709–714.
- Roche, M. & Rowe, G., 1951. The incidence of separate neural arch and coincident bone variations; a survey of 4,200 skeletons. *The Anatomical record*, 109(2), pp.233–252.
- Rossi, F., 1978. Spondylolysis, spondylolisthesis and sports. *The Journal of sports medicine and physical fitness*, 18(4), pp.317–340.
- Rowe, D.E. et al., 1997. A meta-analysis of the efficacy of non-operative treatments for idiopathic scoliosis. *The Journal of bone and joint surgery. American volume*, 79(5), pp.664–674.
- Rowe, G. & MB, R., 1953. The etiology of separate neural arch. *The Journal of bone and joint surgery. American volume*, 35-A(1), pp.102–110.
- Ruf, M. & Harms, J., 2002a. Hemivertebra resection by a posterior approach: innovative operative technique
-

## References

---

and first results. *Spine*, 27(10), pp.1116–1123.

Ruf, M. & Harms, J., 2002b. Pedicle screws in 1- and 2-year-old children: technique, complications, and effect on further growth. *Spine*, 27(21), pp.E460–6.

Ruf, M. & Harms, J., 2003. Posterior hemivertebra resection with transpedicular instrumentation: early correction in children aged 1 to 6 years. *Spine*, 28(18), pp.2132–2138.

Ruf, M. et al., 2006. Anatomic reduction and monosegmental fusion in high-grade developmental spondylolisthesis. *Spine*, 31(3), pp.269–274.

Ryöppy, S. et al., 1992. Foot deformities in diastrophic dysplasia. An analysis of 102 patients. *The Journal of bone and joint surgery. British volume*, 74(3), pp.441–444.

Sairyo, K. et al., 1998. The pathomechanism of isthmic lumbar spondylolisthesis. A biomechanical study in immature calf spines. *Spine*, 23(13), pp.1442–1446.

Saito, N. et al., 1998. Natural history of scoliosis in spastic cerebral palsy. *Lancet*, 351(9117), pp.1687–1692.

Saraste, H., 1987. Long-term clinical and radiological follow-up of spondylolysis and spondylolisthesis. *Journal of pediatric orthopedics*, 7(6), pp.631–638.

Saraste, H., Broström, L.A. & Aparisi, T., 1984. Prognostic radiographic aspects of spondylolisthesis. *Acta radiologica: diagnosis*, 25(5), pp.427–432.

Schlenzka, D. et al., 2006. Direct repair for treatment of symptomatic spondylolysis and low-grade isthmic spondylolisthesis in young patients: no benefit in comparison to segmental fusion after a mean follow-up of 14.8 years. *European spine journal*, 15(10), pp.1437–1447.

Seitsalo, S. et al., 1991. Progression of spondylolisthesis in children and adolescents. A long-term follow-up of 272 patients. *Spine*, 16(4), pp.417–421.

Seitsalo, S. et al., 1990. Severe spondylolisthesis in children and adolescents. A long-term review of fusion in situ. *The Journal of bone and joint surgery. British volume*, 72(2), pp.259–265.

Seitsalo, S. et al., 1992. Solid fusion vs. non-union in long-term follow-up of in situ fusion without internal fixation in symptomatic spondylolisthesis in young patients. *European spine journal*, 1(3), pp.163–166.

Seitsalo, S., Osterman, K. & Poussa, M., 1988a. Scoliosis associated with lumbar spondylolisthesis. A clinical survey of 190 young patients. *Spine*, 13(8), pp.899–904.

Seitsalo, S., Osterman, K., Poussa, M., et al., 1988b. Spondylolisthesis in children under 12 years of age: long-term results of 56 patients treated conservatively or operatively. *Journal of pediatric orthopedics*, 8(5), pp.516–521.

Shono, Y., Abumi, K. & Kaneda, K., 2001. One-stage posterior hemivertebra resection and correction using segmental posterior instrumentation. *Spine*, 26(7), pp.752–757.

Shufflebarger, H.L. & Geck, M.J., 2005. High-grade isthmic dysplastic spondylolisthesis: monosegmental surgical treatment. *Spine*, 30(6 Suppl), pp.S42–8.

Shurtleff, D.B. et al., 1976. Myelodysplasia: the natural history of kyphosis and scoliosis. A preliminary report. *Developmental medicine and child neurology. Supplement*, (37), pp.126–133.

Sillence, D.O., Horton, W.A. & Rimoin, D.L., 1979. Morphologic studies in the skeletal dysplasias. *The American journal of pathology*, 96(3), pp.813–870.

Smith, J.A. et al., 2001. Clinical outcome of trans-sacral interbody fusion after partial reduction for high-grade l5-s1 spondylolisthesis. *Spine*, 26(20), pp.2227–2234.

---

## References

---

- Sorva, R. et al., 1990. Variation of growth in height and weight of children. II. After infancy. *Acta paediatrica Scandinavica*, 79(5), pp.498–506.
- Sox, H. et al., 1993. Screening for adolescent idiopathic scoliosis. Review article. US Preventive Services Task Force. *JAMA*, 269(20), pp.2667–2672.
- Sponseller, P., 2001. Skeletal dysplasias. In *The Pediatric Spine* S. Weinstein, ed., Philadelphia: Lippincott Williams & Wilkins, pp. 279-300
- Sponseller, P.D. et al., 2000. Deep wound infections after neuromuscular scoliosis surgery: a multicenter study of risk factors and treatment outcomes. *Spine*, 25(19), pp.2461–2466.
- Sponseller, P.D. et al., 2008. The use of traction in the treatment of severe spinal deformity. *Spine*, 33(21), pp.2305–2309.
- Sponseller, P.D. et al., 2011. Vertebral Column Resection in Children with Neuromuscular Spine Deformity. *Spine*.
- Sponseller, P.D., Betz, R., et al., 2009a. Differences in curve behavior after fusion in adolescent idiopathic scoliosis patients with open triradiate cartilages. *Spine*, 34(8), pp.827–831.
- Sponseller, P.D., Shah, S.A., et al., 2009b. Scoliosis surgery in cerebral palsy: differences between unit rod and custom rods. *Spine*, 34(8), pp.840–844.
- Standaert, C.J. & Herring, S.A., 2000. Spondylolysis: a critical review. *British journal of sports medicine*, 34(6), pp.415–422.
- Stanescu, V., Stanescu, R. & Maroteaux, P., 1984. Pathogenic mechanisms in osteochondrodysplasias. *The Journal of bone and joint surgery. American volume*, 66(6), pp.817–836.
- Steiner, M.E. & Micheli, L.J., 1985. Treatment of symptomatic spondylolysis and spondylolisthesis with the modified Boston brace. *Spine*, 10(10), pp.937–943.
- Stewart, T., 1953. The age incidence of neural-arch defects in Alaskan natives, considered from the standpoint of etiology. *The Journal of bone and joint surgery. American volume*, 35-A(4), pp.937–950.
- Stone, B. et al., 1979. The effect of an exercise program on change in curve in adolescents with minimal idiopathic scoliosis. A preliminary study. *Physical therapy*, 59(6), pp.759–763.
- Stover, C., Hayes, J. & Holt, J., 1963. Diastrophic dwarfism. *The American journal of roentgenology, radium therapy, and nuclear medicine*, 89, pp.914–922.
- Sucato, D.J., 2010. Management of severe spinal deformity: scoliosis and kyphosis. *Spine*, 35(25), pp.2186–2192.
- Sucato, D.J., 2007. Spine deformity in spinal muscular atrophy. *The Journal of bone and joint surgery. American volume*, 89 Suppl 1, pp.148–154.
- Suh, S.-W. et al., 2009. Posterior multilevel vertebral osteotomy for correction of severe and rigid neuromuscular scoliosis: a preliminary study. *Spine*, 34(12), pp.1315–1320.
- Suh, S.W. et al., 2001. Evaluating congenital spine deformities for intraspinal anomalies with magnetic resonance imaging. *Journal of pediatric orthopedics*, 21(4), pp.525–531.
- Suk, S.-I. et al., 2007. Is anterior release necessary in severe scoliosis treated by posterior segmental pedicle screw fixation? *European spine journal*, 16(9), pp.1359–1365.
- Suk, S.-I. et al., 2002. Posterior vertebral column resection for severe spinal deformities. *Spine*, 27(21), pp.2374–2382.
-

## References

---

- Suk, S.-I. et al., 2005. Selective thoracic fusion with segmental pedicle screw fixation in the treatment of thoracic idiopathic scoliosis: more than 5-year follow-up. *Spine*, 30(14), pp.1602–1609.
- Suk, S.I. et al., 1995. Segmental pedicle screw fixation in the treatment of thoracic idiopathic scoliosis. *Spine*, 20(12), pp.1399–1405.
- Suk, S.I. et al., 2001. Thoracic pedicle screw fixation in spinal deformities: are they really safe? *Spine*, 26(18), pp.2049–2057.
- Sullivan, P.B., 2008. Gastrointestinal disorders in children with neurodevelopmental disabilities. *Developmental disabilities research reviews*, 14(2), pp.128–136.
- Taillard, W., 1954. [Spondylolisthesis in children and adolescents]. *Acta orthopaedica Scandinavica*, 24(2), pp.115–144.
- Taimela, S. et al., 1997. The prevalence of low back pain among children and adolescents. A nationwide, cohort-based questionnaire survey in Finland. *Spine*, 22(10), pp.1132–1136.
- Takaso, M. et al., 2010. Can the caudal extent of fusion in the surgical treatment of scoliosis in Duchenne muscular dystrophy be stopped at lumbar 5? *European spine journal*, 19(5), pp.787–796.
- Takayama, K., Nakamura, H. & Matsuda, H., 2009. Quality of life in patients treated surgically for scoliosis: longer than sixteen-year follow-up. *Spine*, 34(20), pp.2179–2184.
- Teli, M.G.A. et al., 2006. Spinal fusion with Cotrel-Dubouset instrumentation for neuropathic scoliosis in patients with cerebral palsy. *Spine*, 31(14), pp.E441–7.
- Thompson, A.G. et al., 1995. Long-term results of combined anterior and posterior convex epiphysiodesis for congenital scoliosis due to hemivertebrae. *Spine*, 20(12), pp.1380–1385.
- Thompson, G.H., Akbarnia, B.A. & Campbell, R.M., 2007. Growing rod techniques in early-onset scoliosis. *Journal of pediatric orthopedics*, 27(3), pp.354–361.
- Thomsen, K. et al., 1997. 1997 Volvo Award winner in clinical studies. The effect of pedicle screw instrumentation on functional outcome and fusion rates in posterolateral lumbar spinal fusion: a prospective, randomized clinical study. *Spine*, 22(24), pp.2813–2822.
- Thulbourne, T. & Gillespie, R., 1976. The rib hump in idiopathic scoliosis. Measurement, analysis and response to treatment. *The Journal of bone and joint surgery. British volume*, 58(1), pp.64–71.
- Tokuhashi, Y. & Matsuzaki, H., 1996. Repair of defects in spondylolysis by segmental pedicular screw hook fixation. A preliminary report. *Spine*, 21(17), pp.2041–2045.
- Tolo, V. & Kopits, S., 1989. Spinal deformity in diastrophic dysplasia. *Orthop Trans*, pp.31–32.
- Tsirikos, A.I. & Mains, E., 2011. Surgical Correction of Spinal Deformity in Patients With Cerebral Palsy Using Pedicle Screw Instrumentation. *Journal of spinal disorders & techniques*.
- Tsirikos, A.I. & McMaster, M.J., 2005. Congenital anomalies of the ribs and chest wall associated with congenital deformities of the spine. *The Journal of bone and joint surgery. American volume*, 87(11), pp.2523–2536.
- Tsirikos, A.I. et al., 2008. Surgical correction of scoliosis in pediatric patients with cerebral palsy using the unit rod instrumentation. *Spine*, 33(10), pp.1133–1140.
- Turi, M., Johnston, C.E. & Richards, B.S., 1993. Anterior correction of idiopathic scoliosis using TSRH instrumentation. *Spine*, 18(4), pp.417–422.
- Turner, R.H. & Bianco, A.J., 1971. Spondylolysis and spondylolisthesis in children and teen-agers. *The Journal*
-

## References

---

of bone and joint surgery. *American volume*, 53(7), pp.1298–1306.

Vaara, P. et al., 1998. Development of the hip in diastrophic dysplasia. *The Journal of bone and joint surgery. British volume*, 80(2), pp.315–320.

Vande Velde, S. et al., 2010. Gastric Dysmotility Following Orthopaedic Scoliosis Surgery in Patients with Cerebral Palsy: A Case Series. *Neuropediatrics*, 41(04), pp.182–185.

Vasiliadis, E.S., Grivas, T.B. & Kaspiris, A., 2009. Historical overview of spinal deformities in ancient Greece. *Scoliosis*, 4, p.6.

Vedantam, R. et al., 2000. A prospective evaluation of pulmonary function in patients with adolescent idiopathic scoliosis relative to the surgical approach used for spinal arthrodesis. *Spine*, 25(1), pp.82–90.

Veldhuizen, A.G. et al., 2002. A new orthotic device in the non-operative treatment of idiopathic scoliosis. *Medical engineering & physics*, 24(3), pp.209–218.

Vialle, R. et al., 2007. Is there a sagittal imbalance of the spine in isthmic spondylolisthesis? A correlation study. *European spine journal*, 16(10), pp.1641–1649.

Vitale, M.G. et al., 2008. A retrospective cohort study of pulmonary function, radiographic measures, and quality of life in children with congenital scoliosis: an evaluation of patient outcomes after early spinal fusion. *Spine*, 33(11), pp.1242–1249.

Walker, B.A. et al., 1972. Diastrophic dwarfism. *Medicine*, 51(1), pp.41–59.

Ward, K. et al., 2010. Validation of DNA-based prognostic testing to predict spinal curve progression in adolescent idiopathic scoliosis. *Spine*, 35(25), pp.E1455–64.

Watanabe, K. et al., 2010. Efficacy of perioperative halo-gravity traction for treatment of severe scoliosis ( $\geq 100^\circ$ ). *Journal of orthopaedic science*, 15(6), pp.720–730.

Weinsten, S.L., Zavala D.C. & Ponseti, I.V., 1981. Idiopathic scoliosis: long-term follow-up and prognosis in untreated patients. *Journal of bone and joint surgery, American volume*, 63(5), pp. 702-712.

Weinstein, S.L., 2001. *The Pediatric Spine* S. Weinstein, ed., Philadelphia: Lippincott Williams & Wilkins.

Weinstein, S.L. et al., 2008. Adolescent idiopathic scoliosis. *Lancet*, 371(9623), pp.1527–1537.

Weinstein, S.L. et al., 2003. Health and function of patients with untreated idiopathic scoliosis: a 50-year natural history study. *JAMA*, 289(5), pp.559–567.

Weiss, H.-R., Weiss, G. & Petermann, F., 2003. Incidence of curvature progression in idiopathic scoliosis patients treated with scoliosis in-patient rehabilitation (SIR): an age- and sex-matched controlled study. *Pediatric rehabilitation*, 6(1), pp.23–30.

White, K.K. et al., 2011. VEPTR™ growing rods for early-onset neuromuscular scoliosis: feasible and effective. *Clinical orthopaedics and related research*, 469(5), pp.1335–1341.

Wiltse, L.L., 1962. The etiology of spondylolisthesis. *The Journal of bone and joint surgery. American volume*, 44-A, pp.539–560.

Wiltse, L.L. & Jackson, D.W., 1976. Treatment of spondylolisthesis and spondylolysis in children. *Clinical orthopaedics and related research*, (117), pp.92–100.

Wiltse, L.L. & Winter, R.B., 1983. Terminology and measurement of spondylolisthesis. *The Journal of bone and joint surgery. American volume*, 65(6), pp.768–772.

Wiltse, L.L., Newman, P.H. & Macnab, I., 1976. Classification of spondylolysis and spondylolisthesis. *Clinical*

---

## References

---

*orthopaedics and related research*, (117), pp.23–29.

Winter, R.B. & Pinto, W.C., 1986. Pelvic obliquity. Its causes and its treatment. *Spine*, 11(3), pp.225–234.

Winter, R.B. et al., 1988. Convex growth arrest for progressive congenital scoliosis due to hemivertebrae. *Journal of pediatric orthopedics*, 8(6), pp.633–638.

Winter, R.B., Moe, J.H. & Eilers, V.E., 1968. Congenital Scoliosis. A Study of 234 Patients Treated and Untreated. Part I: Natural History. *The Journal of bone and joint surgery. American volume*, 50-A, pp.1–15.

Winter, R.B., Moe, J.H. & Lonstein, J.E., 1984. Posterior spinal arthrodesis for congenital scoliosis. An analysis of the cases of two hundred and ninety patients, five to nineteen years old. *The Journal of bone and joint surgery. American volume*, 66(8), pp.1188–1197.

Winter, R.B., Moe, J.H. & Wang, J.F., 1973. Congenital kyphosis. Its natural history and treatment as observed in a study of one hundred and thirty patients. *The Journal of bone and joint surgery. American volume*, 55(2), pp.223–256.

Wood, K.B. et al., 1991. Rotational changes of the vertebral-pelvic axis following Cotrel-Dubousset instrumentation. *Spine*, 16(8 Suppl), pp.S404–8.

Wu, X. et al., 2010. Comparative intermediate and long-term results of pedicle screw and hook instrumentation in posterior correction and fusion of idiopathic thoracic scoliosis. *Journal of spinal disorders & techniques*, 23(7), pp.467–473.

Wynne-Davies, R., 1975. Congenital vertebral anomalies: aetiology and relationship to spina bifida cystica. *Journal of medical genetics*, 12(3), pp.280–288.

Wynne-Davies, R., 1968. Familial (idiopathic) scoliosis. A family survey. *The Journal of bone and joint surgery. British volume*, 50(1), pp.24–30.

Wynne-Davies, R. & Scott, J.H., 1979. Inheritance and spondylolisthesis: a radiographic family survey. *The Journal of bone and joint surgery. British volume*, 61-B(3), pp.301–305.

Yaszay, B. et al., 2011. Efficacy of hemivertebra resection for congenital scoliosis: a multicenter retrospective comparison of three surgical techniques. *Spine*, 36(24), pp.2052–2060.

---