



Received: 2017.01.10
Accepted: 2017.04.17
Published: 2017.12.15

Authors' Contribution:

- A** Study Design
- B** Data Collection
- C** Statistical Analysis
- D** Data Interpretation
- E** Manuscript Preparation
- F** Literature Search
- G** Funds Collection

Multiple Brain Abscesses Caused by *Citrobacter Koseri* in a Preterm Neonate – Case Report

Miłosz Lechowicz^{1ADEF}, Katarzyna Dąbek^{2DEF}, Urszula Majewska^{1AB},
Monika Bekesińska-Figatowska^{3DE}, Maria K. Borszewska-Kornacka^{1D},
Renata Bokiniec^{1AGDEF}

¹ Department of Neonatal and Intensive Care, Medical University of Warsaw, Warsaw, Poland

² Division of Gynaecology and Perinatology, Department of Neonatal, Medical University of Lublin, Lublin, Poland

³ Department of Diagnostic Imaging, Institute of Mother and Child, Warsaw, Poland

Author's address: Renata Bokiniec, Department of Neonatal and Intensive Care, Medical University of Warsaw, Karowa 2 Str., 00-315 Warsaw, Poland, e-mail: r.bokiniec@wp.pl

Summary

Background:

Brain abscesses are very rarely diagnosed in neonates, but if present, they are associated with a high risk of severe complications and mortality. In neonates, brain abscesses can be detected on transfontanelle ultrasonography, in which they appear as hyperechogenic lesions surrounded by a hypoechogenic border.

Case Report:

We present a female neonate, born in the 28th week of gestation, with birth weight of 950 grams, who was born in an ambulance by spontaneous vaginal vertex delivery. No signs of infection were present until the 35th day of hospitalization, when a sudden and serious deterioration in the patient's condition was observed due to late-onset sepsis. Cranial US, performed on the 40th day of life, revealed hyperechogenic lesions with a hypoechogenic halo in the right frontal lobe, which could correspond to brain abscesses. These lesions were caused by *Citrobacter koseri* septicaemia, identified by transfontanelle ultrasonography, and confirmed on magnetic resonance imaging. The patient recovered and was discharged on the 91th day of life (39 PCA) with a recommendation of permanent neurological surveillance.

Conclusions:

Ultrasonography of the central nervous system can reveal inflammatory changes and developing brain abscesses. In neonates, magnetic resonance imaging should be performed as the method of choice for confirming brain abscesses.

MeSH Keywords:

Brain Abscess • *Citrobacter Koseri* • Magnetic Resonance Imaging • Ultrasonography

PDF file:

<http://www.polradiol.com/abstract/index/idArt/903276>

Background

Brain abscesses are rare in neonates [1–3], and it is estimated that only 1.3–4% of all meningitis cases are complicated by brain abscesses [2]. This risk increases to about 40–70% in patients infected with *Citrobacter koseri* or *Proteus mirabilis* [2,4,5]. *Citrobacter koseri* are physiological bacteria of the human digestive tract [2], but they may also be found in water, food, and sludge. Although *Citrobacter koseri* does not usually cause infections, it has a very strong affinity to the brain tissue. It is worth mentioning that mixed aetiology infections, including fungal infections, may also cause brain abscesses, especially

in low-birth-weight neonates or immunocompromised patients.

Patients with brain abscesses have a high mortality rate that ranges from 4 to 30% [2,4]. Unfortunately, in 50–80% of children who recover from such infections, chronic central nervous system (CNS) damage is often observed, resulting in delayed mental development, behavioural disorders, or epilepsy [2,5].

Brain abscesses are usually caused by a localised infarction due to microthrombi in the white matter or within the germinal matrix of the ventricles. In early phases on

Table 1. Cerebrospinal fluid (CSF) analysis in the patient over time.

Day of life	Pleocytosis [cells/mm ³] (normal range=0–6)	Description of CSF	Chloride [mmol/L] (normal range=112–130)	Glucose [mg/dL]	Protein [mg/dL] (normal range=20–80)
35	482	Light yellow coloured to transparent after centrifugation	105	23	200
40	1031	Slightly turbid to straw coloured after centrifugation	108	8	200
47	413	Light yellow coloured to transparent after centrifugation	110	16	300
57	44	Light pink to transparent after centrifugation	112	29	100

the inflammatory process, transfontanelle ultrasonography can reveal a round, hyperechogenic lesion in the brain parenchyma, resulting from inflammation and necrosis. After several days, a typical hyperechogenic lesion surrounded by a hypoechogenic border can be seen, indicating an abscess. We report of a 5-week-old infant with multiple brain abscesses caused by *Citrobacter koseri* that were revealed on cranial US and later confirmed on magnetic resonance imaging (MRI).

Case Report

A female neonate, born in the 28th week of gestation, with low birth weight of 950 g was born in an ambulance by spontaneous vaginal vertex delivery to a 26-year-old mother (gravida 2, para 1; one miscarriage). The pregnancy was complicated by vaginal bleeding, but there was no evidence of bacterial presence in the mother, and prenatal steroid therapy was not administered.

The initial and follow-up cranial ultrasound (US) examinations were normal.

On the 35th day of hospitalization, a significant deterioration in the patient's condition was observed due to late-onset sepsis. The main symptoms were anxiety, apnoea that required using nCPAP, hypertonia, tachycardia, and feeding intolerance. Blood tests revealed inflammation, increased levels of C-reactive protein (CRP) and procalcitonin (PCT), and blood smear was abnormal. Cerebrospinal fluid (CSF) was abnormal (Table 1). Blood culture was positive for *Citrobacter koseri*, but CSF was negative for this bacterium.

Cranial US was performed on the 40th day of life and revealed hyperechogenic lesions with hypoechogenic halos, which could indicate brain abscesses, especially in this clinical setting. Initial lesions were localized in the frontal lobe, surrounding the frontal horn of the right lateral ventricle (dimensions 1.53×0.95 cm), another lesion in the right frontal lobe (1.54×1.25 cm), and an adjacent lesion in the left occipital horn (0.56×0.60 cm). These three abscesses were confirmed on magnetic resonance imaging (MRI) that was performed on the 44th day of life. Features of raised intracranial pressure were also observed on Doppler ultrasonography - resistance index (RI) for the anterior cerebral artery was 0.9. On subsequent ultrasound

examinations, enlargement of the ventricular system was also observed. The ventricular index (Levene method) was raised - 1.44 cm for the left ventricle and 0.69 for the right ventricle. The evolution of the abscesses during treatment is shown on US and MR images (Figures 1–4).

Initially, the patient was treated with a combination of a third generation cephalosporin, gentamicin, and vancomycin. This treatment was modified after microbiological testing revealed *Citrobacter koseri*. Subsequently, meropenem was used for 42 days, gentamicin for 14 days, and vancomycin for 7 days. Fluconazole was used as prophylaxis of fungal infections.

The patient's condition stabilized and an improvement in blood and CSF studies was observed. Control microbiological cultures were negative. During hospitalization, the patient underwent several neurosurgical consultations. Due to the absence of focal symptoms, good condition of the patient, and a normal evolution of abscesses on imaging, no surgical intervention was necessary.

On the 91st day of life (39 weeks post-conception), the patient was discharged with a recommendation of permanent neurological surveillance.

Discussion

Various types of neurological disorders are observed in about 50–80% of children who survive *Citrobacter koseri* infections complicated by brain abscesses [2,3,4]. It is claimed that *Citrobacter koseri* may be transferred vertically from the mother to the child, but there is no evidence that this route of bacterial transfer is responsible for brain abscesses in premature neonates [4]. Oftentimes, bacterial transfer occurs horizontally from hospital personnel [3,4]. However, the source of infection in our patient remains unclear.

In neonates, most infections associated with brain abscesses are caused by Gram-negative bacteria, especially by *Citrobacter koseri* and *Proteus mirabilis* [1,2]. However, other pathogens should be taken into consideration, such as Gram-positive bacteria, fungi, or mixed infections.

In our patient, blood cultures that were drawn at the time of clinical deterioration were positive for *Citrobacter*

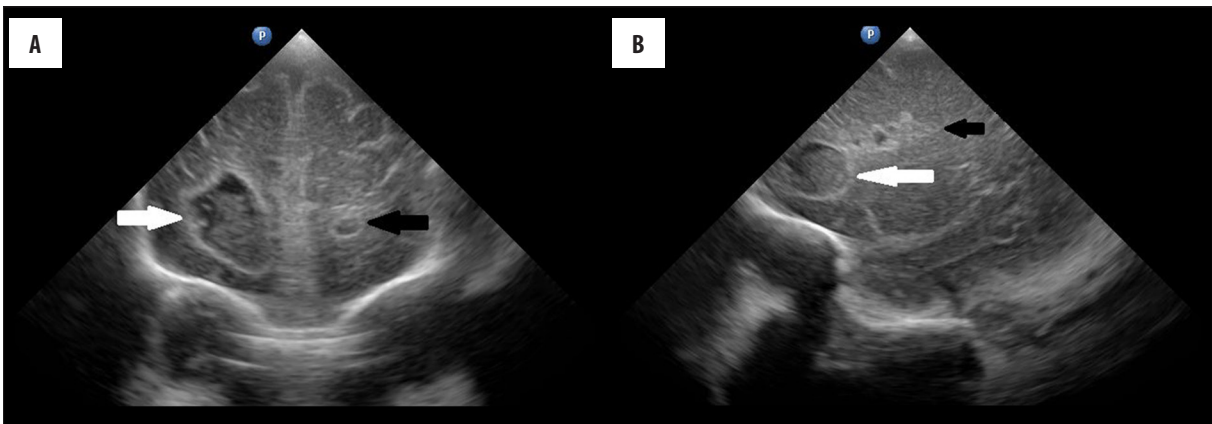


Figure 2. Cranial ultrasonography of the patient on the 46th day of life. (A) Frontal plane image showing multiple brain abscesses in both frontal lobes. A large abscess is located in the right frontal lobe (white arrow) and a smaller one in the left frontal lobe (black arrow). (B) Sagittal plane image showing a brain abscess located in the left frontal lobe (white arrow), and changes in that area (black arrow).

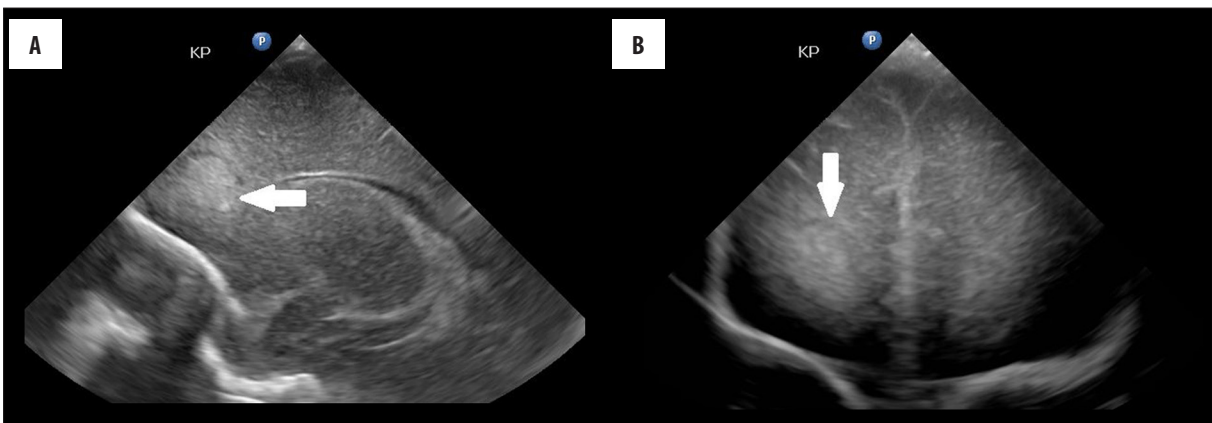


Figure 1. Cranial ultrasonography of the patient on the 40th day of life. (A) Frontal plane image showing a hyperechogenic change (abscess) located in the right frontal lobe (white arrow). (B) Sagittal plane image showing a hypoechogenic halo surrounding the abscess located in the right frontal lobe (white arrow).

koseri. Interestingly, the CSF culture remained negative, which may be explained by the bacterial clot hypothesis. This hypothesis states that bacterial clots localize in the small brain vessels and consequently cause brain abscesses. This can be found especially in infections caused by *Citrobacter koseri* that has a strong affinity for the brain tissue. Consequently, inflammation within the CNS develops without seeding bacteria into the CSF, which explains sterile cultures.

Typically, symptoms of brain abscesses are found in neonates between the 1st and 60th day after admission and usually within the first week of life. However, these symptoms are not specific [2]. They are similar to general symptoms of infections, e.g. anxiety, rapidly growing head circumference, raised fontanelle, and wide cranial sutures [2,4]. Vomiting, seizures, or eating disorders are rarely described in such small children. In our patient, on the 35th day of life, deterioration of the general condition was observed and manifested as respiratory abnormalities with apnoea, increased muscle tension, anxiety, tachycardia, and food intolerance. Because the symptoms were nonspecific, it was astonishing to find lesions suggestive of brain abscesses on US and MRI.

Imaging studies that are used in the diagnostic process include transfontanelle US, MRI, and possibly computed tomography (CT) if MRI is not available or contraindicated [2,4,6]. In principle, ultrasound is the first examination which reveals abnormalities. On ultrasonography, brain abscesses are described as hyperechoic areas surrounded by hypoechoic rims. MRI should be performed to confirm the diagnosis. Ultrasonography is a safe and accurate method for detecting complications of cerebral infection; however, small abscesses and subdural collections cannot be seen on ultrasound and therefore MRI is the method of choice in these cases as it shows the full extent of the disease. In our case, the extent of brain involvement was greater on MRI than on US, and the typical MRI appearance confirmed the diagnosis. MRI provides very characteristic images of bacterial brain abscesses: a capsule that is hyperintense (white) on T1-weighted images and hypointense (dark) on T2-weighted images, which enhances after administration of contrast material. Importantly, a hyperintense signal of the contents of the abscess can be seen on diffusion weighted imaging (DWI), which corresponds to low apparent diffusion coefficient (ADC) values on ADC maps. This is due to restriction of water diffusion within the abscess, which was also observed in our patient [6]. Follow-up neuroimaging studies should be carried out at intervals of 1-2 weeks

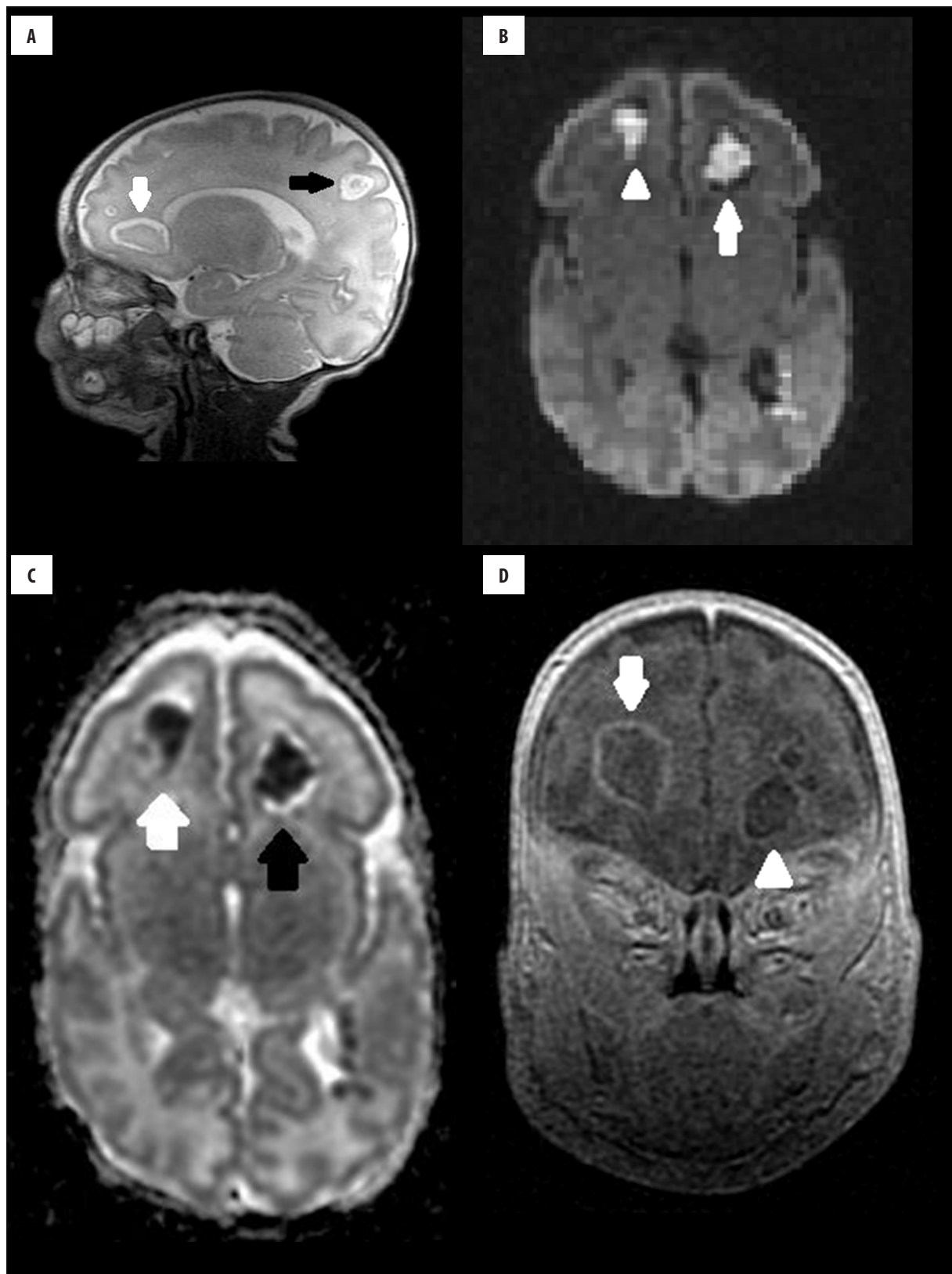


Figure 3. Brain MRI of the patient on the 44th day of life. Multiple abscesses. (A) T2-weighted image in the sagittal plane: two abscesses are located in the frontal lobes (white arrow) and one in the parietal lobe (black arrow). (B) DWI sequence in the axial plane: typical, hyperintense contents of the abscesses in both frontal lobes (right side-white arrow, left side-arrowhead). (C) ADC map corresponding to Figure (B) with very low values of ADC (black and white arrow), typical of an abscesses. (D) T1-weighted, post-contrast image in the coronal plane. Contrast enhancement of the abscess capsule is readily observed in the right frontal lobe (white arrow).

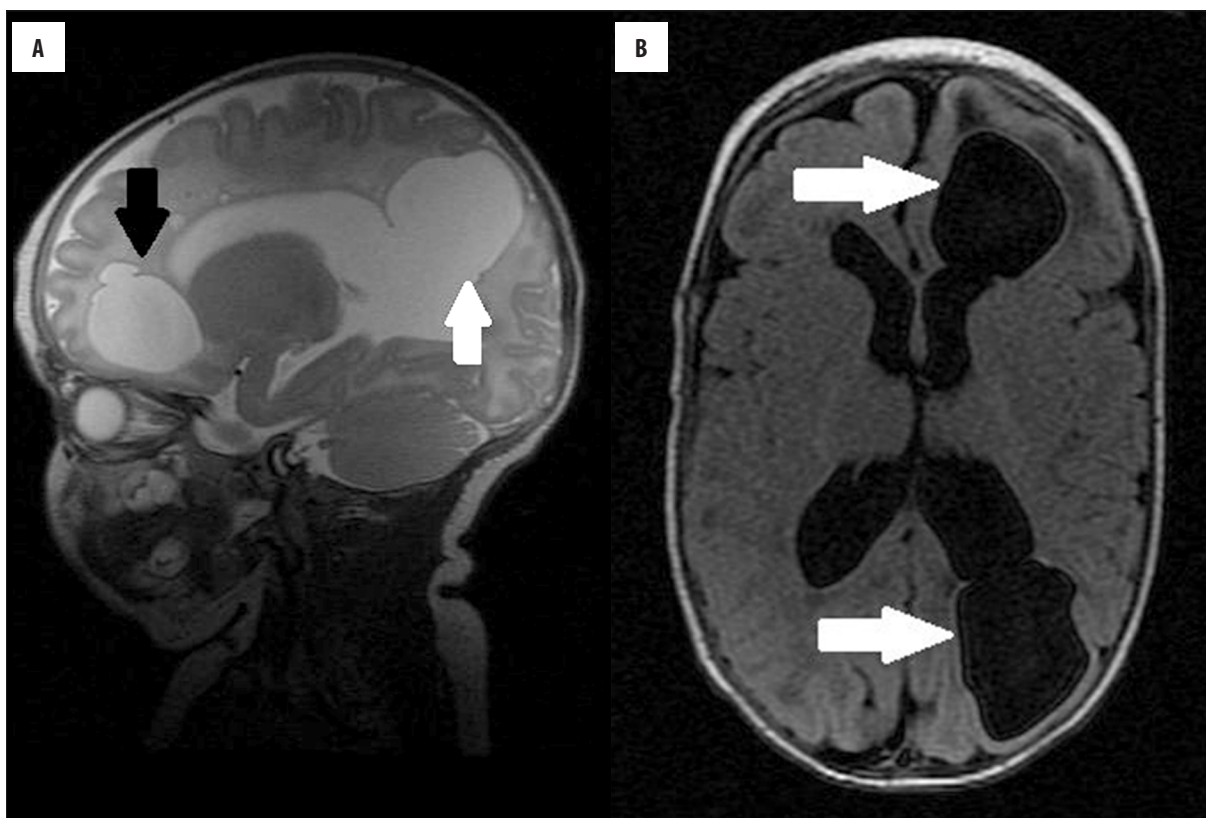


Figure 4. Brain MRI of the patient on the 88th day of life. **(A)** T2-weighted image in the sagittal plane showing cavities in the left frontal lobe (black arrow) and in the left occipital lobe (white arrow), bordering the left lateral ventricle. **(B)** FLAIR image in the coronal plane.

to assess the effectiveness of treatment [4,6]. We monitored the evolution of changes on US and MRI.

Brain abscesses are treated empirically with broad-spectrum antibiotics that penetrate well through the blood-brain-barrier. Surgical methods can also be used, but pharmacotherapy is the primary method of treatment. Pharmacological treatment may be used in patients with brain abscesses ≤ 2.5 cm that respond well to antibiotics and do not elicit focal symptoms. Surgical interventions, such as stereotactic biopsy of the abscess or its enucleation in older patients, are used in patients with multiple abscesses or abscesses with diameter >2.5 cm, and in those patients who do not respond to antibiotics [2,4,5]. Treatment is administered under ultrasound or CT surveillance. Unfortunately, in approximately 25% of cases the procedure needs to be repeated [4]. According to some

authors, biopsy should only be performed in patients with a brain abscess that has become encapsulated [2]. However, when considering such a procedure, the possibility of complications such as spreading of inflammation to the healthy brain tissue, recurrence, and the need to repeat the procedure should be taken into account.

Conclusions

Ultrasonography of the central nervous system can reveal inflammatory changes and developing brain abscesses. Magnetic resonance imaging should be performed as the method of choice to confirm brain abscesses in the neonate.

Conflict of interest

None of the authors declared any conflict of interest.

References:

1. Aljubaisi S, Buhner Ch, Thomale UW, Spors B: Favorable outcome in cerebral abscesses caused by *Citrobacter koseri* in a newborn infant. IDCases, 2015; 2: 22–24
2. Marecos CV, Ferreira M, Ferreira MM, Barroso MR: Sepsis, meningitis and cerebral abscesses caused by *Citrobacter koseri*. BMJ Case Rep, 2012; 10: 1135–41
3. Rodrigues J, Rocha D, Santos F, Joao A: Neonatal *Citrobacter koseri* meningitis: Report of four cases. Case Rep Pediatr, 2014; 2014: 195204
4. Chowdhry SA, Cohen AN: *Citrobacter* abscess in neonates: Early surgical intervention and review of literature. Childs Nerv Syst, 2012; 28: 1715–22
5. Cuadros EN, Castilla CY, Algarra CM et al: Medical and neurosurgical management of *Citrobacter koseri*, a rare cause of neonatal meningitis. J Med Microbiol, 2014; 63: 144–47
6. Alam MS, Sajjad Z, Azeemuddin M et al: Diffusion weighted MR imaging of ring enhancing brain lesions. J Coll Physicians Surg Pak, 2012; 22(7): 428–31