



Received: 2017.03.02  
Accepted: 2017.03.29  
Published: 2017.12.15

**Authors' Contribution:**

- A** Study Design
- B** Data Collection
- C** Statistical Analysis
- D** Data Interpretation
- E** Manuscript Preparation
- F** Literature Search
- G** Funds Collection

## Evaluation of Pancreas with Strain Elastography in Children with Type 1 Diabetes Mellitus

Mehmet Öztürk<sup>1ABC</sup>, Ruken Yildirm<sup>2DEF</sup>

<sup>1</sup> Department of Pediatric Radiology, Diyarbakır Children's Hospital, Diyarbakır, Turkey

<sup>2</sup> Department of Pediatric Endocrinology, Diyarbakır Children's Hospital, Diyarbakır, Turkey

**Author's address:** Mehmet Ozturk, Department of Pediatric Radiology, Diyarbakır Children's Hospital, 21100, Diyarbakır, Turkey, e-mail: drmehmet2121@gmail.com

**Background:**

**Material/Methods:**

**Results:**

**Conclusions:**

**MeSH Keywords:**

**PDF file:**

### Summary

To investigate changes in pancreatic elasticity in children with type 1 diabetes mellitus (T1DM).

The study group consisted of 60 children with T1DM, and the control group was comprised of 60 healthy children. Strain ratios were obtained for the pancreas using ultrasound strain elastography (Toshiba Applio 500 device). Baseline descriptive data, hemoglobin A1c (%) level, time since diagnosis of T1DM (months), and strain ratio values were noted and compared between the 2 groups. Furthermore, correlation between strain ratio values and other variables was investigated.

ROC analysis yielded an optimal cut-off value of 2.245 (AUC=0.999,  $p<0.001$ , sensitivity=0.983, specificity=1.00) for the strain ratio. Strain ratio values greater than 2.245 were likely to be pathological, which could be attributed to increased tissue stiffness in T1DM. The strain ratio was significantly higher in T1DM patients than in the control group ( $3.38\pm0.66$  vs.  $1.32\pm0.35$ ;  $p<0.001$ ). The strain ratio correlated positively with age and duration of T1DM ( $p<0.001$  for both), and there was a correlation between the strain ratio and age in the control group ( $p=0.011$ ).

Strain elastography is a promising, safe, non-invasive, and practical method for early detection, long-term screening, and follow-up in children with T1DM.

**Child • Diabetes Mellitus • Elasticity Imaging Techniques • Pancreas**

<http://www.polradiol.com/abstract/index/idArt/904118>

### Background

Pancreatic changes including those affecting the parenchyma and ductal structures can be due to degenerative processes associated with aging, inflammation, and diabetes mellitus [1,2]. Age-related changes of the pancreatic parenchyma include a decrease in pancreatic volume, observed after the sixth decade of life, and an increase in pancreatic fat content; histologically, lipomatosis, fibrosis, and focal necrosis can also be attributed to aging [3–5].

Transabdominal ultrasonography is a non-invasive imaging method that has been used in patients with pancreaticobiliary diseases for many decades. In conjunction with elastography, transabdominal ultrasonography can yield more information on the mechanical texture of tissues. Ultrasound strain elastography is one of the useful methods for evaluating pancreatic lesions. Since tissues affected

by various pathologic processes exhibit distinct mechanical features, identification of lesions can be based on differences in their elasticities [1,6,7]. Two types of ultrasound elastography, which can be used for this purpose, include strain elastography and shear wave elastography [8]. The feasibility of tissue elastography with transabdominal ultrasound in the diagnosis of pancreatic diseases and age-related changes has been studied [9]. Recently, real-time tissue elastography has been used to visualize the strain between ultrasound image-pairs of tissues under compression and decompression. The strains of different tissues are encoded by different colors to reflect their relative hardness. The applications of sonoelastography in different organs are currently being intensively investigated [10–12]. Strain elastography is based on acquisition of data that are later used for calculating the strain ratio and strain histograms or for neural network analysis. Strain histograms are used to evaluate tissue stiffness by transformation of color

images, that represent different levels of stiffness, into the gray-scale and into calculated parameters [8].

The pancreas can undergo structural changes due to the initiation and progression of type 1 diabetes mellitus (T1DM). Vascular parameters, such as transient vasoconstriction and vasodilation, and increased blood flow and vascular leakage accompany inflammation [13]. Vascular swelling, alterations of endothelial cell morphology in the perisplectic region, increased blood flow, and edema have been reported in the pancreas of patients with T1DM [13]. Elasticity can be altered due to fibrosis in chronic processes or due to vascular engorgement during inflammation in diabetes mellitus. Therefore, there is a need to exclude the causes which can cause chronic pancreatitis in these patients.

In the present study, we aimed to evaluate T1DM-related elasticity changes in the pancreas of children using transabdominal ultrasonography. Furthermore, we analyzed the association between strain ratio values and descriptive/clinical parameters in these patients.

## Material and Methods

### Study design

This cross-sectional, controlled trial was performed in the pediatric radiology department of our tertiary care center between November 2015 and October 2016. Before study initiation, we obtained the approval of our local Institutional Review Board. Written informed consent was obtained from parents of every participant.

In total, 120 children (59 girls, 61 boys) with an average age of  $138.1 \pm 41.1$  months (range: 62 to 204) were recruited. Participants were allocated into two groups: Group 1 consisted of 60 children (30 girls, 30 boys) diagnosed with T1DM in accordance with the criteria of the American Diabetes Association [14]; Group 2 was comprised of 60 healthy children (29 girls, 31 boys). Healthy volunteers did not undergo any biochemical testing. Assurance of confidentiality was provided with respect to health information in all participants. Scanning was performed early in the morning after an overnight fasting period. In some cases, subjects were instructed to drink 250 ml of water during the procedure in order to improve the visibility of the pancreas. The identification of the pancreas was facilitated by using the left lobe of the liver, portal vein, superior mesenteric artery, and inferior vena cava as landmarks.

Exclusion criteria were age greater than 16 years, history of pancreatic diseases like pancreatitis, cystic fibrosis, neoplasms, autoimmune disease, and diagnosis of type 2 DM and liver diseases.

### Transabdominal ultrasonography examinations

Ultrasonography was performed with Toshiba Applio 500 device (Toshiba Medical Systems, Co., Ltd., Otawara, Japan). Strain elastography was carried out using a 3.5-5 MHz, convex probe. A single radiologist with 5 years of experience in pediatric and abdominal radiology (M.O.)

carried out transabdominal ultrasonography examinations. Strain ratio measurements were obtained made suspended respiration.

The ultrasound probe was placed parallel to the pancreas, and the region of interest (ROI) was located in the body of the pancreas. The relative elasticity of the tissue was displayed in different colors; red, green and, blue were consistent with soft, average, and hard tissues, respectively. Images stable for at least 5 seconds were used for quantitative analysis and definition of the pattern. The region of interest (ROI) for the elastographic evaluation was manually selected to include the targeted area of the pancreas and the surrounding tissues. Two different areas (T and R) were derived from the ROI for quantitative elastographic analysis (Figures 1, 2). Area T was the largest possible area of the target tissue (pancreatic parenchyma), while Area R indicated the reference area, corresponding to the left lobe of the liver, which was cautiously selected with respect to position and size [15]. The result of the elastographic evaluation was defined as the quotient R/T, i.e., the strain ratio. Three different elastographic measurements were taken in each patient at the head, body, and tail of the pancreas. The final result of the analysis was a mean of the three values. The procedure of elastography was carried out in accordance with previously described principles [16].

Since the pancreas is a retroperitoneal structure, manual compression of the pancreas should be amplified on the left lobe, where it is in line with aorta, whose pulsations aid in compression.

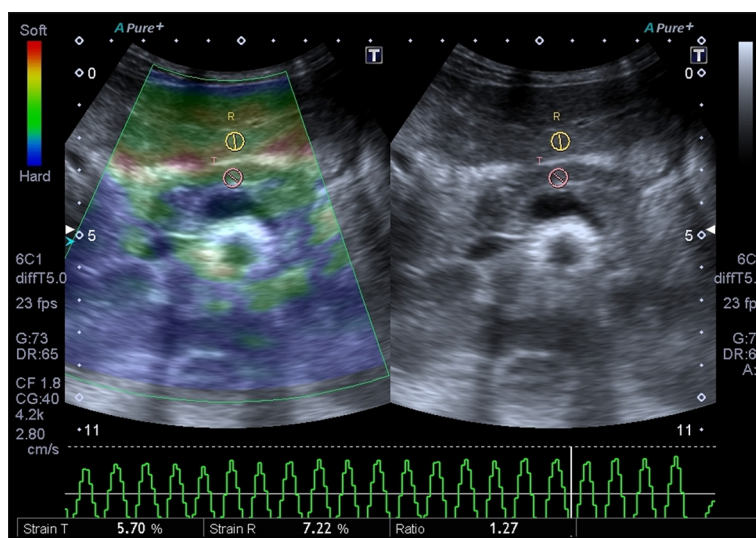
The intensity and duration of the manual compression was adjusted by monitoring the elastogram on the video screen of the ultrasound system. Movements of the transducer were repeated using different compression ratios until a stable and reproducible image series was obtained. The ultrasound B-mode and elastography images were recorded on the internal hard disk of the ultrasound machine.

### Outcome parameters

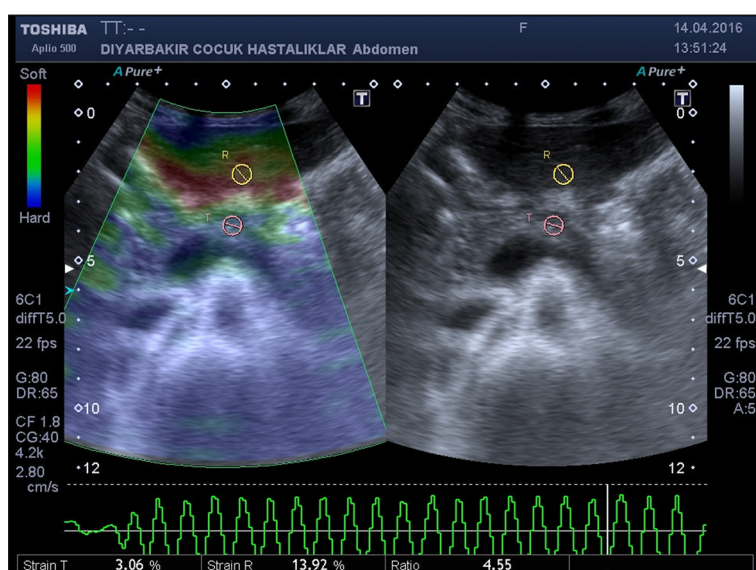
In this study, we focused on baseline descriptive statistics including age (months) and gender (female, male), duration of disease (months), strain ratio for the pancreas, and serum hemoglobin (Hb) A1c levels (%).

### Statistical analysis

Data analysis was performed with IBM Statistical Package for Social Sciences (SPSS) Statistics 20 software (SPSS Inc., Chicago, IL, USA). Normality of distribution was assessed with the Kolmogorov-Smirnov test. Correlations between variables were evaluated with the Pearson's correlation coefficient. Comparisons between two independent groups were made with the independent-samples t test, whereas comparisons between categorical variables were performed with the Pearson's chi-squared test. Quantitative data were expressed as means, standard deviations, and minimum and maximum values. Confidence intervals were 95%, and p values lower than 0.05 were considered as statistically significant.



**Figure 1.** Elastography of the pancreas in a 72-month-old, healthy girl displayed a strain index of 1.27. Region of interest (T) is set on the body of pancreas, and ROI (R) is set on read area around the left lobe of liver. The strain ratio (R/T) was calculated automatically and displayed on the bottom of the screen.



**Figure 2.** Elastography of the pancreas in a 196-month-old girl with type 1 diabetes mellitus exhibited a strain index of 4.55. Region of interest (T) is set on the body of pancreas and ROI (R) is set on read area around the left lobe of the liver. The strain ratio (R/T) was calculated automatically and displayed on the bottom of the screen.

## Results

Our series consisted of 60 T1DM patients (30 girls, 30 boys) and 60 healthy controls (29 girls, 31 boys). An overview of demographic and clinical data is presented in Table 1. No difference was observed between the 2 groups with respect to gender ( $p=0.855$ ). There was no difference between T1DM patients and controls in terms of age ( $139.2 \pm 41.4$  vs.  $137.1 \pm 41.1$ ;  $p=0.78$ ). However, the strain ratio was significantly higher in T1DM patients ( $3.4 \pm 0.7$  vs.  $1.3 \pm 0.4$ ;  $p<0.001$ ). Correlation analysis revealed that there was a positive correlation between the strain ratio and age in the whole sample, T1DM patients, and controls ( $p<0.001$ ,  $p<0.001$ , and  $p=0.011$ ; respectively) (Table 2). In other words, aging was associated significantly with higher strain ratios. In diabetic children, duration of T1DM was also positively correlated with the strain ratio ( $p<0.001$ ). However, there was no correlation between the strain ratio and HbA1c levels ( $p=0.091$ ). Figures 3–5 demonstrate the relationship between the strain index, age, duration of T1DM, and HbA1c levels.

ROC analysis yielded that cut-off value for strain ratio was 2.245 (AUC=0.999,  $p<0.001$ , sensitivity=0.983 and specificity=1.00) (Figure 6). Strain ratio values greater than 2.245 were likely to be pathological attributed to increased tissue stiffness in T1DM.

## Discussion

The objective of the present study was to evaluate T1DM-related changes in pancreatic elasticity in children. We noted that there were significant changes in pancreatic elasticity, and the strain ratio was significantly higher in T1DM. There was a positive correlation between the strain ratio and age in both T1DM patients and controls. Notably, the strain ratio was correlated positively with duration of T1DM, but the HbA1c level was not associated with the strain ratio.

Elastographic images represent tissue elasticity, which may be related to histopathologic features [17]. Elastography of the pancreas can be challenging to perform with sufficient accuracy and reproducibility, which can be attributed to the small size and deep location of the organ. Moreover,

**Table 1.** An overview of descriptive and clinical parameters in our series.

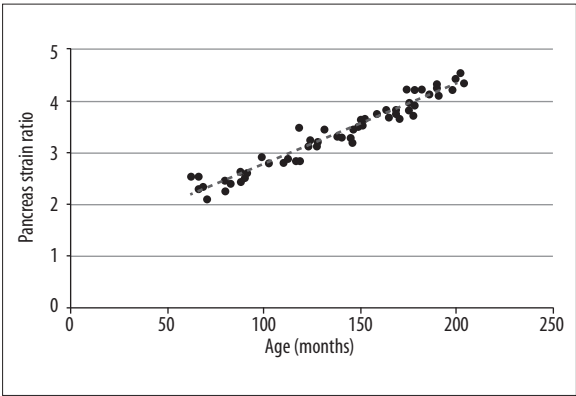
Group	n	Variable	Average (mean±standard deviation)	Range (minimum–maximum)
Whole	120	Age (months)	138.1±4.1	62–204
T1DM	60	Age (months)	139.2±41.4	63–204
		Duration of T1DM (months)	62.9±27.8	14–113
		HbA1c level (%)	9.7±2.5	6.30–17.00
Control	60	Age (months)	137.1±41.1	62–203

T1DM – type 1 diabetes mellitus; HbA1c – haemoglobin A1c.

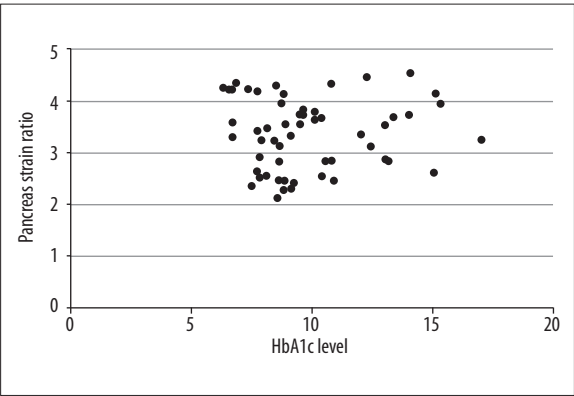
**Table 2.** Results of the correlation analysis between strain ratio of pancreas elastography and clinical variables.

Group	n	Variable	Variable	r-value	p-value
Whole	120	Strain ratio	Age (months)	0.349	<0.001*
T1DM	60	Strain ratio	Age (months)	0.976	<0.001*
			Duration of diabetes (months)	0.923	<0.001*
			HbA1c level (%)	0.015	0.910
Control	60	Strain ratio	Age (months)	0.327	0.011*

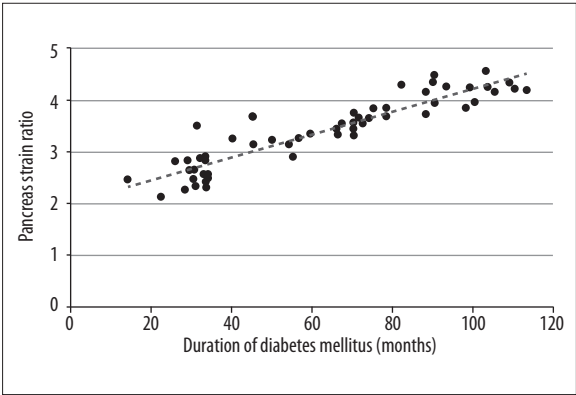
T1DM – type 1 diabetes mellitus; HbA1c – haemoglobin A1c; \* statistically significant.



**Figure 3.** Association between the strain ratio and age (months) in patients with type 1 diabetes mellitus.



**Figure 5.** Relationship between the strain ratio and serum hemoglobin A1c levels (%).



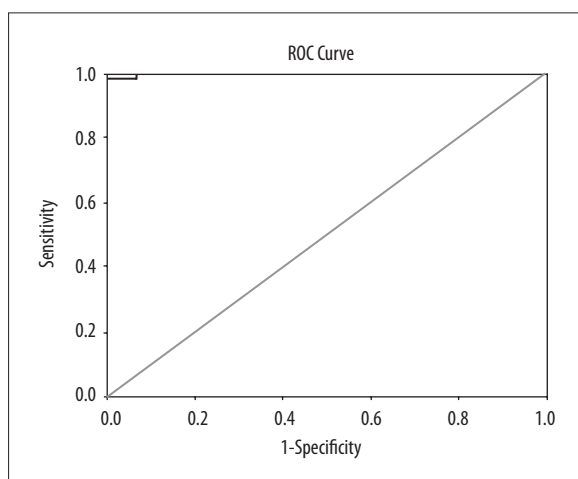
**Figure 4.** Relationship between the strain ratio and duration of type 1 diabetes mellitus (months).

confirmation of elastographic data is hard due to the difficulty of obtaining a biopsy. Elastography is a promising imaging modality for inflammatory and neoplastic diseases of the pancreas and for identification of high-risk patients with pancreatic cancer [18]. To our knowledge, the structural alterations in the pancreas of children with T1DM have not been studied using elastography.

Clinical practice guidelines for elastography of the pancreas have been announced recently [8]. Verification of findings derived from elastography cannot be made due to the difficulty of obtaining a biopsy specimen. An elastogram allows a satisfactory evaluation of the pancreatic body, but it may not be sufficient for the head or tail of the pancreas.

Type 1 diabetes mellitus not only necessitates lifelong insulin treatment, but screening for long-term complications and meticulous follow-up are also mandatory to avoid





**Figure 6.** ROC curve demonstrates the cut-off value of 2.245 for the strain ratio for type 1 diabetes mellitus patients (AUC: 0.999,  $p < 0.001$ , sensitivity: 0.983, specificity: 1.000).

morbidity and mortality associated with T1DM [18]. In this context, strain elastography can be a useful and reliable measure to be used in periodical screening and follow-up.

Strain elastography has been used successfully to document age-related changes in the pancreas [18]. Our results are in line with a report supporting the fact that age has an important impact on strain ratio values in both T1DM patients and healthy controls. Janssen et al. reported that elastography was a feasible method that yielded convincing results in chronic pancreatitis and focal lesions of the pancreas [19]. As far as we know, this is the only study investigating the utility of elastography of the pancreas in children with T1DM. Cut-off values for the strain ratio have been investigated for pancreatic tumors and pancreatitis, and the optimal values of the strain ratio vary substantially in different reports [17,20]. In the case of chronic pancreatitis, a correlation between the strain ratio and disease classification was shown [15]. The cut-off value for chronic pancreatitis was found to be 2.25 by ROC analysis. In our series, we calculated a cut-off value of 2.245, which is very close to that in chronic pancreatitis. This finding suggests that T1DM may be associated with a chronic inflammatory process similar to chronic pancreatitis. Histopathological studies are essential to unveil the characteristics of structural changes in the pancreas in T1DM. We observed that duration of disease and age correlated positively with the strain ratio in T1DM, but the HbA1c level was not associated with the strain ratio.

A recent publication reported that the carotid intima-media thickness was an early indicator of atherosclerosis in children with type 1 diabetes, and this could be followed by macro- and microvascular atherosclerotic changes [21]. Similarly, strain elastography may be another parameter that could predict the course of the disease. Even though HbA1c reflects glycemic control, it may not be necessarily accompanied by alterations of the strain ratio.

Assessment of pancreatic volume with helical computerized tomography indicated that pancreatic volume was decreased remarkably in T1DM. Elastography can be useful for detection of early changes in the pancreas attributed

to T1DM in patients with less visible symptoms. Focal or diffuse stiffness may indicate patients at risk in whom a detailed examination for T1DM should be performed. In spite of certain limitations, transabdominal ultrasound strain elastography seems to be a convenient option for screening of large populations. Selection of ROI is important particularly in patients with a high body-mass index since identification of the pancreas may be difficult.

Our findings showed that the strain ratio was significantly higher in children with T1DM. Hopefully, strain elastograms can be a promising and non-invasive tool for the evaluation and follow-up of these patients. However, determination of cut-off values necessitates elimination of technical and operator-related problems. Therefore, multi-center, prospective, controlled studies on larger series must be conducted to obtain more reliable results. The indications and limitations of elastography remain to be elucidated in further trials on larger series. Thus, popularization of clinical application and improvement of accuracy and reproducibility could be obtained. The quantification of the pancreatic parenchymal stiffness can help estimate the risk of pancreatic fistula formation. We noted a positive correlation between age and pancreatic stiffness in all groups, and there is a positive correlation between pancreatic stiffness and duration of DM. This finding may be due to the fact that patients with long-standing DM may have stiffer pancreata because of an older age.

This study has certain limitations such as the lack of analysis of possible confounding factors, operator- and equipment-related restrictions, and data derived from a single institution. No consensus exists on the reference area to be set during elastography of the pancreas [17]. Alternatively, the strain ratio and the elasticity of area T may be calculated in triplicate for every case in order to eliminate the selection bias of areas R and T. In this circumstance, a mean of the 3 measurements can be used as a more reliable measure. The influence of reference on the results of the strain ratio cannot be ignored. Moreover, the color map in elastography is prone to be influenced by the size of ROI. The elastographic appearance of the pancreas may vary due to an inhomogeneous affection of the organ and different stages of the disease. Lack of correlation between the severity of the disease with the elastographic appearance is another significant limitation of this study. It must be taken into account. Moreover, different cut-off values can be reported for chronic pancreatitis and for tumors with hard texture.

## Conclusions

In conclusion, we suggest that elastography of the pancreas can provide important clues reflecting the histopathological alterations associated with T1DM. We observed that strain ratios, that represent tissue stiffness, were significantly higher in children with T1DM. Therefore, strain elastography is a promising, safe, non-invasive, and practical tool for the early detection, long-term screening, and follow-up of these patients.

## Conflict of interest

None of the authors has any conflict of interest, financial or otherwise.

---

**References:**

---

1. Chantarojanasiri T, Hirooka Y, Kawashima H et al: Age-related changes in pancreatic elasticity: When should we be concerned about their effect on strain elastography? *Ultrasonics*, 2016; 69: 90–96
2. Marks WM, Filly RA, Callen PW: Ultrasonic evaluation of normal pancreatic echogenicity and its relationship to fat deposition. *Radiology*, 1980; 137: 475–79
3. Detlefsen S, Sipos B, Feyerabend B, Klöppel G: Pancreatic fibrosis associated with age and ductal papillary hyperplasia. *Virchows Arch*, 2005; 447: 800–5
4. Saisho Y, Butler AE, Meier JJ et al: Pancreas volumes in humans from birth to age one hundred taking into account sex, obesity, and presence of type-2 diabetes. *Clin Anat*, 2007; 20: 933–42
5. Stamm BH: Incidence and diagnostic significance of minor pathologic changes in the adult pancreas at autopsy: A systematic study of 112 autopsies in patients without known pancreatic disease. *Hum Pathol*, 1984; 15: 677–83
6. Ophir J, Céspedes I, Ponnekanti H et al: Elastography: A quantitative method for imaging the elasticity of biological tissues. *Ultrason Imaging*, 1991; 13: 111–34
7. D'Onofrio M, Crosara S, De Robertis R et al: Elastography of the pancreas. *Eur J Radiol*, 2014; 83: 415–19
8. Hirooka Y, Kuwahara T, Irisawa A et al: JSUM ultrasound elastography practice guidelines: pancreas. *J Med Ultrason*, 2015; 42: 151–74
9. Uchida H, Hirooka Y, Itoh A et al: Feasibility of tissue elastography using transcutaneous ultrasonography for the diagnosis of pancreatic diseases. *Pancreas*, 2009; 38: 17–22
10. Zhang Y, Tang J, Li YM et al: Differentiation of prostate cancer from benign lesions using strain index of transrectal real-time tissue elastography. *Eur J Radiol*, 2012; 81: 857–62
11. Sedelaar JP, Vijverberg PL, De Reijke TM et al: Transrectal ultrasound in the diagnosis of prostate cancer: State of the art and perspectives. *Eur Urol*, 2001; 40: 275–84
12. Cho N, Moon WK, Kim HY et al: Sonoelastographic strain index for differentiation of benign and malignant nonpalpable breast masses. *J Ultrasound Med*, 2010; 29: 1–7
13. Denis MC, Mahmood U, Benoist C et al: Imaging inflammation of the pancreatic islets in type 1 diabetes. *Proc Natl Acad Sci USA*, 2004; 101: 12634–39
14. Silverstein J, Klingensmith G, Copeland K et al., American Diabetes Association: Care of children and adolescents with type 1 diabetes: A statement of the American Diabetes Association. *Diabetes Care*, 2005; 28: 186–212
15. Iglesias-Garcia J, Domínguez-Muñoz JE, Castiñeira-Alvarino M et al: Quantitative elastography associated with endoscopic ultrasound for the diagnosis of chronic pancreatitis. *Endoscopy*, 2013; 45: 781–88
16. Janssen J, Schlörner E, Greiner L: EUS elastography of the pancreas: feasibility and pattern description of the normal pancreas, chronic pancreatitis, and focal pancreatic lesions. *Gastrointest Endosc*, 2007; 65: 971–78
17. Kawada N, Tanaka S: Elastography for the pancreas: Current status and future perspective. *World J Gastroenterol*, 2016; 22: 3712–24
18. Kielgast U, Holst JJ, Madsbad S: Antidiabetic actions of endogenous and exogenous GLP-1 in type 1 diabetic patients with and without residual  $\beta$ -cell function. *Diabetes*, 2011; 60: 1599–607
19. Itokawa F, Itoi T, Sofuni A et al: EUS elastography combined with the strain ratio of tissue elasticity for diagnosis of solid pancreatic masses. *J Gastroenterol*, 2011; 46: 843–53
20. Pezeshki Rad M, Farrokh D, Vakili R et al: The association between carotid intima-media thickness and the duration of type 1 diabetes in children. *Iran J Pediatr*, 2014; 24: 249–54
21. Goda K, Sasaki E, Nagata K et al: Pancreatic volume in type 1 and type 2 diabetes mellitus. *Acta Diabetol*, 2001; 38: 145–49