

From the Departments of Otolaryngology & Head and Neck Surgery and Neurosurgery  
Helsinki University Central Hospital  
Finland

# **VESTIBULAR SCHWANNOMA: POSTOPERATIVE RECOVERY**

Hilla Levo

*Academic dissertation*

*To be presented with the consent of the Medical Faculty of the University of Helsinki for public examination in the Auditorium of the Otolaryngological Hospital, Haartmaninkatu 4 E, Helsinki, on April 20<sup>th</sup>, 2001 at 12 o'clock noon.*

Helsinki 2001

## **Supervised by**

Professor Ilmari Pyykkö, M.D.  
Department of Otorhinolaryngology  
Karolinska Hospital  
Stockholm, Sweden

Göran Blomstedt, M.D.  
Department of Neurosurgery  
Helsinki University Central Hospital  
Helsinki, Finland

## **Reviewed by**

Docent Kalle Aitasalo, M.D.  
Department of Otorhinolaryngology  
Turku University Central Hospital  
Turku, Finland

Professor John Koivukangas, M.D.  
Department of Neurosurgery  
Oulu University Central Hospital  
Oulu, Finland

## **Opponent**

Docent Tapani Rahko, M.D.  
Department of Audiology  
Tampere University Central Hospital  
Tampere, Finland

ISBN 952-91-3309-X (kirja)

ISBN 951-45-9911-X (PDF)

© Hilla Levo

Yliopistopaino

Helsinki 2001

# CONTENTS

ABSTRACT .....	7
ACKNOWLEDGMENTS .....	8
LIST OF ORIGINAL PUBLICATIONS .....	9
ABBREVIATIONS .....	10
<b>1. INTRODUCTION</b> .....	<b>11</b>
<b>2. REVIEW OF THE LITERATURE</b> .....	<b>12</b>
2.1. Tumor characteristics .....	12
Epidemiology .....	12
Pathogenesis .....	12
Histopathology .....	13
Genetics .....	13
2.2. Symptoms .....	14
Hearing loss .....	14
Tinnitus .....	15
Vertigo .....	15
Cerebellar dysfunction .....	15
Trigeminal nerve dysfunction .....	15
Headache .....	16
Facial nerve dysfunction .....	16
Cranial nerve IX-XI palsies and long tract signs .....	16
Asymptomatic tumors .....	16
2.3. Diagnosis .....	16
2.3.1. Audiologic assessment .....	17
Pure tone audiogram and speech discrimination .....	17
Auditory brain stem response .....	17
2.3.2. Vestibular assessment .....	17
2.3.3. Imaging .....	17
2.4. Treatment .....	18
History .....	18
2.4.1. Surgery .....	18
Retrosigmoid (suboccipital) surgery .....	18
Translabyrinthine surgery .....	19
Middle cranial fossa surgery .....	20
2.4.2. Nonsurgical management .....	20
Conservative management .....	20
Stereotactic radiosurgery .....	21

2.5. Outcome .....	21
Complete tumor removal .....	21
Facial nerve .....	22
Hearing preservation .....	23
Contralateral hearing .....	24
Postural stability .....	24
Headache .....	25
<b>3. PURPOSE OF THE STUDY .....</b>	<b>27</b>
<b>4. MATERIAL AND METHODS .....</b>	<b>28</b>
4.1. Patients .....	28
4.2. Methods .....	29
4.3. Statistical methods .....	29
4.4. Ethics .....	30
<b>5. RESULTS .....</b>	<b>31</b>
5.1. Postoperative headache (I) .....	31
5.2. Postoperative headache (II) .....	32
5.3. Cochleolabyrinthitis (III) .....	33
5.4. Hearing preservation (IV) .....	34
5.5. Postural stability (V) .....	35
<b>6. DISCUSSION .....</b>	<b>38</b>
6.1. Methodological aspects .....	38
6.2 . Postoperative headache .....	40
6.3 . Sympathetic cochleolabyrinthitis .....	40
6.4 . Hearing preservation .....	40
6.5 . Postural stability .....	41
<b>7. CONCLUSION .....</b>	<b>42</b>
APPENDIX .....	43
REFERENCES .....	44
ORIGINAL PUBLICATIONS (I-V) .....	53

## ABSTRACT

The purpose was to characterize the postoperative outcome of patients with vestibular schwannoma (VS) by evaluating especially postoperative headache, contralateral hearing loss, hearing preservation and recovery of postural stability. Altogether 384 VS patients in Helsinki University Central Hospital were included in the study in addition to a survey on 97 patients operated on at Sahlgrenska Hospital, Gothenburg, Sweden.

Almost 60% of the VS patients suffered from headache after surgery. One year later headache persisted in 40% and it was more common among those with also preoperative headache. If headache continued for one year, it tended to be permanent. The most important risk factor for headache was retrosigmoid (RS) operation. No single mechanism for postoperative headache was found. However, a sumatriptan trial suggested that vascular structures may be involved in at least some cases.

After translabyrinthine (TL) operation contralateral hearing loss starting few week after surgery, was observed in 6% of the patients. After RS operation 1.8% of the patients developed a significant contralateral hearing loss which started after two to four years.

Hearing was preserved in 40% of the patients. Sixty-six per cent of these patients considered the preserved hearing a success, although in only 10 patients the preserved hearing was better than 30 dB. Tinnitus did not interfere with speech understanding.

Subjectively 31% of the patients had problems with gait, but based on measurements of postural stability deterioration occurred in 68% of the patients. The impairment of postural stability was usually slight. Most patients had good postural stability with eyes open, but with eyes closed the postural stability was poor. Advanced age, depression and the RS approach were risk factors for postoperative gait problems. Also female gender had a negative influence on recovery. Elderly patients had increased risk for poor vestibular compensation after surgery.

In conclusion, postoperative headache, although probably multietiological, may be caused by trigeminal neuropathy in the posterior fossa, where pain afferents trigger abnormal reflexes analogously with local vascular headache. If postoperative headache has continued for more than one year no significant reduction in the maximum pain intensity can be expected. The usefulness of preserved hearing was better than predicted and surgeons should continue to preserve hearing in VS surgery. Vestibular habituation therapy increased the use of proprioception and improved postural stability.

## ACKNOWLEDGMENTS

This work was carried out in the Department of Otorhinolaryngology, Helsinki University Central Hospital. I am grateful to Professors Jukka Ylikoski and Pekka Karma for providing me with the opportunity to work there and for placing the facilities of the Department at my disposal. Most of the data recordings were made there.

My deepest gratitude is devoted to my supervisors, Professor Ilmari Pyykkö and Göran Blomstedt, M.D. Ilmari Pyykkö had visionary ideas and ability to provide expert guidance. Combined with his enthusiasm, patience and support throughout the course of this work, they made this study possible. I received considerable help from Göran Blomstedt who had an essential role in helping me with the manuscripts. His fruitful scientific discussions and encouraging attitude toward the problems that arose during the work, are especially appreciated.

I am grateful to Heikki Aalto, for helping me with the many questions concerning technical problems throughout the course of this work and Pekka Honkavaara, M.D. for helping me with the final technical problems.

I am grateful for the assistance offered by librarians Marja-Leena Yli-Vakkuri, M.A., and Aino Nikupaavo, M.A., National Library of Health Sciences, Department of Otolaryngology and Mr Teo Hämäläinen from Helsinki University Central Hospital. They provided expert library assistance. The skillful linguistic revision has been done by Pekka Rikonen.

The work was reviewed by Docent Kalle Aitasalo, M.D, of the Department of Otorhinolaryngology, University of Turku and Professor John Koivukangas, M.D. of the Department of Neurosurgery, University of Oulu. Their constructive criticism and valuable comments were of great help.

Helsinki 25<sup>th</sup> of March, 2001

Hilla Levo

## LIST OF ORIGINAL PUBLICATIONS

This dissertation is based on the following articles, which will be referred to in the text by the Roman numerals I to V.

- I Levo H, Blomstedt G, Pyykkö I. Postoperative headache after surgery for vestibular schwannoma. *Ann Otol Rhinol Laryngol* 2000; 109(9): 853-8.
- II Levo H, Blomstedt G, Hirvonen H, Pyykkö I. Causes of persistent postoperative headache after surgery for vestibular schwannoma. *Clin Otolaryngol* (in press)
- III Pyykkö I, Levo H, Blomstedt G, Rosenhall U. Sympathetic cochleolabyrinthitis - an occult disease? *J Audiol Med* 1997; 6(1): 24-35.
- IV Levo H, Blomstedt G, Pyykkö I. Is hearing preservation useful in vestibular schwannoma surgery? *Ann Otol Rhinol Laryngol* (in press)
- V Levo H, Blomstedt G, Pyykkö I. Postural stability after vestibular schwannoma removal. *Neurosurgery* (submitted)

The publishers of these communications have kindly granted their permission to reproduce the articles in this thesis.

## ABBREVIATIONS

ABR	Auditory brain stem response
AID	Autoimmune inner-ear disease
CPA	Cerebellopontine angle
CSF	Cerebrospinal fluid
CT	Computerized tomography
HL	Hearing level
IAC	Internal auditory canal
MPQ	McGill Pain Questionnaire
MRI	Magnetic resonance imaging
NF1	Neurofibromatosis 1
NF2	Neurofibromatosis 2
POH	Postoperative headache
PTA	Pure tone average hearing level
RS	Retrosigmoid
SDS	Speech discrimination scores
SO	Suboccipital
TL	Translabyrinthine
VAS	Visual Analogue Scale
VAT	Vestibular autorotation test
VS	Vestibular schwannoma(s)



# 1. INTRODUCTION

Vestibular schwannoma (VS), previously called acoustic neuroma and neurinoma, is a benign growth of the eighth nerve sheath. The growth rate of VS is characteristically slow. The first symptom is usually a hearing loss indicating damage to the cochlear nerve and it may be due to tumor compression or invasion (Tos et al. 1998, Selesnick and Jackler 1992, Matsunaga et al. 1995). Vertigo is seldom present (Selesnick and Jackler 1992, Tos et al. 1998). The treatment of VS is mainly surgical, although other alternatives, such as stereotactic radiation therapy and conservative management also exist.



Figure 1. Arthur af Forselles (1864-1953), the first Professor of oto-rhino-laryngology in Helsinki University Central Hospital.

In 1913 af Forselles (Fig. 1) performed the first successful VS removal in Finland (af Forselles 1916). Two years after operation the patient was able to work although he had total facial paralysis and spontaneous nystagmus to the right. Historically, discussion of postoperative morbidity focused on complications such as meningitis, cerebrospinal fluid leak, intracranial hemorrhage, cerebral vascular accidents and brain compression injuries (Dandy 1934, Horrax and Poppen 1939, Driscoll et al. 1998). After the development of surgical technique postoperative mortality has decreased below 2%, facial nerve preservation has become routine and even hearing preservation is obtained in selected cases. The quality of life after surgery has become an issue and questions such as hearing preservation, tinnitus, dysequilibrium, headache, damage to the facial nerve and depression have arisen (Parving et al. 1992, Driscoll et al. 1998).

The object of the present work was to characterize the postoperative outcome and in particular the following aspects: 1. headache, 2. contralateral hearing loss, 3. hearing preservation and 4. postural stability.

## 2. REVIEW OF THE LITERATURE

### 2.1. Tumor characteristics

**Epidemiology.** VS is reported to occur in all races (Lanser et al. 1992). The tumor accounts for 6 to 10% of all primary intracranial tumors (Shiffman et al. 1973, Nager 1985, Tos et al. 1998), and for about 71 to 90% of all cerebellopontine angle tumors (Nager 1985, Tos et al. 1998). The incidence of occult VS estimated from autopsies of asymptomatic cases is about 1% (Karjalainen et al. 1984), but the real incidence of VS has been debated (Nestor et al. 1988, Lanser et al. 1992), and can even be lower (Selesnick et al. 1999). Tos et al. (1999) found a gradual increase in clinical incidence of VS during the last 20 years, which can be due to better diagnostic tools. The majority of the tumors were microscopic without clinical significance. Tos et al. (1999) suggest that the clinical incidence is 7.8 to 12.4 tumors per million per year.

Most commonly VS occurs during the fourth and fifth decades of life (Shiffman et al. 1973), and it is about two times as common in females as in males (Nager 1985). There are two distinct clinical presentations: sporadic unilateral VS and hereditary bilateral VS. Sporadic VS does not result in development of other tumors within the CNS or in transmission of the disease to the proband's offspring (Lanser et al. 1992). Bilateral schwannoma of the internal auditory canal (IAC) usually manifests itself during the second or third decade of life (Shiffman et al. 1973), and is often an expression of neurofibromatosis 2 (NF2) (Tos et al. 1998). NF2 is an autosomal dominantly inherited disorder with a high degree of penetrance, which predisposes to the development of vestibular schwannomas (usually bilateral) to affected individuals; schwannomas of the other cranial, spinal or peripheral nerves; meningiomas, both intracranial and intraspinal; and some low grade central nervous system malignancies (ependymomas, gliomas) (Evans et al. 1999). Bilateral tumors account for about 4-5% of all VS (Nager 1985, Evans et al. 1999).

Neurofibromatosis 1 (NF1) or von Recklinghausen's neurofibromatosis, a separate genetic disease resembling NF2, extremely rarely causes VS (Lanser et al. 1992, Tos et al. 1998).

**Pathogenesis.** VS is a benign growth of the eighth nerve sheath, an overproliferation of Schwann cells, usually beginning along the vestibular nerve within the IAC at the junction of peripheral and central myelin sheath (Shiffman 1973). VS is initially located in the vestibular division of the eighth nerve in the IAC in the majority of the cases (Henschen 1916, Ylikoski et al. 1978, Nager 1985, Rhoton and Tedeschi 1992).

VS is a slowly growing neoplasm and insidiously progressive in its development (Shiffman 1973). The tumor growth varies between -0.3 (shrinking) to 20 mm per year (Kawamoto et al. 1995), and is generally slow (Lesser et al. 1991). The progression of VS growth may be extremely difficult to determine (Lanser et al. 1992), as the VS may be dormant for several years and then grow rapidly. The growth has been categorized into one of three growth patterns: slow, medium and fast (Lanser et al. 1992). According to Rosenberg (2000) the vast majority of VS patients over 65 years of age have an overall growth rate of 0.9 mm per year when followed with MRI scans, and therefore these patients do not require intervention.

The growth of VS may affect all four nerves (the facial, the superior and the inferior vestibular, and the cochlear nerves) and blood vessels within the IAC (Shiffman 1973). In the beginning the tumor mechanically displaces the nerves and the vessels that are ultimately flattened against the canal walls. The expanding tumor widens or erodes the canal, and a portion of the tumor spills out of the porus and into the cerebellopontine angle. If the tumor growth progresses, the tumor finally contacts cranial nerves V and VI in the anteromedial direction and cranial nerves IX, X and XI in the inferior direction. The tumor compromises cerebrospinal fluid circulation when

it compresses the cerebellum and the brain stem. Tumor infiltration of the cochlear nerve has also been verified (Ylikoski et al 1978), although some suggest (Perre et al. 1990) that only neurofibromas, not schwannomas, infiltrate the cochlear nerve.

The typical sporadic unilateral tumor with expansive growth affects adversely the cochlear nerve by compression (Lanser et al. 1992). With NF2 patients the tumors tend to be more aggressive and will often infiltrate adjacent nerves (Lanser et al. 1992).

Bilateral eighth nerve tumors differ from unilateral ones in several ways. Bilateral lesions obviously reveal a multicentric growth pattern (Nager 1985), which reflects more often a fast growth pattern (Lanser et al. 1992). They can reach a remarkable size and can cause severe compression of the brain stem. The bony changes are also more extensive, and the tumor tends to invade the pneumatic cells and marrow spaces.

**Histopathology.** VSs are generally well demarcated and encapsulated, with a pale color and a firm consistence initially (Nager 1985). The color and consistency of the tumor varies with the amount of regressive changes (Nager 1985). Schwannomas are comprised of streams of elongated spindle cells, somewhat fibrous in appearance, and arranged into a characteristic palisade (Shiffman 1973), fascicle, stream or loop pattern (Nager 1985).

Within the VS there can be distinguished two types of tissue: a dense, cellular, fibrillar structure of the tissue type "A" of Antoni, and a loose, less cellular, reticular structure of the tissue type "B" of Antoni (Nager 1985). The histologic distinction of these two cell types is of no known clinical significance (Lanser et al. 1992). Regions of Antoni A and B may coexist within the same tumor.

**Genetics.** Neurofibromatosis type 2 (NF2) is an autosomal dominant disorder associated with bilateral VS. NF2s comprise about 5% of all VSs (Lanser et al. 1992). About half of the NF2s are sporadic and half of them are dominantly inherited. The genetic locus of NF2 has been localized in the long arm of chromosome 22 (22q) (Rouleau et al 1987, Keiser-Kupfer et al. 1989). The diagnosis of NF2 has been based on finding bilateral tumors of the 8th cranial nerves in MRI. The gene defect is in chromosome 22 and is called NF2-gene which is also a tumor growth suppressing gene (Seizinger et al. 1987). It is distinguished from NF1 where the gene defect is in chromosome 17 (Seizinger et al. 1987). NF1 presents with multiple peripheral neurofibromas with frequent cafe-au-lait spots on the skin. NF1 is not linked to vestibular schwannomas, except in some rare cases (Sadeh et al. 1989). Thus, it seems likely that VSs are all linked to the NF2 gene either by sporadic mutation or inherited defect of chromosome 22. Both NF1 and NF2 can also present with other tumors within the central nervous system (CNS) with somewhat different predilections. Thus NF2 has frequently been combined with meningiomas, fifth cranial nerve gliomas, intramedullary astrocytomas and spinal neurofibromas (Riccardi 1981, Evans et al. 1998).

NF2 was probably first reported by Wishart (1820) in a case with multiple intracranial tumors without cutaneous involvement but later confounded with findings of cases with both skin lesions and central nervous system tumors (see Evans et al. 1992). In the 1970's the distinction between the two types of neurofibromatosis (NF1 and NF2) became accepted (Kanter et al. 1980, Riccardi 1981). Subsequent studies have shown that patients with NF1 do not have an increased frequency of vestibular schwannomas when compared to the normal population (Evans et al. 1998). A further effort to separate the NF2 from the usual acoustic neuroma was made by the National Institute Health Consensus Conference (Dec. 1991) where the NF2 tumors were considered histologically analogous to schwannomas of the vestibular nerve. The conference recommended replacing the term acoustic neuroma in NF2 by VS.

## Chromosome 22 and NF2-gene locus

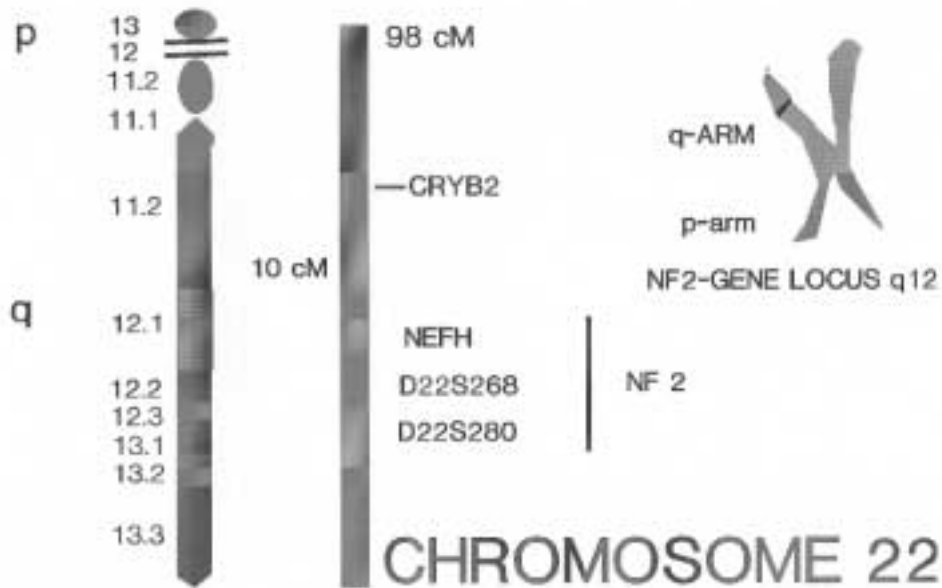


Figure 2. Flanking markers indicating location of NF2-gene in chromosome 22. (Sainio et al. 1995).

The location of the genetic defect of NF2 in the long arm of chromosome 22 lies in the vicinity of the meningioma translocation breaking point and the crystalline gene (Fig. 2). The spontaneous mutation rates and the breaking point in the long arm produce various subtypes of the disorders, some with frequent meningiomas, spinal tumors and posterior capsular cataracts, and some without these signs. Based on clinical observations two subtypes have been proposed: the so called Gardner and Wishart types (Evans et al. 1999). The Gardner type shows a relatively benign course and mainly bilateral schwannomas whereas the Wishart type shows early onset, rapid course and multiple other tumors in addition to bilateral VS (Evans et al. 1999).

### 2.2. Symptoms

Symptoms of VS have been known for over 150 years (Lanser et al. 1992). VS is commonly associated with hearing loss, but may manifest with other symptoms, too, which depend on the site of the origin and the growth pattern of the tumors (Tos et al. 1998).

**Hearing loss.** Hearing loss is the most common symptom of VS. It was the first symptom in 75% of the patients according to Thomsen and Tos (1990) as well as Rosenberg (2000). Hearing loss develops gradually over months or years and manifests as a high frequency unilateral sensorineural hearing loss (Thomsen and Tos 1990). It is associated with impairment of speech discrimination more than expected from the level of hearing loss (Johnson 1977, Schuknecht and Woellner 1955). Among patients with sudden sensorineural hearing loss only 2 to 5% have CPA tumors (Saunders et al. 1995, Doyle 1999), but among patients with VS, from 10 to 26% have had sudden hearing loss (Higgs 1973, Selesnick et al. 1993). According to Selesnick and Jackler (1993) in 15% of patients with VS hearing was subjectively normal at the time of the diagnosis, but only 4% had normal hearing in pure tone audiometry. Thomsen and Tos (1990) recorded in 3 % the patients with VS normal hearing in audiometry at the time of the diagnosis. According to Selesnick et al.

(1993) the incidence of hearing loss as a complaint increased with the size of the tumor: 77% with the tumor less than 1 cm, 88% with the tumor 1 - 3 cm and 95% with the tumor larger than 3 cm. The average duration of hearing loss was 3.9 years before diagnosis.

The exact mechanism causing hearing loss in VS is not certain, but compression of the cochleovestibular nerve by the tumor and compromise of the blood supply to the nerve or to the cochlea are possible explanations (Perre et al. 1990). Compression varies with the tumor growth rate, the location of the tumor within the IAC, and the neural origin of the tumor (Perre et al. 1990). Vascular compromise can lead to either gradual or sudden hearing loss, whereas compression of the cochleovestibular nerve may lead to gradual hearing loss (Higgs 1973, Perre et al 1990). Vascular compromise of the cochlear nerve by the tumor mass or hemorrhage seems to be the mechanism behind sudden hearing loss in VS (Higgs 1973), which was a presenting symptom in 8.2% to 13.8% of the patients (Rosenberg 2000).

**Tinnitus.** Tinnitus is commonly present in VS and may vary in character. It is very seldom the reason for the investigations, and is often overshadowed by the hearing loss (Mathew et al. 1978). Rosenberg (2000) found tinnitus present in 10.2 to 17.5% of cases. According to Parving et al. (1992) 62% of the patients complained of tinnitus. Tinnitus was present in 53% of the patients with small tumors, in 59% of those with medium size tumors and in 52% of those with large tumors. It was an early symptom in 36% of the patients, but seldom the sole initial symptom (Selesnick et al. 1993). From a database of 174 patients having unilateral tinnitus only one VS was detected according to Dawes and Basiouny (1999). The mechanisms for tinnitus are thought to be the same as those for hearing loss: neural compression or vascular derangement (Selesnick et al. 1993).

**Vertigo.** Vertigo can be described as an illusion of motion (Stewart et al. 1999) and it usually occurs relatively early in the clinical course of VS, and after lasting for days or weeks then spontaneously resolves (Selesnick and Jackler 1992). As vertigo resolves, dysequilibrium, a sense of floating or unsteadiness, may begin (Selesnick and Jackler 1992). Symptoms are usually mild or moderate in intensity but rarely disabling. Severe vestibular symptoms begin relatively late in the course of the tumor growth and tend to be continuous and unremitting (Selesnick et al. 1993). Rosenberg (2000) found dysequilibrium present in 20% to 30.7% of the cases and vertigo in 16% of the cases. Fifty-seven percent of the patients had experienced dysequilibrium before surgery according to Parving et al (1992). Selesnick et al. (1993) found 48% of the patients having experienced dysequilibrium: it was present in 37% of the patients with tumor less than 1 cm, in 47% of the 1 to 3 cm tumors and in 71% of the tumors larger than 3 cm.

The etiology of vertigo is most probably tumor infiltration or compression of the vestibular nerve, or compromise of vascular structures or the cerebellum. The distortion of vestibular information from the side of the tumor is gradually compensated for (Magnusson et al. 1992).

**Cerebellar dysfunction.** Cerebellar dysfunction is usually caused by gradual lateral compression (Selesnick and Jackler 1992), so midline structures of the cerebellum are rarely involved. Cerebellar symptoms are manifested as incoordination, ataxia, or dysequilibrium. Cerebellar dysfunction can cause dysequilibrium alone or in combination with vestibular function loss (Selesnick and Jackler 1992). Symptoms begin late in the course of tumor growth. Thomsen and Tos (1990) found cerebellar dysfunction in as many as 45% of the patients, but Rosenberg (2000) in 1.3% to 14.3% of the patients.

**Trigeminal nerve dysfunction.** Trigeminal dysfunction appears as hypoesthesia or paresthesia, most frequently in the midfacial region (Selesnick et al. 1993). It is thought that the earliest trigeminal symptom is the absence of the corneal reflex. Further progression leads to midfacial tingling followed by upper and lower face tingling (Selesnick and Jackler 1992). Facial pain may

occur but is unusual (Snow and Frazer 1987).

In one series the incidence of trigeminal sensory symptoms was 20% of the patients and was dependent on tumor size (Selesnick et al. 1993). No patients with tumor less than 1 cm had trigeminal symptoms, whereas 20% with tumor of 1 to 3 cm and 48% with the tumor larger than 3 cm had trigeminal symptoms. Trigeminal nerve dysfunction was the initial symptom in 3% of the patients (Selesnick et al. 1993). Thomsen and Tos (1990) found the trigeminal nerve affected in 28% of the patients, and in tumors larger than 4 cm 53% were affected. Trigeminal nerve symptoms are thought to arise secondary to compression of the nerve in the CPA between the superior aspect of the nerve and tentorium (Selesnick and Jackler 1992).

**Headache.** Classically cephalalgia secondary to an intracranial lesion is constant, dull, diffuse pain that is gradual in onset and is usually apparent late in the course of the tumor growth as a sequel of hydrocephalus (Selesnick and Jackler 1992). Headache due to VS occurs in a minority of the patients. Pain is often found to be worst in the morning and precipitated by head motion and exertion (Edwards and Patterson 1951).

In one study headache was present in 19% of the patients and the frequency increased as the tumor size increased (Selesnick et al. 1993). Patients with tumor less than 1 cm had no headache, with tumor size 1 to 3 cm 20% had headache and when the tumor was larger than 3 cm 43% of the patients had headache.

Headache, nausea, vomiting, decreased visual acuity, diplopia, anosmia, and obtundation are associated with increased intracranial pressure. They may occur late in the case of a large tumor, tend to be gradual in onset, and are persistent (Selesnick and Jackler 1992). Selesnick et al. (1993) found 4% of VS patients having hydrocephalus at the time of diagnosis, and none of them complained of headache.

**Facial nerve dysfunction.** Facial nerve dysfunction is rare. It manifests gradually, late in the course of the tumor growth, and is rarely seen with small or medium size tumors (Selesnick and Jackler 1992). Dysfunction can be either hypofunction, manifested as facial weakness, and/or hyperfunction, manifested as facial twitch or spasms. Selesnick et al. (1993) found facial nerve dysfunction in 10% of the patients with no relationship to tumor size. It was present in 7% of patients with small tumors, in 11% of patients with medium tumors, and in 10% of patients with large tumors. The average duration of facial nerve dysfunction was 0.6 years prior to diagnosis, and it was present as an initial symptom in only 2% of patients. Thomsen and Tos (1990) found involvement of the intermedius nerve in 48% of patients. In their study facial nerve function was normal in 89%. Syms III et al. (1997) found normal facial nerve function in 96% of the patients.

**Cranial nerve IX-XI palsies and long tract signs.** Clinically palsies of cranial nerves IX-XI present as dysarthria, dysphagia, aspiration, or hoarseness. Long tract signs present as ipsilateral lower or upper extremity dysfunction. These lower cranial nerve palsies and long tract signs rarely occur in VS (Selesnick et al. 1993).

**Asymptomatic tumors.** A new asymptomatic group of patients with VS has appeared when the MRI has been taken for other reasons (Selesnick et al. 1999). With widespread use of MRI asymptomatic VSs are occasionally found (Anderson et al. 2000).

### 2.3. Diagnosis

In 1917 when Cushing reviewed his first series of VS, the landmarks for assessing VS were the history of unilateral hearing loss, cerebellar signs, and physical examination (Cushing 1917). At that

time audiometry was in its infancy. Cushing employed caloric testing with visual inspection on his patients and found that 83% had evidence of vestibular dysfunction (Cushing 1917). He also noted that all the patients had either marked hearing loss or complete deafness and frequently tinnitus. Af Forselles (1916) described a patient with tinnitus in the right ear for 8 years, diplopia since the previous spring, headache more on the right side for 3 months, both hearing loss and vision deterioration on the right, dysequilibrium for one month, stiffness on the right side of the face, and during the last 3 weeks also digestion problems and vomiting. Af Forselles found trigeminal hypoesthesia, facial paralysis and hearing loss in the right, and spontaneous nystagmus both to the left and right. The Caloric test to the right ear gave no reaction, the Romberg test was unstable, the tongue deviated to the right and the sensitivity was also reduced in the right side of the tongue. The diagnosis was tumor of the acoustic nerve.

### 2.3.1. Audiologic assessment

**Pure tone audiogram and speech discrimination.** In pure tone audiometry the hearing loss in VS can be described by the shape of the audiogram: flat or high-tone loss (Selesnick and Jackler 1992). Usually hearing loss in VS is characterized by poor speech discrimination (Johnson 1977, Schuknecht and Woellner 1955).

**Auditory brain stem response.** Auditory brain stem response (ABR) is the most reliable audiologic examination in assessing VS (Ramsden 1995, Doyle 1999). The auditory stimulus elicits through the auditory pathway distinct but weak electrical activation waves that are hidden behind normal brain activity. The characteristic ABR waveform is amplified, filtered, and averaged over a time period. Electrical activity from the auditory nerve is represented in waves I and II. Waves III and V represent presumably synchronous discharge from the cochlear nuclei and the inferior colliculus in the midbrain. Waves III and V are the largest and most reliable waveforms in clinical use. Wave amplitude, latency, and interval between ears are the characteristics commonly measured. The interaural wave I-V latency differences are the most reliable parameters in the diagnosis of CPA tumors. When one ear has normal hearing and the hearing in the ear on the side of the tumor is better than 50 dB at 4 kHz, the normal difference is less than 0.2-0.3 msec (Doyle 1999). Small VS may be associated with normal ABR in 10% to 30% of patients. (Doyle 1999). Thus, ABR was the most accurate of the noninvasive tests in screening for VS before the development of magnetic resonance imaging (MRI) (Brackmann 1999). Robinette et al. (2000) recommend the use of ABR together with MRI, which allows considerable savings if the patient has a low risk for VS.

### 2.3.2. Vestibular assessment

Selesnick and Jackler (1992) found spontaneous nystagmus uncommon among patients with VS. The pathology of unilateral involvement can be localized with the caloric tests if it is abnormal. Today, when even nonsymptomatic small tumors are discovered, ENG abnormalities are no longer a golden standard for assessing VS (Daniels et al. 1996).

Other vestibular tests are available at present, such as the head autorotation test, the rotatory chair tests, and the posturography test (O'Leary et al 1991, Johansson et al 1995). These tests evaluate simultaneously the function of both vestibular organs and have limited value in localizing unilateral CPA tumors (Selesnick and Jackler 1992).

### 2.3.3. Imaging

Roentgen introduced diagnostic imaging in 1895, and Henschen (1910) was the first to use it to detect the erosion of the porus acusticus (Selesnick and Jackler 1992).

Computerized tomography (CT) was previously used as a reliable examination (Curtin and Hirsch 1992), but contrast medium is needed to detect a tumor on CT because of the minimal density differences between the VS and brain tissue (Curtin and Hirsch 1992). With intravenous contrast medium approximately 70% of VS can be detected with CT. Intracanalicular VS are difficult to detect even after contrast injection, since bone and enhancing tumor tissue are essentially equally dense. Only tumors projecting more than 5 mm into the CPA are regularly detected (Brackmann 1999). The reliability of CT is reduced in the CPA due to artifacts from the surrounding bony structures. MRI is today the standard in assessing patients with possible VS (Brackmann 1999, Doyle 1999). On MRI the VS has the same density as brain tissue. MRI is superior to CT because on MRI bony structures appear black and cause less artifacts. The VS enhances intensely with contrast medium, such as gadolinium, and thus virtually all tumors larger than 2 mm, including those in the IAC, appear brightly white against black bone or (on T1 weighted images) black cerebrospinal fluid (CSF) (Doyle 1999, Brackmann 1999).

## 2.4. Treatment

**History.** The first successful removal of an acoustic tumor was accomplished by either Sir Charles Ballance in 1891 or Thomas Annandale in 1895 (Cushing 1917, Ramsden 1995). In the absence of histologic evidence the exact nature of either of the tumors is not known. At the turn of the century Horsely had a series of six surgically treated acoustic tumors and at least one of the patients made an excellent recovery (House and Graham 1973). Krause described unilateral suboccipital (SO) craniectomy in 1903 (Krause 1903, Krause 1906). In 1904 Panse suggested an approach through the labyrinth, that could be the more direct route to the tumor, because it avoided some of the problems associated with cerebellar exposure (Panse 1904). Only a few successes were recorded because of the difficulty in controlling bleeding, the inability to cope with cerebellar swelling, and the limitations imposed by the size of the opening of the skull itself (House and Graham 1973).

In 1917 Cushing described the bilateral suboccipital approach, in which the posterior fossa was widely exposed (Cushing 1917). By carrying out a subtotal enucleation of the tumor and using wide bony decompression of the posterior fossa he was able to reduce surgical mortality to 10%. Dandy reintroduced in 1925 a concept of unilateral exposure of the cerebellopontine angle using a bilateral suboccipital craniectomy as proposed earlier by Krause (Dandy 1925) with even lower mortality rates than Cushing.

### 2.4.1. Surgery

**Retrosigmoid (suboccipital) surgery.** The retrosigmoid approach to the posterior fossa is a modification of the neurosurgical suboccipital craniotomy or craniectomy (for review see Cohen, 1992). It gives a wide view of the posterior fossa. The approach was traditionally performed at the sitting position, but has undergone many modifications.

*Retrosigmoid approach (Cohen 1992). During the operation the patient is in the supine position, with the head turned away from the operator. The skin incision is based anteriorly and centered at the approximate location of the transverse sinus. After craniotomy, which measures 3 to 5 cm, is performed, an anteriorly based dural flap is incised exposing the cerebellum. The cerebellum generally tends to fall away from the tumor, allowing the opening into the cerebellopontine cistern, with release of cerebrospinal fluid.*

*The cerebellum is then retracted medially to expose the tumor. The tumor may be decompressed with the use of an ultrasonic aspirator, if it is bulky. In the case of intracanalicular tumor when cerebellar retraction is minimal, the tumor can usually be excised in one piece. If necessary the tumor is dissected off the cerebellum and brain stem depending on the size of the tumor. The facial nerve can be identified near or at the brain stem. Every attempt is made not to*



*open the posterior semicircular canal or vestibule if hearing preservation is a goal. Up to 7 mm of the posterior IAC wall can generally be removed without endangering the posterior semicircular canal. It is usually possible to recognize the lateral end of the tumor. It is important also to drill superior and inferior to the canal to expose the circumference of the canal, leaving only the anterior wall intact. This allows much easier and less traumatic dissection of the tumor off the nerves.*

*Dissection of the lateral end of the tumor should reveal the origin from the superior or inferior vestibular nerve. When the vestibular nerves are cut laterally, a plane is established between the tumor and the facial nerve superiorly and the cochlear nerve inferiorly. Dissection can proceed either from lateral to medial or medial to lateral. A plane is developed between the tumor and the cochlear nerve and dissection proceeds to remove the entire tumor with preservation of both facial and cochlear nerves.*

**Translabyrinthine surgery.** Approaches to the cerebellopontine angle through the temporal bone had been advocated already in 1904 by Panse (House and House 1964). The route is generally called translabyrinthine since it passes through the mastoid and the labyrinth. In 1964 House reported 54 patient cases of whom 41 underwent the translabyrinthine approach. The translabyrinthine approach is the most direct route to the CPA. Large tumors can be resected through the translabyrinthine approach (Jackler 1994). Sacrifice of residual hearing is a disadvantage of this approach. This method seemingly has the lowest mortality, approximately 0.4%, and possibly also the lowest morbidity (Brackmann and Green 1992).

*Translabyrinthine approach (House and House 1964, Brackmann and Green 1992). In the translabyrinthine approach the patient is placed in the supine position with the head turned to the opposite side. A complete mastoidectomy is performed down to the level of the horizontal semicircular canal after which labyrinthectomy is begun. The opening along the superior petrosal sinus is gradually deepened and widened until the labyrinthine bone is encountered. The lateral and posterior semicircular canals are progressively removed, and the facial nerve, which lies anteriorly, is carefully approached. The superior semicircular canal is followed to its ampulla. The vestibule is opened, and the facial nerve skeletonized from the genu inferiorly to near the stylomastoid foramen. The skeletonizing is done from the posterior direction allowing access to the CPA.*

*Dissection of bone surrounding the IAC is started after the labyrinthine bone has been removed to the level of the vestibule. It is started along the superior petrosal sinus and gradually enlarged in all directions toward the IAC. The dura is identified posteriorly. Dissection is carried inferior to the labyrinth until the blueness of the dome of the jugular bulb is seen through the overlying bone.*

*The vestibular aqueduct and the beginning of the endolymphatic sac are incised and bone is further removed along the posterior fossa dura beneath the sigmoid sinus. After the cochlear aqueduct is identified, bone removal is continued around the IAC to the porus acusticus until the entire posterior lip of the IAC is removed. The bone of the posterior fossa dura is removed inferiorly until the sigmoid sinus is skeletonized. Dura is opened anterior to the sigmoid sinus in front of the IAC.*

*Dissection is carried superiorly and anteriorly around the IAC leaving facial nerve intact. The superior lip of the porus acusticus is removed, but not entirely. Dissection of the lateral end of the IAC begins inferiorly. The transverse crest is identified. After the dissection around the IAC is completed, the posterior fossa dura is opened to expose the CPA.*

*The dura is incised over the midpoint of the IAC. The vessels on the surface of the tumor are avoided. The tumor removal can begin intracapsularly to reduce the tumor size if the tumor is large, and if no nerve bundles are inspected on the posterior surface. During intracapsular removal extensive movement of and pressure on the tumor must be avoided, to avoid injury to the facial nerve.*

*After the inferior end of the tumor has been gutted the surface of the capsule is followed to the brain stem. Inferiorly the IXth cranial nerve and often large vessels are localized. They are*

*separated from the tumor capsule. The plane of the facial nerve is established at the lateral end of the IAC. The facial nerve can often be followed without difficulties even past the area of adhesions.*

*After the facial nerve has been separated from the tumor all the way to the brain stem, the bulk of the tumor is removed, leaving only a small bulk attached to the brain stem, which is then removed.*

**Middle cranial fossa surgery.** The middle cranial fossa approach was reported for vestibular nerve section in 1904 (House and Shelton 1992). The primary indication for the middle fossa approach in VS surgery is a small tumor that is confined to the IAC or protrudes only slightly into the posterior fossa (House and Shelton 1992), but Wiegand (1989) has extended those criteria to larger tumors. This route allows the removing of laterally placed tumors with visual control, preservation of hearing, preservation of function of the facial nerve, avoidance of injury to the brain stem or cerebellum, a minimal amount of vertigo, and a low postoperative morbidity (House and Shelton 1992, House and Graham 1973). With the middle cranial fossa approach there is a small recess at the fundus that cannot be exposed (Haberkamp et al. 1998).

Many authors (Shelton 1992, Fisch 1970, Glasscock 1969, House 1961) favor the use of the middle cranial fossa approach.

*Middle fossa approach (Shelton 1992). During the operation the patient is placed in the supine position with head turned to the side. The incision is in the pretragal area extending superiorly in a gentle curve fashion. An approximately 2.5 cm square craniotomy located two-thirds anterior and one-third posterior to the external auditory canal, is made.*

*The dura from the floor of the middle fossa is elevated. The middle meningeal artery is the initial landmark, marking the anterior extent of the dissection. The dural dissection proceeds in a posterior and anterior fashion. The petrous ridge is identified while avoiding injury to the petrosal sinus. The arcuate eminence and greater superior petrosal nerve are identified; they are the major landmarks to the subsequent intratemporal dissection.*

*After the dura is elevated, a retractor supports the temporal lobe. The blue line of the semicircular canal is identified by drilling at the arcuate eminence. The greater superior petrosal nerve medial to the middle meningeal artery is followed posteriorly to the geniculate ganglion. The labyrinthine portion of the facial nerve is medial to the ganglion. Bone is removed from the superior surface of the IAC down to the porus acusticus internus. The lateral end of the IAC is dissected. The dura of the IAC is divided along the posterior aspect. The facial nerve is followed in the anterior portion of IAC. The superior vestibular nerve is cut at its lateral end and vestibulofacial anastomotic fibers are divided. The tumor is separated from the facial and cochlear nerves. The inferior vestibular nerve is divided, and the tumor is gently freed from the lateral end of the IAC. The tumor is then separated from the cochlear and facial nerves and removed. The internal auditory artery is preserved if hearing is to be preserved.*

#### 2.4.2. Nonsurgical management

**Conservative management.** Improved diagnostic screening with MRI and also a better informed population have resulted in the diagnosis of smaller and even nonsymptomatic VS (Selesnick et al. 1999, Rosenberg 2000). Surgical removal may pose a risk for complications requiring a conservative management strategy (Nedzelski et al. 1992, Fucci et al 1999, Rosenberg 2000). This policy assumes that according to its pattern of growth the tumor will not result in either mortality or significant morbidity within the expected life span of a given patient (Levo et al. 1997). Rosenberg (2000) advises that the majority of the VS patients over 65 years of age do not require intervention. The indication for an intervention should be based on a combination of tumor growth pattern and the severity of symptoms (Rosenberg 2000).

**Stereotactic radiosurgery.** Stereotactic radiosurgery or gamma knife radiosurgery was first time used to treat VS patient in 1969 (Leksell 1971) at the Karolinska Institutet in Stockholm, Sweden. In stereotactic radiosurgery intracranial targets are destroyed using single high dose of focused ionizing radiation. Radiation is administered using stereotactic guidance (Leksell 1969). Tumor growth control was achieved, but incidence of facial or trigeminal dysfunction was also apparent (Pollock et al. 1998). MRI, improvement of dose-planning software and the gradual reduction of radiation dose are important changes in VS radiosurgery (Pollock et al. 1998). The development of a Linac-based system, in which multiple radiation arcs are used to cross-fire photon beams at a target defined in stereotactic space, has improved the accuracy and precision of dose delivery (Niranjan and Lundsford 2000), although also the cost is higher. Although surgery is the treatment of choice for most patients with VS, radiosurgery can be good alternative for those with tumor recurrence (Pollock et al. 1998) or with bilateral tumors (Poen et al. 1999).

## 2.5. Outcome

Cushing (1917) described his mortality rates: *“after the first operation the surgical mortality was 100%. After the first 10 cases it was lowered to 40%, after 15 cases it had dropped to 33.3%, after 20 cases to 30%, after 25 cases to 24%, and after 30 cases to 20%; and it must continue to fall until it drops to 10 or to 5% or better, even though the total figures must carry the burden of early inexperience.”*

Microscopic VS surgery when performed by well-qualified surgeons is associated with relatively low morbidity and mortality rates (Irving et al. 1995, Wiet et al. 1992). With microsurgical technique and modern anesthesia, mortality has fallen from 20% (Hardy et al. 1989). In the 1950s mortality rates were 16% and normal facial nerve function rates 3% (Irving et al. 1995). In 1985 postoperative mortality was 5%, all among patients with large tumor (Welch and Dawes 1985). In 1995 the mortality was reported to be 2-3% with normal facial function in 48-67% of the patients (Irving et al. 1995).

House and House (1964) reported three major complications: hemorrhage (4.9%), meningitis (5.7%), and cerebrospinal fluid leak (9.4% required secondary surgical closure), the mortality being 5.4%. Although the permanent complication rate is very low, cerebrospinal fluid leakage can occur in up to 20% of patients, the majority owing to poor intraoperative identification of exposed air cells within the temporal bone (Wackym et al. 1999). In the patient series of Hardy (1989) 13% of the patients had CSF leakage, part of them developing meningitis (Hardy et al. 1989).

The quality of life after VS surgery is an important measure of outcome of surgery, although various results of facial nerve function following surgery suggest that an increase in tumor size increases morbidity, and that postoperative facial nerve function directly relates to tumor size (Irving et al. 1995). The patient's perspective has been considered in only a few studies (Irving et al. 1995). Poor outcome appears to be relatively independent of the age of the patient according to Irving et al. (1995), and age alone should not be considered a contraindication to surgery.

**Complete tumor removal.** According to Welch and Dawes (1985) complete tumor excision with suboccipital operation was possible in 84% of the patients with no recurrences seen in 5 to 7 years. In 1989 Hardy et al. reported 3 perioperative deaths among 100 TL operations, and the postoperative morbidity was low. Complete tumor excision was achieved in 97% and no recurrences were seen during follow up of 1 to 7 years (Hardy et al. 1989).

A question of debate is subtotal tumor removal (Wiet et al. 1992). Subtotal removal has been used in patients with advanced age or in those who wish to decrease complication risks associated with the VIIth cranial nerve (Wiet et al. 1992). Lownie and Drake (1991) found a

recurrence rate of 18%. The surgical route can impose anatomic limitations (Wackym et al. 1999). Incomplete tumor removal especially within the IAC is possible after suboccipital or translabyrinthine resection (Wackym et al. 1999). With the retrosigmoid approach Haberkamp et al. (1998) had a recurrence rate of 2.4%, compared with 44% for El-Kashlan et al. (2000) after incomplete resection.

**Facial nerve.** Historically, discussion of postoperative morbidity has focused on complications such as meningitis, cerebrospinal fluid leaks, intracranial hemorrhage, cerebral vascular accidents, and compression injuries (Driscoll et al. 1998). With improvement of surgical management mortality has dropped under 2%, the facial nerve is routinely saved, and hearing preservation is obtained in selected cases. Thus quality of life issues such as dysequilibrium, headache, and depression become more important (Driscoll et al. 1998).

Anatomical preservation of the facial nerve with complete tumor removal, especially in patients with large tumors, is still a challenge (Wiet et al. 1992). Facial nerve monitoring has greatly aided separation of the facial nerve from the tumor (Wiet et al. 1992). When 10% of the functioning motoneurons are intact normal facial nerve function is preserved (Axon and Ramsden 1999). In a study by Hardy et al. (1989) the facial nerve was preserved in 82% of the 98 patients with intact nerve preoperatively, and postoperatively 77 patients assessed their life quality to be excellent (Hardy et al. 1989).

The results of postoperative facial nerve function in VS surgery from different surgical teams in Helsinki University Central Hospital (Fig. 3) show the time before the operating microscope era, and the time with facial monitoring (Blomstedt, unpublished data).

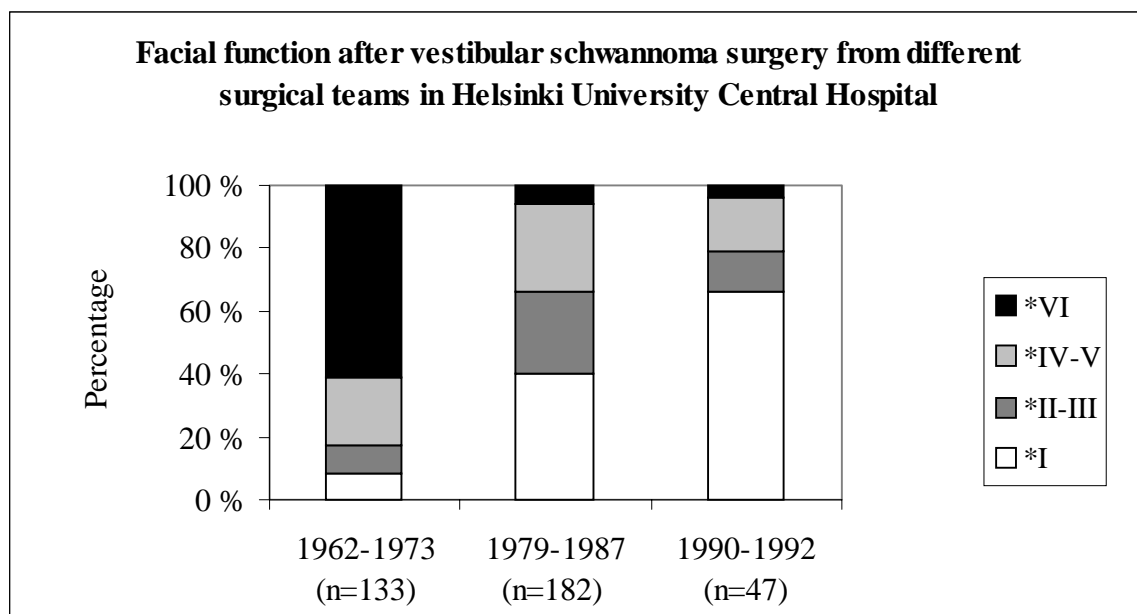


Figure 3. Postoperative facial nerve function after vestibular schwannoma surgery from three different surgical teams in Helsinki University Central Hospital. (\* = House- Brackmann scale (House and Brackmann 1985))

The facial nerve is sometimes severed during the removal of VS, either intentionally to ensure complete tumor removal, or unintentionally because of difficulties in identification of the nerve. The risk for permanent facial paralysis increases with the size of the tumor (Harner and Ebersold 1985). In a study by Jääskeläinen et al. (1990) altogether 36 facial nerves out of 219 patients were severed during years 1979 to 1987. Twenty-five facial nerves were cut intentionally

to ensure complete tumor removal, and 11 unintentionally because of difficulties in identification. Ramsay and Blomstedt (1999) studied the results of 90 adherent tumors. They left remnants of tumor on the facial nerve in order to preserve the facial anatomical integrity of the nerve. Functionally 94% of the patients had House-Brackmann grading IV or better postoperatively and regrowth occurred in 9% of the cases (Ramsay and Blomstedt 1999). Eighty-five percent out of 48 patients had normal facial function immediately after operation according to Aitasalo et al. (1999).

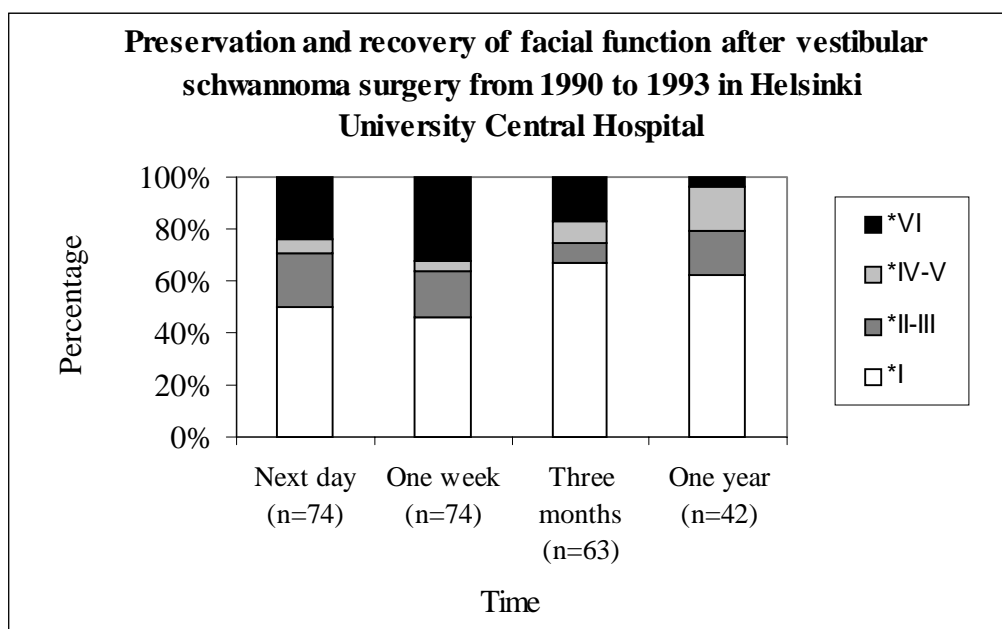


Figure 4. The preservation percentage and recovery of facial function after vestibular schwannoma surgery during years 1990 to 1993 in Helsinki University Central Hospital. (\* = House – Brackmann scale)

Recovery of the facial nerve after surgery was followed during years 1990 to 1993 (Fig. 4) in Helsinki University Central Hospital (Blomstedt, unpublished data). Although facial nerve, neuromonitoring, and the postoperative outcome of facial nerve were not in the scope of the present study the outcome of facial nerve was analyzed and used in different outcome analysis to evaluate dependencies between various factors, such as postoperative headache, recovery of postoperative stability and hearing preservation.

**Hearing preservation.** In VS surgery hearing can be preserved using either the retrosigmoid (suboccipital) or the middle fossa approach (Shelton 1992) (Table 1).

Preoperative criteria for choosing patients for hearing preservation vary (Shelton 1992). Some authors propose that the risk for morbidity is too high compared to low likelihood of success (Tos and Thomsen 1982). Most surgeons consider the limit for hearing preservation in the RS approach being tumor size less than 2 cm (Glasscock et al. 1987) and in middle cranial fossa approach less than 1.5 cm (Sanna et al. 1987). Intraoperative auditory nerve monitoring during surgery is useful for hearing preservation (Shelton 1992), although the absence of an ABR at the end of the surgery does not always mean that hearing preservation has failed (Ojemann et al. 1984). Measurable postoperative hearing remains in 12 to 65% of patients (Shelton 1992). Hearing preservation in cases of bilateral tumors, which tend to be more invasive than unilateral ones and

tend to involve the cochlear nerves, is difficult (Bance and Ramsden 1999), but is not impossible (Samii and Matthies 1997, Glasscock et al. 1987).

Table 1. Hearing preservation after vestibular schwannoma surgery according to the literature.

	Year	Patients (number)	Approach	Tumor size (mean)	Hearing preserved
Harner et al	1984	119	MCF	17mm	12%
Palva et al	1985	30	RS	<20mm	43%
Silverstein et al	1985	13	RS		38%
Kemink et al	1990	20	RS	15.5mm	65%
Hoehmann	1991	41	MCF	17<10mm, 22 10-20mm, 2>20mm	46%
Cohen et al	1993	146	RS	10.2mm	26%
Glasscock et al	1993		MCF, RS		
unilateral		136		49 IC, 75<10mm,12<20mm	35%
bilateral		22		9 IC, 13<10mm, 3<20mm,1>20mm	44%
Dornhoffer et al	1995	93	MCF	(65<5mm, 11 5-10mm, 17 10-15mm)	58%
Umezu et al	1996	51	RS transmeatal	15.7 mm/22.8 mm	41.2%
Samii and Matthies	1997	732	RS		39.5%
Kanzaki et al	1998	94	MCF	6.9 mm	50%
Ishikawa et al	1998	43	MCF	1 IC, 18<10mm,10 10-20mm, 10>20mm	41%
Slattery et al	1998	18	MCF	11mm	65%

Abbreviations: MCF = middle cranial fossa, RS = retrosigmoid, IC = intracanalicular

**Contralateral hearing.** Contralateral hearing loss after surgery is a rare complication that can have immediate or delayed onset (Wiet et al. 1992). It has been reported to occur in the recovery room, during the first postoperative week, months after surgery and several years after surgery (Greiner et al. 1971, Clemis et al. 1982). Harris et al (1985) have proposed that sympathetic cochleolabyrinthitis may occur in up to 1.3% of the patients.

**Postural stability.** Vertigo and imbalance postoperatively may be caused by vestibular or cerebellar dysfunction (Wiet et al. 1992). Vestibular disability may persist in elderly patients (Wiet et al. 1992). According to Wiet et al. (1992) most of VS arise from the vestibular nerve, and therefore vestibular function has already been considerably reduced or even totally lost before surgery and immediate postoperative vertigo is usually minimal. It is also thought that if postoperative imbalance does occur from absence of vestibular compensation, it is usually transient and diminishes within some weeks, and although it may persist longer in some older patients, it seldom causes significant disability (Wiet et al. 1992) (Table 2).

Table 2. Postoperative balance problems after vestibular schwannoma surgery reported in the literature.

	Year	Patients (number)	Approach	Balance problems
Magnusson et al	1991	57	TL	stiffness increased with eyes open
Parving et al	1992	273	TL	56% dizziness 6 months after surgery
Jorgensen and Pedersen	1994	46	TL	30 out of 44 vertigo
		13	RS	8 out of 9 vertigo
Pyykkö et al	1994	224	RS/TL	41% slight postural instability 41% moderate postural instability 3% could not walk without help
van Leeuwen et al	1996	134	TL/RS	more vertigo after TL
Rigby et al	1997	130	TL,RS,MCF	14.3% balance troubles
Andersson et al	1997	141	TL	45% balance problems 19% dizziness
Driscoll et al	1998	210	RS	31% balance problems
Lynn et al	1999	237	RS	65% balance problems

Abbreviations: TL = translabyrinthine, RS = retrosigmoid, MCF = middle cranial fossa

**Headache.** Severe postoperative headache is associated with VS surgery (Vijayan 1995, Schessel et al. 1992) and it may be related to surgical bone debris in the subarachnoidal space, residual intracranial air, or a transient elevation in intracranial pressure (Wiet et al. 1992).

Postoperative headache can be very severe in nature and last for many years after surgery. Despite the use of nonsteroidal anti-inflammatory drugs or even narcotic analgesics the headache may be persistent (Hanson et al. 1998). Many studies have confirmed a high incidence of headache (Table 3.) and some have also postulated possible mechanisms and means of prevention with varied degrees of success (Hanson et al. 1998).

Table 3. Postoperative headache after vestibular schwannoma surgery according to the literature.

	Year	Patients (number)	Approach	Headache
Parving et al	1992	273	TL	29%
Cohen et al	1993	146	RS	14.3%
Schessel et al	1992	58	RS	64%
		40	RS	67% (sigmoid incision, craniectomy)
		13	RS	69% (triradiate incision, craniectomy)
		19	RS	5% (triradiate incision, craniotomy)
Harner et al	1993	331	RS	9% (two years postoperatively)
Harner et al	1995	24	RS	4% (cranioplasty)
		24	RS	17% (no cranioplasty)
Pedrosa et al	1994	155	RS	73%
			TL	53%
Vijayan	1995	280		75%
van Leeuwen et al	1996	134	TL/RS	more pain after RS
Ruckenstein et al	1996	18	TL	no difference between TL and
		35	RS	SO groups one year postoperatively
Catalano et al	1996	84	RS	64% (excision)
				81% (excision and cranioplasty)
				10% (excision, cranioplasty, residue trapping)
Andersson et al	1997	141	TL	22%

Abbreviations: TL = translabyrinthine, RS = retrosigmoid



### **3. PURPOSE OF THE STUDY**

The purpose of this study was to characterize the postoperative outcome of patients operated on for VS and to evaluate some quality of life aspects of VS patients after surgery. The specific aims were:

1. To characterize the frequency, type, and severity of postoperative headache in a retrospective study of patients after VS removal with special reference to possible risk factors and recovery.
2. To study the etiology of postoperative headache with special reference to vestibular function.
3. To evaluate the occurrence of hearing loss in the contralateral ear following cerebellopontine angle tumor surgery through the TL and the RS approach.
4. To evaluate the usefulness of preserved hearing including the role of tinnitus, and to evaluate pre- and postoperative factors predicting successful outcome in hearing preservation.
5. To evaluate postural stability after VS removal.

## 4. MATERIAL AND METHODS

### 4.1. Patients

The main study group consisted of 384 patients with unilateral or bilateral VS operated on during years 1979 to 1994 in Helsinki University Central Hospital (Table 4.). In addition, 97 unilateral VS cases operated on during the years 1978 to 1988 at Sahlgrenska Hospital, Gothenburg, Sweden were also included in one part of the main study.

Table 4. Patient data (N = 348) of vestibular schwannoma patients operated on during years 1979 to 1994 in Helsinki University Central Hospital.

Bilateral / Unilateral	19 / 365
Operation route (retrosigmoid / translabyrinthine)	348 / 36
Tumor size (mm)	mean 22.0 (range 3-58 mm)
Age (years)	mean 47.7 (range 7.9-73.4 years)
Gender (Male / female)	158 / 226
Operation radicality (yes / no)	325 / 59
Follow up time (years)	8.9 (range 1-16 years)
Tumor side (right / left)	178 / 206

Study I included charts from 359 patients. A questionnaire, based on the McGill Pain Questionnaire (MPQ) (Melzack 1975, Melzack 1987) and the Finnish Pain Questionnaire (Ketovuori and Pöntinen 1981, Ketovuori et al. 1984), was mailed to 317 patients with unilateral tumor, and altogether 251 (79.2%) responded. Ninety-two patients out of these 251 reported having postoperative headache, but only 27 patients considered it a major problem. These 27 patients, 11 men and 16 women, were entered further into Study II.

Study III consisted of 364 patients with unilateral VS. In addition, a survey was performed on cases operated on during the years 1978 to 1988 at Sahlgrenska Hospital, Gothenburg, Sweden. There were altogether 114 patients of whom 97 had unilateral VS, 14 cerebellopontine angle meningeoma and 3 bilateral tumors. Only the 97 patients with unilateral cerebellopontine angle tumors were included. All cases with postoperative hearing loss of contralateral ear exceeding 20 dB HL were evaluated (n = 9).

Study IV included 119 unilateral VS patients in whom the cochlear nerve was preserved in order to preserve hearing.

In Study V the retrospective group consisted of 177 patients with unilateral VS operated on during 1979 to 1987. The RS approach in the sitting position was used in 166 patients, and TL approach in the supine position in 11 patients. Active postoperative habituation was started in 1988, and the prospective group consisted of 44 patients with unilateral VS operated on after 1988. In 40 patients the approach was RS in the lateral recumbent position and in 4 patients TL in the supine position.

## 4.2. Methods

The intensity of postoperative headache was expressed using the Visual Analogue Scale (VAS) ranging from “no pain“ (0) to “worst possible pain“ (100) (Huskisson 1974). The scale is a 10 cm long line and patients choose the intensity of their headache between the two points “no pain” ja “worst possible pain”. The number of words chosen in the MPQ or more clearly in the Finnish Pain Questionnaire (Ketovuori et al. 1981) was also used to characterize pain intensity (Melzack 1975). Using a VAS, the patients were grouped into the categories of “no or slight headache“ (VAS<3.3 cm), “moderate headache“ (VAS between 3.3 and 6.6 cm), or “severe headache“ (VAS>6.6 cm).

The tinnitus questionnaire was based on the Tinnitus Handicap Questionnaire (Tyler et al. 1989, Kuk et al. 1990). The hearing questionnaire was based on the Social Hearing Handicap Index (Ewertsen and Birk-Nielsen 1973) (see Appendix).

Pure-tone audiograms and speech audiometries were performed to evaluate hearing.

The Vestibulo-ocular reflex (VOR), producing compensatory eye movements during head movements in the operative frequency range of 0.1 to 5 Hz (Juhola et al. 1997), was evaluated with the Vestibular Autorotation Test (VAT). In the VAT the patient is asked to rotate his or her head 10 degrees from side to side in pace with a sound signal while gazing at a stationary red spot on the wall 150 cm to the front (Hirvonen et al. 1995). The head movement accelerates gradually over 20 seconds from 0.5 Hz to as fast as possible (about 5 Hz). The VOR is measured at different frequencies; the highest frequency reached and also the gain and phase shift values are measured. Gain is computed for each sine wave of the signals as the ratio of the eye movement amplitude and the head movement amplitude. The phase shift is computed between the maxima or minima of the sine waves of the eye and head movement signals.

In posturography the force platform is constructed according to the strain gauge principle (Aalto et al. 1988). The vertical force distribution over the platform surface is measured and the coordinates of the center point of the force in the forward-backward and lateral directions are measured and analyzed. The posturography measurement lasted for 180 seconds. Stabilograms are recorded during two tests, one with (eyes open) and one without (eyes closed) visual control. The program calculates the sway velocity (SV). The Romberg quotient (RQ) describes the ratio between SV with eyes closed and SV with eyes open.

Postural perturbation is induced with vibrators, bilaterally on the calf muscles or on the neck muscles. Vibration is generated by means of a revolving DC motor (Escap, Switzerland) with a 5 g unbalanced weight at one end. The vibrator is built in a metal cylinder, length 50 mm and diameter 18 mm. Varying the input voltage of the DC motor controls the frequency of the vibration. The waveform of the vibration is sinusoidal. Eklund (1971) has provided a detailed description of this kind of vibrator system. Frequencies of 20, 40, 60, 80 and 100 Hz are used and delivered in pseudo-random fashion. The stimulator unit is controlled with a microcomputer (Hewlett Packard 75 C). The amplitude of the vibration is 0.4 mm (peak-to-peak) and is constant at all frequencies when measured unloaded. Two vibrators were held firmly against the calf muscles or the neck muscles with straps. The Proprioceptive index is the ratio between the SV during vibration perturbation on the calf muscles at 80 Hz and the baseline SV, both with eyes closed.

During the testing of the 27 patients with POH the headache was provoked with both the VAT and the posturography measurement. When the headache occurred the patient was given 100mg sumatriptan.

## 4.3. Statistical methods

In Study I the variables characterizing the patients' headache were analyzed by a factor analysis using simple correlation and varimax rotation. To find variables suggesting a risk of postoperative

headache a linear discriminant function analysis and logistic regression analysis were used. Duncan's multiple range test was used to compare the groups.

In Study II the Chi-square test with Yates correction was used for comparing the maximal frequency in the VAT. For the continuous variables of the VAT and the posturography, an analysis of variance was used, and the differences were gauged with Bonnferoni's test.

In Study IV linear regression analysis was used for the comparison between the outcome of various factors influencing the success of hearing preservation. Stepwise logistic regression analysis was used when evaluating factors determining the outcome of hearing preservation surgery. In studying internal correlations Kendall's linear correlation analysis was used. Student's t-test was used for the statistical calculations between the groups of patients.

In Study V factors influencing the postural stability were assessed with linear regression analysis and logistic regression analysis. The patients and controls were compared with Student's t-test.

#### **4.4. Ethics**

The ethics committee of Helsinki University Central Hospital approved the present study (KO11/94, KO 41/95).

## 5. RESULTS

### 5.1 Postoperative headache (I)

Headache that commenced only after surgery was regarded postoperative headache (POH). In the results the subjects with headache were classified into two groups: the POH group and those with preoperative and postoperative headache, the prePOH group.

The patients with postoperative headache experienced their headache mainly in the area of the neck (71%) and the occiput (76%) regardless of the surgical approach. In both groups the pain was typically unilateral and felt on the side of the surgery. The changes of postoperative headache after surgery in both prePOH and POH groups is shown in the Figures 5 and 6. The severity of the postoperative headache declined more among the POH patients than among the prePOH patients ( $X^2$ ,  $p < 0.05$ ). (I)

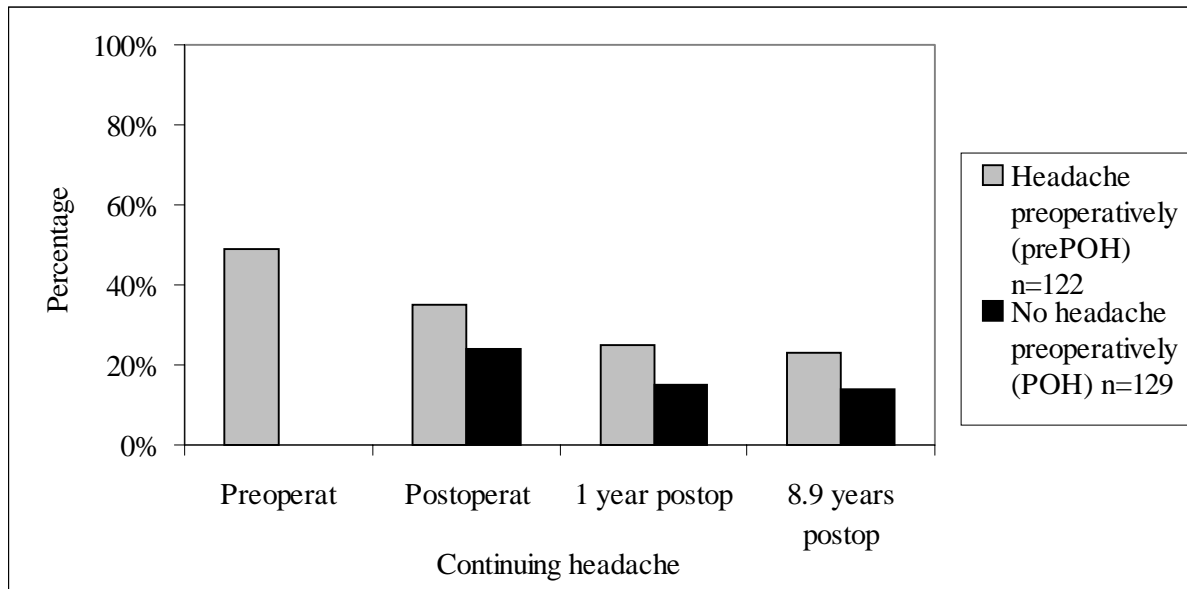


Figure 5. Continuing headache among the patients with headache pre- and postoperatively (prePOH) and among the patients with no headache preoperatively (POH) (N = 251).

The model consisting of preoperative headache, surgical approach, postoperative gait disorders, and tumor size predicted headache postoperatively for 68.1% of the patients, and was statistically highly significant ( $p < 0.001$ ) when analyzed with logistic regression analysis. The surgical approach ( $p < 0.05$ ) was the most important single risk factor linked to severe postoperative headache, the odds ratio (OR) being 3.9 for the retrosigmoid approach. Preoperative headache was also a statistically significant risk factor ( $p < 0.05$ ) for postoperative headache (OR 2.5), and postoperative gait disorders increased the probability of postoperative headache (OR 2.4,  $p < 0.05$ ). Also small tumor size was a risk factor (OR 1.1,  $p < 0.01$ ).

When only the patients with postoperative headache were studied, the logistic regression analysis showed that the surgical approach (RS) was the single most important risk factor for postoperative headache (OR 5.8,  $p < 0.05$ ).

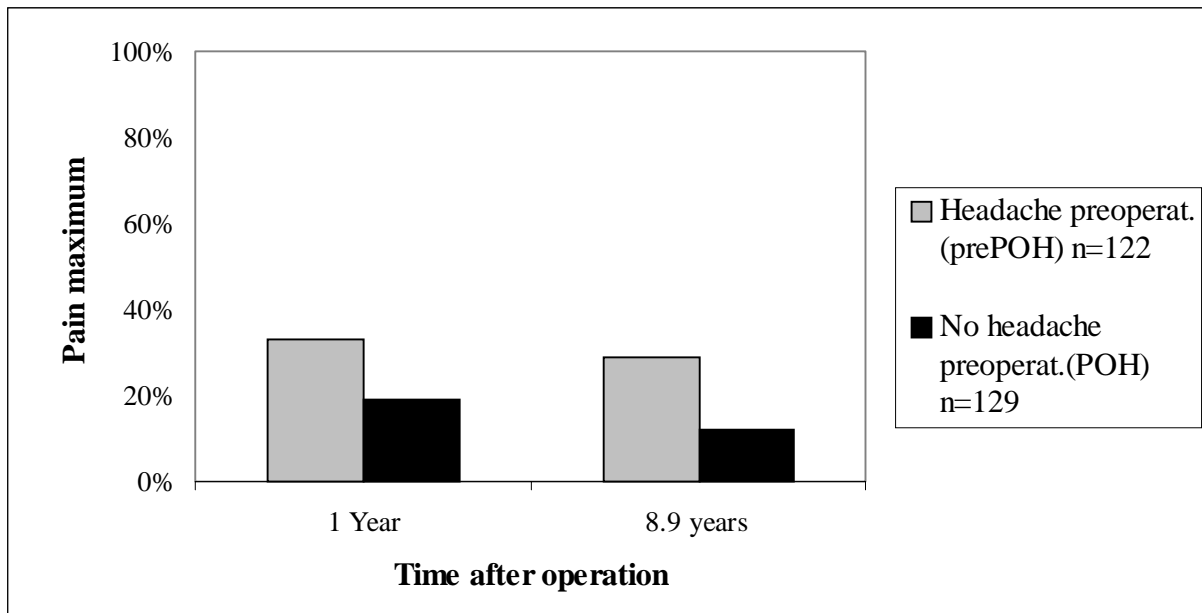


Figure 6. Maximum pain 1 year after operation and a mean of 8.9 years after operation. Patients with postoperative headache are grouped as those with headache preoperatively (prePOH) and those with no headache preoperatively (POH). N = 251.

## 5.2. Postoperative headache (II)

All 27 patients with severe headache were able to carry out the VAT; there was no difference in performance among patients with or without headache. The difference in gain was significant between the patients and normal controls ( $p < 0.01$ ).

Body sway in posturography was significantly increased among the patients with headache during the baseline stance, and during the vibration of neck muscles, when comparing the patients with the healthy controls ( $p < 0.01$ ). No differences were observed between the patients with and without headache.

After anaesthetising the neck muscles, 25 patients were able to rotate their head at a frequency of 1 Hz, 17 at 3 Hz and 7 patients at 4 Hz. All 9 normal controls reached 4 Hz (Fig. 7).

Of the 27 patients 26 reported headache during the three days of testing and provocation, only one experiencing no pain or discomfort at all. In the 26 patients in whom headache occurred 100mg sumatriptan alleviated pain in 9 patients and completely abolished the pain in 1 patient.

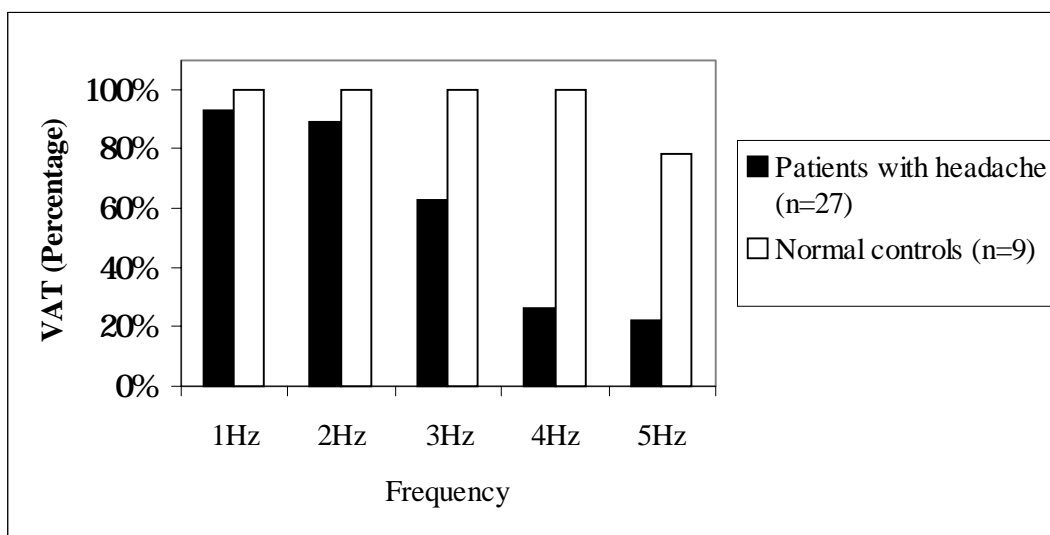


Figure 7. Highest performed VAT (percentage) frequencies after neck muscle anesthesia. Results of vestibular schwannoma patients with headache and the normal controls.

### 5.3. Cochleolabyrinthitis (III)

Altogether 478 patients with VS or cerebellopontine angle meningiomas were studied, 32 of whom were operated on using the TL approach and 446 the RS approach. Two patients with the TL approach developed vertigo and prominent hearing loss in the contralateral ear (Table 5). The hearing loss started within two weeks of the surgery. Eight patients with the RS approach developed a significant hearing loss of the contralateral ear that started two to four years after operation, and in three patients this was identical to delayed hydrops (Table 5).

Table 5. The development of cochleolabyrinthitis. Contralateral hearing loss, tumor size and vertigo in patients with removed vestibular schwannoma and one cerebellopontine angle meningioma.

Case	Operation route	Mean tumor size (mm)	Preop. HL (dB)	Post-op HL (dB)	Time to onset of HL	Onset and course of HL	Vertigo
1	TL	30	7	35	1 week	fast, stabilized	yes
2	TL	13	10	50	2 weeks	fast, stabilized	yes
3	RS	*	17	90	4 years	fast, progressive	no
4	RS	25	15	55	2 years	fast, fluctuant	yes
5	RS	10	10	45	2 years	fast, fluctuant	no
6	RS	27	10	35	2 years	fast, fluctuant	yes
7	RS	37	7	30	2 years	slow, fluctuant	no
8	RS	27	10	47	5 to 7 years	slow, progressive	no
9	RS	35	15	35	3 to 6 years	slow, stabilized	no
10	RS	30	12	35	3 to 6 years	slow, stabilized	no

TL = translabyrinthine, RS = retrosigmoid, \* = meningioma

#### 5.4. Hearing preservation (IV)

Hearing was preserved in 47 out of 119 patients (Table 6). In 10 patients with preserved hearing tumor size was larger than 15 millimeters. Ten patients had hearing better than 30 dB. Hearing was followed on average 7.3 years, range 1 to 16 years. There was gradual deterioration (about 5 dB) during the follow-up time. Hearing was lost in four patients during the follow up period (three months, one year, and in two patients two years after surgery).

Table 6. Vestibular schwannoma patients grouped to those with and without successful hearing preservation surgery.

Factor	Cochlear nerve intact	
	Hearing lost n = 72	Hearing preserved n = 47
Mean age (yr)	45	49.2
Mean tumor size (mm)	15.0	12.6
Mean preoperative PTA (dB HL)	37.1	31.0
Mean preoperative Discrimination (%)	76.2	82.9
Mean postoperative PTA (dB HL)	>120	54.7
Mean postoperative Discrimination (%)	0	64.6
Mean facial function*	1.3	1.1

\* = House and Brackmann scale, PTA = pure tone average, HL = hearing level

The model for predicting successful hearing preservation consisted of age, tumor size, PTA, SDS and hearing level at 1000 Hz in pure-tone audiometry ( $p < 0.003$ ). In the model age ( $p < 0.008$ ) and SDS ( $p < 0.06$ ) were the strongest predictors for preserved hearing. Tumor size, PTA and hearing at 1000 Hz did not reach the level of statistical significance. During surgery the interface between the nerve and the tumor seemed to be the most important factor for hearing preservation, an easily identifiable cleavage plane enabling less traumatic tumor removal.



Table 7. Vestibular schwannoma patients' subjective evaluation of the usefulness of their preserved hearing.

<b>Rating scale</b>	<b>Usefulness of hearing preservation*</b> (n=39)	<b>Hearing of sound</b> (n=39)	<b>Speech discrimination</b> (n=39)	<b>Sound localization</b> (n=39)
None	8% (16dB / 97%)	8%	15%	28%
Undecided	20% (10dB / 100%)	26%	23%	23%
Some	23% (3dB / 100%)	20%	21%	15%
Moderate	13% (3dB / 97%)	13%	18%	21%
Very	36% (11dB / 97%)	33%	23%	13%

\*=Mean contralateral PTA / SDS

PTA = Pure tone average hearing level, SDS = Speech discrimination scores

The questionnaire indicated that 70% of the patients found their preserved hearing useful or very useful (Table 7). Sound distortion was not experienced to be a problem in the majority of the patients (65%), but was distressing in 15%. Tinnitus was present in 68% of the patients. It localized to the tumor ear in all but 2 patients. Table 8 shows the subjective handicap caused by tinnitus.

Table 8. Subjective disability, and use of sleeping pills due to tinnitus according the vestibular schwannoma patients with preserved hearing.

<b>Rating severity of tinnitus</b>	<b>Subjective disability</b> (n=39)	<b>Interference with sleep</b> (n=39)	<b>Use of sleeping pills</b> (n=39)
No tinnitus	38%	38%	38%
Very mild	5%	38%	54%
Slight	33%	21%	8% (occasionally)
Moderate	21%	3%	0 (weekly)
Severe	3%	0	0 (every night)

### 5.5. Postural stability (V)

In the retrospective study 122 out of 177 patients considered their moving ability normal, 27 had slight difficulties, 7 needed a cane, 3 were able to move only with human support and 1 patient was totally unable to walk. Postural stability, based on posturography measured 5 or 7 years after surgery, was normal in 122 patients (69%) under visual control and in 67 patients (38%) under non-visual control (Fig. 8). Vibration in non-visual control increased body sway more than in visual control ( $p < 0.001$ ).

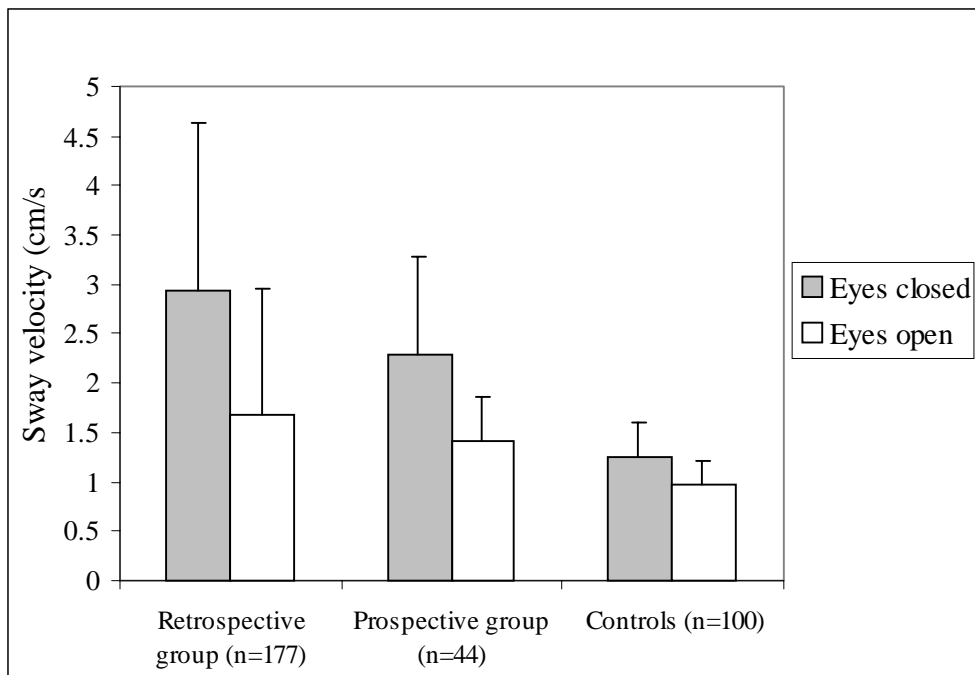


Figure 8. Sway velocity under visual and non-visual control among the patients in the prospective and the retrospective groups, and among normal controls.

In the prospective patient group, under visual control 30 patients (68%) had normal postural stability on posturography one year after the operation. Under non-visual control 23 patients (52%) had normal postural stability. The difference between the retrospective and the prospective patient groups regarding SV was statistically significant ( $p < 0.05$ ) under non-visual control (Fig. 8).

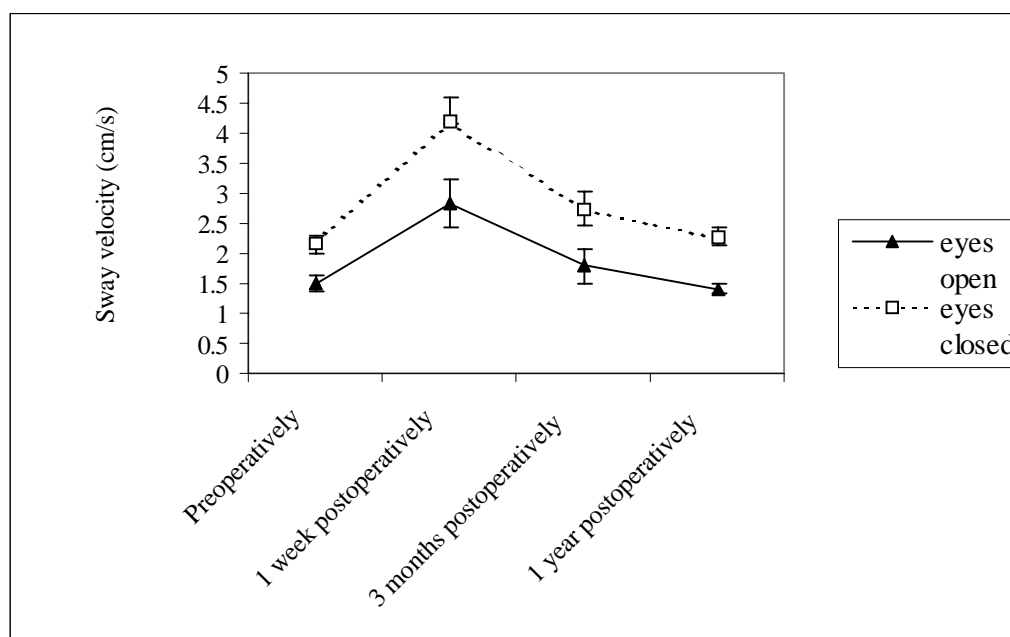


Figure 9. Sway velocity (cm/s) both with visual- and non-visual control measured preoperatively and during the first postoperative year. The prospective patient group. (N = 44)

The changes in the mean SV before and after operation under visual and non-visual control are shown in Figure 9. Three months after surgery the mean SV had returned almost to the preoperative value; however, one year after surgery the mean SV was still not better than the value before surgery.

The retrospective and prospective groups were combined to study the role of the postural active habituation and surgical position for outcome of postural recovery. In the logistic regression analysis the surgical position and habituation are heavily intercorrelated as both changes took place at the same time. With gait problems the model consisting of surgical position ( $p < 0.01$ ), gender ( $p < 0.01$ ), and outcome of posturography ( $p < 0.001$ ) as the independent variables was statistically significant and could explain 65% of the variance of the gait problems. The odds ratios for surgical position and female gender were 6 and 2.5, respectively, making them the most important risk factors for poor postural stability.

The role of proprioception and visual control as compensatory vestibular mechanisms was also studied. A high proprioceptive index indicates relative reliance on the former ( $p < 0.001$ ), and a high Romberg quotient on the latter ( $p < 0.001$ ). Those who relied more on proprioception fared better than those who relied on visual control.

## 6. DISCUSSION

In the present study we examined headache after vestibular schwannoma surgery. If headache was present before the operation it tended to continue also postoperatively, although 20% of patients who had headache preoperatively did not complain of headache postoperatively. Sixty (23.9%) patients developed POH without preoperative headache. Headache declined during the first year after operation, but if it persisted for a year, it seemed to become permanent.

There was no difference in vestibular function when the POH patients were compared with VS patients without POH. Differences were not observed between these groups in vestibulo-ocular or vestibulo-spinal reflexes, either. Therefore the POH may not be explained by the vestibular imbalance. The postoperative headache, although probably multietiological, may be caused by trigeminal neuropathy in the posterior fossa, where pain afferents trigger abnormal reflexes mimicking local vascular headache (Vass et al.1997, Vass et al. 1998). Bone dust irritation or manipulation of the sensitive duro-periosteal complex may cause this trigeminal neuropathy.

Ten out of 478 patients in study III developed hearing impairment of the non-operated side: two patients directly after TL operation (6%) and eight patients after RS operation (1.8%) with a late onset. One explanation could be AID (autoimmune inner-ear disease) (Hariri 1993). The contralateral hearing loss in the RS cases with an intact labyrinth might be due to the removal of the endolymphatic sac. It is therefore speculated that even in the RS cases, AID may be the reason for contralateral hearing loss.

In the present study hearing was preserved in 39% of patients in whom the cochlear nerve was preserved. The result is very similar to that of other studies (Cohen et al. 1993, Samii and Matthies 1997). Four patients (8.5%) with preserved hearing later experienced significant hearing impairment. Similar impairment has been reported to occur in other series with the same frequency (Shelton and House 1990). The preserved hearing was considered beneficial by 66% of the patients contrary to the results of Tos et al. (1988), although the preserved hearing was better than 30 dB in only 10 patients. Preserved hearing was perceived as valuable for speech discrimination during conversation. We found that neither distortion of speech nor aggravation of tinnitus caused major disability after surgery.

Vestibular compensation after removal of VS takes place during the first months after surgery (Haid et al. 1991), even without active habituation (Mruzek et al. 1995). However, Lynn et al. (1999) reported persistent dysequilibrium in up to 65% of patients. In the present series the results of retrospective study showed that 69% of the patients considered their gait normal, while in posturography only 32% had postural stability within normal limits, indicating that subjective evaluation of gait and measured postural stability are evaluating different aspects of body equilibrium. The impairment of postural stability was usually slight, as only four patients had severe difficulties with postural stability.

The VS patients in present study were all in all quite satisfied with their postoperative condition. Although headache was frequent for majority of the patients it was a minor complaint. Only one patient had headache which did not relieve with any medication, but headache appeared very seldom. Hearing preservation was experienced beneficial. The contralateral hearing loss was rare. Patients did not complain of balance difficulties spontaneously, but they had motivation to active postoperative habituation. Although the patients succeeded in their every day life, the retiring tendency was apparent.

### 6.1. Methodological aspects

The diagnosis of VS has changed during the last years considerably as MRI has become the most preferred diagnostic tool (Möller 2000, Robinette 2000). The incidence of VS increases with age

(Möller 2000) and even tumors of only a few millimeters in size are diagnosed with MRI. Nowadays the patients present with minor symptoms and smaller tumors than in the beginning of the present study, which causes differences within the patient material. The total patient material in this study is large, including all the VS patients treated at Helsinki University Central Hospital during 1979 to 1994. The study was done in a tertiary center to which the most of the VS patients in the southern Finland are referred. Mainly two operative methods were used, TL operation and RS operation, although the group of TL patients was altogether small.

In a study by Blomstedt et al. (1991) in which the VS operations were done before the operating microscope era, the mortality was quite obviously higher among VS patients than among the matched general population during the first year after surgery, but after the first year the mortality rates became equal (Blomstedt et al. 1991). In 1985 Welch and Dawes reported 5% postoperative mortality, all among patients with large tumors. In 1995 Irving et al. reported a postoperative mortality rate of 2-3%, and Guerin et al. in 1999 a rate of 0.3%. Even results with no postoperative mortality have been reported (Jung et al. 2000, Lanman et al. 1999). NF2 patients have a larger risk for postoperative mortality because of the more progressive tumor growth (Samii et al. 1997). The development of the operative technique during the years of present study together with the presenting smaller tumor size have influenced the postoperative results. The tumor sizes during years 1962 to 1973 and 1990 to 1992 were compared in Helsinki University Central Hospital (Fig. 10). There are today about equally frequently giant tumors but fewer large and mid-size tumors than at the early 70's. The dominance is shifting towards small tumors. When the major complications hemorrhage, meningitis, and cerebrospinal fluid leak are becoming rare, quality of life issues such as dysequilibrium, headache, and hearing preservation are more important.

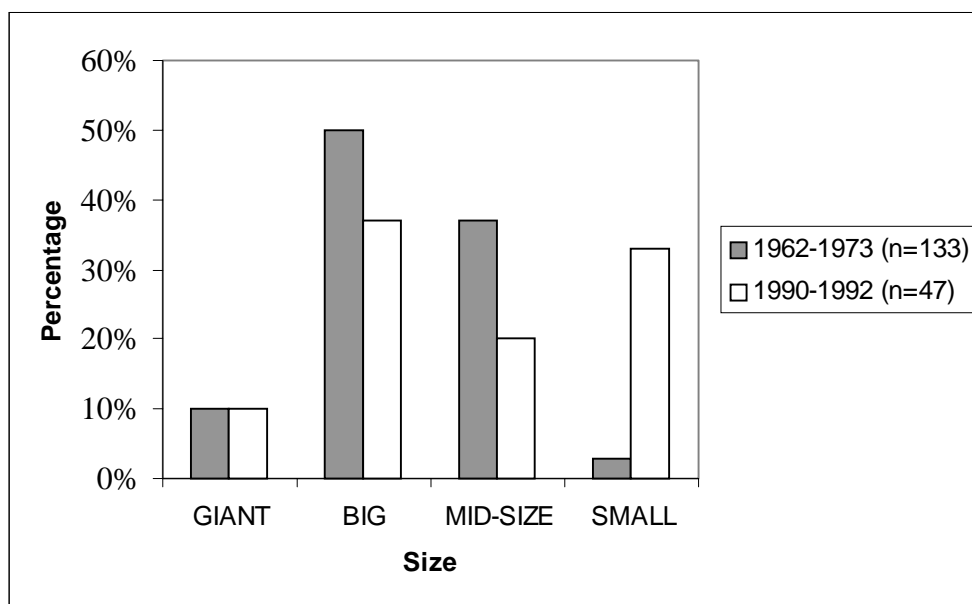


Figure 10. The size of vestibular schwannoma during years 1962 to 1973 (N = 133) and 1990 to 1992 (N = 47) in Helsinki University Central Hospital.

Several questionnaires were used in present study. VAS (Huskisson 1974), MPQ (Melzack 1975), Finnish Pain Questionnaire (Ketovuori et al. 1981), Tinnitus Handicap Questionnaire (Tyler et al. 1989, Kuk et al. 1990) and Social Hearing Handicap Index (Ewertsen and Birk-Nielsen 1973) are all validated international questionnaires. Only the questionnaires concerning gait, depression, and quality of life were not international.

## **6.2. Postoperative headache**

Postoperative headache is usually connected with the SO or RS approach in surgery for VS (Schessel et al. 1992), and up to 73% of patients suffering from POH have undergone the suboccipital approach (Pedrosa et al. 1994). The incidence of headache after the TL approach varies in the literature from 0% (Schessel et al. 1992) to 75% (Vijayan 1995). In the present study the incidence of headache after the TL approach was 39%. Thus none of the operative approaches are without risk for headache, but in the present study the RS approach carried a 3.8 times higher risk for headache than did the TL procedure.

Mechanical, electrical or chemical stimulation of the trigeminal sensory nerves may produce neurogenic inflammation and intense head pain (Hargreaves et al. 1999). Vass et al. (1997, 1998) demonstrated that the first branch of the trigeminal ganglion sends projections to the cochlea and also to the dura of the posterior fossa (Keller et al. 1985). Vass et al. (1997) suggested that the trigeminal sensory innervation of the cochlea plays an important role in cochlear blood flow regulation. Stimulation of trigeminal perivascular nerve endings causes vasodilatation and edema leading to further sensory nerve activation and neurogenic inflammation (Vass et al 1998).

Sumatriptan interacts with the trigemino-vascular system, possibly through direct cerebral vessel constriction or through the inhibition of sensory neuropeptide release or both (Moskowitz and Buzzi 1991). In present study one patient responded to sumatriptan with complete pain relief, and nine others considered it helpful to some extent. The sumatriptan trial was not randomized and therefore our observation is not reliable. However this result suggests that vascular structures may be involved in at least some cases. More research is needed to solve the etiology of headache.

## **6.3. Sympathetic cochleolabyrinthitis**

AID can be induced experimentally by infection (Gloddek et al. 1992), trauma ((Jackson 1994) or vaccination (Harris 1984). Recent animal models using immunization to inner ear extracts (Gloddek et al. 1994) or adjuvant therapy (Harris 1984) indicate that the pathological changes in the inner ear are characteristic of a disease like Ménière's disease, with autoimmune cellular response against the endolymphatic sac (Soliman 1996).

Sympathetic ophthalmia may be used as an analogy for sympathetic cochleolabyrinthitis. In the recent literature the incidence of sympathetic ophthalmia varies between 0.2% and 0.5% among subjects with a penetrating eye wound, although in the older literature an incidence as high as 16% has been reported (Towler and Lightman 1996, Power and Foster 1996). After eye surgery the incidence is significantly lower, being about 0.007% (Tower and Lightman 1996). The latency of onset of sympathetic ophthalmia varies from 10 days to 50 years from the original traumatic incident. In present study the onset of hearing loss after operation varied from 2 weeks to four years.

A test to prove the presence of antibodies to inner ear proteins in affected patients, and their absence from patients without contralateral hearing loss, is needed before the etiology of sympathetic cochleolabyrinthitis can be confirmed.

## **6.4. Hearing preservation**

Hearing was preserved in 40% of the 119 attempted cases. The preservation of hearing was considered a success by 66% of the patients, although in only 10 patients the preserved hearing was better than 30 dB. There is controversy as to what should be considered useful, acceptable or serviceable hearing (Shelton and House 1990). Usually when audiometric criteria are advocated, it

is said that the 50/50 rule should apply to serviceable hearing (Glasscock et al. 1983). Our patients' subjective evaluation of the usefulness of their residual hearing indicates that the levels are beyond these limits, and there was no correlation between the measured PTA levels and speech discrimination. The second general belief is that if the hearing level between the ears differs by more than 20 dB the weaker ear does not aid in conversation (Glasscock et al 1983). It is also claimed that leaving the cochlear nerve increases the risk of handicapping tinnitus (Harcourt et al. 1997). In 5 patients with a deaf ear and tinnitus, the non-functioning cochlear nerve was removed. In 2 cases of them tinnitus was significantly relieved, but in 3 cases it was unchanged. This experience has discouraged us from attempts to eliminate tinnitus by re-operation. Among the patients with residual hearing tinnitus was a major problem in only one patient. Thus the argument that leaving the cochlear nerve will worsen the tinnitus seems unfounded. The results of the present study encourage surgeons to continue efforts to preserve hearing in VS surgery.

### **6.5. Postural stability**

Herdman et al. (1995) and Lynn et al. (1999) found no relationship between age and postural instability after VS removal, but in their study the surgical approach in the experimental group was TL (Herdman et al. 1995). Tumor size was not related to postural stability (Herdman et al. 1995, Lynn et al. 1999) either, as was also found in the present study, also. In the present study elderly patients showed increased risk for poor vestibular compensation. In these patients postural stability is influenced by poor vision, diminishing of stretch reflexes, and changes in the vestibular part of the labyrinth (Hytönen et al. 1993), which results in decreased adaptive capability.

Depression seems to be associated with VS surgery (Blomstedt et al. 1996). Postoperative depression was associated with a significant risk for poor postural recovery. The reason remains unclear. The RS approach had 6.8 times greater risk for poor postural recovery than the TL approach. This may be linked to the sitting position in RS during which the cerebellum must be firmly retracted and the subject is exposed to air embolism. The patients' position during RS surgery was changed to the supine in 1988.

Female gender was a risk factor for postoperative gait problems as shown in other studies (Driscoll et al. 1998). Postural imbalance may be linked to reduction of estrogen levels with ageing (Naessen et al. 1997). Postural balance is better preserved in long-term estrogen users than in non-users (Naessen et al. 1997). In the present study the postmenopausal female patients did not use estrogen, which may be one reason for the female patients being at risk for postoperative gait problems.

The results of the present study show that not all of the VS patients compensate the vestibular damage after VS surgery, and that they benefit from the use of vestibular active habituation to improve their postural stability.

## 7. CONCLUSIONS

1. At an average of 9 years after surgery, 93 out of 251 patients with headache postoperatively still reported headache, which was a major problem for 27 of them. Headache declined during the first year after operation, but if it persisted for a year, it seemed to become permanent. The retrosigmoid approach, postoperative gait problems, preoperative headache and small tumor size predicted problematic headache after surgery.
2. Vestibular imbalance or abnormal activation of neck muscles did not explain postoperative headache. Occipital nerve entrapment or craniotomy-related dural retraction explained headache in a few patients. POH was alleviated by sumatriptan in eleven of the 27 patients with persistent headache. The sumatriptan effect may suggest a vascularly mediated trigeminal neuropathy in the etiology of postoperative headache. Trigeminal irritation in the inner ear or the posterior fossa may cause neurogenic inflammation mediated through vascular structures.
3. Contralateral hearing loss was observed to occur in 6% of the TL and 1.8% of the RS cases, indicating that the TL approach may be related with more complications than are presently known.
4. Hearing preservation was successful in 40% of the cases with intact cochlear nerve. Of those patients 66% rated preserved hearing valuable. Neither tinnitus nor speech distortion were considered disadvantageous for hearing preservation. The vascular structure of the inner ear is possibly the most significant factor for hearing preservation.
5. After operation 69% of patients spontaneously regained normal postural stability in visual conditions, but only 37% in non-visual conditions. Vestibular active habituation increased the use of proprioception in maintaining postural control. Advanced age was a risk factor for poor postural recovery. Female gender and surgical position were risk factors for postoperative gait problems.

More research is needed to solve the etiology of postoperative headache. A test proving the presence of antibodies to inner ear proteins in affected patients, and their absence from patients without contralateral hearing loss is needed before the etiology of sympathetic cochleolabyrinthitis can be confirmed. Hearing preservation is worthwhile after VS surgery. Not all of VS patients can compensate for vestibular damage after VS surgery, but many patients benefit from the use of active habituation to improve their postural stability.

Overall impression of the VS patients was satisfaction with postoperative condition in spite of different minor or even major problems. Although the patients succeeded in their every day life, the retiring tendency was apparent.



## APPENDIX

### The Social Hearing Handicap Questionnaire (Ewertsen and Birk-Nielsen 1973)

---

1. If you are sitting opposite a person at a distance about 1 m, will you be able to understand everything if the person speaks in a normal tone of voice?
  2. Do you have problems in understanding when members of the family are gathered together?
  3. Is it difficult for you to hear in the kitchen when the water is running?
  4. Do you find it difficult to hear what the shop assistant says to you?
  5. Is it difficult for you to carry on a telephone conversation?
  6. Can you follow the conversation when you are talking to several people?
  7. Is it difficult for you to follow a conversation at a tea table with several persons?
  8. Can you hear most of what is said when sitting at the back of a lecture room, a theatre or a church?
  9. Can you carry on a conversation with someone sitting at the other end of the room and speaking in a normal tone of voice?
  10. Can you hear the radio well when it is set at normal volume?
  11. Can you carry on a conversation easily in a car, tram or bus?
  12. Can you carry on a conversation easily at the dinner table at home?
  13. Do you understand what is said to you when there is noise from other voices, typewriters, traffic, music?
  14. Do you recognize persons by their voices?
  15. Is it difficult for you to hear people speaking on TV when it is not turned up?
  16. Is it difficult for you to follow a conversation at a large dinner table?
  17. Can you carry on a conversation with someone when the radio or TV is not turned down?
  18. Is it difficult for you to carry on a conversation with someone in a busy street?
  19. Is it difficult for you to understand what is said to you from an adjoining room?
  20. Can you carry on a conversation with a person where there is noise, for instance at a restaurant or at a party?
  21. Do you often misunderstand other people's conversation?
-

## REFERENCES

- Aalto H, Pyykkö I, Starck J. Computerized posturography, a development of measuring system. *Acta Otolaryngol Suppl* (Stockh) 1988; 449: 71-5.
- Af Forselles A. Ett translabyrintärt opererat fall av akustikustumör. *Nord Tidskr Otorhinolaryngol* 1916; 1: 29-46.
- Aitasalo K, Suonpää J, Jääskeläinen S. Intraoperative monitoring of the facial nerve during acoustic neurinoma surgery. In: Sanna M, Taibah A, Russo A, Mancini F (editors): *Acoustic neurinoma and other CPA tumors*. Bologna: Monduzzi Editore 1999, 433-7.
- Andersson G, Ekvall L, Kinnefors A, Nyberg G, Rask-Andersen H. Evaluation of quality of life and symptoms after translabyrinthine acoustic neuroma surgery. *Am J Otol* 1997; 18: 421-6.
- Anderson TD, Loevner LA, Bigelow DC, Mirza N. Prevalence of unsuspected acoustic neuroma found by magnetic resonance imaging. *Otolaryngol Head Neck Surg* 2000; 122: 643-6.
- Axon PR, Ramsden RT. Facial nerve injury caused by vestibular schwannoma compression: severity and adaptation to maintain normal clinical facial function. *Am J Otol* 1999; 20: 763-9.
- Bance M, Ramsden TR. Management of neurofibromatosis Type 2. *ENT Ear Nose Throat J* 1999; 78 (2): 91-6.
- Blomstedt GC, Jääskeläinen JE, Pyykkö IV, Sankila RJ. Recurrence of acoustic neurinomas after subtotal removal: a comparison of the observed and expected survival rates of 139 patients operated on from 1962 to 1973. In: Tos M, Thomsen J (editors): *Acoustic Neuroma. Proceedings of the First International Conference of acoustic neuroma*. Amsterdam, New York: Kugler Publications 1991, 709-12.
- Blomstedt GC, Katila H, Henriksson M, Ekholm A, Jääskeläinen J, Pyykkö I.: Depression after surgery for acoustic neuroma. *J Neurol Neurosurg Psychiatry* 1996; 61: 403-6.
- Brackmann DE. Current status of ABR audiometry in acoustic neuroma diagnosis. *Arch Otolaryngol Head Neck Surg* 1999; 125: 235.
- Brackmann DE, Green JD. Translabyrinthine approach for acoustic tumor removal. *Otolaryngol Clin North Am* 1992; 25: 311-29.
- Catalona PJ, Jacobowitz O, Post KD. Prevention of headache after retrosigmoid removal of acoustic tumors. *Am J Otol* 1996; 17: 904-8.
- Clemis JD, Masticola PG, Schuler-Vogler M. Sudden hearing loss in the contralateral ear in postoperative acoustic tumor: three case reports. *Laryngoscope* 1982; 92: 76-9.
- Cohen NL. Retrosigmoid approach for acoustic tumor removal. *Otolaryngol Clin N Am* 1992; 125: 295-310.
- Cohen NL, Lewis WS, Ransohoff J. Hearing preservation in cerebellopontine angle tumor surgery: the NYU experience 1974-1991. *Am J Otol* 1993; 14: 423-33.
- Curtin HD, Hirsch WL. Imaging of acoustic neuromas. *Otolaryngol Clin North Am* 1992; 25(3): 553-607.
- Cushing H. *Tumors of the nervus acusticus and the syndrome of the cerebellopontine angle*. Philadelphia: WB Saunders, 1917.
- Dandy WE. An operation for total removal of cerebellopontile (acoustic) tumors. *Surg Gynec Obst* 1925; 41: 129-48.
- Daniels RL, Shelton C, Harnsberger R. Ultra high resolution nonenhanced fast spin echo magnetic resonance imaging: cost-effective screening for acoustic neuroma in patients with sudden sensorineural hearing loss. *Otolaryngol Head Neck Surg* 1998; 119: 364-9.
- Dawes PJD, Basiouny HE. Outcome of using magnetic resonance imaging as an initial screen to exclude vestibular schwannoma in patients presenting with unilateral tinnitus. *J Laryngol Otol* 1999; 113: 818-22.

- Dornhoffer JL, Helms J, Hoehmann DH. Hearing preservation in acoustic tumor surgery: results and prognostic factors. *Laryngoscope* 1995; 105: 184-7.
- Doyle KJ. Is there still a role in auditory brain stem response audiometry in the diagnosis of acoustic neuroma? *Arch Otolaryngol Head Neck Surg* 1999; 125(2): 232-4.
- Driscoll CL, Lynn SG, Harner G, Beatty CW, Atkinson EJ. Preoperative identification of patients at risk of developing persistent dysequilibrium after acoustic neuroma removal. *Am J Otol* 1998; 19 (4): 491-5.
- Edwards CH, Patterson JH. A review of the symptoms and signs of acoustic neurofibromata. *Brain* 1951; 4: 144-90.
- Eklund G. Some physical properties of muscle vibrators used to elicit tonic proprioceptive reflexes in man. *Acta Soc Med Ups* 1971; 76: 271-80.
- El-Kashlan HK, Zeitoun H, Arts HA, Hoff JT, Telian SA. Recurrence of acoustic neuroma after incomplete resection. *Am J Otol* 2000; 21: 389-92.
- Evans DGR, Huson SM, Donnai D, Neary W, Blair V, Newton V, Harris R. A clinical study of type 2 neurofibromatosis. *Q J Med* 1998; 42: 603-18.
- Evans DGR, Lye R, Neary W, Black G, Strachan T, Wallace A, Ramsden RT. Probability of bilateral disease in people presenting with a unilateral vestibular schwannoma. *J Neurol Neurosurg Psychiatry* 1999; 66: 764-7.
- Ewertsen HW, Birk-Nielsen H. Social hearing handicap index. *Audiology* 1973; 12: 180-7.
- Fisch U. Transtempora surgery of the internal auditory canal. *Adv Otorhinolaryngol* 1970; 17: 202-39.
- Fucci MJ, Buchman CA, Brackmann DE, Berliner KI. Acoustic tumor growth: implications for treatment choices. *Am J Otol* 1999; 20: 495-9.
- Glasscock ME, McKennan KX, Levine SC. Acoustic neuroma surgery: the results of hearing preservation surgery. *Laryngoscope* 1987; 97: 785-9.
- Glasscock ME, Hays JW, Minor LB, Haynes DS, Carrasco VN. Preservation of hearing in surgery for acoustic neuromas. *J Neurosurg* 1983; 78: 864-70.
- Gloddek B, Lamm K, Haslov K. Influence of middle ear immune response on the immunological state and function of the inner ear. *Laryngoscope* 1992; 102: 177-81.
- Gloddek B, Rogowski M, Arnold W. Adoptive transfer of autoimmune labyrinthitis in the guinea pig; animal model for sympathetic cochleolabyrinthitis. *Clin Exp Immunol* 1994; 97: 133-7.
- Greiner GF, Philippides D, Collard M, Conraux C, Buchheit F, Maitrot D. Hypoacusie controlaterale dans le neurinome du VIII. Evolution post-operative. *Rev Oto Neuro Ophthalmol* 1971; 43: 54-8.
- Guerin C, Sampath P, Long DM. Acoustic neuroma: outcome of surgical resection and study on the anatomy of facial and cochlear nerves. *Ann Acad Med Singapore* 1999; 28: 402-8.
- Haberkamp TJ, Meyer GA, Fox M. Surgical exposure of the fundus of the internal auditory canal: anatomic limits of the middle fossa versus the retrosigmoid transcanal approach. *Laryngoscope* 1998; 108: 1190-4.
- Haid CT, Goertzen W, Christ P, Schuster B. Posture and central compensation after acoustic neurinoma surgery. *Acta Oto-rhino-laryngol Belg* 1991; 45: 349-54.
- Hanson MB, Glasscock III ME, Brandes JL, Jackson CG. Medical treatment of headache after suboccipital acoustic tumor removal. *Laryngoscope* 1998; 108: 1111-4.
- Harcourt J, Thomsen J, Tos M. Translabyrinthine vestibular schwannoma surgery: postoperative tinnitus and cochlear nerve integrity. *Auris Nasus Larynx* 1997; 24: 21-6.
- Hardy DG, MacFarlane R, Baguley D, Moffat DA. Surgery for acoustic neuroma. An analysis of 100 translabyrinthine operations. *J Neurosurg* 1989; 71: 799-804.
- Hargreaves R, Williamson D, Shepherd S. Neurogenic inflammation: relation to novel antimigraine drugs. In: Edvinsson A (editor) *Migraine and Headache Pathophysiology*. London: Martin Dunitz, 1999: 93-101.
- Hariri MA. Autoimmune inner ear disease. *J Audiol Med* 1993; 2: 41-52.

- Harner SG, Beatty CW, Ebersold MJ. Headache after acoustic neuroma excision. *Am J Otol* 1993; 14: 552-5.
- Harner SG, Beatty CW, Ebersold MJ. Impact of cranioplasty on headache after acoustic neuroma removal. *Neurosurgery* 1995; 36: 1097-100.
- Harner SG, Ebersold MJ. Management of acoustic neuromas, 1978-1983. *J Neurosurg* 1985; 63: 175-9.
- Harner SG, Laws ER Jr, Onofrio BM. Hearing preservation after removal of acoustic neurinoma. *Laryngoscope* 1984; 94: 1431-4.
- Harris JP: Immunology of the inner ear: evidence of local antibody production. *Ann Otol Rhinol Laryngol* 1984; 93: 157-62.
- Harris JP, Low NC, House WF. Contralateral hearing loss following inner ear injury: sympathetic cochleolabyrinthitis? *Am J Otol* 1985; 6: 371-7.
- Henschen F. Zur Histologie und Pathogenese der Kleinhirnbruchenwinkeltumoren. *Arch Psychiatr* 1916; 56: 21-122.
- Herdman S, Clendaniel R, Mattox D, Holliday M, Niparko J. Vestibular adaptation exercises and recovery: acute stage after acoustic neuroma resection. *Otolaryngol Head Neck Surg* 1995; 113: 77-7.
- Higgs WA. Sudden deafness as the presenting symptom of acoustic neurinoma. *Arch Otolaryngol* 1973; 98: 73-6.
- Hirvonen T, Pyykkö I, Juhola M, Aalto H. High frequency deficit of the vestibular system after acoustic neurinoma surgery. *Acta Otolaryngol Suppl (Stockh)* 1995; 520: 16-8.
- Hoehmann D. Pre- and postoperative hearing thresholds and brainstem responses in patients with acoustic neuroma: follow-up study using the middle fossa approach. *Am J Otol* 1991; 12: 172-8.
- Horrax G, Poppen JL. Experiences with the total and intracapsular extirpation of acoustic neuromata. *Ann Surg* 1939; 110: 513-24.
- House HP, House WF. Historical review and problems of acoustic neuroma: monograph - transtemporal bone microsurgical removal of acoustic neuromas. *Arch Otolaryngol* 1964; 80: 601-4.
- House JW, Brackmann DE. Facial nerve grading system *Otolaryngol Head Neck Surg* 1995; 93: 146-7.
- House WF. Surgical exposure to the internal auditory canal and its contents through the middle cranial fossa. *Laryngoscope* 1961; 71: 1363-85.
- House WF, Graham MD. Surgery of acoustic tumors. *Otolaryngol Clin North Am* 1973; 6: 245-66.
- House WF, Hitselberger WE. Morbidity and mortality of acoustic neuromas; monograph - transtemporal bone microsurgical removal of acoustic neuromas. *Arch Otolaryngol* 1964; 80: 745-54.
- House WF, Shelton C. Middle fossa approach for acoustic tumor removal. *Otolaryngol Clin North Am* 1992; 25: 347-59.
- Huskisson EC. Measurement of pain. *Lancet* 1974; 2: 1127-31.
- Hytönen M, Pyykkö I, Aalto H, Starck J. Postural control and age. *Acta Otolaryngol (Stockh)* 1993; 113: 119-22.
- Irving RM, Beynon GJ, Viani L, Hardy DG, Baguley DM, Moffat DA. The patient's perspective after vestibular schwannoma removal: quality of life and implications for management. *Am J Otol* 1995; 16: 331-7.
- Ishikawa K, Yasui N, Mineura K, Sasajima H, Togawa K. Significance of hearing preservation in acoustic neuroma surgery. *Acta Otolaryngol Suppl (Stockh)* 1998; 537: 16-9.
- Jackler RK. Acoustic neuroma (vestibular schwannoma). In: Jackler RK, Brackmann DE (editors): *Neurotology*. St Louis: Mosby 1994, 729-85.
- Jackson CA. Autoimmune inner ear disease. In: Jackler RK, Brackman DE (editors) *Neurotology*. St Louis: Mosby 1994, 517-25.
- Johansson R, Magnusson M, Fransson PA, Karlberg M. Discrimination of patients with acoustic neuroma and peripheral vestibular lesion with human posture dynamics. *Acta Otolaryngol Suppl (Stockh)* 1995;

- Johnson EW. Auditory test results in 500 cases of acoustic neuroma. *Arch Otolaryngol* 1977; 103:152-8.
- Jorgensen BG, Pedersen CB. Acoustic neuroma: follow-up of 78 patients. *Clin Otolaryngol* 1994; 19: 478-84.
- Juhola M, Hirvonen T, Aalto H, Pyykkö I. Computational problems in the analysis of eye movement signals in the determination of vestibulo-ocular reflex. *Comput Biomed Res* 1997; 30: 49-60.
- Jung S, Kang S, Kim T, Kim H, Jeong S, Seok-Chul, Lee J, Kim J, Kim S. Current surgical results of retrosigmoid approach in extralarge vestibular schwannomas. *Surg Neurol* 2000; 53: 370-7.
- Jääskeläinen J, Pyykkö I, Blomstedt G, Porras M, Palva T, Troupp H. Functional results of facial nerve suture after removal of acoustic neurinoma: Analysis of 25 cases. *Neurosurgery* 1990; 27: 408-11.
- Kanter WR, Eldringe R, Fabricant R, Allen JC, Koerber T. Central neurofibromatosis with bilateral acoustic neurinoma: Genetic, clinical and biochemical distinction from peripheral neurofibromatosis. *Neurology* 1980; 30: 851-9.
- Kanzaki J, Ogawa K, Inoue Y, Shiobara R, Toya S. Quality of hearing preservation in acoustic neuroma surgery. *Am J Otol* 1998; 19: 644-8.
- Karjalainen S, Nuutinen J, Neittaanmäki H, Naukkarinen A, asikainen R. The incidence of acoustic neuroma in autopsy material. *Arch Otorhinolaryngol* 1984; 240: 91-3.
- Kawamoto Y, Uozumi T, Kiya K, Fujioka Y, Kurisu K, Kawamoto K, Sugiyama K. Clinicopathological growth factors of acoustic neuromas. *Surg Neurol* 1995; 43: 546-52.
- Keiser-Kupfer MI, Freidlin V, Datiles MB et al. The association of posterior capsular lens opacities with bilateral acoustic neurinomas in patients with neurofibromatosis type 2. *Arch Ophthalmol* 1989; 107: 541-544.
- Keller JT, Saunders MC, Beduk A, Jollis JG. Innervation of the posterior fossa dura of the cat. *Brain Res Bull* 1985; 14: 97-102.
- Kemink JL, LaRouere MJ, Kileny PR, Telian SA, Hoff JT. Hearing preservation following suboccipital removal of acoustic neuromas. *Laryngoscope* 1990; 100: 597-602.
- Ketovuori H, Kohvakka A, Hurri H, Eskelinen L. The Finnish pain questionnaire: comparison of descriptions of pain in coronary heart disease and low back pain. *Scand J Rehab Med* 1984; 16:71-6.
- Ketovuori H, Pöntinen PJ. A pain vocabulary in Finnish - the Finnish pain questionnaire. *Pain* 1981; 11: 247-53.
- Krause F. Zur Freilegung der hinteren Felsenbeinfläche und des Kleinhirns. *Beitr Klin Chir* 1903; 37: 728-64.
- Krause F. Operationen in der hinteren Schädelgrube. *Arch Klin Chir* 1906; 81: 40-60.
- Kuk FK, Tyler RS, Russell HJ. The psychometric properties of a tinnitus handicap questionnaire. *Ear Hear* 1990; 11: 434-45.
- Lanman TH, Brackmann DE, Hitselberger WE, Subin B. Report of 190 consecutive cases of large acoustic tumors (vestibular schwannoma) removed via the translabyrinthine approach. *J Neurosurg* 1999; 90: 617-23.
- Lanser MJ, Sussman SA, Frazer K. Epidemiology, pathogenesis, and genetics of acoustic tumors. *Otolaryngol Clin North Am* 1992; 25: 499-520.
- Leksell L A note on the treatment of acoustic tumours. *Acta Chir Scand* 1971; 137: 673-5.
- Lesser THJ, Janzer RC, Kleihues P, Fish U. Clinical growth rate of acoustic schwannomas: Correlation with the growth fraction as defined by the monoclonal antibody Ki-67. *Skull Base Surg* 1991; 1: 11-5.
- Levo H, Pyykkö I, Blomstedt G. Non-surgical treatment of vestibular schwannoma patients. *Acta Otolaryngol Suppl (Stockh)* 1997; 529: 56-8.
- Lownie SP, Drake CG. Radical intracapsular removal of acoustic neuromas. *J Neurosurg* 1991; 74: 422.

- Lynn SG, Driscoll CLW, Harner SG, Beatty CW, Atkinson EJ. Assessment of dysequilibrium after acoustic neuroma removal. *Am J Otol* 1999; 20: 484-94.
- Magnusson M, Johansson R, Merche U, Harris S, Sundbärg G. Postural control in subjects with acoustic neurinoma and effects of surgery. In: Tos M, Thomsen J (editors). *Acoustic Neuroma. Proceedings of First Acoustic Neurinoma Conference 1991*. Amsterdam, New York: Kugler Publications, 1992: 921-3.
- Mathew GD, Fager GW, Suh KW, Houser OW, O'Brien PC. Symptoms, findings, and methods of diagnosis in patients with acoustic neuroma. *Laryngoscope* 1978; 88: 1893-903.
- Matsunaga T, Kanzaki J, Igarashi M. The limitations of hearing preservation in acoustic neuroma surgery: histological study of the interface between the eighth cranial nerve and the tumor. *Acta Otolaryngol (Stockh)* 1995; 115: 269-72.
- Melzack R. The short-form McGill pain questionnaire. *Pain* 1987; 30: 191-7.
- Melzack R. The McGill pain questionnaire: major properties and scoring methods. *Pain* 1975; 1: 277-99.
- Moskowitz MA, Buzzi MG. Neuroeffector function of sensory fibers: implications for headache mechanisms and drug actions. *J Neurol* 1991; 238: S18-S22.
- Mruzek M, Barin K, Nichols DS, Burnet CN, Welling DB. Effects of vestibular rehabilitation and social reinforcement on recovery following ablative vestibular surgery. *Laryngoscope* 1995; 105: 686-92.
- Möller P, Myrseth E, Pedersen PH, Larsen JL, Krakenes J, Moen G. Acoustic neuroma treatment modalities. Surgery, gamma-knife or observation? *Acta Otolaryngol Suppl (Stockh)* 2000; 543: 34-7.
- Naessen T, Lindmark B, Larsen HC. Better postural balance in elderly women receiving estrogens. *Am J Obstet Gynecol* 1997; 177: 412-6.
- Nager GT. Acoustic neurinomas. *Acta Otolaryngol (Stockh)* 1985; 99: 245-61.
- Nedzelski JM, Schessel DA, Pfeleiderer A, Kassel EE, Rowed DW. Conservative management of acoustic neuromas. *Otolaryngol Clin North Am* 1992; 25: 691-728.
- Nestor JJ, Korol HW, Nutik SL, Smith R. The incidence of acoustic neuromas. *Arch Otolaryngol Head Neck Surg* 1988; 114: 680.
- Niranjan AM, Lunsford LD. Radiosurgery: where we were, are, and may be in the third millenium. *Neurosurgery* 2000; 46: 531-43.
- Ojemann RG, Levine RA, Montgomery W, McGaffigan PM. Use of intraoperative auditory evoked potentials to preserve hearing in unilateral acoustic neuroma removal. *J Neurosurg* 1984; 61: 938-48.
- O'Leary DP, Davis LL, Maceri DR. Vestibular autorotation test asymmetry analysis of acoustic neuromas. *Otolaryngol Head Neck Surg* 1991; 104: 103-9.
- Palva T, Troupp H, Jauhiainen T. Hearing preservation in acoustic neurinoma surgery. *Acta Otolaryngol (Stockh)* 1985; 99: 1-7.
- Panse R. Klinische und pathologische Mitteilungen. IV Ein Glioms des Akustikus. *Arch Ohrenheilk* 1904; 61: 251-5.
- Parving A, Tos M, Thomsen J, Moller H, Buchwald C. Some aspects of life quality after surgery of acoustic neuroma. *Arch Otolaryngol Head Neck Surg* 1992; 118: 1061-4.
- Pedrosa CA, Ahern DK, McKenna MJ, Ojemann RG, Acquadro MA. Determinants and impact of headache after acoustic neuroma surgery. *Am J Otol* 1994; 15: 793-7.
- Perre J, Viala P, Foncin J-F. Involvement of cochlear nerve in acoustic tumors. *Acta Otolaryngol (Stockh)* 1990; 110:245-52.
- Poen JC, Golby AJ, Forster KM, Martin DP, Chinn DM, Hancock SL, Adler JR. Fractionated stereotactic radiosurgery and preservation of hearing in patients with vestibular schwannoma: a preliminary report. *Neurosurgery* 1999; 45: 1299-307.
- Pollock BE, Lundsford DL, Norén G. Vestibular schwannoma management in the next century: a radiosurgical perspective. *Neurosurgery* 1998; 43: 475-81.
- Power WJ, Foster CS. Update of sympathetic ophthalmia. *Int Ophthalmol Clin* 1996; 35: 127-37.

- Pyykkö I, Ishizaki H, Blomstedt G, Jääskeläinen J, Levo H. Further studies on postural stability in patients with removed acoustic neurinoma. In: Tagushi M, Igarashi M, Mori S (editors): Vestibular and Neural Front. Amsterdam: Elsevier Science BV, 1994, 291-4.
- Ramsay H, Blomstedt G. Near total removal of acoustic neurinoma. Results in 90 cases. In: Sanna M, Taibah A, Russo A, Mancini F (editors): Acoustic neurinoma and other CPA tumors. Bologna: Monduzzi Editore 1999, 201-4.
- Ramsden RT. The bloody angle: 100 years of acoustic neuroma surgery. *J Royal Soc Med* 1995; 88: P64-P68.
- Ramsden RT. 'A brilliant surgical result, the first recorded': Annandale's case, 3 May 1895. *J Laryngol Otol* 1995; 109: 369-73.
- Rhoton AL, Tedeschi H. Microsurgical anatomy of acoustic neuroma. *Otolaryngol Clin North Am* 1992; 25: 257-94.
- Riccardi VM. Von Recklinghausens neurofibromatosis. *N. Engl. J. Med.* 1981; 305: 1617-27.
- Rigby PL, Shah SB, Jackler RK, Chung JH, Cooke DD. Acoustic neuroma surgery: outcome analysis of patient-perceived disability. *Am J Otol* 1997; 18: 427-35.
- Robinette MS, Bauch CD, Olsen WO, Cevette MJ: Auditory brainstem response and magnetic resonance imaging for acoustic neuromas. *Arch Otolaryngol Head Neck Surg* 2000; 126: 963-6.
- Rosenberg SI. Natural history of acoustic neuromas. *Laryngoscope* 2000;110: 497-508.
- Rouleau GA, Wertelecki W, Haines JL, Hobbs WJ, Trofatter JA, Seizinger BR, Martuza RL, Superneau DW, Conneally PM, Gusella JF. Genetic linkage of bilateral acoustic neurofibromatosis to a DNA marker on chromosome 22. *Nature* 1987; 329: 246-8.
- Ruckenstein MJ, Harris JP, Cueva RA, Prioleau G, Alksne J. Pain subsequent to resection of acoustic neuromas via suboccipital and translabyrinthine approaches. *Am J Otol* 1996; 17: 620-4.
- Sadeh M, Martinovits G, Goldhammer Y. Occurrence of both neurofibromatosis 1 and 2 in the same individual with a rapidly progressive course. *Neurology* 1989; 39: 282-3.
- Sainio M, Straham T, Blomstedt G, Salonen O, Setälä K, Palotie A, Palo J, Pyykkö I, Peltonen L, Jääskeläinen J. Presymptomatic DNA and MRI diagnosis of neurofibromatosis 2 (NF2) with mild clinical course in an extended pedigree. *Neurology* 1995; 45: 1314-22.
- Samii M, Matthies C. Management of 1000 vestibular schwannomas (acoustic neuromas): hearing function in 1000 tumor resections. *Neurosurgery* 1997; 40: 248-62.
- Samii M, Matthies C, Tatagiba M. Management of vestibular schwannomas (acoustic neuromas): auditory and facial function after resection of 120 vestibular schwannomas in patients with neurofibromatosis 2. *Neurosurgery* 1997; 40: 696-705.
- Sanna M, Zini C, Mazzoni A, Gandolfi A, Parechi R, Pasani E, Gamoletti R. Hearing preservation in acoustic neuroma surgery. Middle cranial versus suboccipital approach. *Am J Otol* 1987; 8: 500-6.
- Saunders JE, Luxford WM, Devgan KK, Fetterman BL. Sudden hearing loss in acoustic neuroma patients. *Otolaryngol Head Neck Surg* 1995; 113: 23-31.
- Schessel DA, Nedzelski JM, Rowed D, Feghali JG. Pain after surgery for acoustic neuroma. *Otolaryngol Head Neck Surg* 1992; 107: 424-9.
- Schessel DA, Rowed DW, Nedzelski JM, Feghali JG. Postoperative pain following excision of acoustic neurinoma by the suboccipital approach: observations of possible cause and potential amelioration. *Am J Otol* 1993; 14: 491-4.
- Schuknecht HF, Woellner RC. An experimental and clinical study of deafness from lesions of the cochlear nerve. *J Laryngol Otol* 1955; 69: 75-97.
- Seizinger BR, Rouleau G, Ozelius LJ, Lane AH, Faryniarz AG, Chao MV, Huson S, Parry DM, Pericak-Vance MA et al. Genetic linkage of von Recklinghausen neurofibromatosis to the nerve growth factor receptor gene. *Cell* 1987; 49: 589-94.

- Seizinger BR, Rouleau G, Ozelius LJ, Lane AH, St George-Hyslop P, Huson S, Gusella JF, Martuza RL. Common pathogenetic mechanism for three tumour types in bilateral acoustic neurofibromatosis. *Science* 1987; 236: 317-9.
- Selesnick SH, Deora M, Drotman MB, Heier LA. Incidental discovery of acoustic neuromas. *Otolaryngol Head Neck Surg* 1999; 120:815-8.
- Selesnick SH, Jackler RK. Atypical hearing loss in acoustic neuroma patients. *Laryngoscope* 1993; 103: 437-41.
- Selesnick SH, Jackler RK. Clinical manifestations and audiologic diagnosis of acoustic neuromas. *Otolaryngol Clin N Am* 1992; 25: 521-51.
- Selesnick SH, Jackler RK, Pitts LH. Clinical presentation of acoustic neuroma in the MRI era. *Laryngoscope* 1993; 103: 431-6.
- Shelton C. Hearing preservation in acoustic tumor surgery. *Otolaryngol Clin North Am* 1992; 25: 609-21.
- Shelton C, House WF. Hearing improvement after acoustic neuroma tumor removal. *Otolaryngol Head Neck Surg* 1990; 103: 963-5.
- Shiffman F, Dancer J, Rothballer AB, Berrett A, Baum S. The diagnosis and evaluation of acoustic neuromas. *Otolaryngol Clin North Am* 1973; 6: 189-228.
- Silverstein H, McDaniel A, Norrell H, Haberkamp T. Hearing preservation after acoustic neuroma surgery with intraoperative direct eighth cranial nerve monitoring: Part II. A classification of results. *Otolaryngol Head Neck Surg* 1986; 95: 285-91.
- Slattery WH 3<sup>rd</sup>, Brackmann DE, Hitselberger W. Hearing preservation in neurofibromatosis type 2. *Am J Otol* 1998; 19: 638-43.
- Snow RB, Frazer RAR. Cerebellopontine angle tumor causing contralateral trigeminal neuralgia: a case report. *Neurosurgery* 1987; 21: 84-6.
- Soliman AM. A subpopulation of Meniere's patients produce antibodies that bind to endolymphatic sac antigen. *Am J Otol* 1996; 17: 76-80.
- Stewart MG, Chen AY, Wyatt JR, Favrot S, Beinart S, Coker NJ, Jenkins HA. Cost-effectiveness of the diagnostic evaluation of vertigo. *Laryngoscope* 1999; 109: 600-5.
- Syms III CA, House III JR, Luxford WM, Brackmann DE. Preoperative electroneurography and facial nerve outcome in acoustic neuroma surgery. *Am J Otol* 1997; 18: 401-3.
- Thomsen J, Tos M. Acoustic neuroma: clinical aspects, audiovestibular assessment, diagnostic delay, and growth rate. *Am J Otol* 1990; 11: 12-9.
- Tos M, Charabi S, Thomsen J. Clinical experience with vestibular schwannomas: epidemiology, symptomatology, diagnosis, and surgical results. *Eur Arch Otorhinolaryngol* 1998; 255: 1-6.
- Tos M, Charabi S, Thomsen J. Incidence of vestibular schwannomas. *Laryngoscope* 1999; 109: 736-40.
- Tos M, Thomsen J. The price of preservation of hearing in acoustic neuroma surgery. *Ann Otol Rhinol Laryngol* 1982; 91: 240-5.
- Tos M, Thomsen J, Harmsen Å. Is preservation of hearing in acoustic neuroma worthwhile? *Acta Otolaryngol Suppl (Stockh)* 1988; 452: 57-68.
- Towler HMA, Lightman S. Sympathetic ophthalmia. *Int Ophthalmol Clin* 1996; 35: 31-42.
- Tyler S, Stouffer J, Schum R. Audiological rehabilitation of the tinnitus client. *JARA* 1989; 22: 30-42.
- Umezu H, Aiba T, Tsuchida S, Seki Y. Early and late postoperative hearing preservation in patients with acoustic neuromas. *Neurosurgery* 1996; 39: 267-72.
- Van Leeuwen JPPM, Branspenning JCC, Meijer H, Cremers CWRJ. Quality of life after acoustic neuroma surgery. *Ann Otol Rhinol Laryngol* 1996; 105: 423-30.
- Vass Z, Shore S, Nuttall A., Jancso G, Brechtelsbauer PB, Miller J. Trigeminal ganglion innervation of the cochlea - a retrograde transport study. *Neuroscience* 1997; 79: 605-15.



- Vass Z, Shore S, Nuttall A, Miller J. Direct evidence of trigeminal innervation of the cochlear blood vessels. *Neuroscience* 1998; 84: 559-67.
- Vijayan N. Postoperative headache in acoustic neuroma. *Headache* 1995; 35: 98-100.
- Wackym PA, King WA, Poe DS, Meyer GA, Ojemann RG, Barker FG, Walsh PR, Staecker H. Adjunctive use of endoscopy during acoustic neuroma surgery. *Laryngoscope* 1999; 109: 1193-201.
- Welch AR, Dawes JDK. Suboccipital approach in the removal of acoustic neuromas. *J Laryngol Otol* 1985; 99: 1217-23.
- Wiet RJ, Teixido M, Liang JG. Complications in acoustic neuroma surgery. *Otolaryngol Clin North Am* 1992; 125: 389-412.
- Wiegand DA, Fickel V. Acoustic neuroma - the patient's perspective: subjective assessment of symptoms, diagnosis, therapy and outcome in 541 patients. *Laryngoscope* 1989; 99: 179-87.
- Ylikoski J, Palva T, Collan Y. Eighth nerve in acoustic neuromas. *Arch Otolaryngol* 1978; 104: 532-7.



## ORIGINAL PUBLICATIONS (I-V)