

# Improvement of cisplatin-induced injuries to sperm quality, the oxidant-antioxidant system, and the histologic structure of the rat testis by ellagic acid

Gaffari Türk, Ph.D.,<sup>a</sup> Ahmet Ateşşahin, Ph.D.,<sup>b</sup> Mustafa Sönmez, Ph.D.,<sup>a</sup> Ali Osman Çeribaşı, Ph.D.,<sup>c</sup> and Abdurrauf Yüce, Ph.D.<sup>d</sup>

<sup>a</sup> Department of Reproduction and Artificial Insemination, <sup>b</sup> Department of Pharmacology and Toxicology, <sup>c</sup> Department of Pathology, and <sup>d</sup> Department of Physiology, Faculty of Veterinary Medicine, Firat University, Elazığ, Turkey

**Objective:** To investigate whether ellagic acid (EA) has a possible protective effect against cisplatin (CP)-induced negative changes in epididymal sperm characteristics and the histologic structure of testis and prostate associated with oxidative stress in rats.

**Design:** Experimental study.

**Setting:** Firat University Medical School Experimental Research Center, Elazığ, Turkey.

**Patient(s):** Eight-week-old adult male Sprague Dawley rats (n = 24).

**Intervention(s):** Cisplatin was administered to rats at a single dose of 7 mg/kg IP. Ellagic acid was administered both separately and simultaneously with CP by gavage daily for 10 days at the dose of 10 mg/kg.

**Main Outcome Measure(s):** Reproductive organ weights, epididymal sperm characteristics, and histopathologic structure of testes and ventral prostate were determined along with malondialdehyde (MDA) and glutathione (GSH) levels and glutathione-peroxidase (GSH-Px) and catalase (CAT) activities of plasma, sperm, and testicular tissue.

**Result(s):** Ellagic acid ameliorated the CP-induced reductions in weights of testes, epididymides, seminal vesicles, and prostate along with epididymal sperm concentration and motility. Additionally, EA decreased the CP-induced increments in abnormalities of sperm. Whereas CP increased the MDA levels of plasma, sperm, and testicular tissue, it decreased the GSH-Px and CAT activities in the study samples compared with the control group. The administration of EA to CP-treated rats decreased the MDA level and increased GSH-Px and CAT activities in these samples. Cisplatin caused degeneration, necrosis, interstitial edema, and reduction in germinative cell layer thickness and rarely reduction in spermatogenic activity in some seminiferous tubules. The CP-induced changes in histopathologic findings of testis were partially reversed by treatment with EA. No significant changes were observed in the histopathologic structure of the prostate among any of groups.

**Conclusion(s):** Ellagic acid has a protective effect against testicular toxicity caused by CP. This protective effect of EA seems to be closely involved with the suppressing of oxidative stress. (Fertil Steril® 2008;89:1474–81. ©2008 by American Society for Reproductive Medicine.)

**Key Words:** Cisplatin, ellagic acid, oxidative stress, sperm characteristics, testis, rat

Cytotoxic chemotherapy has improved the survival rates in many conditions, particularly testicular malignancies. Treatment is, however, associated with significant morbidity, and testicular dysfunction is among the most common long-term side effects of this therapy (1). The introduction of alkylating agent cisplatin (CP; cis-diamminedichloroplatinum-II), an antineoplastic drug, into clinical practice has led to extraordinary improvement in the curability of testicular, ovarian, and bladder cancers (2, 3). Currently, treatment of testicular germ cell cancer with CP is often successful. However, receiving a high cumulative dose of CP (4) and/or other chemotherapeutics (5) may cause genotoxicity and infertility.

Cisplatin-based chemotherapy for testicular cancer may also result in impaired spermatogenesis (6), chromosomal abnormalities in sperm (7), and temporary or permanent azoospermia (8).

Fertilization and pregnancy are dependent on a series of functional sperm parameters, which are affected by reactive oxygen species (ROS) such as hydrogen peroxide (H<sub>2</sub>O<sub>2</sub>), superoxide anion (O<sub>2</sub><sup>-</sup>), and/or hydroxyl radical (·OH) (9). The production of ROS is a normal physiologic event in various organs, including the testis. However, the overproduction of ROS stimulates DNA fragmentation and can be detrimental to sperm function, associated with peroxidative damage to the mitochondria and plasma membrane. Additionally, spermatozoa are especially susceptible to peroxidative damage, because of high concentration of polyunsaturated fatty acids and low antioxidant capacity (10, 11). Lipid peroxidation destroys the structure of lipid matrix in the membranes of spermatozoa, and it is associated with loss of motility and defects

Received March 6, 2007; revised and accepted April 30, 2007.

Reprint requests: Dr. Gaffari Türk, Ph.D., Department of Reproduction and Artificial Insemination, Faculty of Veterinary Medicine, Firat University, 23119, Elazığ, Turkey (FAX: +90-424-238 81 73; E-mail: [gturk@firat.edu.tr](mailto:gturk@firat.edu.tr)).

of membrane integrity (12, 13). Cisplatin causes an increase in lipid peroxidation and reduction in antioxidant enzyme activities that prevent and/or protect against peroxidative damage in testis tissue.

The administration of some antioxidants, such as melatonin (14), vitamin E (15), vitamin C (16), and lycopene (17), may have a protective effect against CP-induced damage. Flavonoids, which are polyphenolic antioxidants, occur naturally in vegetables and fruits. Ellagic acid (EA; 2,3,7,8-tetrahydroxy[1]-benzopyrano[5,4,3-cde][1]benzopyran-5,10-dione) is a naturally occurring phenolic constituent in certain fruits and nuts, such as raspberries, strawberries, walnuts, longan seed, mango kernel (18, 19), and pomegranate (20–22). Ellagic acid has a variety of biologic activities, including potent antioxidant (23, 24), anticancer (25), antiproliferative (26), antimutagen (27), antiatherogenic, apoptotic (28), and estrogen receptor modulator (29) properties. Although the exact mechanism of EA effects is unknown, its potent scavenging action on both  $\cdot\text{OH}$  and  $\text{O}_2^-$  might be responsible for these effects (30). Therefore, the present study was designed to investigate whether EA has a protective effect against CP-induced negative changes in epididymal sperm characteristics and histologic structure of testis and prostate associated with oxidative stress in rats.

## MATERIALS AND METHODS

### Chemicals

Cisplatin (10 mg/10 mL, code 1876A) was obtained from Faulding Pharmaceuticals (Warwickshire, U.K.). Ellagic acid and the other chemicals were purchased from Sigma-Aldrich Chemical Co. (St. Louis, MO).

### Animals and Treatment Design

Twenty-four healthy adult male Sprague-Dawley rats (8 weeks old,  $249 \pm 7.2$  g body weight) were used in this study. The animals were obtained from Firat University School of Medicine Experimental Research Center, Elazığ, Turkey. They were maintained at  $24 \pm 3^\circ\text{C}$  with a 12-hour light/dark cycle and given a commercial pellet diet (Elazığ Food Company, Elazığ, Turkey) and fresh drinking water ad libitum. The animal use protocol was approved by the National Institutes of Health and the local Committee on Animal Research.

The rats were randomly divided into four groups, each group containing 6 rats. Cisplatin was intraperitoneally (IP) injected to animals at the single dose of 7 mg/kg. The dose and administration period of CP was selected according to previous studies that demonstrated significant damage in sperm parameters of rats (14, 17). Ellagic acid was suspended in corn oil at the concentration of 5 mg/mL and administered to animals by gavage at the dose of 10 mg/kg/day. Isotonic saline (1.0 mL) and corn oil (0.5 mL) were the vehicles for administering CP and EA, respectively. The first group of rats served as control and were administered corn oil for 10 days after a single-dose IP injection

of isotonic saline. The second group of rats were treated with EA for 10 days after a single-dose IP injection of isotonic saline. The third group received corn oil for 10 days after a single-dose IP injection of CP. The fourth group of rats were treated with EA for 10 days after a single-dose IP injection of CP.

### Sample Collection

The rats were killed with ether at the end of 10 days. Blood samples were collected from vena cava via sterile injector containing EDTA and centrifuged at 3000g for 10 minutes. Plasma was separated and then stored at  $-20^\circ\text{C}$  until analysis.

Testes, epididymides, seminal vesicles, and ventral prostate were removed, cleared of adhering connective tissue, and weighed. One of the testes and the prostate were fixed in 10% formalin for histopathologic examination. Plasma and the other testis samples were stored at  $-20^\circ\text{C}$  until biochemical analysis.

### Evaluation of Sperm Parameters

The epididymal sperm concentration was determined with a hemocytometer using a modified method described by Türk et al. (31). Briefly, the right epididymis was finely minced by anatomic scissors in 1 mL of isotonic saline in a Petri dish. It was completely squashed by a tweezers for 2 minutes and then allowed to incubate at room temperature for 4 hours to provide the migration of all spermatozoa from epididymal tissue to fluid. After incubation, the epididymal tissue–fluid mixture was filtered via strainer to separate the supernatant from tissue particles. The supernatant fluid was diluted at the rate of 1:200 with a solution containing 5 g sodium bicarbonate, 1 mL formalin (35% v/v), and 25 mg eosin per 100 mL distilled water using a pipette designed for counting red blood cells. Approximately 10  $\mu\text{L}$  of the diluted sperm suspension was transferred to counting chambers (Improved Neubauer Depth 0.1 mm; Labart, Darmstadt, Germany) and allowed to stand for 5 minutes. The sperm cells in two chambers were counted with the help of light microscope at  $\times 200$  magnification. The remainder of supernatant fluid of each rat was stored at  $-20^\circ\text{C}$  to determine the lipid peroxidation level and antioxidant enzyme activities in spermatozoa.

The percentage of forward progressive sperm motility was evaluated using a light microscope with heated stage as described by Sönmez et al. (32). For this process, a slide was placed on a light microscope with a heated stage warmed to  $37^\circ\text{C}$ , and then several droplets of Tris buffer solution [3.63 g tris (hydroxymethyl) aminomethane, 0.50 g glucose, 1.99 g citric acid, and 100 mL distilled water] were dropped on the slide and a very small droplet of fluid obtained from left cauda epididymis with a pipette was added to the Tris buffer solution and mixed by a cover-slip. The percentage of forward progressive sperm motility was evaluated visually at  $\times 400$  magnification. Motility estimations were performed

from three different fields in each sample. The mean of the three successive estimates was used as the final motility score. To determine the percentage of morphologically abnormal spermatozoa, slides stained with eosin-nigrosin (1.67 g eosin, 10 g nigrosin, and 2.9 g sodium citrate per 100 mL distilled water) were prepared. After preparation, the slides were viewed under a light microscope at  $\times 400$  magnification. A total of 300 sperm cells were examined on each slide (1800 cells in each group), and the head, tail, and total abnormality rates of spermatozoa were expressed as percentages (31).

## Biochemical Studies

**Lipid peroxidation level** Testes were homogenized in Teflon-glass homogenizer with buffer containing 1.5% potassium chloride to obtain 1:10 (w/v) whole homogenate to determine lipid peroxidation and antioxidant enzyme activity in testicular tissue. The plasma, sperm, and testicular tissue lipid peroxidation levels were measured according to the concentration of thiobarbituric acid reactive species (33). The amount of produced malondialdehyde (MDA) was used as an index of lipid peroxidation. Briefly, one volume of the test sample and two volumes of stock reagent (15% w/v trichloroacetic acid in 0.25 N HCl and 0.375% w/v thiobarbituric acid in 0.25 N HCl) were mixed in a centrifuge tube. The solution was heated in boiling water for 15 minutes. After cooling, the precipitate was removed by centrifugation at 1500g for 10 minutes, and then absorbance of the supernatant was read at 532 nm against a blank containing all reagents except test sample on a spectrophotometer (2R/UV-visible; Shimadzu, Tokyo, Japan). The MDA level was expressed as nmol/mL for plasma and sperm and as nmol/g protein for testicular tissue.

**Glutathione level and glutathione peroxidase activity** The reduced glutathione (GSH) contents in plasma, sperm and testicular tissue were measured at 412 nm using the method of Sedlak and Lindsay (34). The samples were precipitated with 50% trichloroacetic acid and then centrifuged at 1000g for 5 minutes. The reaction mixture contained 0.5 mL supernatant, 2.0 mL Tris-EDTA buffer (0.2 mol/L, pH 8.9) and 0.1 mL of 0.01 mol/L 5,5'-dithio-bis-2-nitrobenzoic acid. The solution was kept at room temperature for 5 minutes and then read at 412 nm on the spectrophotometer. The levels of GSH were expressed as nmol/mL for plasma and sperm and as nmol/g protein for testicular tissue. The glutathione peroxidase (GSH-Px) activity was determined according to the method of Lawrence and Burk (35). The reaction mixture consisted of 50 mmol/L potassium phosphate buffer (pH 7.0), 1 mmol/L EDTA, 1 mmol/L sodium azide ( $\text{NaN}_3$ ), 0.2 mmol/L reduced nicotinamide adenine dinucleotide phosphate (NADPH), 1 EU/mL oxidized GSH reductase, 1 mmol/L GSH, and 0.25 mmol/L  $\text{H}_2\text{O}_2$ . Enzyme source (0.1 mL) was added to 0.8 mL of the above mixture and incubated at 25°C for 5 minutes before initiation of the reaction with the addition of 0.1 mL of peroxide solution. The absorbance at 340 nm was recorded for 5 minutes on a spectrophotometer.

The activity was calculated from the slope of the lines as micromoles NADPH oxidized per minute. The blank value (with enzyme replaced by distilled water) was subtracted from each value. The GSH-Px activity was expressed as IU/g protein for plasma, sperm, and testicular tissue. The protein concentration was also measured by the method of Lowry et al. (36).

**Catalase activity** The plasma and sperm catalase (CAT) activity was measured as previously described by Góth (37). Briefly, 0.2 mL of plasma sample was incubated in 1.0 mL substrate (65  $\mu\text{mol/L}$  hydrogen peroxide in 50 mmol/L phosphate buffer, pH 7.0) at 37°C for 60 seconds. The enzymatic reaction was terminated with 1.0 mL 32.4 mmol/L ammonium molybdate. The color after this reaction was read on a spectrophotometer at 405 nm against blank containing all the components except the enzyme. The plasma and sperm CAT activity was measured according to the decrease in  $\text{H}_2\text{O}_2$  level and expressed as kU/L, where k is the first-order rate constant and U is the unit. The testicular tissue CAT activity was determined by measuring the decomposition of hydrogen peroxide at 240 nm, according to the method of Aebi (38), and was expressed as k/g protein.

## Histopathologic Examination

Fixed testes and prostate tissue samples in 10% formalin were embedded in paraffin, sectioned at 5  $\mu\text{m}$ , and stained with hematoxylin and eosin. Light microscopy was used for the evaluations. The diameter and germinal cell layer thickness of the seminiferous tubules (ST) from five different areas of each testicle were measured using an ocular micrometer, and averages were calculated.

## Data Analysis

Data are presented as mean  $\pm$  standard error of means. One-way analysis of variance and post hoc Tukey-HSD test was used to determine the differences between the groups in terms of all studied parameters using the SPSS/PC computer program (version 10.0; SPSS, Chicago, IL); a value of  $P < .05$  was considered to be significant.

## RESULTS

Table 1 demonstrates the changes in reproductive organ weights, epididymal sperm concentration, sperm motility, and abnormal sperm rate in response to various treatments for 10 days. Cisplatin caused statistically significant decreases in weights of testes ( $P < .01$ ), epididymides ( $P < .05$ ), and seminal vesicles ( $P < .01$ ) and insignificant ( $P > .05$ ) reduction in prostate weight compared with the control group. Administration of EA to CP-treated rats resulted in statistically significant increments ( $P < .01$ ) in testes weight and insignificant ( $P > .05$ ) increases in weights of epididymides, seminal vesicles, and prostate compared with the CP-alone group.

Although CP treatment significantly decreased sperm concentration ( $P < .01$ ) and sperm motility ( $P < .05$ ) and increased

**TABLE 1**

**Mean  $\pm$  SEM values of reproductive organ weights, diameter of seminiferous tubules (ST), germinal cell layer thickness, and sperm characteristics belonging to each group.**

Parameters	Control	Ellagic acid	Cisplatin	Cisplatin + ellagic acid
Testes (g)	1.37 $\pm$ 0.02 <sup>A</sup>	1.39 $\pm$ 0.03 <sup>A</sup>	1.25 $\pm$ 0.01 <sup>B</sup>	1.35 $\pm$ 0.01 <sup>A</sup>
Epididymides (g)	0.40 $\pm$ 0.01 <sup>ab</sup>	0.42 $\pm$ 0.01 <sup>a</sup>	0.35 $\pm$ 0.01 <sup>c</sup>	0.37 $\pm$ 0.08 <sup>bc</sup>
Seminal vesicles (g)	0.83 $\pm$ 0.06 <sup>A</sup>	0.92 $\pm$ 0.06 <sup>A</sup>	0.49 $\pm$ 0.03 <sup>B</sup>	0.71 $\pm$ 0.08 <sup>AB</sup>
Prostate (g)	0.40 $\pm$ 0.05 <sup>ab</sup>	0.44 $\pm$ 0.03 <sup>a</sup>	0.29 $\pm$ 0.02 <sup>b</sup>	0.34 $\pm$ 0.04 <sup>ab</sup>
Diameter of ST ( $\mu$ m)	211.04 $\pm$ 2.06	212.67 $\pm$ 3.19	207.84 $\pm$ 2.57	207.60 $\pm$ 1.97
Germinal cell layer thickness ( $\mu$ m)	54.08 $\pm$ 0.88 <sup>x</sup>	55.36 $\pm$ 0.57 <sup>x</sup>	48.40 $\pm$ 0.52 <sup>y</sup>	51.52 $\pm$ 0.49 <sup>z</sup>
Epididymal sperm concentration (million/g)	313.33 $\pm$ 11.53 <sup>A</sup>	326.36 $\pm$ 60.62 <sup>A</sup>	218.01 $\pm$ 10.90 <sup>B</sup>	296.64 $\pm$ 9.38 <sup>A</sup>
Sperm motility (%)	71.30 $\pm$ 4.79 <sup>a</sup>	72.64 $\pm$ 2.45 <sup>a</sup>	50.60 $\pm$ 6.78 <sup>b</sup>	69.32 $\pm$ 3.23 <sup>a</sup>
Abnormal sperm rate (%)				
Head	3.52 $\pm$ 1.22 <sup>a</sup>	2.32 $\pm$ 0.59 <sup>a</sup>	8.08 $\pm$ 1.42 <sup>b</sup>	4.96 $\pm$ 1.48 <sup>ab</sup>
Tail	4.24 $\pm$ 0.24 <sup>A</sup>	3.36 $\pm$ 0.77 <sup>A</sup>	11.76 $\pm$ 1.07 <sup>B</sup>	4.40 $\pm$ 1.19 <sup>A</sup>
Total	7.76 $\pm$ 1.36 <sup>A</sup>	5.68 $\pm$ 0.62 <sup>A</sup>	19.84 $\pm$ 2.07 <sup>B</sup>	9.36 $\pm$ 2.56 <sup>A</sup>

*Note:* The mean differences between the values bearing different superscript letters within the same row are statistically significant (a, b, and c:  $P < .05$ ; A and B:  $P < .01$ ; x, y, and z:  $P < .001$ ).

*Türk. Ellagic acid protects testis from CP toxicity. Fertil Steril 2008.*

the percentage of head ( $P < .05$ ), tail ( $P < .01$ ), and total ( $P < .01$ ) abnormality of sperm compared with the control group, the administration of EA to CP-treated rats significantly (including concentration [ $P < .01$ ], motility [ $P < .05$ ], and abnormality [ $P < .01$ ]) prevented the CP-induced negative effects in sperm quality, including concentration, motility, and abnormality, compared with the CP group.

The MDA and GSH levels and GSH-Px and CAT activities of all the treatment groups are shown in [Figure 1](#). Cisplatin caused significant increases in MDA levels in plasma ( $P < .01$ ), sperm ( $P < .001$ ), and testicular tissue ( $P < .001$ ) compared with the control group. Significant decreases ( $P < .001$ ) were observed in CP + EA rats compared with the CP-alone group with respect to plasma, sperm, and testicular tissue MDA levels.

Cisplatin did not significantly affect the GSH levels compared with the control and CP + EA groups. Only CP treatment caused significant decreases in GSH-Px activities of plasma ( $P < .05$ ), sperm ( $P < .01$ ), and testicular tissue ( $P < .001$ ) compared with the control group. Administration of EA to CP-treated rats prevented the CP-induced decreases in GSH-Px activities. Although decreases in the CAT activities of plasma (insignificant;  $P > .05$ ), sperm (insignificant;  $P > .05$ ), and testicular tissue (significant;  $P < .01$ ) were found in the CP group compared with the control group, it was observed that administration of EA to the CP-treated group could bring the plasma, sperm, and testicular tissue activity of this enzyme back to the level of the control group.

Upon histopathologic examination of testis, degeneration, necrosis, and interstitial edema were detected in CP-treated group compared with the control group. Desquamative germinal cells and the reductions in spermatogenic activity were seen in lumen of some ST of CP-treated rats ([Fig. 2A](#)). Although CP treatment caused a significant ( $P < .001$ ) decrease in germinal cell layer thickness of the testis compared with the control group, its effect was absent on the diameter of the ST ([Table 1](#)). The CP-induced changes in histopathologic findings of testis were partially reversed by treatment with EA ([Fig. 2B](#)). No significant changes were observed in the histopathologic structure of the prostate among any of treatment groups.

## DISCUSSION

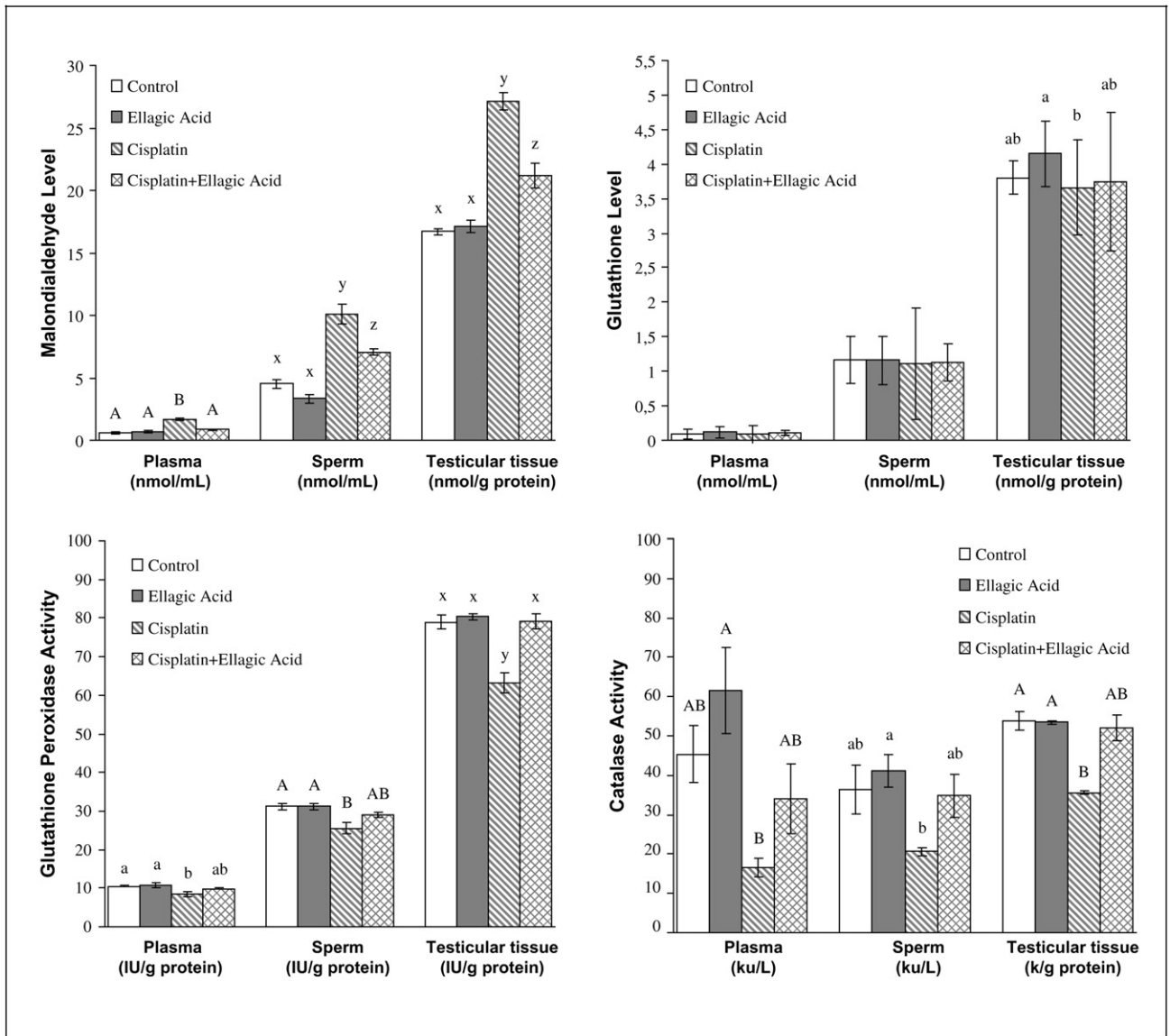
Many drugs used for chemotherapy, particularly alkylating agents, have gonadotoxic effects, and their gonadotoxicity or spermitoxicity is associated with variables such as anti-neoplastic agent group, number of chemotherapeutic agents used, their total doses, treatment duration, and individual sensitivity (1, 7). The present aim of all multiagent chemotherapeutic protocols is to achieve a balance between highest care results and the smallest side effects. Cisplatin is an effective alkylating chemotherapeutic agent using for the treatment of testicular, ovary, head, neck, and cervix cancer types (3, 8).

Germinal epithelial damage, resulting in oligo- or azoospermia, has long been a recognized consequence of



**FIGURE 1**

Malondialdehyde (MDA), glutathione (GSH) levels, and glutathione peroxidase (GSH-Px), catalase (CAT) activities in plasma, sperm, and testicular tissue samples. The mean differences between the bars bearing values with different superscript letters are statistically significant (a and b:  $P < .05$ ; A and B:  $P < .01$ ; x, y, and z:  $P < .001$ ).



Türk. *Ellagic acid protects testis from CP toxicity. Fertil Steril* 2008.

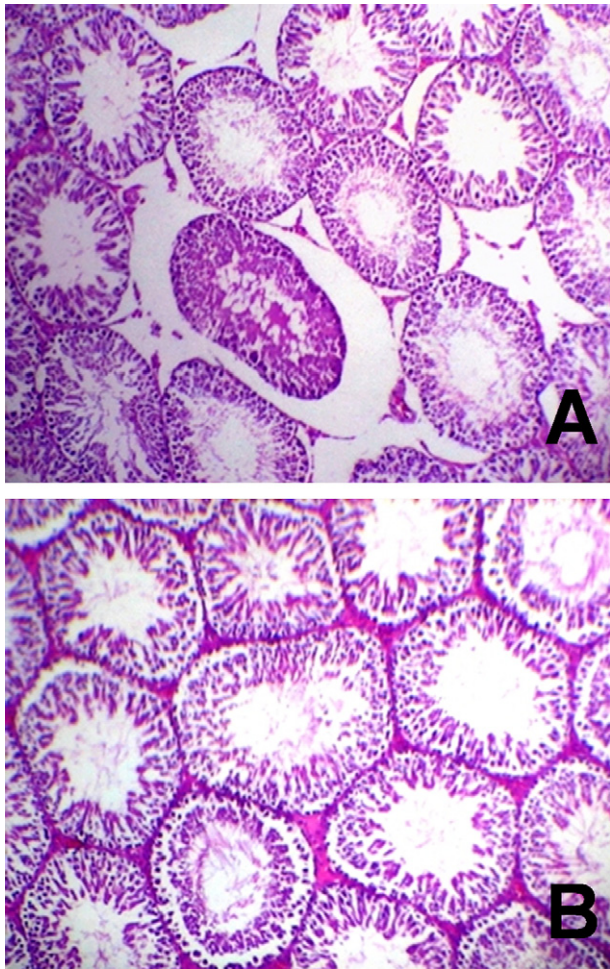
treatment with chemotherapeutic agents (6, 14, 17). Chemotherapeutic regimen-induced testicular damage is drug specific and dose related (1). In the present study, CP caused decreases in weights of testes, epididymides, seminal vesicles, and prostate compared with the control group. These findings are confirmed by our previous reports, which clearly demonstrated that the use of CP (14, 17) or adriamycin (39) caused decreases in the relative weight of the reproductive organs of healthy male rats. The reductions in testis and epididymis weights are due to the marked parenchymal atrophy in germinal cell layer thickness and the other deteriorated histopathologic findings in testis, along with decreased sperm

concentration, which were observed in CP-treated rats in the present study. The secretory activity of accessory glands is dependent on testosterone produced by the interstitial cells. In the present study, the reduction in accessory reproductive organ weights may be explained that the secretion of these organs likely decreased because testosterone levels were diminished, as suggested by our previous study in which a significant decrease was observed in plasma testosterone level of CP-treated rats (17).

The cellular/biochemical mechanisms by which CP causes reproductive toxicity is poorly understood; however, CP has

## FIGURE 2

Light microscopy of testis tissue from rat treated with cisplatin alone (A) and cisplatin + ellagic acid (B) (hematoxylin and eosin,  $\times 20$ ). Seminiferous tubules show degeneration, necrosis, and interstitial edema in the cisplatin-alone group. These damages were reversed by ellagic acid administration, and seminiferous tubules show nearly normal structure in the cisplatin + ellagic acid group.



Türk. Ellagic acid protects testis from CP toxicity. *Fertil Steril* 2008.

physiologic side effects leading to mutations and other genotoxic changes in DNA of nontumor cells (40), and CP exposure enhances intracellular ROS production (16). These highly reactive substances, which exhibit half-life times in the nanosecond ( $\cdot\text{OH}$ ) to milli-second range ( $\text{O}_2^-$ ), are very strong oxidants and are physiologically produced in any living cell during respiration (9). However, the overproduction of ROS stimulates DNA fragmentation and can be detrimental to sperm function associated with oxidative stress to the mitochondria and plasma membrane. Additionally, because of the extraordinarily high content of polyunsaturated fatty acids in the plasma membrane, which is an essential require-

ment for the male germ cell to maintain sperm functions, and owing to the very low content of protective systems, spermatozoa are highly susceptible to oxidative stress. The lipid peroxidation destroys the structure of lipid matrix in the membranes of spermatozoa and thus causes the loss of motility, presumably by a rapid loss of intracellular ATP leading to axonemal damage, decreased sperm viability, defects of membrane integrity, and increased morphologic defects (12, 13). The negative changes observed in sperm quality in the present study may be attributed to the peroxidation of polyunsaturated fatty acids in plasma membranes of spermatozoa, mutations, and other genotoxic effects caused by CP administration.

The increments in plasma, sperm, and testicular tissue MDA levels determined in the present study are due to the increases in peroxidation of lipids, which is supported by earlier studies of ours (14, 17) and of other researchers (15, 16), and in cellular peroxidative DNA damage caused by CP regimen. Glutathione is the major cellular sulfhydryl compound that serves as both a nucleophilic and an effective reductant by interacting with numerous electrophilic and oxidizing compounds. It can act as a nonenzymatic antioxidant by direct interaction of sulfhydryl group with ROS. However, in the present study GSH content does not appear to be altered, as confirmed by other studies (14, 17, 41), and this may be attributed to the direct conjugation of CP with free or protein-bound sulfhydryl groups, thereby interfering with the antioxidant functions. The decreases in the activities of the antioxidant enzymes might predispose the spermatozoa to increased ROS damage. Glutathione peroxidase and CAT have been considered to be the primary scavengers of  $\text{H}_2\text{O}_2$  (42, 43). In the absence of adequate GSH-Px or CAT activity, more  $\text{H}_2\text{O}_2$  could be converted to toxic  $\cdot\text{OH}$  radicals and may contribute to the oxidative stress of CP toxicity. The decline observed in the activities of these antioxidant enzymes in the present study may be elucidated with their inactivation caused by excessive ROS production. Therefore, the balance of this enzyme system is essential to dispose the  $\text{O}_2^-$  and peroxides generated in the spermatozoa. The reduction in the activities of these enzymes and increase in MDA could reflect the adverse effects of CP on this finely balanced antioxidant system in the epididymal sperm of rats.

Various agents have been attempted to protect from and/or prevent the side effects of many chemotherapeutics. Flavonoids are among these agents and are found in almost all food categories, with fruits and vegetables being the main source. Flavonoids have many functions, such as phenolic antioxidants, scavengers of free radicals, chelating agents, and modifiers of various enzymatic and biologic reactions (44). Ellagic acid is a naturally occurring plant polyphenol (18, 19) that exhibits antioxidative properties both in vivo (23, 24) and in vitro (26). In fact, EA has been shown to exert a potent scavenging action on both  $\text{O}_2^-$  and  $\cdot\text{OH}$ , as well as lipid peroxidation (45). Administration of EA to CP-treated rats resulted in a statistically significant increment in testes weight and insignificant increases in weights of epididymides,

seminal vesicles, and prostate. Additionally, the CP-induced decreases in germinal cell layer thickness, and the other deteriorated histopathologic findings of testis were partially ameliorated by EA administration to CP-treated rats. This status may be explained with partially attenuation of CP-induced degeneration, reduction in germinal cell layer thickness, and possibly enhancement of sperm concentration in the epididymis and increment in fluids of accessory glands due to the decreased lipid peroxidation and increased antioxidant enzyme activities caused by EA administration.

The declining of lipid peroxidation in all samples studied apparently indicates that EA potently scavenged the free radicals ( $O_2^-$  and  $\cdot OH$ ), and suppressed oxidative DNA damage. The antioxidant activity of EA and mitigation of ROS-induced depletion of GSH-Px and CAT activities also show that EA has strong antioxidant activity.

In conclusion, this study apparently suggests that EA has a protective effect against testicular toxicity caused by CP. This protective effect of EA seems to be closely involved with the suppression of oxidative stress. Therefore, EA may be used combined with CP in chemotherapeutic treatments to improve CP-induced injuries in sperm quality and oxidative stress parameters.

## REFERENCES

- Howell SJ, Shalet SM. Testicular function following chemotherapy. Hum Reprod Update 2001;7:363–9.
- Hooser SB, van Dijk-Knijnenburg WCM, Waalkens-Berendsen IDH, Smits-van Prooije AE, Snoij NJ, Baan RA, et al. Cisplatin-DNA adduct formation in rat spermatozoa and its effect on fetal development. Cancer Lett 2000;151:71–80.
- Colpi GM, Contalbi GF, Nerva F, Sagone P, Piediferro G. Testicular function following chemo-radiotherapy. Eur J Obstet Gynecol Reprod Biol 2004;113S:S2–6.
- Desantis M, Albrecht W, Hörtl W, Jörg P. Impact of cytotoxic treatment on long-term fertility in patients with germ-cell cancer. Int J Cancer 1999;83:864–5.
- Ishikawa T, Kamidono S, Fujisawa M. Fertility after high-dose chemotherapy for testicular cancer. Urology 2004;63:137–40.
- Cherry SM, Hunt PA, Hassold TJ. Cisplatin disrupts mammalian spermatogenesis, but does not affect recombination or chromosome segregation. Mutat Res 2004;564:115–28.
- Martin RH, Ernst S, Rademaker A, Barclay L, Ko E, Summers N. Analysis of sperm chromosome complements before, during, and after chemotherapy. Cancer Genet Cytogenet 1999;108:133–6.
- Howell SJ, Shalet SM. Spermatogenesis after cancer treatment: damage and recovery. J Natl Cancer Inst Monogr 2005;34:12–7.
- Henkel R. The impact of oxidants on sperm function. Andrologia 2005;37:205–6.
- de Lamirande E, Jiang H, Zini A, Kodama H, Gagnon C. Reactive oxygen species and sperm physiology. Rev Reprod 1997;2:48–54.
- Köksal IT, Usta M, Orhan I, Abbasoğlu S, Kadioğlu A. Potential role of reactive oxygen species on testicular pathology associated with infertility. Asian J Androl 2003;5:95–9.
- Sharma RK, Agarwal A. Role of reactive oxygen species in male infertility. Urology 1996;48:835–50.
- Sikka SC. Oxidative stress and role of antioxidants in normal and abnormal sperm function. Front Biosci 1996;1:78–86.
- Ateşahin A, Şahna E, Türk G, Çeribaşı AO, Yılmaz S, Yüce A, et al. Chemoprotective effect of melatonin against cisplatin-induced testicular toxicity in rats. J Pineal Res 2006;41:21–7.
- Choudhury RC, Jagdale MB. Vitamin E protection from/potential of the cytogenetic toxicity of cisplatin in Swiss mice. J Chemother 2002;14:397–405.
- Giri A, Khynriam D, Prasad SB. Vitamin C mediated protection on cisplatin induced mutagenicity in mice. Mutat Res 1998;421:139–48.
- Ateşahin A, Karahan I, Türk G, Gür S, Yılmaz S, Çeribaşı AO. Protective role of lycopene on cisplatin-induced changes in sperm characteristics, testicular damage and oxidative stress in rats. Reprod Toxicol 2006;21:42–7.
- Soong Y-Y, Barlow PJ. Antioxidant activity and phenolic content of selected fruit seeds. Food Chem 2004;88:411–7.
- Soong Y-Y, Barlow PJ. Quantification of gallic acid and ellagic acid from longan (*Dimocarpus longan* Lour.) seed and mango (*Mangifera indica* L.) kernel and their effects on antioxidant activity. Food Chem 2006;97:524–30.
- Lei F, Xing D-M, Xiang L, Zhao Y-N, Wang W, Zhang L-J. Pharmacokinetic study of ellagic acid in rat after oral administration of pomegranate leaf extract. J Chromatogr B 2003;796:189–94.
- Sudheesh S, Vijayalakshmi NR. Flavonoids from *Punica granatum*—potential antiperoxidative agents. Fitoterapia 2005;76:181–6.
- Wang R-F, Xie W-D, Zhang Z, Xing D-M, Ding Y, Wang W, et al. Bioactive compounds from the seeds of *Punica granatum* (pomegranate). J Nat Prod 2004;67:2096–8.
- Hassoun EA, Walter AC, Alsharif NZ, Stohs SJ. Modulation of TCDD-induced fetotoxicity and oxidative stress in embryonic and placental tissues of C57BL/6J mice by vitamin E succinate and ellagic acid. Toxicology 1997;124:27–37.
- Hassoun EA, Vodhanel J, Abushaban A. The modulatory effects of ellagic acid and vitamin E succinate on TCDD-induced oxidative stress in different brain regions of rats after subchronic exposure. J Biochem Mol Toxicol 2004;18:196–203.
- Whitley AC, Stoner GD, Darby MV, Walle T. Intestinal epithelial cell accumulation of the cancer preventive polyphenol ellagic acid—extensive binding to protein and DNA. Biochem Pharmacol 2003;66:907–15.
- Seeram NP, Adams LS, Henning SM, Niu Y, Zhang Y, Nair MG, et al. In vitro antiproliferative, apoptotic and antioxidant activities of punicalagin, ellagic acid and a total pomegranate tannin extract are enhanced in combination with other polyphenols as found in pomegranate juice. J Nutr Biochem 2005;16:360–7.
- Loarca-Piña G, Kuzmicky PA, de Mejía EG, Kado NY. Inhibitory effects of ellagic acid on the direct-acting mutagenicity of aflatoxin B<sub>1</sub> in the *Salmonella* microsuspension assay. Mutat Res 1998;398:183–7.
- Yu Y-M, Chang W-C, Wu C-H, Chiang S-Y. Reduction of oxidative stress and apoptosis in hyperlipidemic rabbits by ellagic acid. J Nutr Biochem 2005;16:675–81.
- Papoutsis Z, Kassi E, Tsiapara A, Fokialakis N, Chrousos GP, Moutsatsou P. Evaluation of estrogenic/antiestrogenic activity of ellagic acid via the estrogen receptor subtypes ER $\alpha$  and ER $\beta$ . J Agric Food Chem 2005;53:7715–20.
- Priyadarsini KI, Khopde SM, Kumar SS, Mohan H. Free radical studies of ellagic acid, a natural phenolic antioxidants. J Agric Food Chem 2002;50:2200–6.
- Türk G, Ateşahin A, Sönmez M, Yüce A, Çeribaşı AO. Lycopene protects against cyclosporine A-induced testicular toxicity in rats. Theriogenology 2007;67:778–85.
- Sönmez M, Türk G, Yüce A. The effect of ascorbic acid supplementation on sperm quality, lipid peroxidation and testosterone levels of male Wistar rats. Theriogenology 2005;63:2063–72.
- Placer ZA, Cushman LL, Johnson BC. Estimation of product of lipid peroxidation (malonyl dialdehyde) in biochemical systems. Anal Biochem 1966;16:359–64.
- Sedlak J, Lindsay RH. Estimation of total, protein-bound and nonprotein sulphhydryl groups in tissue with Ellman's reagent. Anal Biochem 1968;25:192–205.
- Lawrence RA, Burk RF. Glutathione peroxidase activity in selenium-deficient rat liver. Biochem Biophys Res Commun 1976;71:952–8.
- Lowry OH, Rosebrough NJ, Farr AL, Randall RJ. Protein measurement with folin phenol reagent. J Biol Chem 1951;193:265–75.



37. Góth L. A simple method for determination of serum catalase activity and revision of reference range. *Clin Chim Acta* 1991;196:143–51.
38. Aebi H. Catalase. In: Bergmeyer HU, ed. *Methods in enzymatic analysis*. New York: Academic Press, 1983:276–86.
39. Ateşşahin A, Türk G, Karahan I, Yılmaz S, Çeribaşı AO, Bulmuş Ö. Lycopene prevents adriamycin-induced testicular toxicity in rats. *Fertil Steril* 2006;85(Suppl 1):1216–22.
40. Sanocka D, Kurpisz M. Reactive oxygen species and sperm cells. *Reprod Biol Endocrinol* 2004;2(12):1–7.
41. Khyriam D, Prasad SB. Cisplatin-induced genotoxic effects and endogenous glutathione levels in mice bearing ascites Dalton's lymphoma. *Mutat Res* 2003;526:9–18.
42. Vernet P, Aitken RJ, Drevet JR. Antioxidant strategies in the epididymis. *Mol Cell Endocrinol* 2004;216:31–9.
43. Selvakumar E, Prahalathan C, Sudharsan PT, Varalakshmi P. Chemoprotective effect of lipoic acid against cyclophosphamide-induced changes in the rat sperm. *Toxicology* 2006;217:71–8.
44. Khanduja KL, Gandhi RK, Pathania V, Syal N. Prevention of N-nitrosodiethylamine-induced lung tumorigenesis by ellagic acid and quercetin in mice. *Food Chem Toxicol* 1999;37:313–8.
45. Iino T, Nakahara K, Miki W, Kiso Y, Ogawa Y, Kato S, et al. Less damaging effect of whisky in rat stomachs in comparison with pure ethanol. Role of ellagic acid, the nonalcoholic component. *Digestion* 2001;64:214–21.