

Lycopene protects against cyclosporine A-induced testicular toxicity in rats

Gaffari Türk^{a,*}, Ahmet Ateşşahin^b, Mustafa Sönmez^a, Abdurrauf Yüce^c,
Ali Osman Çeribaşı^d

^aDepartment of Reproduction and Artificial Insemination, Faculty of Veterinary Medicine, Firat University, 23119 Elazığ, Turkey

^bDepartment of Pharmacology and Toxicology, Faculty of Veterinary Medicine, Firat University, 23119 Elazığ, Turkey

^cDepartment of Physiology, Faculty of Veterinary Medicine, Firat University, 23119 Elazığ, Turkey

^dDepartment of Pathology, Faculty of Veterinary Medicine, Firat University, 23119 Elazığ, Turkey

Received 22 June 2006; received in revised form 16 October 2006; accepted 19 October 2006

Abstract

Cyclosporine A (CsA)-induced direct failures in hypothalamic–pituitary–gonadal axis and Sertoli cell phagocytic function have been considered for testicular toxicity so far. It has clearly been reported that oxidative stress leads to damage in sperm functions and structure of the testis. Therefore, this study was conducted to demonstrate whether CsA causes testicular and spermatozoal toxicity associated with the oxidative stress, and to investigate the possible protective effect of lycopene against CsA-induced damages in all reproductive organs and sperm characteristics in male rats. While the daily administration of CsA at the dose 15 mg/kg for 21 days significantly decreased the seminal vesicles weight, epididymal sperm concentration, motility, testicular tissue glutathione (GSH), glutathione peroxidase (GSH-Px) and catalase (CAT), diameter of seminiferous tubules and germinal cell thickness, it increased malondialdehyde (MDA) level and abnormal sperm rates along with degeneration, necrosis, desquamative germ cells in testicular tissue. However, the CsA along with simultaneous administration of lycopene at the dose of 10 mg/kg markedly ameliorated the CsA-induced all the negative changes observed in the testicular tissue, sperm parameters and oxidant/antioxidant balance. In conclusion, CsA-induced oxidative stress leads to the structural and functional damages in the testicular tissue and sperm quality of rats and, lycopene has a potential protective effect on these damages.

© 2006 Elsevier Inc. All rights reserved.

Keywords: Cyclosporine A; Lycopene; Oxidative stress; Reproductive organs; Sperm characteristics

1. Introduction

Today, organ and bone marrow are successfully transplanted. But, the rejection reactions occur when a foreign organ is attacked by the body's immune system. Many immunosuppressive drugs are used to prevent the

rejection reactions. CsA, a fungal peptide, is most frequently used in the transplant surgery and the treatment of autoimmune diseases as a potent immunosuppressant, because of its specific inhibiting effect on the lymphokine generation, differentiation and signal transduction pathways of cell T receptor [1–3]. However, clinical use of CsA is limited by side effects which the most important is nephrotoxicity [4–6]. The previous studies have shown that CsA also caused toxicities such as vascular dysfunction [7], hepatotoxicity [8,9], ovarian damage [10], testicular [11,12] and spermatozoal toxicity [13–18].

* Corresponding author. Tel.: +90 424 237 00 00/3987;
fax: +90 424 238 81 73.

E-mail addresses: gTURK@firat.edu.tr, gaffariturk@hotmail.com
(G. Türk).

Lycopene, an aliphatic hydrocarbon and is richly found in tomato and tomato-based products, is one of the 600 known naturally occurring carotenoids [19]. Recently, lycopene has received particular attention as a result of studies indicating that it has highly efficient antioxidant and free radical scavenging capacity [20,21]. It has been demonstrated in previous studies that the biochemical mechanism of CsA-induced toxicity is attributed to the oxidative stress [3,6]. But, CsA-induced direct alterations in hypothalamic–pituitary–gonadal axis [13–15] and reduction in Sertoli cell phagocytic function [12] are probably responsible for the pathogenesis of testicular and spermatozoal toxicity. However, there is no exact evidence about that CsA causes infertility by affecting the oxidant/antioxidant balance of testis. Therefore, this study was conducted to demonstrate whether the CsA leads to testicular and spermatozoal toxicity associated with the oxidative stress, and to investigate the possible protective effect of lycopene against CsA-induced damages in reproductive organs and sperm characteristics of male rats.

2. Materials and methods

2.1. Chemicals

CsA (Sandimmun® sol., 50 mg/ml) was purchased from Novartis (İstanbul, Turkey). Lycopene 10% FS (Redivivo TM, Code 7803) was obtained from DSM Nutritional Products (İstanbul, Turkey). All other chemicals were purchased from Sigma (St. Louis, MO, USA).

2.2. Experimental groups and sample collection

Twenty-four healthy adult male Sprague–Dawley rats (8 weeks old, 200–240 g body weight) were used in this study. The animals were obtained from University of Firat, Faculty of Medicine, Experimental Research Centre (Elazığ, Turkey) and were housed under standard laboratory conditions (temperature 24 ± 3 °C, humidity 40–60%, 12 h/12 h light/dark cycle). The commercial pellet diet (Elazığ Food Company, Elazığ, Turkey) and fresh drinking water were given ad libitum. Animal use protocol was approved by the National Institutes of Health and Local Committee on Animal Research.

CsA was subcutaneously (sc) injected to the animals at the dose of 15 mg/kg day for 21 days. The dose and administration period of CsA were selected according to previous studies [4,22]. About 5 mg of lycopene was suspended in 0.5 ml corn oil and administered to the animals by gavage at the dose of 10 mg/kg day for 21

days. The dose of lycopene used in this study was selected on the basis of the previous studies [23,24]. The rats were randomly divided into four experimental groups of six rats each. These groups were arranged as follows:

- Group 1 —control: treated with placebo – received sc injection of 0.5 ml isotonic saline +0.5 ml corn oil for 21 days.
- Group 2 —CsA: received sc injection of CsA +0.5 ml corn oil for 21 days.
- Group 3 —lycopene: treated with sc injection of 0.5 ml isotonic saline + lycopene for 21 days.
- Group 4 —CsA + lycopene: received sc injection of CsA + lycopene for 21 days.

The rats were decapitated at the end of the treatment period. Testes, epididymides, seminal vesicles and prostate were removed, cleared of adhering connective tissue and weighed. One of the testes was fixed in 10% formalin sol. for histopathological examinations. The other testis samples were also stored at -20 °C until biochemical analyses.

2.3. Evaluation of sperm characteristics

The epididymal sperm concentration was determined with a hemocytometer using a modification of the method described by Yokoi et al. [25]. Briefly, the right epididymis was finely minced by anatomical scissors within 1 ml of isotonic saline in a Petri dish. It was completely squashed by a tweezers for 2 min, and then allowed to incubate at room temperature for 4 h to provide the migration of all spermatozoa from epididymal tissue to fluid. After incubation, the epididymal tissue-fluid mixture was filtered via strainer to separate the supernatant from tissue particles. The supernatant fluid containing all epididymal spermatozoa was drawn into the capillary tube up to 0.5 lines of the pipette designed for counting red blood cells. The solution containing 5 g sodium bicarbonate, 1 ml formalin (35%, v/v) and 25 mg eosin per 100 ml distilled water was pulled into the bulb up to 101 lines of the pipette. This gave a dilution rate of 1:200 in this solution. Approximately 10 μ l of the diluted sperm suspension was transferred to each counting chamber of Improved Neubauer (Deep 1/10 mm, LABART, Germany) and allowed to stand for 5 min. The sperm cells in both chambers were counted with the help of light microscope at 200 \times magnification.

The percentage of forward progressive sperm motility was evaluated using a light microscope with heated stage as described by Sönmez et al. [26]. For this

process, a slide was placed on a light microscope with a heated stage warmed to 37 °C, and then several droplets of Tris buffer solution [Tris (hydroxymethyl) amino-methane 3.63 g, glucose 0.50 g, citric acid 1.99 g and distilled water 100 ml] were dropped on the slide and a very small droplet of fluid obtained from left cauda epididymis with a pipette was added on the Tris buffer solution and mixed by a cover-slip. The percentage of forward progressive sperm motility was evaluated visually at 400× magnification. Motility estimations were performed from three different fields in each sample. The mean of the three successive estimates was used as the final motility score. To determine the percentage of morphologically abnormal spermatozoa, the slides stained with eosin-nigrosin (1.67 g eosin, 10 g nigrosin and 2.9 g sodium citrate per 100 ml distilled water) were prepared. After preparation, the slides were viewed under a light microscope at 400× magnification. For each animal, a total of 300 sperm cells were examined on each slide.

2.4. Biochemical measurements

The testicular tissue was homogenized in a Teflon-glass homogenizer with a buffer containing 1.5% potassium chloride to obtain 1:10 (w/v) whole homogenate. The testicular tissue lipid peroxidation level was measured according to the concentration of thiobarbituric acid reactive substances (TBARs) [27]. The amount of produced malondialdehyde (MDA) was used as an index of lipid peroxidation. Briefly, one volume of the test sample and two volume of stock reagent (15%, w/v trichloroacetic acid in 0.25 N HCl and 0.375%, w/v thiobarbituric acid in 0.25N HCl) were mixed in a centrifuge tube. The solution was heated in boiling water for 15 min. After cooling, the precipitate was removed by centrifugation at 1500 × *g* for 10 min, and then absorbance of the supernatant was read at 532 nm against a blank containing all reagents except test sample on a spectrophotometer (Shimadzu 2R/UV-vis, Tokyo, Japan). The MDA level was expressed as nmol/ml.

The reduced glutathione (GSH) level of testicular tissue was measured at 412 nm using the method of Sedlak and Lindsay [28]. The samples were precipitated with 50% trichloroacetic acid, and then centrifuged at 1000 × *g* for 5 min. The reaction mixture contained 0.5 ml of supernatant, 2.0 ml of Tris-EDTA buffer (0.2 mol/l; pH 8.9) and 0.1 ml of 0.01 mol/l 5,5'-dithio-bis-2-nitrobenzoic acid. The solution was kept at room temperature for 5 min, and then read at 412 nm on the spectrophotometer. The level of GSH was expressed as nmol/ml.

The glutathione peroxidase (GSH-Px) activity in testicular tissue was determined according to the method of Lawrence and Burk [29]. The reaction mixture consisted of 50 mM potassium phosphate buffer (pH 7.0), 1 mM EDTA, 1 mM sodium azide (NaN₃), 0.2 mM reduced nicotinamide adenine dinucleotide phosphate (NADPH), 1 EU/ml oxidized glutathione (GSSG)-reductase, 1 mM GSH, and 0.25 mM H₂O₂. Enzyme source (0.1 ml) was added to 0.8 ml of the above mixture and incubated at 25 °C for 5 min before initiation of the reaction with the addition of 0.1 ml of peroxide solution. The absorbance at 340 nm was recorded for 5 min on a spectrophotometer. The activity was calculated from the slope of the lines as micromoles of NADPH oxidized per minute. The blank value (the enzyme was replaced with distilled water) was subtracted from each value. The protein concentration was also measured by the method of Lowry et al. [30]. The GSH-Px activity was expressed as IU/g protein.

The testicular tissue catalase (CAT) activity was determined by measuring the decomposition of hydrogen peroxide at 240 nm, according to the method of Aebi [31], and was expressed as *k* U/g protein, where *k* is the first-order rate constant.

2.5. Histopathological examination

Fixed testis tissue samples in 10% formalin were embedded in paraffin, sectioned at 5 μm, and were stained with hematoxylin and eosin (H&E). Light microscopy was used for the evaluations. The diameter and germinal cell thickness of the seminiferous tubules (ST) from five different areas of each testicle were measured using an ocular micrometer in a light microscope, and the average size of ST and germinal cell thickness were calculated.

2.6. Statistical analysis

The SPSS/PC program (Version 10.0; SPSS, Chicago, IL) was used for the statistical analysis. Data are presented as mean ± standard error of means (S.E.M.), and a value of *P* < 0.05 was considered as significant. Values were compared by one-way analysis of variance (ANOVA) and post hoc Tukey—HSD test to determine the differences among all the groups.

3. Results

3.1. Reproductive organ weights

Table 1 shows the changes in the reproductive organ weights in response to various treatments for 21 days of

Table 1
The weights of testis, epididymis, seminal vesicles and prostate in all groups

Organ weights (g)	Control (n = 6)	CsA (n = 6)	Lycopene (n = 6)	CsA + lycopene (n = 6)
Testis	1.29 ± 0.04	1.16 ± 0.11	1.28 ± 0.03	1.23 ± 0.02
Epididymis	0.30 ± 0.04	0.30 ± 0.05	0.32 ± 0.01	0.35 ± 0.03
Seminal vesicles	0.55 ± 0.05 a	0.19 ± 0.03 b	0.59 ± 0.08 a	0.41 ± 0.05 a
Prostate	0.31 ± 0.05	0.21 ± 0.05	0.33 ± 0.07	0.29 ± 0.04

Data are expressed as mean ± S.E.M. The mean differences between values bearing different lower case (a and b) within the same row are statistically significant ($P < 0.01$).

treatment period. No statistically significant differences were observed between any of groups in terms of testes, epididymides and prostate weights. However, CsA administration caused the significant decrease ($P < 0.01$) in weights of seminal vesicles in comparison to the control group. A marked ($P < 0.01$) increase in CsA + lycopene group was observed in seminal vesicles weight compared to CsA group.

3.2. Epididymal sperm characteristics

The effects of CsA and lycopene administrations on epididymal sperm concentration, sperm motility and abnormal sperm rate are presented in Figs. 1 and 2 and Table 2, respectively. Only lycopene administration for 21 days did not markedly affect all the studied sperm characteristics when compared to the control group. CsA treatment significantly ($P < 0.05$) decreased sperm concentration (37.7%), sperm motility (40.9%) and increased the percentage of head (225%) and entire (179%) abnormality of sperm in comparison to the control group. The administration of lycopene to CsA-treated rats significantly ($P < 0.05$) protected the CsA-

induced negative effects in sperm quality including the concentration (49.9%), motility (53.8%) and abnormality (58.1% in head, 54.7% in entire) versus CsA group.

3.3. Biochemical parameters

Markers of testicular tissue lipid peroxidation and antioxidant status of all the groups are given in Table 3. Lycopene treatment remained ineffective in MDA and GSH levels along with GSH-Px and CAT activities in comparison to the control group. While CsA administration resulted in a significant ($P < 0.01$) increase in MDA level when compared to the control group, the CsA + lycopene treatment provided a marked reduction ($P < 0.01$) in the increased MDA levels versus CsA group.

CsA treatment caused the significant decreases in GSH levels ($P < 0.01$), GSH-Px ($P < 0.05$) and CAT ($P < 0.05$) activities when compared to the control group. However, administration of lycopene to CsA-treated rats prevented the CsA-induced decreases in these antioxidants.

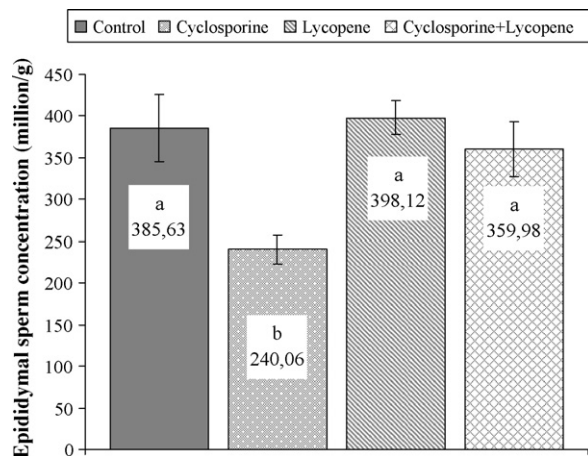


Fig. 1. Epididymal sperm concentrations in all groups. The mean differences between the bars bearing values with different lower case (a and b) are statistically significant ($P < 0.05$).

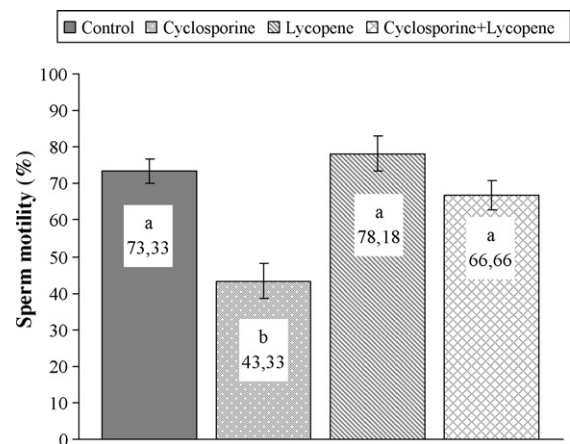


Fig. 2. The percentage of sperm motility in all groups. The mean differences between the bars bearing values with different lower case (a and b) are statistically significant ($P < 0.05$).

Table 2
The percent values of abnormal sperm in all groups

Sperm cell	Control (n = 6)	CsA (n = 6)	Lycopene (n = 6)	CsA + lycopene (n = 6)
Head	2.00 ± 0.50 a	6.50 ± 1.22 b	1.76 ± 0.38 a	2.72 ± 0.65 ab
Tail	3.50 ± 0.50	8.88 ± 2.40	3.00 ± 0.96	4.25 ± 1.18
Entire	5.50 ± 1.00 a	15.38 ± 3.24 b	4.76 ± 0.57 a	6.97 ± 1.09 ab

Data are expressed as mean ± S.E.M. The mean differences between values bearing different lower case (a and b) within the same row are statistically significant ($P < 0.05$).

Table 3
The MDA and GSH levels, GSH-Px and CAT activities and diameter of seminiferous tubules and germinal cell thickness in testis tissue of all groups

Parameters	Control (n = 6)	CsA (n = 6)	Lycopene (n = 6)	CsA + lycopene (n = 6)
MDA (nmol/ml)	16.41 ± 0.22 a	22.99 ± 1.01 b	14.88 ± 0.17 a	18.17 ± 1.13 a
GSH (nmol/ml)	3.46 ± 0.20 a	2.50 ± 0.13 b	3.92 ± 0.06 a	2.98 ± 0.03 ab
GSH-Px (IU/g protein)	60.13 ± 3.84 A	40.40 ± 1.22 B	63.34 ± 2.03 A	54.32 ± 2.37 A
CAT (ku/g protein)	83.34 ± 3.86 A	56.32 ± 3.22 B	85.11 ± 3.72 A	74.72 ± 4.58 A
Diameter of ST (μm)	211.06 ± 1.88*	186.87 ± 2.52 [#]	221.36 ± 2.07*	211.34 ± 2.27*
Germinal cell thickness (μm)	54.11 ± 0.80*	47.87 ± 0.62 [#]	55.54 ± 0.62*	52.35 ± 0.68*

Data are expressed as mean ± S.E.M. The mean differences between values bearing different lower case (a and b, $P < 0.01$), upper case (A and B, $P < 0.05$) and icon (* and #, $P < 0.001$) within the same row are statistically significant.

3.4. Histopathological findings

While CsA treatment caused significant decreases in the diameter of ST and germinal cell thickness of the testis compared to the control group, CsA plus lycopene treatment provided a marked ($P < 0.001$) amelioration in these parameters (Table 3). When the structure of testis was histopathologically examined; degeneration, necrosis and interstitial oedema were detected in testis of CsA-treated group when compared to the control group. Desquamative germinal cells and the deceleration of spermatogenesis were seen in the lumen of certain ST of CsA-treated rats (Fig. 3). The adminis-

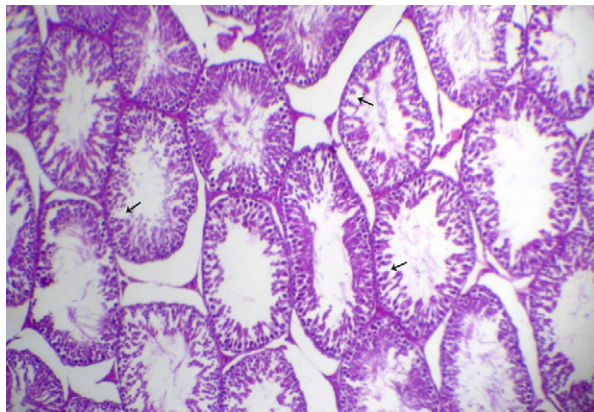


Fig. 3. The effect of cyclosporine A on testis tissue of rat. Seminiferous tubules show degeneration, necrosis and interstitial oedema (H&E, 20×).

tration of lycopene to CsA-treated rats improved nearly all the CsA-induced damages in the structure of testis (Fig. 4).

4. Discussion

CsA-induced toxicities in different organs such as kidney [4], vein [7] liver [9], ovary [10] and testis [13–15] in transplanted and/or non-transplanted humans and animals have been investigated in detail and well documented. It has been reported that the CsA administration causes a dose-dependent decline (20 mg/kg or higher) in the reproductive organ weights

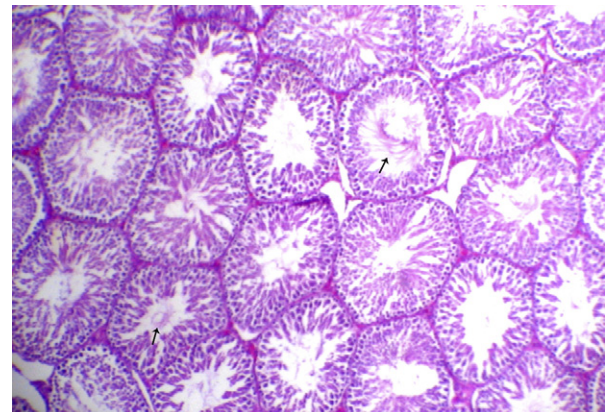


Fig. 4. The effect of lycopene on testis tissue of rat treated with cyclosporine A. Seminiferous tubules show nearly normal structure (H&E, 20×).

of non-transplanted male rats [13–15]. CsA has no significant negative effects on reproductive organ weights except seminal vesicles in this study. The secretory activity of accessory glands is dependent on testosterone produced by the interstitial cells. *In vivo* and/or *in vitro* CsA administrations lead to decrease in level of testosterone [32,33]. The reduction in seminal vesicles weights observed in the study may be explained that the secretion of this organ likely decreased because testosterone levels were diminished by CsA. However, there are no differences between CsA group and control group regarding to reproductive organ weights. The situation may be explained by the low dose of CsA.

CsA directly leads to reduced haploid cell population, pachytene spermatocytes, and desquamation of round spermatids and numerous residual bodies [11,12]. In the present study, CsA administration caused the significant decreases in diameter of ST and germinal cell thickness. Additionally, degeneration, necrosis, interstitial oedema, desquamative germinal cells and the deceleration of spermatogenesis were also seen in the lumen of certain ST of CsA-treated rats. These findings are in agreement with our earlier studies at which similar changes were observed in the histological structure of testis associated with oxidative stress after treatment of some cytotoxic agent [20,21]. In this study, the damages observed in the histological structure of testis may be explained by the direct effect of CsA inducing impaired maturation or release of spermatozoa or by indirect effect of CsA. CsA indirectly induces lipid peroxidation that is a chemical mechanism capable of disrupting the structure and function of testis.

Earlier studies indicate that the alterations in hypothalamic–pituitary–gonadal axis [13–15], and/or reduction in Sertoli cell phagocytic function [12] caused by CsA administration is probably responsible for the pathogenesis of testicular and spermatozoal toxicity. Although CsA-induced nephrotoxicity and hepatotoxicity are related with oxidative stress, there is no evidence concerning the relationship between cellular/biochemical mechanisms of gonadal damage and oxidative stress. Reactive oxygen species (ROS) are normally synthesized in several essential metabolic processes for living cells including the spermatozoa. ROS are highly reactive and can react with many intracellular molecules, mainly unsaturated fatty acids [34]. Spermatozoa are especially susceptible to peroxidative damage because of high concentration of polyunsaturated fatty acids which are involved in regulation of sperm maturation, spermatogenesis, capacitation, acrosome reaction and eventually in membrane fusion, and low antioxidant capacity. The

peroxidation of sperm lipids destroys the structure of lipid matrix in the membranes of spermatozoa, and it is associated with rapid loss of intracellular ATP leading to axonemal damage, decreased sperm viability and increased mid-piece morphological defects, and even it completely inhibits spermatogenesis in extreme cases [35]. In this study, it was observed that CsA treatment significantly decreased sperm concentration and motility, and increased abnormal sperm rate in comparison to the control group. These results are in agreement with previous studies at which was demonstrated that CsA caused spermatozoal damage [13–18]. Additionally, the CsA treatment caused a significant increase in testicular tissue MDA level compared to the control. The negative changes observed in sperm quality in the present study may be attributed to the peroxidation of polyunsaturated fatty acids in plasma membranes of spermatozoa or alterations of the intracellular redox state by CsA.

CsA treatment caused significant increase in MDA level, and decrease in GSH level, GSH-Px and CAT activities of testicular tissue compared to the control in the present study. The increments in MDA levels are probably due to the excessive generation of ROS by blocking the permeability transition pore, providing an increase in Ca^{2+} concentration, and changing electron transport chain of mitochondrial cells [36,37]. When ROS begin to accumulate, testes exhibit a defensive mechanism using various antioxidant enzymes. The main detoxifying systems for peroxides are CAT and GSH. CAT is an antioxidant enzyme, which destroys H_2O_2 that can form a highly reactive OH in presence of iron as a catalyst. By participating in the glutathione redox cycle, GSH together with GSH-Px convert H_2O_2 and lipid peroxides to non-toxic products [8,35,38,39]. Reduced activity of one or more antioxidant systems due to the direct toxic effect of CsA causes to increase of lipid peroxidation and oxidative stress, and consequently testicular and spermatozoal toxicity.

Lycopene, the most effective antioxidant among the carotenoids is known as highly efficient scavengers of $^1\text{O}_2$ and other excited species. During $^1\text{O}_2$ quenching, energy is transferred from $^1\text{O}_2$ to the lycopene molecule, converting it to the energy-rich triplet state. Thus, lycopene may protect *in vivo* against oxidation of lipids, proteins, and DNA [40]. Lycopene administration to CsA-treated rats resulted in significant ameliorations in the weight of seminal vesicles, diameter of ST and germinal cell thickness in the present study. Additionally, lycopene improved nearly all the CsA-induced damages in the structure of testis, and the other deteriorated histopathological findings. This status may be explained with partially attenuation of CsA-induced

degeneration, atrophy in the diameter of ST and germinal cell thickness, and increment in fluids of accessory glands due to the decreased lipid peroxidation, and increased antioxidant enzyme activities caused by lycopene administration.

In the present study, it was observed that while treatment with lycopene significantly inhibited the increase in testes MDA level, it increased the reductions in GSH, GSH-Px and CAT activities of testicular tissue by CsA. The possible explanation for the protective effects of lycopene against the increase in CsA-induced lipid peroxidation is its ability to react with the free oxygen metabolites.

The significant decrease in epididymal sperm concentration, motility and increase in abnormal sperm rates was observed in CsA-treated group, but lycopene treatment to CsA administered rats was provided a marked normalization in these parameters in our study. A rational mechanism for potential antitoxic effects of carotenoids is its ability to scavenge free radicals that cause oxidative DNA damage.

In conclusion, this study clearly indicates that CsA-induced oxidative stress leads to the structural and functional damages in the testicular tissue and sperm quality of rats and, lycopene has a potential protective effect on these damages. Therefore, lycopene may be used combined with CsA to prevent CsA-induced injuries in sperm quality and oxidant/antioxidant balance.

References

- [1] Website of Department of The University of Texas Medical School at Houston. The Division of Immunology & Organ Transplantation. Immunosuppression. Available from http://surgery.uth.tmc.edu/organ_transplant/historyofimmunosuppression.html. Last modified April 2006.
- [2] Upton H. Origin of drugs in current use: the cyclosporin story. Available from http://www.world-of-fungi.org/Mostly_Medical/Harriet_Upton/Harriet_Upton.htm 2001.
- [3] Rezzani R. Exploring cyclosporine A-side effects and the protective role-played by antioxidants: the morphological and immunohistochemical studies. *Histol Histopathol* 2006;21:301–16.
- [4] Chung BH, Li C, Sun BK, Lim SW, Ahn KO, Yang JH, et al. Rosiglitazone protects against cyclosporine-induced pancreatic and renal injury in rats. *Am J Transplant* 2005;5:1856–67.
- [5] Atasoyu EM, Yildiz S, Cimsit M, Cermik H, Qyrdedi T, Evrenkaya TR, et al. Investigation of the effect of hyperbaric oxygen on experimental cyclosporine nephrotoxicity. *Basic Clin Pharmacol Toxicol* 2006;98:150–4.
- [6] Origlia N, Migliori M, Panichi V, Filippi C, Bertelli A, Carpi A, et al. Protective effect of L-propionylcarnitine in chronic cyclosporine-a induced nephrotoxicity. *Biomed Pharmacother* 2006;60:77–81.
- [7] Lexis LA, Fenning A, Brown L, Fassett RG, Coombes JS. Antioxidant supplementation enhances erythrocyte antioxidant status and attenuates cyclosporine-induced vascular dysfunction. *Am J Transplant* 2006;6:41–9.
- [8] Hagar HH. The protective effect of taurine against cyclosporine A-induced oxidative stress and hepatotoxicity in rats. *Toxicol Lett* 2004;151:335–43.
- [9] Rezzani R, Buffoli B, Rodella L, Stacchiotti A, Bianchi R. Protective role of melatonin in cyclosporine A-induced oxidative stress in rat liver. *Int Immunopharmacol* 2005;5:1397–405.
- [10] Ergüder İB, Çetin R, Devrim E, Kılıçoğlu B, Avcı A, Durak İ. Effects of cyclosporine on oxidant/antioxidant status in rat ovary tissues: protective role of black grape extract. *Int Immunopharmacol* 2005;5:1311–5.
- [11] Sirinivas M, Agarwala S, Datta Gupta S, Das SN, Jha P, Misro MM, et al. Effect of cyclosporine on fertility in male rats. *Pediatr Surg Int* 1998;13:388–91.
- [12] Masuda H, Fujihira S, Ueno H, Kagawa M, Katsuoka Y, Mori H. Ultrastructural study on cytotoxic effects of cyclosporine A in spermiogenesis in rats. *Med Electron Microsc* 2003;36:183–91.
- [13] Seethalakshmi L, Menon M, Malhotra RK, Diamond DA. Effect of cyclosporine A on male reproduction in rats. *J Urol* 1987;138:991–5.
- [14] Seethalakshmi L, Flores C, Diamond DA, Menon M. Reversal of the toxic effects of cyclosporine on male reproduction and kidney function of rats by simultaneous administration of hCG + FSH. *J Urol* 1990;144:1489–92.
- [15] Seethalakshmi L, Flores C, Khauli RB, Diamond DA, Menon M. Evaluation of the effect of experimental cyclosporine toxicity on male reproduction and renal function. Reversal by concomitant human chorionic gonadotropin administration. *Transplantation* 1990;49:17–9.
- [16] Iwasaki M, Fuse H, Katayama T. The effects of cyclosporin azathioprine and mizoribine on male reproduction in rats. *Nippon Hinyokika Gakkai Zasshi* 1996;87:42–9.
- [17] Misro MM, Chaki SP, Srinivas M, Chaube SK. Effect of cyclosporine on human sperm motility in vitro. *Arch Androl* 1999;43:215–20.
- [18] Xu LG, Xu HM, Zhang JR, Song QZ, Qi XP, Wang XH. Effects of different dosages of cyclosporine A on the semen parameters of renal transplant patients. *Zhonghua Nan Ke Xue* 2003;9:679–80. 683.
- [19] Cohen LA. A review of animal model studies of tomato carotenoids, lycopene, and cancer chemoprevention. *Exp Biol Med* 2002;227:864–8.
- [20] Ateşşahin A, Karahan İ, Türk G, Gür S, Yılmaz S, Çeribaşı AO. Protective role of lycopene on cisplatin-induced changes in sperm characteristics, testicular damage and oxidative stress in rats. *Reprod Toxicol* 2006;21:42–7.
- [21] Ateşşahin A, Türk G, Karahan İ, Yılmaz S, Çeribaşı AO, Bulmuş Ö. Lycopene prevents adriamycin-induced testicular toxicity in rats. *Fertil Steril* 2006;85(Suppl. 1):1216–22.
- [22] Kotolová H, Kollár P, Jarošová M. Carvedilol protects against cyclosporine nephropathy in rats. *Acta Vet Brno* 2006;75:85–9.
- [23] Jonker D, Kuper CF, Frail N, Estrella A, Rodrigues Otero C. Ninety-day oral toxicity study of lycopene from *Blakeslea trispora* in rats. *Regul Toxicol Pharmacol* 2003;37:396–406.
- [24] Velmurugan B, Santhiya ST, Nagini S. Protective effect of S-allylcysteine and lycopene in combination against N-methyl-N'-nitro-N-nitrosoguanidine-induced genotoxicity. *Pol J Pharmacol* 2004;56:241–5.
- [25] Yokoi K, Uthus EO, Nielsen FH. Nickel deficiency diminishes sperm quantity and movement in rats. *Biol Trace Elem Res* 2003;93:141–53.

- [26] Sönmez M, Türk G, Yüce A. The effect of ascorbic acid supplementation on sperm quality, lipid peroxidation and testosterone levels of male Wistar rats. *Theriogenology* 2005;63:2063–72.
- [27] Placer ZA, Cushman LL, Johnson BC. Estimation of product of lipid peroxidation (malonyl dialdehyde) in biochemical systems. *Anal Biochem* 1966;16:359–64.
- [28] Sedlak J, Lindsay RH. Estimation of total, protein-bound and nonprotein sulfhydryl groups in tissue with Ellman's reagent. *Anal Biochem* 1968;25:192–205.
- [29] Lawrence RA, Burk RF. Glutathione peroxidase activity in selenium-deficient rat liver. *Biochem Biophys Res Commun* 1976;71:952–8.
- [30] Lowry OH, Rosebrough NJ, Farr AL, Randall RJ. Protein measurement with folin phenol reagent. *J Biol Chem* 1951;193:265–75.
- [31] Catalase AH. In: Bergmeyer HU, editor. *Methods in enzymatic analysis*. New York: Academic Press; 1983. p. 276–86.
- [32] Sikka SC, Bhasin S, Coy DC, Koyle MA, Swerdloff RS, Rajfer J. Effects of cyclosporine on the hypothalamic-pituitary-gonadal axis in the male rat: mechanism of action. *Endocrinology* 1988;123:1069–74.
- [33] Sikka SC, Coy DC, Lemmi CA, Rajfer J. Effect of cyclosporine on steroidogenesis in rat Leydig cells. *Transplantation* 1988;46:886–90.
- [34] Parra Cid T, Coneja García JR, Carballo Álvarez F, de Arriba G. Antioxidant nutrients protect against cyclosporine A nephrotoxicity. *Toxicology* 2003;189:99–111.
- [35] Sanocka D, Kurpisz M. Reactive oxygen species and sperm cells. *Reprod Biol Endocrinol* 2004;2(12):1–7.
- [36] Fournier N, Ducet G, Crevat A. Action of cyclosporine on mitochondrial calcium fluxes. *J Bioenerg Biomembr* 1987;19:297–303.
- [37] Nicolli A, Basso E, Petronilli V, Wenger RM, Bernard P. Interactions of cyclophilin with the mitochondrial inner membrane and regulation of the permeability transition pore, cyclosporine A-sensitive channel. *J Biol Chem* 1996;271:2185–92.
- [38] Sharma RK, Agarwal A. Role of reactive oxygen species in male infertility. *Urology* 1996;48:835–50.
- [39] Sikka SC. Oxidative stress and role of antioxidants in normal and abnormal sperm function. *Front Biosci* 1996;1:78–86.
- [40] Stahl W, Sies H. Antioxidant activity of carotenoids. *Mol Aspects Med* 2003;24:345–51.