



<http://dx.doi.org/10.1016/j.ultrasmedbio.2014.03.028>

● Original Contribution

ELASTOGRAPHY CAN EFFECTIVELY DECREASE THE NUMBER OF FINE-NEEDLE ASPIRATION BIOPSIES IN PATIENTS WITH CALCIFIED THYROID NODULES

MIN-HEE KIM,* SI LUO,[†] SUN HEE KO,* SO-LYUNG JUNG,[‡] DONG-JUN LIM,* and YONGMIN KIM^{§||}

*Division of Endocrinology and Metabolism, Department of Internal Medicine, Catholic University of Korea, Seoul, Korea;

[†]Department of Electrical Engineering, University of Washington, Seattle, Washington, USA; [‡]Department of Radiology, Catholic University of Korea, Seoul, Korea; [§]Department of Bioengineering, University of Washington, Seattle, Washington, USA; and ^{||}Department of Creative IT Engineering, Pohang University of Science and Technology Pohang, Pohang, Korea

(Received 30 November 2013; revised 12 March 2014; in final form 26 March 2014)

Abstract—When calcification, frequently found in both benign and malignant nodules, is present in thyroid nodules, non-invasive differentiation with ultrasound becomes challenging. The goal of this study was to evaluate the utility of elastography in differentiating calcified thyroid nodules. Consecutive patients (165 patients with 196 nodules) referred for fine-needle aspiration who had undergone both ultrasound elastography and B-mode examinations were analyzed retrospectively. Calcification was present in 45 benign and 20 malignant nodules. On 65 calcified nodules, elastography had 95% sensitivity, 51.1% specificity, 46.3% positive predictive value and 95.8% negative predictive value in detecting malignancy. Twenty-three of 45 benign calcified nodules were correctly diagnosed with elastography compared with 4 of 45 by B-mode ultrasound. Although it is difficult to differentiate benign and malignant calcified thyroid nodules solely with B-mode ultrasound, elastography has the potential to reduce the number of fine-needle aspiration biopsies performed on calcified nodules. (E-mail: ldj6026@catholic.ac.kr) © 2014 World Federation for Ultrasound in Medicine & Biology.

Open access under [CC BY-NC-ND license](http://creativecommons.org/licenses/by-nc-nd/4.0/).

Key Words: Thyroid nodule, Elastography, Calcification, Fine-needle aspiration.

INTRODUCTION

Calcification is a key ultrasound (US) feature suggesting malignancy of thyroid nodules (Kim et al. 2002; Moon et al. 2008; Papini et al. 2002). Current major guidelines (Cooper et al. 2009; Gharib et al. 2010; Moon et al. 2011) strongly recommended that a calcified nodule larger than 5 mm be biopsied. Calcification is frequently detected in thyroid nodules: 19.8%–41.3% of thyroid nodules have calcification (Kakkos et al. 2000; Khoo et al. 2002; Moon et al. 2008; Seiberling et al. 2004; Wang et al. 2006; Watters et al. 1992). Also, calcification can occur in both benign (17%–38.7%) and malignant (26.1%–78.8%) nodules, although it is more frequently seen in malignant nodules (Kakkos et al. 2000; Khoo et al. 2002; Moon et al. 2008; Seiberling

et al. 2004; Wang et al. 2006; Watters et al. 1992). Because it is difficult to differentiate benign and malignant nodules with calcification on B-mode US (Kim et al. 2013; Lu et al. 2011) and many thyroid nodules have calcification, a large number of benign calcified nodules are subjected to fine-needle aspiration (FNA) biopsy. To reduce the number of FNA biopsies of benign calcified nodules, a tool with a high negative predictive value for malignancy is desired.

Numerous studies have reported that US elastography has high sensitivity and specificity in detecting malignant thyroid nodules (Asteria et al. 2008; Friedrich-Rust et al. 2010; Hong et al. 2009; Lyshchik et al. 2005; Rago et al. 2007; Rubaltelli et al. 2009). However, elastography is not widely used in clinical practice to manage thyroid nodules. A major reason is the lack of inter-observer agreement resulting from the variability in elastography data acquisition and scoring (Gharib et al. 2010; Unlütürk et al. 2012). Compared with elastography using external compression, described in many previous studies, intrinsic compression elastography, in which carotid artery pulsation is the internal compression source, has had significant

Address correspondence to: Dong-Jun Lim, Division of Endocrinology and Metabolism, Department of Internal Medicine, Seoul St. Mary's Hospital, College of Medicine, Catholic University of Korea, 505 Banpo-Dong, Seocho-Gu, Seoul 137-701, Korea. E-mail: ldj6026@catholic.ac.kr

Conflicts of Interest: The authors have indicated that they have no conflicts of interest regarding the content of this article.

inter-observer and intra-observer agreement (Lim et al. 2012). However, whether intrinsic compression elastography can effectively differentiate calcified benign and malignant nodules has not been studied.

The aim of this study was to evaluate the role elastography could play in managing thyroid nodules with calcification.

METHODS

Patients

One hundred eighty-eight patients (229 nodules) referred to our institution (Seoul St. Mary's Hospital, The Catholic University of Korea) by primary care physicians for a FNA biopsy from May 2011 to January 2012 were recruited for the study. After undergoing US and elastography examinations, all patients underwent FNA biopsy with laboratory tests regardless of the results of elastography. Though repeated FNA biopsies were performed on nodules with atypical cells of undetermined significance or unsatisfactory results, 18 nodules were excluded from the study because of inconclusive cytology ($n = 9$) or unsatisfactory ($n = 9$) results during the study period. Additionally, 9 cystic ($>90\%$ of content) and 6 dominant cystic ($>50\%$ of content) nodules, which were classified based on recommendations (Moon et al. 2011), were also excluded. For patients with multiple nodules, only the nodule(s) that underwent FNA biopsy was included in the study. In total, 196 nodules from 165 patients were included in this study, 62 from 31 patients with multiple nodules and 134 from patients with single nodules. Among them, 34 patients (20.6%) had undergone surgery in our institution, and their histopathology results were used as the final diagnosis of those nodules.

This study was approved by the institutional review board of our institution, and all patients signed the informed consent.

B-Mode ultrasound imaging

B-Mode US images of thyroid nodules were acquired using a commercial US machine (iU22, Philips Medical Systems, Bothell, WA) with a 5- to 12-MHz high-resolution linear probe. Retrospectively, a radiologist (with 15 y experience) who was blind to the cytologic and elastography results and the patient's clinical information examined the B-mode US images. Several B-mode US features (echogenicity, margin, shape and presence of calcification) were extracted. Echogenicity was described as hyper-, iso-, hypo- or marked hypo-echogenicity compared with the echogenicity of thyroid parenchyma and strap muscle. Margins were described as well-defined smooth, spiculated or ill-defined. Shape was described as ovoid to round, irregular or taller than wide, whereas calcification was categorized as micro-

calcification, macro-calcification, rim calcification or no calcification (Moon et al. 2008; Park et al. 2010). The maximum diameter of three dimensions was used for the analysis.

All thyroid nodules were classified into three groups based on their B-mode US features: benign (group 1), indeterminate (group 2) and suspicious for malignancy (group 3). Nodules with one or more suspicious US features indicative of malignancy (*e.g.*, marked hypo-echogenicity, ill-defined or spiculated margin, micro-calcification, taller-than-wide shape) were classified as suspicious for malignancy (group 3). Nodules were classified as benign (group 1) if there were no suspicious US features. Nodules that could not be clearly classified as either group 1 or group 3, because of the presence of ambiguous US features, were classified as indeterminate (group 2) (Moon et al. 2011; Park et al. 2010).

Real-time US elastography examination

Elastography examinations were performed by three endocrinologists with more than 1 y of experience with intrinsic compression elastography, using a commercial US machine (Accuvix XG, Samsung Medison, Seoul, Korea) with a L5-13 linear transducer. To perform an elastography examination, the operator searched for a transverse plane showing the common carotid artery; the patient was then asked to hold his or her breath while the US data were acquired (~ 4 s). No external compression was applied during data acquisition as carotid artery pulsation was used as an intrinsic compression source. A quantitative scoring method (*i.e.*, elasticity contrast index [ECI]) described in our previous study (Luo et al. 2012) was used. The ECI value was computed interactively and displayed on the monitor of the US machine after the nodule's boundaries were delineated by the operator (Lim et al. 2012; Luo et al. 2012).

For each nodule, a minimum of two elastography measurements were made at the imaging plane on which the largest diameter of the thyroid nodule was visible in the transverse view. Additional measurements were made on imaging planes exhibiting US characteristics (*e.g.*, echogenicity and presence of calcification) different from those visible on the plane with the largest diameter. A larger ECI value suggests a stiffer nodule, indicating an increased likelihood of malignancy. In the presence of multiple ECI values, the largest ECI value was used for analysis.

Statistical data analysis

Levene's test for normality was used to test the distribution of continuous variables. Normally distributed and non-normally distributed variables are expressed as the mean (standard deviation) and median (range) for descriptive statistics, respectively. Nominal variables

were compared with the χ^2 test or Fisher's exact test. The independent *t*-test and Mann–Whitney *U*-test for unpaired values were used for comparison of normally distributed and non-normally distributed continuous variables, respectively.

To assess the diagnostic accuracy of US elastography, we varied the ECI cutoff value and determined the sensitivity and specificity combination that resulted in the maximum geometric mean (*i.e.*, [sensitivity \times specificity]^{1/2}) in detecting malignant nodules. The positive predictive value (PPV) and negative predictive value (NPV) of elastography in the detection of malignant nodule were also calculated.

All statistical analysis was performed using SPSS 12.0 (IBM, Chicago, IL, USA). A *p*-value < 0.05 was considered to indicate statistical significance.

RESULTS

Baseline characteristics of patients and nodules

There were 154 benign and 42 malignant nodules from 165 patients (138 women, 27 men). All malignant nodules were diagnosed as papillary thyroid carcinomas. The median age of patients with malignant nodules (46 [range: 24–72]) did not significantly differ (*p* = 0.193) from that of patients with benign nodules (52 [23–78]). There was no difference in gender between patients with benign nodules and those with malignant nodules (*p* = 0.164).

The mean size of nodules was 11.09 \pm 5.83 mm. Malignant nodules (9.10 \pm 4.17 mm) were significantly (*p* = 0.012) smaller than benign nodules (11.31 \pm 6.10 mm). There were 184 solid nodules and 12 dominant solid nodules (solid in more than 50%). In 65 nodules (33.2%) calcification was present as assessed by the radiologist. Table 1 lists the numbers of nodules with each suspicious B-mode US feature. All nodules were categorized into three groups (benign, indeterminate and malignant) on the basis of B-mode US features and two groups (benign and malignant) on the basis of ECI values (Table 2).

Diagnostic performance of elastography

The mean ECI value of malignant nodules (4.51 \pm 2.22) was significantly (*p* < 0.001) larger than that of benign nodules (2.98 \pm 1.47). The sensitivity, specificity, PPV and NPV of elastography were 81.0%, 63.6%, 37.8% and 92.5% at an ECI cutoff value of 3.11. For nodules <1 cm (*n* = 91, 65 benign and 26 malignant), the sensitivity, specificity, PPV and NPV were 73.1%, 56.9%, 34.9% and 84.1% with elastography, respectively. Higher diagnostic performance (sensitivity = 93.8%, specificity = 68.5%, PPV = 34.9%, NPV = 98.4%) was achieved with nodules \geq 1 cm (*n* = 105, 89 benign

Table 1. Baseline characteristics of the nodules (N = 196)

Size (mm)	11.09 \pm 5.83
Malignancy	42 (21.4%)
B-mode features	
Taller-than-wide shape	38 (19.4%)
Spiculated margin	75 (38.3%)
Hypo-echogenicity	117 (59.7%)
Calcification	65 (33.2%)
Micro-calcification	26
Macro-calcification	7
Rim calcification	17
Mixed calcification	15

and 16 malignant) than with nodules <1 cm. There were 8 false negatives (7 from non-calcified nodules, 1 from calcified nodules) and 56 false positives (34 from non-calcified nodules and 22 from calcified nodules) with elastography.

Utility of elastography on calcified thyroid nodules

Among the nodules with calcification (*n* = 65, 45 benign and 20 malignant), only 4 nodules were classified as benign by the radiologist, and 3 of the 4 nodules were found to be benign by elastography. On the basis of B-mode ultrasound, 61 nodules were classified as either indeterminate (*n* = 29) or suspicious for malignancy (*n* = 32) by radiologist. As illustrated in Figure 1, elastography of 32 calcified nodules classified as suspicious for malignancy by the radiologist revealed 9 nodules as benign, all of which were confirmed as benign by FNA biopsy. Among 29 indeterminate nodules, elastography classified 12 nodules as benign, and 11 of the 12 were confirmed as benign by FNA biopsy. One malignant nodule with rim calcification was incorrectly classified by elastography as benign. Four nodules classified as benign by B-mode US were confirmed as benign by FNA biopsy. The sensitivity, specificity, PPV and NPV of elastography in 65 nodules with calcification were 95%, 51.1%, 46.3% and 95.8%, respectively. Twenty-three benign calcified nodules (51.1% of benign calcified nodules) were correctly classified by elastography, whereas only 4 (8.9%) were correctly classified by B-mode US. Figure 2 are images of two malignant-looking calcified nodules correctly classified by elastography.

DISCUSSION

In this study, elastography was found to have a possible role in the management of calcified thyroid nodules. On the basis of B-mode US only, 61 nodules with calcification were considered indeterminate or suspicious for malignancy (Fig. 1). Among the 61 modules, 41 turned out to be benign by FNA biopsy. When the 41 nodules false positive by B-mode US alone were examined

Table 2. Nodule classification with B-mode ultrasound and elastography

Fine-needle aspiration biopsy result	B-mode ultrasound			Elastography	
	Benign (n = 43)	Indeterminate (n = 86)	Malignant (n = 67)	Benign (n = 106)	Malignant (n = 90)
Benign (n = 154)	43	79	32	98	56
Malignant (n = 42)	0	7	35	8	34

by elastography, 20 were correctly re-classified as benign with a high negative predictive value (95.8%). Of 4 benign nodules correctly classified with B-mode US, 1 was mis-classified as malignant by elastography. Thus, with the use of elastography on those calcified nodules, for which B-mode US has low specificity (*i.e.*, 8.9%) in detecting malignancy, FNA biopsy could have been avoided in 23 (35.4%) of 65 calcified nodules. In terms of reducing the number of FNA biopsies, our study found that elastography had a clinical impact similar to that reported in a previous study that evaluated the usefulness of elastography in calcified breast lesions (Cho et al. 2009).

In the new management scheme illustrated in Figure 3, a clinician could rely on elastography findings in deciding which nodules with calcification should be referred for FNA biopsy. First, the clinician determines whether a thyroid nodule is calcified or not. It is well known that the presence of calcification has good inter-observer agreement (Choi et al. 2010; Kim et al. 2012; Park et al. 2010). Even among non-expert readers, good inter-observer agreement was obtained (Kim et al. 2012). Thus, clinicians would have little difficulty in identifying calcified nodules by B-mode US imaging and using elastography in those nodules. If a calcified nodule has an elastography finding indicative of malignancy, the clinician should refer the patient for FNA biopsy. On the other hand, if US elastography suggests

benignity, even a nodule with calcification could be followed up instead of being aspirated. As the presence of calcification has been known to have a relatively lower positive predictive value than other features, resulting in a substantial number of false positives (Moon et al. 2008), the addition of elastography with high negative predictive value would be appropriate to reduce the number of FNA biopsies of benign calcified nodules.

Calcification has been known to influence the stiffness value of thyroid nodules and has resulted in false positives in previous elastography studies (Asteria et al. 2008; Bojunga et al. 2010; Hong et al. 2009; Rago et al. 2007). We also found that calcification could lead to false positives. In analyzing individual benign nodules, we found that calcification occurred more frequently in false positives than true negatives (22/55 [40%] vs. 23/99 [23.2%], $p = 0.023$). Furthermore, the amount of calcification (no, micro- and macro-calcification) was significantly correlated with ECI value (correlation coefficient = 0.211, $p = 0.003$), suggesting that a calcified nodule would generally have a larger ECI value than a nodule without calcification. Among malignant nodules, the incidence of calcification was significantly higher in true-positive cases than false-negative cases (19/34 [55.9%] vs. 1/8 [12.5%], $p = 0.047$). Therefore, if a calcified nodule has a relatively low ECI value, its chance of being malignant would

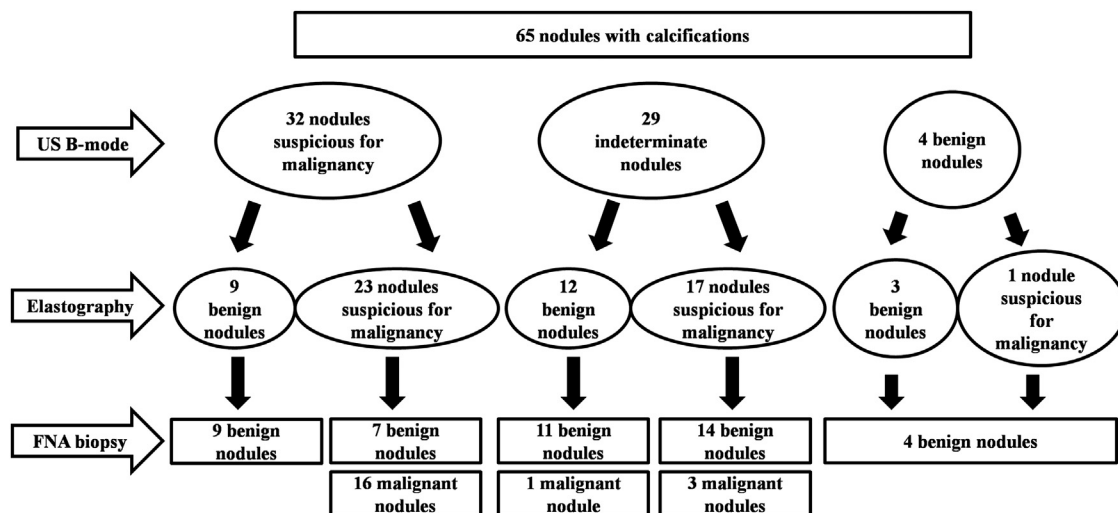


Fig. 1. Classification of 65 calcified nodules with B-mode ultrasound and elastography. US = ultrasound, FNA = fine-needle aspiration.

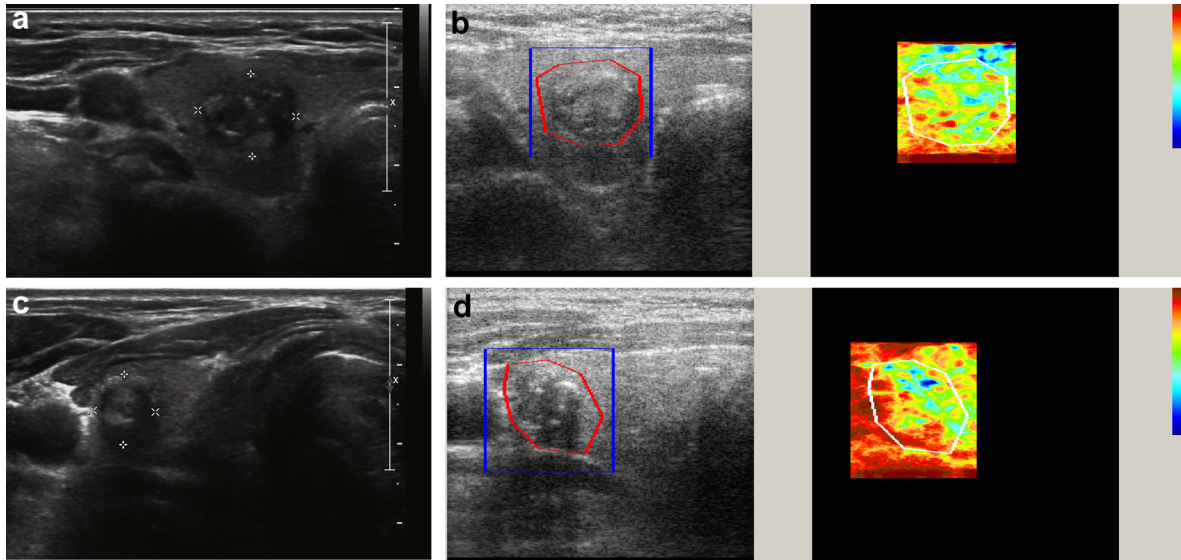


Fig. 2. Representative cases of calcified nodules that were categorized as benign and malignant by elastography. (a, b) A 68-y-old woman presented with a 1.4-cm nodule on the right side of the thyroid. (a) B-Mode ultrasound revealed a hypo-echoic, spiculated, ovoid to round nodule with both micro- and macro-calcification. (b) Elastography revealed an elasticity contrast index (ECI) of 2.34, which indicated benignity (left: B-mode ultrasound, right: elastography). This nodule was confirmed as benign by fine-needle aspiration biopsy. (c, d) A 57-y-old man presented with a 1.3-cm nodule on the right side of the thyroid. (c) B-Mode ultrasound revealed an iso- to hypo-echoic, ill-defined, taller-than-wide nodule with both micro- and macro-calcification. (d) Elastography revealed an ECI of 3.93, which indicated malignancy (left: B-mode ultrasound, right: elastography). Fine-needle aspiration biopsy revealed a papillary thyroid carcinoma.

decrease, which might explain the reason why the number of false-negative cases was small in the analysis of calcified nodules.

There are several possible reasons that benign nodules have low ECI values despite the presence of calcification. One is a difference in stiffness between the

Suggested algorithm

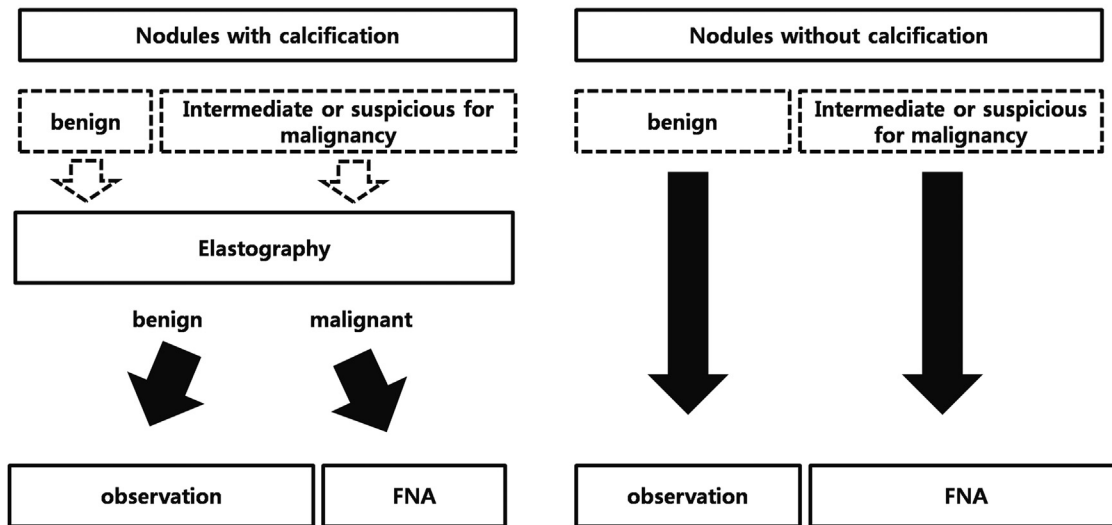


Fig. 3. How elastography could be used to manage thyroid nodules. When a nodule is detected by B-mode ultrasound, different management algorithms can be applied depending on the absence or presence of calcification. In nodules without calcification, B-mode ultrasound features could determine whether fine-needle aspiration is needed. A lack of any suspicious ultrasound features indicative of malignancy (*i.e.*, marked hypo-echogenicity, ill-defined or spiculated margin, micro-calcification and taller-than-wide shape) could define a benign nodule by B-mode ultrasound. In nodules with calcification, elastography has priority over B-mode ultrasound features. If the nodule is classified as benign by elastography, fine-needle aspiration can be avoided. FNA = fine-needle aspiration.

extracellular matrix of malignant nodules and that of benign nodules, as the extracellular matrix encircling cancer cells hardens from the beginning of cancer formation (Huang and Ingber 2005). Elastography could detect this difference in stiffness between calcified benign and malignant nodules. Additionally, the dense fibrosis or condensed colloid found on histopathology could mimic micro-calcification on B-mode US images (Khoo et al. 2002), and elastography discriminates these features from real calcification, which makes it able to detect benign calcified nodules more accurately.

There are several limitations to this study. First, the number of calcified nodules was relatively small, although they were derived from a total of 196 nodules in patients enrolled in a tertiary referral hospital. Further studies including a large number of calcified thyroid nodules are required to generalize the concept of our study. Second, inter-observer agreement was not evaluated in this study, even though it was assessed in our previous study (Lim et al. 2012). Although the false negativity of FNA cytology is known to be <3% (Cibas and Ali 2009), another limitation is that FNA biopsy was performed once on each benign nodule. Even though the radiologist was very experienced, the interpretation of B-mode US images by only one radiologist is another limitation. Lastly, as the cutoff value for the detection of malignant nodules was inferred from a relatively small population, validation of the value with a larger patient population is necessary.

CONCLUSIONS

Our study found that intrinsic compression elastography has a high negative predictive value (95.8%) in nodules with calcification. The use of elastography in 65 calcified nodules eliminated the need for FNA biopsy in 23 (35.4%) benign nodules. Intrinsic compression elastography can be used in conjunction with B-mode US to reduce the number of FNA biopsies of calcified thyroid nodules.

Acknowledgments—We did not receive any research funds for this study. A portion of these results was presented in abstract form at the 2013 Spring Meeting of Korean Thyroid Association.

REFERENCES

Asteria C, Giovanardi A, Pizzocaro A, Cozzaglio L, Morabito A, Somalvico F, Zoppo A. US-elastography in the differential diagnosis of benign and malignant thyroid nodules. *Thyroid* 2008;18:523–531.

Bojunga J, Herrmann E, Meyer G, Weber S, Zeuzem S, Friedrich-Rust M. Real-time elastography for the differentiation of benign and malignant thyroid nodules: A meta-analysis. *Thyroid* 2010;20:1145–1150.

Cho N, Moon WK, Park JS. Real-time US elastography in the differentiation of suspicious microcalcifications on mammography. *Eur Radiol* 2009;19:1621–1628.

Choi SH, Kim EK, Kwak JY, Kim MJ, Son EJ. Interobserver and intra-observer variations in ultrasound assessment of thyroid nodules. *Thyroid* 2010;20:167–172.

Cibas ES, Ali SZ. The Bethesda System for Reporting Thyroid Cytopathology. *Thyroid* 2009;19:1159–1165.

Cooper DS, Doherty GM, Haugen BR, Kloos RT, Lee SL, Mandel SJ, Mazzaferri EL, McIver B, Pacini F, Schlumberger M, Sherman SI, Steward DL, Tuttle RM. Revised American Thyroid Association management guidelines for patients with thyroid nodules and differentiated thyroid cancer. *Thyroid* 2009;19:1167–1214.

Friedrich-Rust M, Sperber A, Holzer K, Diener J, Grunwald F, Badenhop K, Weber S, Kriener S, Herrmann E, Bechstein WO, Zeuzem S, Bojunga J. Real-time elastography and contrast-enhanced ultrasound for the assessment of thyroid nodules. *Exp Clin Endocrinol Diabetes* 2010;118:602–609.

Gharib H, Papini E, Paschke R, Duick DS, Valcavi R, Hegedus L, Vitti P. American Association of Clinical Endocrinologists, Associazione Medici Endocrinologi, and European Thyroid Association Medical Guidelines for Clinical Practice for the Diagnosis and Management of Thyroid Nodules. *Endocr Pract* 2010;16(Suppl 1):1–43.

Hong Y, Liu X, Li Z, Zhang X, Chen M, Luo Z. Real-time ultrasound elastography in the differential diagnosis of benign and malignant thyroid nodules. *J Ultrasound Med* 2009;28:861–867.

Huang S, Ingber DE. Cell tension, matrix mechanics, and cancer development. *Cancer Cell* 2005;8:175–176.

Kakkos SK, Scopa CD, Chalmoukis AK, Karachalios DA, Spiliotis JD, Harkoftakis JG, Karavias DD, Androulakis JA, Vagenakis AG. Relative risk of cancer in sonographically detected thyroid nodules with calcifications. *J Clin Ultrasound* 2000;28:347–352.

Khoo ML, Asa SL, Witterick IJ, Freeman JL. Thyroid calcification and its association with thyroid carcinoma. *Head Neck* 2002;24:651–655.

Kim BK, Choi YS, Kwon HJ, Lee JS, Heo JJ, Han YJ, Park YH, Kim JH. Relationship between patterns of calcification in thyroid nodules and histopathologic findings. *Endocr J* 2013;60:155–160.

Kim EK, Park CS, Chung WY, Oh KK, Kim DI, Lee JT, Yoo HS. New sonographic criteria for recommending fine-needle aspiration biopsy of non-palpable solid nodules of the thyroid. *AJR Am J Roentgenol* 2002;178:687–691.

Kim HG, Kwak JY, Kim EK, Choi SH, Moon HJ. Man to man training: Can it help improve the diagnostic performances and inter-observer variabilities of thyroid ultrasonography in residents? *Eur J Radiol* 2012;81:e352–e356.

Lim DJ, Luo S, Kim MH, Ko SH, Kim Y. Interobserver agreement and intra-observer reproducibility in thyroid ultrasound elastography. *AJR Am J Roentgenol* 2012;198:896–901.

Lu Z, Mu Y, Zhu H, Luo Y, Kong Q, Dou J, Lu J. Clinical value of using ultrasound to assess calcification patterns in thyroid nodules. *World J Surg* 2011;35:122–127.

Luo S, Lim DJ, Kim Y. Objective ultrasound elastography scoring of thyroid nodules using spatiotemporal strain information. *Med Phys* 2012;39:1182–1189.

Lyshchik A, Higashi T, Asato R, Tanaka S, Ito J, Mai JJ, Pellot-Barakat C, Insana MF, Brill AB, Saga T, Hiraoka M, Togashi K. Thyroid gland tumor diagnosis at US elastography. *Radiology* 2005;237:202–211.

Moon WJ, Baek JH, Jung SL, Kim DW, Kim EK, Kim JY, Kwak JY, Lee JH, Lee YH, Na DG, Park JS, Park SW. Ultrasonography and the ultrasound-based management of thyroid nodules: Consensus statement and recommendations. *Korean J Radiol* 2011;12:1–14.

Moon WJ, Jung SL, Lee JH, Na DG, Baek JH, Lee YH, Kim J, Kim HS, Byun JS, Lee DH. Benign and malignant thyroid nodules: US differentiation—Multicenter retrospective study. *Radiology* 2008;247:762–770.

Papini E, Guglielmi R, Bianchini A, Crescenzi A, Taccogna S, Nardi F, Panunzi C, Rinaldi R, Toscano V, Pacella CM. Risk of malignancy in non-palpable thyroid nodules: Predictive value of ultrasound and color-Doppler features. *J Clin Endocrinol Metab* 2002;87:1941–1946.

Park CS, Kim SH, Jung SL, Kang BJ, Kim JY, Choi JJ, Sung MS, Yim HW, Jeong SH. Observer variability in the sonographic evaluation of thyroid nodules. *J Clin Ultrasound* 2010;38:287–293.

- Rago T, Santini F, Scutari M, Pinchera A, Vitti P. Elastography: New developments in ultrasound for predicting malignancy in thyroid nodules. *J Clin Endocrinol Metab* 2007;92:2917–2922.
- Rubaltelli L, Corradin S, Dorigo A, Stabilito M, Tregnaghi A, Borsato S, Stramare R. Differential diagnosis of benign and malignant thyroid nodules at elastosonography. *Ultraschall Med* 2009;30:175–179.
- Seiberling KA, Dutra JC, Grant T, Bajramovic S. Role of intrathyroidal calcifications detected on ultrasound as a marker of malignancy. *Laryngoscope* 2004;114:1753–1757.
- Unlütürk U, Erdoğan MF, Demir O, Güllü S, Başkal N. Ultrasound elastography is not superior to gray-scale ultrasound in predicting malignancy in thyroid nodules. *Thyroid* 2012;22:1031–1038.
- Wang N, Xu Y, Ge C, Guo R, Guo K. Association of sonographically detected calcification with thyroid carcinoma. *Head Neck* 2006;28:1077–1083.
- Watters DA, Ahuja AT, Evans RM, Chick W, King WW, Metreweli C, Li AK. Role of ultrasound in the management of thyroid nodules. *Am J Surg* 1992;164:654–657.