

Report

A Case of Ulcerative Colitis with Appendiceal Hemorrhage

Sayumi NAKAO, Michio ITABASHI, Yoshiko BAMBА,
Tomoichiro HIROSAWA, Shimpei OGAWA and Shingo KAMEOKA

Department of Surgery II, Tokyo Women's Medical University

(Accepted September 25, 2014)

A case of ulcerative colitis with appendiceal hemorrhage is presented. A 30-year old man was diagnosed with ulcerative colitis at age 16 years and treated with 5-aminosalicylic acid. He had been treated for aortitis syndrome from the age of 21 years with steroids and cyclosporine. At ages 28 and 29 years, he presented with massive amounts of melena, but the origin of the hemorrhages could not be identified. At age 30 years, he again presented with a massive amount of melena. The colonoscopy revealed clot emerging from the appendiceal orifice, and the definitive diagnosis for the appendiceal bleeding was clear. Laparoscopic appendectomy was performed to prevent recurrence of bleeding. The histopathological examination showed bleeding, infiltration of neutrophils, and crypt abscesses within the mucosal layer, which suggested the appendiceal lesion of ulcerative colitis. Appendiceal bleeding is thought to be a rare cause of lower gastrointestinal bleeding. The common causes are acute appendicitis, appendiceal diverticulum, angiodysplasia, and intussusception of the appendix; appendiceal bleeding with ulcerative colitis has been thought to be rare.

Key Words: ulcerative colitis, appendiceal hemorrhage

Introduction

Appendiceal hemorrhage is an extremely rare cause of lower gastrointestinal bleeding, the common causes of which are acute appendicitis, appendiceal diverticulum, angiodysplasia, and intussusception of the appendix. Hemorrhage from an appendiceal lesion of ulcerative colitis is rare. To the best of our knowledge, we present here the first reported case of ulcerative colitis with appendiceal hemorrhage.

Case Report

A 30-year old man was diagnosed with ulcerative colitis at age 16 years and treated with 5-aminosalicylic acid. At ages 28 and 29 years, he presented with massive amounts of melena resulting in unconsciousness and was admitted to our hospital's gastroenterology department. Despite thorough in-

vestigation, the origin of the hemorrhage was unable to be identified. He was treated with conservative measures and observed on an outpatient basis. At age 30 years, he again presented with a massive amount of melena and was admitted to the gastroenterology department. He had been treated for aortitis syndrome from the age of 21 years with steroid and cyclosporine. On admission, he was on anticoagulant therapy. His height was 173 cm, and his weight was 57 kg. His blood pressure was 101/66 mmHg, his heart rate was 88 beats/minute, and his temperature was 36.7°C on admission. The abdomen was soft and flat, and he had no abdominal pain. Rectal examination revealed blood. The leukocyte count was 7,860/mm³, hemoglobin was 7.5 g/dL, and the platelet count was 202,000/mm³. Electrolytes, biochemistry, and coagulation tests were

✉ : Michio ITABASHI Department of Surgery II, Tokyo Women's Medical University, 8-1 Kawada-chou, Shinjyuku-ku, Tokyo, 162-8666 Japan
E-mail: itabashi@surg2.twmu.ac.jp

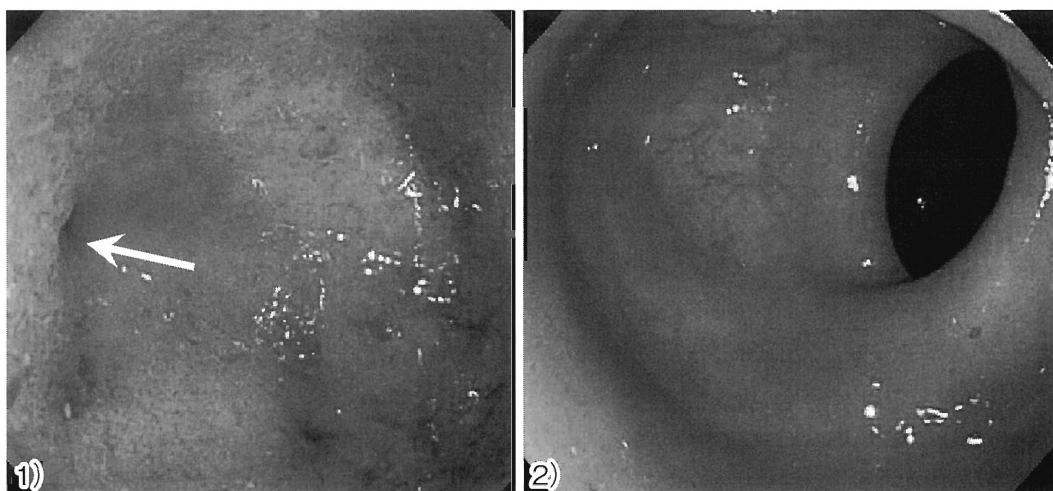


Fig. 1 Colonoscopic findings after the 2nd admission

- 1) The mucosa of the cecum is edematous but no bleeding is detected (→appendiceal orifice).
- 2) There are no inflammatory changes in the mucosa of the left-side colon.

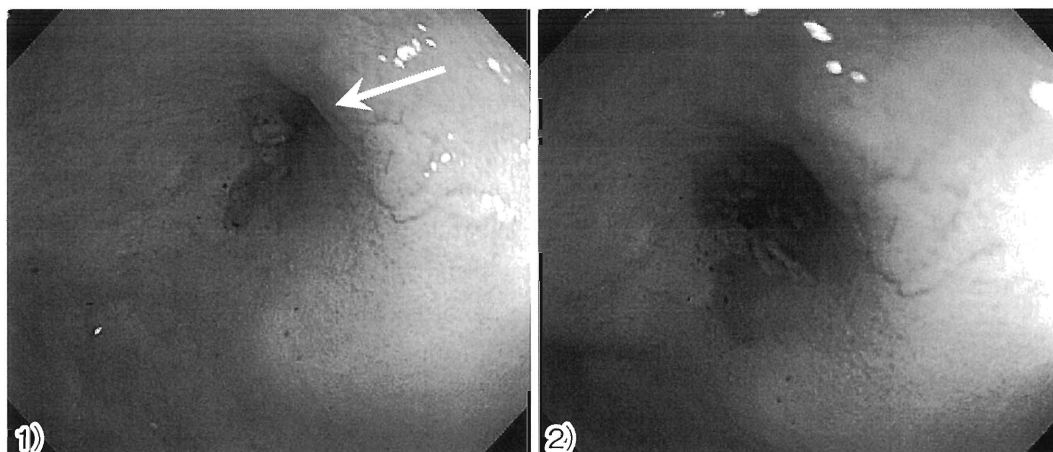


Fig. 2 Colonoscopic findings after the 3rd admission

- 1) Clot is observed from the appendiceal orifice (arrow).
- 2) Close-up view of the appendiceal orifice

within normal limits. A computed tomography scan of the abdomen detected no inflammatory changes, tumor, or diverticula. Capsule endoscopy detected fresh blood in the cecum and ascending colon, but the small intestine was intact. Therefore, colonoscopy was performed on the second day after admission. The previous colonoscopy showed redness and edema of the mucosa from the appendiceal orifice to the ascending colon, but failed to detect the exact site of bleeding (Fig. 1).

This time, the colonoscopy revealed a clot emerging from the appendiceal orifice, and the lesion responsible for bleeding was thought to be in the ap-

pendix (Fig. 2). No other site of bleeding was identified. There was also disappearance of the visible vascular pattern and contact bleeding from the cecum to the ascending colon; however, no lesions of ulcerative colitis from the transverse colon to the rectum were evident, suggesting that the activity of the ulcerative colitis was mild. He had no symptoms after admission. Oral intake was restarted on the fourth day after admission, and he was discharged on the 11th day after admission. He had experienced a massive amount of melena resulting in unconsciousness or anemia three times every year. Therefore, he came to our department for surgery

to prevent further refractory hemorrhage from the appendix. Six months later, he was admitted, and an elective laparoscopic appendectomy was performed. At surgery, the entire colon was observed, but there were no findings suggesting activity of ulcerative colitis, such as redness of the serosa. The appendix was totally edematous, but no inflammatory changes were found. The appendix was resected using an auto-suture instrument. The resected specimen showed edema of the entire appendix; there was no redness of the mucosa or ulceration (Fig. 3). The histopathological examination revealed congestion and bleeding in the mucosal layer, which confirmed bleeding from the lumen of

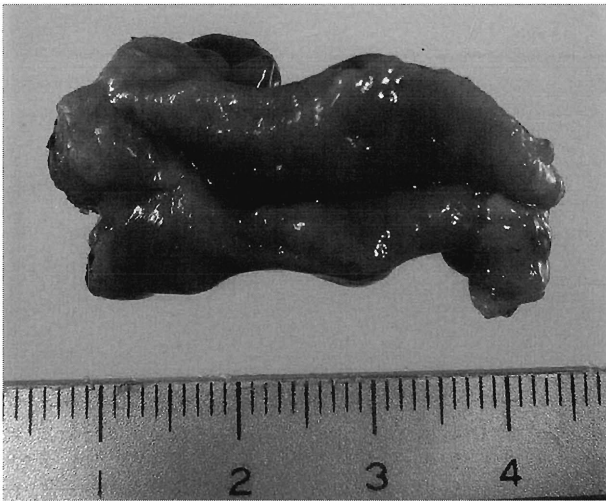


Fig. 3 The resected specimen of the appendix
The mucosa is edematous with no ulcer.

the appendix (Fig. 4-1). Infiltration of neutrophils, erosions, and crypt abscesses within the mucosal layer were also detected, which suggested the possibility of an ulcerative colitis lesion in the appendix (Fig. 4-2). The patient's postoperative course was uneventful, and he was discharged on the fifth postoperative day.

Discussion

Involvement of the appendix is relatively common in ulcerative colitis. Appendiceal lesions can be divided into two groups: continuous disease affecting the entire colon (pancolitis), and discontinuous (skip) lesions with appendiceal involvement with intact intermediate mucosa¹⁾.

Cohen et al²⁾ reported the skip lesion in the appendix as "ulcerative appendicitis" for the first time. There are many reports referring to the frequency of the appendiceal lesion. Funayama et al³⁾ reported that there was no relationship between the activity of the appendiceal lesion and the severity or the range of disease involvement. Hemorrhage from the appendiceal lesion is rare. Although a PubMed search using "ulcerative colitis", "appendix", and "bleeding" as key words produced no results, appendiceal bleeding could be a cause of lower gastrointestinal bleeding in patients with ulcerative colitis.

Appendiceal bleeding is thought to be a rare cause of lower gastrointestinal bleeding⁴⁾. The common causes are acute appendicitis, appendiceal diverticulum, angiodysplasia, and intussusception of

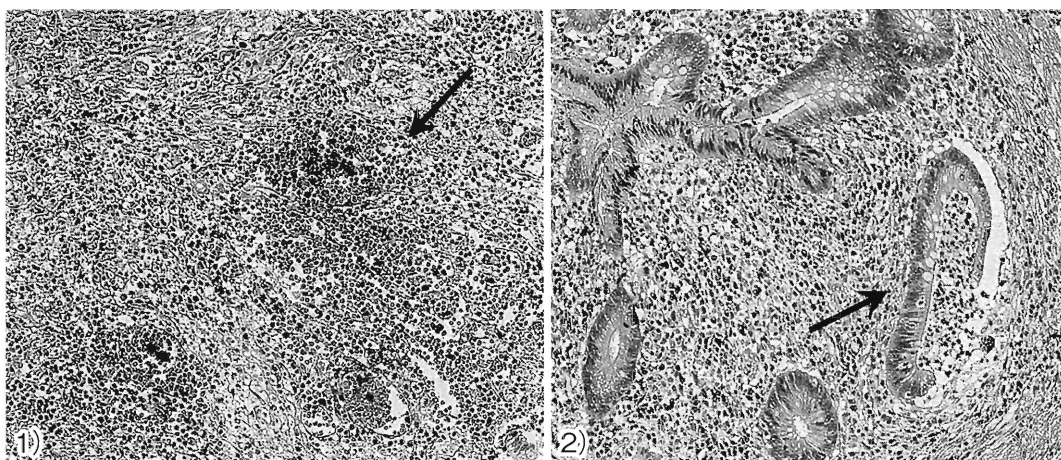


Fig. 4 Histopathological examination

- 1) Histopathological examination shows erythrocytes in the mucosal layer (arrow).
- 2) Infiltration of neutrophils and a crypt abscess (arrow) are seen.

the appendix⁴⁾⁵⁾.

To make the definitive diagnosis, observation of bleeding from the appendiceal orifice using colonoscopy is useful; however, it is difficult to detect the site of bleeding because the conditions for observation are poor in the acute phase, and bleeding may occur intermittently. Therefore, repeated colonoscopy is required for the definitive diagnosis of appendiceal bleeding⁶⁾. Although angiography and scintigraphy have been reported as useful, detecting the bleeding site is difficult unless massive bleeding continues for a certain period⁷⁾.

As treatment for appendiceal bleeding, surgery is recommended to prevent recurrence, even though there are some reports of endoscopic treatment or arterial embolization⁸⁾. This case was thought to be an appendiceal lesion of ulcerative colitis. Given that the clinical symptoms and endoscopic results for ulcerative colitis were in remission, we could have chosen to step up the treatment of the appendiceal lesion. However, the patient had aortitis syndrome and had been treated with steroids and an immunomodulating drug. Therefore, increasing the dosages of these drugs was not recommended. Infliximab or adalimumab were options for further stepping-up of therapy, but since the ulcerative colitis was in clinical remission, both were deemed unsuitable. Total colectomy is the standard operative procedure for ulcerative colitis, but in this case, the indication for surgery was control of the bleeding from the appendix, rather than to cure the ulcerative colitis completely. Therefore, because it is minimally invasive

and convenient, and the patient's bowel habit would be little affected postoperatively, laparoscopic appendectomy was chosen.

Conclusion

A rare case of ulcerative colitis with appendiceal hemorrhage while in apparent clinical remission was described.

The authors have no conflicts of interest to declare.

References

- 1) **Barclay RL, Depew WT, Taguchi KK et al:** Ulcerative colitis of the appendix ('ulcerative appendicitis') mimicking acute appendicitis. *Can J Gastroenterol* **15** (3): 201–204, 2001
- 2) **Cohen T, Pfeffer RB, Valensi Q:** "Ulcerative appendicitis" occurring as a skip lesion in chronic ulcerative colitis: report of a case. *Am J Gastroenterol* **62**: 151–155, 1974
- 3) **Funayama Y, Sasaki I, Masuda T et al:** Appendiceal involvement in ulcerative colitis-histopathological study using operative specimen. *Stomach and Intestine* **33** (9): 1213–1218, 1998
- 4) **Ogi M, Kawamura YJ, Konishi F et al:** Idiopathic hemorrhage from appendix. *Jichi Medical University Journal* **29**: 217–221, 2006
- 5) **Chung IH, Kim KH:** A case of successful colonoscopic treatment of acute appendiceal bleeding by endoclips. *J Korean Soc Coloproctol* **27** (6): 329–332, 2011
- 6) **Chung KS, Gao JP:** Massive lower gastrointestinal bleeding from the appendix. *Gut Liver* **5** (2): 234–237, 2011
- 7) **Shinozaki H, Takahashi O, Morita Y et al:** A case of bleeding from the appendix treated with appendectomy. *J Jpn Surg Assoc* **68** (9): 108–111, 2007
- 8) **Arai S, Oda K, Nunomura K et al:** A case report of appendicular angiodysplasia with lower gastrointestinal hemorrhage. *Jpn J Gastroenterol Surg* **45** (6): 657–663, 2012

潰瘍性大腸炎の経過中に虫垂出血を来した1例

東京女子医科大学医学部外科学（第2）講座

ナカオ	サユミ	イタバシ	ミチオ	バンバ	ヨシコ
中尾	紗由美	板橋	道朗	番場	嘉子
ヒロサワ	トモイテロウ	オガワ	シンペイ	カメオカ	シンゴ
廣澤	知一郎	小川	真平	亀岡	信悟

潰瘍性大腸炎の経過中に虫垂出血を来した1例を経験したので報告する。症例は30歳男性で16歳時に潰瘍性大腸炎と診断され5-アミノサリチル酸製剤の内服で緩解を維持していた。21歳時に大動脈炎症候群を合併し、ステロイドとシクロスポリンを使用していた。28歳と29歳時に大量下血を認めたが出血源は同定されなかった。30歳時に再度下血を認め、下部消化管内視鏡検査の結果、虫垂開口部から凝血塊を認め虫垂出血の診断に至った。大量下血を繰り返すため手術適応と判断し、腹腔鏡下虫垂切除術を施行した。病理組織結果では、虫垂粘膜の出血・好中球浸潤・陰窩膿瘍を認め、潰瘍性大腸炎の虫垂病変を示唆する所見であった。下部消化管出血の原因は多岐に渡るが、虫垂からの出血は稀である。虫垂出血の原因としては急性虫垂炎・憩室・血管異型性・腸重積等が報告されているが、潰瘍性大腸炎に伴う虫垂出血は極めて稀と考えられた。