



Available online at  
**ScienceDirect**  
[www.sciencedirect.com](http://www.sciencedirect.com)

Elsevier Masson France  
**EM|consulte**  
[www.em-consulte.com/en](http://www.em-consulte.com/en)



Original article

# A semi-automated quantitative CT method for measuring rotator cuff muscle degeneration in shoulders with primary osteoarthritis



A. Terrier<sup>a,\*</sup>, J. Ston<sup>a</sup>, A. Dewarrat<sup>a</sup>, F. Becce<sup>b,1</sup>, A. Farron<sup>c,1</sup>

<sup>a</sup> Laboratory of biomechanical orthopedics, école polytechnique fédérale de Lausanne, Station 19, 1015 Lausanne, Switzerland

<sup>b</sup> Department of diagnostic and interventional radiology, Lausanne university hospital, 46, rue du Bugnon, 1011 Lausanne, Switzerland

<sup>c</sup> Service of orthopedics and traumatology, Lausanne university hospital, 46, rue du Bugnon, 1011 Lausanne, Switzerland

## ARTICLE INFO

### Article history:

Received 8 July 2016

Accepted 5 December 2016

### Keywords:

Rotator cuff muscles  
 Atrophy  
 Fatty infiltration  
 Degeneration  
 Quantitative imaging  
 Shoulder osteoarthritis

## ABSTRACT

**Background:** Rotator cuff muscle degeneration is an important parameter to consider when planning shoulder arthroplasty.

**Hypothesis:** We hypothesized that rotator cuff muscle degeneration is correlated with scapulohumeral subluxation in patients planned for anatomical total shoulder arthroplasty (TSA).

**Materials and methods:** We developed a semi-automated quantitative CT method to measure rotator cuff muscle degeneration, and retrospectively analyzed 107 preoperative shoulder CT scans of patients with primary osteoarthritis. On a standardized sagittal-oblique CT slice perpendicular to the scapular axis, two observers measured the cross-sectional areas of residual rotator cuff muscle tissues, normalized by the estimated area of healthy muscles. Muscle degeneration was quantified in a semi-automated manner, and divided into atrophy and fatty infiltration. Scapulohumeral subluxation was determined in 3D as the distance between the humeral head center and the glenoid surface center, projected on the same CT slice, and normalized by the humeral head radius. We tested all potential correlations between muscle degeneration and scapulohumeral subluxation.

**Results:** Muscle degeneration, primarily due to atrophy, predominated in the supraspinatus; it varied from 0.8% to 88.8%. Scapulohumeral subluxation varied from 2.5% to 72.9%, and was mainly in a posterior and postero-superior orientation. There was a significant but weak correlation between the amount of subluxation and both supraspinatus ( $R=0.207$ ,  $P=0.032$ ) and infraspinatus ( $R=0.225$ ,  $P=0.020$ ) degeneration. Inter- and intra-observer reproducibility of muscle degeneration measurements were both excellent (ICCs range = 0.955–0.987 and 0.971–0.988, respectively).

**Conclusion:** This new semi-automated CT method allows to quantitatively and reproducibly measure rotator cuff muscle degeneration in shoulders with primary osteoarthritis. Muscle degeneration is weakly correlated with scapulohumeral subluxation in patients planned for anatomical TSA.

**Level of evidence:** Level IV.

**Type of study:** Diagnostic retrospective study.

© 2016 Elsevier Masson SAS. All rights reserved.

## 1. Introduction

Rotator cuff muscle degeneration and scapulohumeral subluxation are key elements to consider when planning anatomical total shoulder arthroplasty (TSA) for primary osteoarthritis (OA) with no rotator cuff tear [1,2]. Degenerative changes of rotator cuff muscles may induce a loss of joint stability and eventually asymmetric glenoid loading after anatomical TSA [3,4]. For the same reasons, preoperative scapulohumeral subluxation is

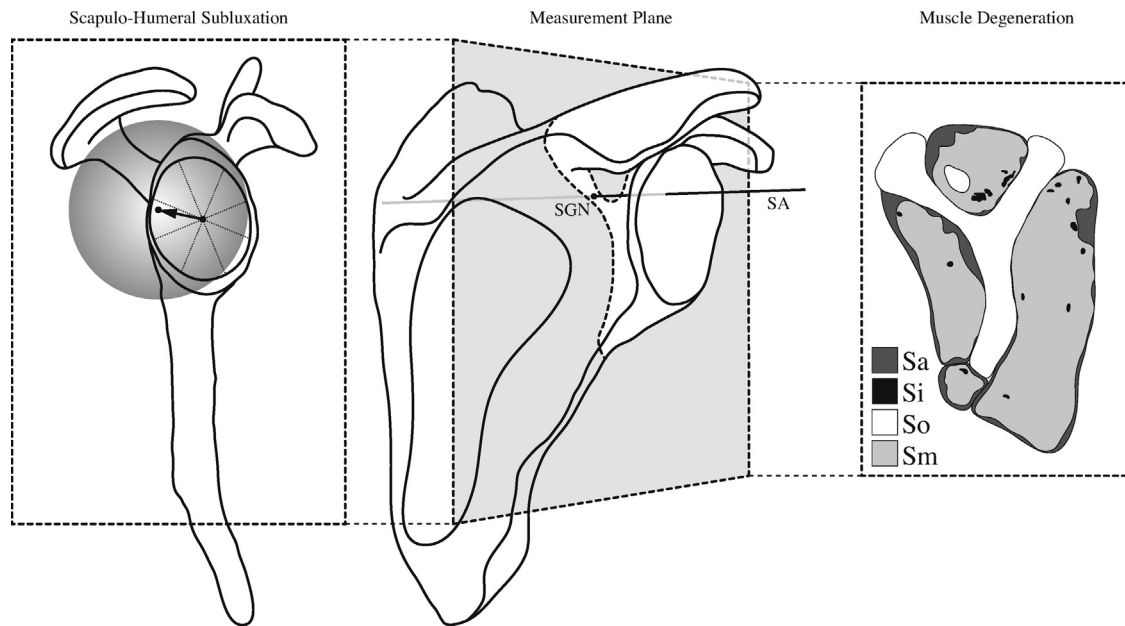
also a concern in anatomical TSA, and should thus be corrected, despite the risk of postoperative recurrence of static subluxation [2].

Rotator cuff muscle degeneration is generally evaluated using the well-recognized semi-quantitative Goutallier grading system for fatty infiltration and Thomazeau's occupational ratio for atrophy [5,6]. However, Goutallier's classification is known to be subjective, only moderately reproducible, and is by definition not accurate (Grade 2 corresponds to fatty infiltration ranging from approximately 10 to 49%) [7–9]. Static scapulohumeral subluxation is commonly measured in 2D, on an axial computed tomography (CT) slice crossing the glenoid fossa [10]. A quantitative measurement method in 3D has recently been described, providing both subluxation amplitude and orientation [11].

\* Corresponding author.

E-mail address: [alexandre.terrier@epfl.ch](mailto:alexandre.terrier@epfl.ch) (A. Terrier).

<sup>1</sup> F. Becce and A. Farron contributed equally to this work.



**Fig. 1.** The standardized sagittal-oblique measurement plane was determined from a 3D reconstruction of the scapula (middle). This plane was perpendicular to the scapular axis (SA) and coincident with the spinoglenoid notch (SGN). The sagittal-oblique CT slice was subsequently reconstructed in this exact plane from original CT data sets, producing the typical Y-shaped image (right). On this slice, we measured the surface of muscle atrophy (Sa), fatty infiltration (Si), and secondary bone formation (So), as well as the residual muscle surface (Sm), for each rotator cuff muscle. Scapulohumeral subluxation was measured as the distance between the glenoid surface center and the humeral head center, projected on the same measurement plane (left). Subluxation orientation was determined in height sectors.

Rotator cuff muscle degeneration and scapulohumeral subluxation have repeatedly been measured using different methods, but their association and causes are not yet fully understood. Therefore, the objective of this study was to test the hypothesis that degeneration of rotator cuff muscles is correlated with subluxation of the humeral head in patients planned for anatomical TSA. To answer this question, we developed a semi-automated quantitative CT method to measure rotator cuff muscle degeneration.

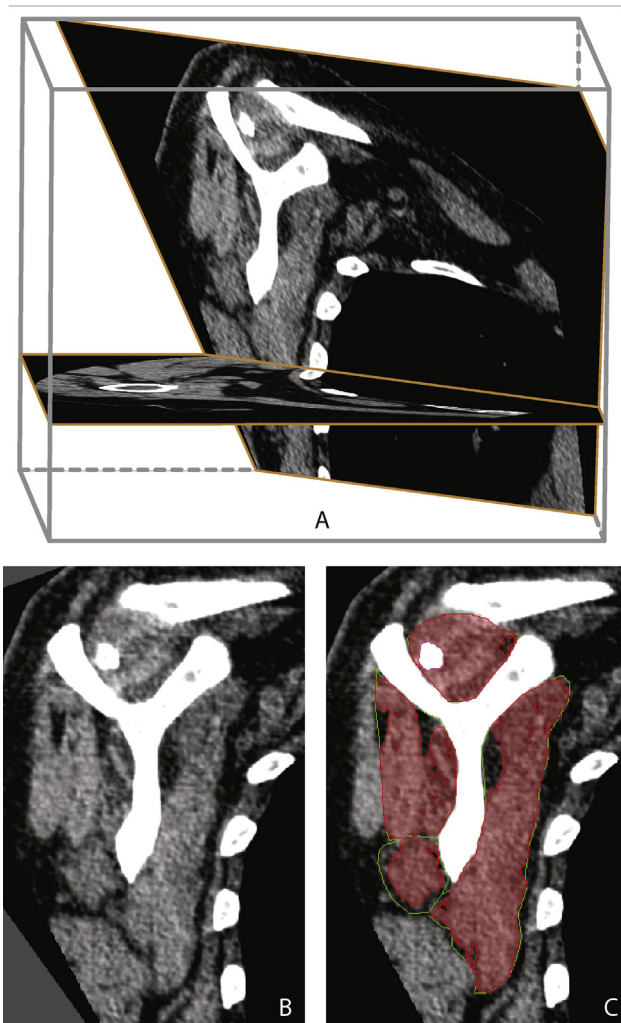
## 2. Materials and methods

We retrospectively reviewed 210 consecutive patients examined from 2002 to 2014 by shoulder CT scan as part of their planning for arthroplasty. Exclusion criteria were: any shoulder girdle fracture, malunion or nonunion, avascular necrosis of the humeral head, and rheumatoid arthritis. We thus considered 107 CT scans from 95 different patients (62 females and 33 males; mean age, 70.5 years, range 36–89) treated with anatomical TSA for primary OA. All shoulder CT scans were performed on multi-detector row CT scanners using standardized acquisition parameters. Image reconstruction parameters were as follows: field of view, 20 × 20 cm; slice thickness, 0.63–1.25 mm; slice interval, 0.5–1 mm; and both smooth (standard) and sharp (bone) convolution kernels. By secondarily searching in the picture archiving and communication system, 27 patients (28 shoulders, 26.2%) also underwent shoulder magnetic resonance imaging (MRI), MR arthrography, or CT arthrography prior to arthroplasty. All these examinations were reviewed by a musculoskeletal radiologist for the presence of rotator cuff tendon tears. Approval of the institutional ethics committee was obtained, with waiver of informed consent (protocol 505-15).

Muscle degeneration was quantitatively measured in a standardized sagittal-oblique plane, which was reconstructed from the original CT data sets using the visualization software Amira (FEI Visualization Sciences Group, Burlington, MA, USA). This reconstructed CT slice was perpendicular to the scapular axis and coincident with the spinoglenoid notch (Fig. 1). The scapular axis was fitted along the supraspinatus groove and within the scapular

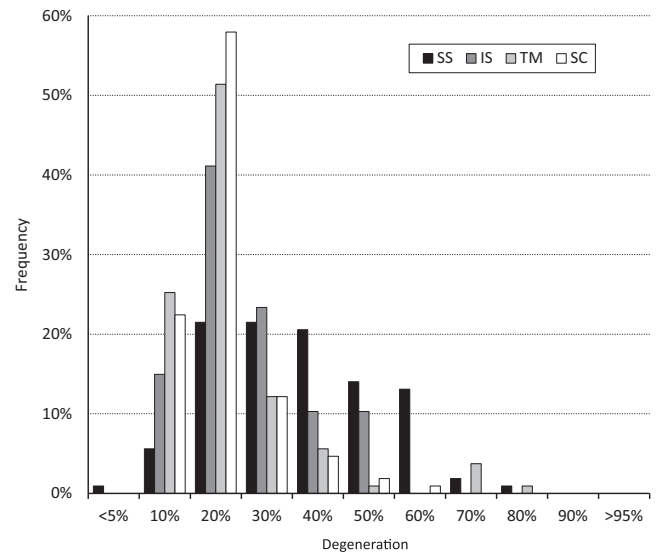
plane. The scapular plane was fitted along the supraspinatus groove and the lateral border of the scapula [11,12]. On this CT slice, a musculoskeletal radiologist delineated the presumed cross-sectional area (S) of the normal supraspinatus (SS), subscapularis (SC), infraspinatus (IS), and teres minor (TM) muscles. Areas of muscle atrophy (Sa), fatty infiltration (Si), and secondary bone formation (including osteophytes, osteochondromas encased in the synovium, and heterotopic ossifications) (So) were automatically generated within S, using user-defined Matlab scripts (MathWorks, Natick, MA, USA) (Fig. 2). We considered CT numbers between –29 and +166 Hounsfield unit (HU) as muscle, fat below, and bone above [13,14]. The threshold values used to segment secondary bone formations were obtained by considering that cancellous bone is composed of 25% trabecular bone and 75% soft tissue, with CT numbers of +1000 and +30 HU, respectively [14]. We thus took the average of these two values (+272.5 HU), and then the in-between value with the upper limit for muscle (+100 HU) to get the threshold limit at +166 HU [13]. From the freehand delineation of normal muscle contours, the algorithm identified muscle, fat, and bone within S, using the above HU thresholds. It first segmented muscle by applying a lower threshold value of –29 HU. This preliminary muscle area could contain holes (fat) and islands. Holes were filled and islands (<10% of S) removed. Within Sa, the algorithm then determined Si using the upper threshold value of –29 HU. Similarly, So was obtained using the lower threshold value of +166 HU. Finally, the effective muscle cross-sectional area (Sm) corresponded to:  $Sm = S - Sa - Si - So$ . We also defined degeneration ratios for atrophy ( $Ra = Sa/S$ ), fatty infiltration ( $Ri = Si/S$ ), and secondary bone formation ( $Ro = So/S$ ) separately, as well as the overall muscle degeneration ratio:  $Rd = (S - Sm)/S = Ra + Ri + Ro$ . Rd was 0% for a fully healthy muscle and 100% for a completely deficient muscle.

Scapulohumeral subluxation was measured according to a recently described 3D quantitative method, providing both amplitude and orientation of subluxation [11]. Subluxation amplitude was defined as the distance between the glenoid surface center and the humeral head center, projected on the same standardized



**Fig. 2.** This is a typical example of the standardized sagittal-oblique CT slice together with an axial slice and the box containing the dataset (A), the standardized sagittal-oblique CT without (B) and with (C) delineation of rotator cuff muscle contours. The freehand regions of interest of the estimated healthy rotator cuff muscles are delineated in green. The corresponding residual muscle surfaces are represented by transparent red areas. The space between green and red contours is muscle atrophy. The islands within red areas represent fatty infiltration. The island circled with purple corresponds to secondary bone formation; in this particular case, a secondary osteochondroma encased in the synovium of the glenohumeral joint and displacing the supraspinatus muscle.

sagittal-oblique plane used for muscle measurements. Subluxation amplitude was normalized to the humeral head radius. A value of 0% corresponded to perfect centering of the humeral head in the glenoid fossa, while 100% corresponded to an eccentric displacement equal to the humeral head radius. Subluxation orientation was identified in 8 glenoid sectors: posterior, postero-superior,



**Fig. 3.** Bar chart showing the frequency of muscle degeneration ratios (percentage) in the supraspinatus (SS), subscapularis (SC), infraspinatus (IS), and teres minor (TM).

superior, antero-superior, anterior, antero-inferior, inferior, and postero-inferior.

We tested all potential linear correlations between the 12 muscle ratios defined above and scapulohumeral subluxation. We also verified the dependency of these muscle ratios with patient age, for men, women, and altogether. The sex dependency was tested (Wilcoxon rank-sum test) for men and women age-adjusted groups, which were obtained by iteratively removing the youngest man and oldest woman until the age difference between the two groups was no longer statistically significant ( $P < 0.05$ ). We assessed the inter- and intra-observer reproducibility of quantitative muscle measurements with intraclass correlation coefficients (ICCs). Twenty randomly-selected cases were re-measured after a 2-week interval, and twice during the same time period by a second observer.

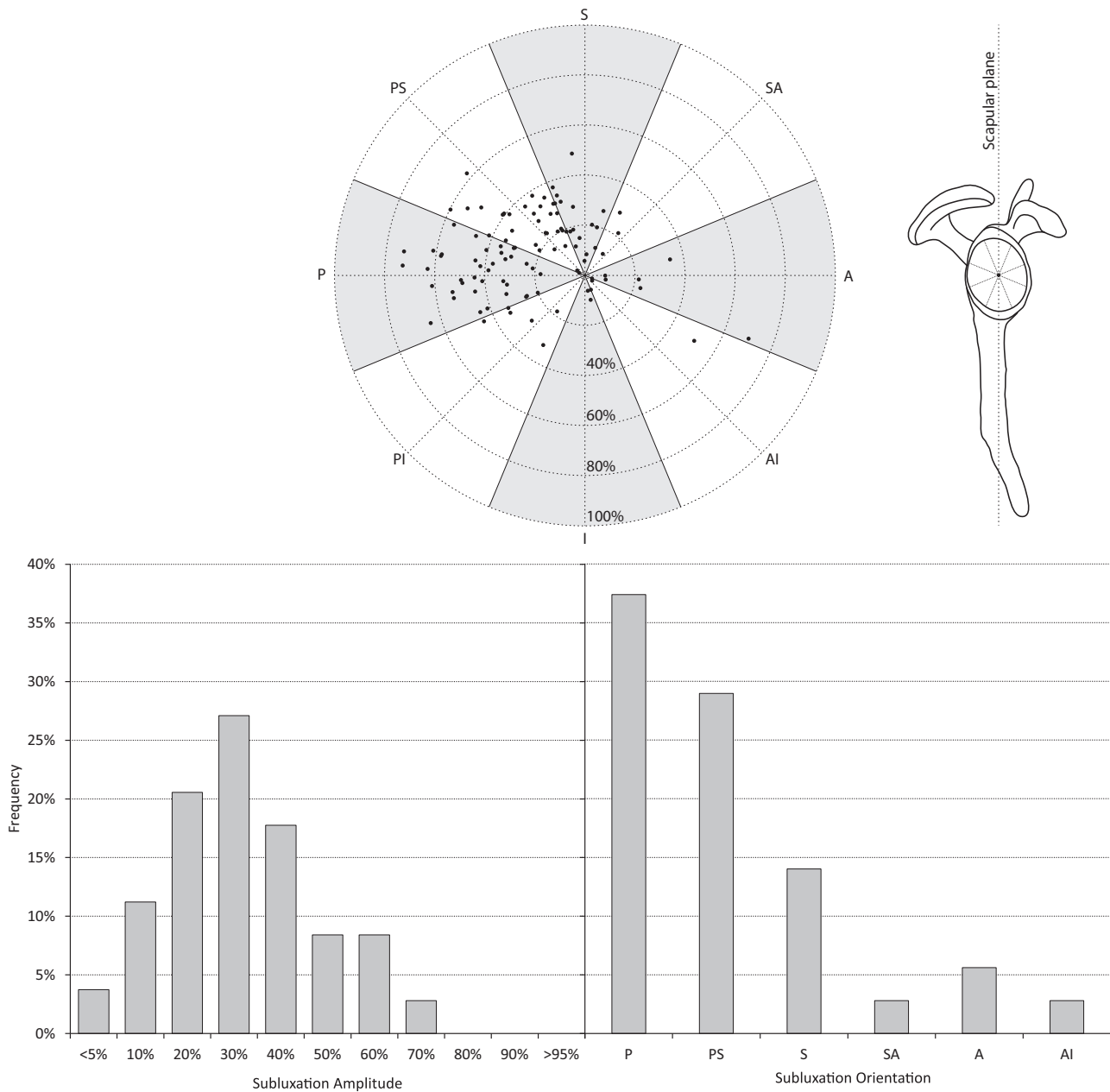
### 3. Results

Atrophy was the main contributor to muscle degeneration and largely predominated in the SS muscle (Table 1). Fatty infiltration was lower than 2% in each muscle. Secondary bone formation was 0.5% and only observed in the SS and SC. The SS was the most severely degenerated muscle, followed by the IS, TM, and SC. The SS was also the most frequently degenerated muscle (Fig. 3). More than 20% of cases presented a SS degeneration ratio above 50%, while it was lower than 20% for the IS and TM taken together, and lower than 5% for the SC. Inter- and intra-observer reproducibility of quantitative muscle measurements were both excellent (Table 2).

**Table 1**

Ratios (mean percentage  $\pm$  standard deviation [range]) of muscle atrophy, fatty infiltration, secondary bone formation, and degeneration in each of the four rotator cuff muscles.

	Supraspinatus	Infraspinatus	Teres minor	Subscapularis
Atrophy	34.6 $\pm$ 16.9% (0.7–79.9%)	14.0 $\pm$ 11.2% (0.2–41.1%)	12.3 $\pm$ 12.8% (1.3–73.4%)	9.6 $\pm$ 8.0% (1.2–54.9%)
Fatty infiltration	1.5 $\pm$ 2.2% (0–13.3%)	1.9 $\pm$ 2.0% (0–8.1%)	0.6 $\pm$ 1.3% (0–9.4%)	1.1 $\pm$ 1.5% (0–12.0%)
Secondary bone formation	0.4 $\pm$ 1.7% (0–12.9%)	None	None	0.5 $\pm$ 1.7% (0–11.0%)
Degeneration	35.5 $\pm$ 16.2% (4.0–80.8%)	15.9 $\pm$ 11.1% (0.8–43.0%)	17.1 $\pm$ 8.3% (1.3–74.2%)	11.2 $\pm$ 8.5% (1.4–54.9%)



**Fig. 4.** The upper polar scatter plot illustrates the amplitude (radius) and orientation (angle) of scapulohumeral subluxation. Below, the bar charts show the frequencies of scapulohumeral subluxation amplitude (left), where bars represent  $\pm 5\%$  around the value on the horizontal axis; and of scapulohumeral subluxation orientation (right), where bars represent the posterior (P), postero-superior (PS), superior (S), supero-anterior (SA), anterior (A), and antero-inferior (AI) sectors.

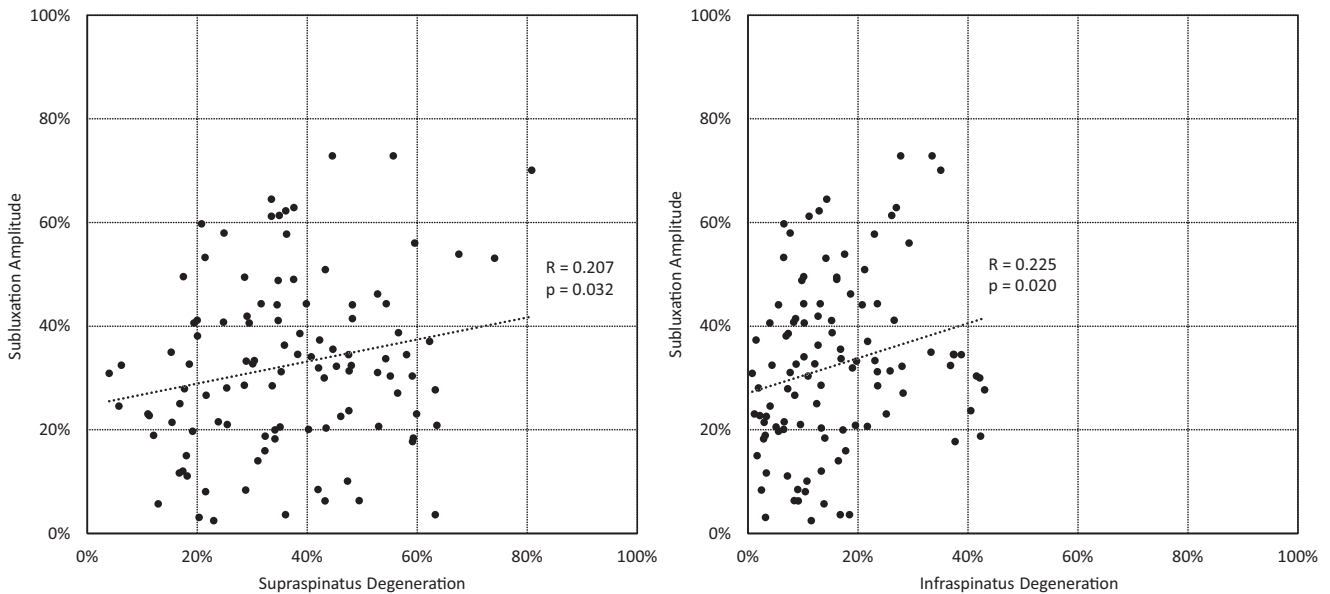
Average scapulohumeral subluxation amplitude was 32.4% (from 2.5 to 72.9%). More than 60% of cases had a subluxation amplitude above 25% (Fig. 4). Subluxation orientation covered all sectors of the glenoid, but it was mainly posterior, postero-superior, and superior.

Subluxation was correlated with SS atrophy ( $R=0.194$ ,  $P=0.045$ ), IS atrophy ( $R=0.206$ ,  $P=0.033$ ), and TM fatty infiltration ( $R=0.191$ ,  $P=0.020$ ). The correlation was slightly higher for the overall degeneration of the SS ( $R=0.207$ ,  $P=0.032$ ) and IS ( $R=0.225$ ,  $P=0.020$ ) (Fig. 5), but not found for the SC ( $R=-0.076$ ,  $P=0.475$ ) and TM ( $R=-0.043$ ,  $P=0.661$ ). Subluxation orientation was not correlated with any muscle degeneration ratio ( $P \geq 0.2$ ). Overall muscle degeneration was correlated with age ( $R=0.317$ ,  $P=0.001$ ). There was no difference between males and females ( $P=0.409$ ). The male and female age-adjusted groups were composed of 29 males (mean age, 68.3 years; range 55–88) and 54 females (mean age, 71.1 years;

range 54–80), respectively. Of the 28 shoulders previously examined with MRI, MR arthrography or CT arthrography, none had a full-thickness complete tear of any rotator cuff tendon, and only 2 (7.1%) full-thickness partial tendon tears were found, both on SS.

#### 4. Discussion

We developed a new semi-automated and highly-reproducible quantitative CT method for measuring degeneration of rotator cuff muscles. Measurements were performed on standardized sagittal-oblique CT slices precisely reconstructed from original CT data sets using specific anatomical landmarks. This reconstruction plane is biomechanically relevant because it is perpendicular to the scapular axis, which can be seen as the major axis of the action line of rotator cuff muscles [11,12]. In addition, it corresponds to the widely-used plane with the typical Y-shape of the scapula, albeit



**Fig. 5.** Scatter charts of scapulohumeral subluxation versus supraspinatus (left) and infraspinatus (right) muscle degenerations, including dotted linear trend lines.

**Table 2**

Intraclass correlation coefficients (ICCs) showing the inter- and intra-observer reproducibility of quantitative measurements for the various muscle parameters, and for each of the four rotator cuff muscles.

	Intraclass correlation coefficients (ICCs)	
	Inter-observer	Intra-observer
<i>Atrophy</i>		
SS	0.988	0.973
IS	0.961	0.946
TM	0.899	0.903
SC	0.899	0.903
<i>Fatty infiltration</i>		
SS	0.988	0.951
IS	0.965	0.871
TM	0.883	0.955
SC	0.991	0.965
<i>Secondary bone formation</i>		
SS	0.999	0.996
IS	NA	NA
TM	NA	NA
SC	1.000	1.000
<i>Degeneration</i>		
SS	0.987	0.971
IS	0.974	0.988
TM	0.955	0.974
SC	0.955	0.974

SS: supraspinatus; IS: infraspinatus; TM: teres minor; SC: subscapularis; NA: not applicable.

with the advantage of not being subject to inter- and intra-observer variability when determined alternately by radiologists or surgeons. The same slice was further used to quantify scapulohumeral subluxation.

The widely-used semi-quantitative, and therefore subjective, Goutallier grading system for fatty infiltration was first developed for CT [5], subsequently adapted to MRI [15], and extended to the assessment of muscle atrophy [6,16]. Dependencies with age, sex, and rotator cuff tendon tears have been reported, but not with glenohumeral joint instability [16,17]. However, although easy to use, this classification has weaknesses and is known to be only moderately reproducible [7–9]. Consequently, several simplified versions or quantitative (i.e. objective) adaptations of Goutallier grading system have successively been proposed [8,15,16,18–21]. Of particular interest is the study by van de Sande et al., who

described producible CT method to quantify fatty infiltration of rotator cuff muscles. However, the parasagittal reconstruction plane was adjusted manually, thereby representing a source of error, and the authors only measured the mean muscle density rather than quantifying muscle atrophy and fatty infiltration separately [21]. Further quantitative methods using MRI fat-water separation techniques have recently been reported [18,19,22]. Fat fraction values in rotator cuff muscles were found to be reliable and correlated well with shoulder pain and range of motion [22], the severity of SS tendon tears [18], and the occupational ratios [19]. Although very interesting and preferred in patients with rotator cuff tendon tears, these quantitative MRI methods are limited in patients planned for shoulder arthroplasty because CT allows more accurate analysis of glenoid version, scapulohumeral subluxation, and particularly glenoid bone mineral density.

Static scapulohumeral subluxation is usually measured as the eccentricity of the humeral head center relative to the glenoid centerline on an axial CT slice crossing the glenoid surface center [10]. More recently, subluxation was measured relative to the scapular axis, first in 2D [23], and lately in 3D [11,24]. Our 3D measurement method extended the classic 2D measurement proposed by Walch et al. [10,23]. However, we defined 0% subluxation for perfect centering of the humeral head, instead of 50%, and normalized to the radius, instead of the diameter as previously proposed [10,11,23]. Accounting for this definition difference, our subluxation values were slightly higher than those measured in 2D on 115 patients [23]. Moreover, our 3D analysis of subluxation further provided the orientation, which was interesting given that it was not always anterior or posterior. However, we were not able to associate subluxation orientation with a specific pattern of rotator cuff muscle degeneration. Subluxation was primarily posterior, while muscle degeneration was mainly superior (SS) and posterior (IS and TM).

Rotator cuff muscle degeneration and scapulohumeral subluxation are critical parameters when anatomical TSA is intended for primary OA with no rotator cuff tear [1,2]. Given that rotator cuff muscles are responsible for glenohumeral joint stability, their degeneration might induce a loss of this function, and thus eccentric loading of the prosthetic glenoid component, and eventually aseptic loosening [3,4]. Muscle degeneration and subluxation have already been hypothetically associated, but this link has not yet been established. Despite a large variability among OA patients,

we observed a significant correlation between rotator cuff muscle degeneration and scapulohumeral subluxation. The correlation was however weak, compared with that between scapulohumeral subluxation and glenoid version [11]. The amplitude and orientation of subluxation were indeed previously reported as being both very strongly correlated with the amplitude and orientation of glenoid version. These results suggest that muscle degeneration alone poorly explains static subluxation. To further assess the relative effect of muscle degeneration on scapulohumeral subluxation, we might perform a multivariate analysis between the amplitude and orientation of glenoid version, the degeneration ratios of all rotator cuff muscles, and the amplitude and orientation of scapulohumeral subluxation.

The correlation coefficients between SS and IS muscle degenerations and scapulohumeral subluxation were weak, though statistically significant. This means that there is a link, but certainly other mechanisms are involved in the progression of subluxation and/or muscle degeneration. This association could explain the reported postoperative recurrent subluxation in shoulders with primary OA because muscle degeneration cannot be corrected by anatomical TSA. The scatter chart of scapulohumeral subluxation versus SS muscle degeneration presented a triangular empty zone in the upper left corner (Fig. 5). Above 30% subluxation, the minimum SS degeneration increased gradually. This is another indication of the association between subluxation and muscle degeneration. The opposite relationship was not observed: low subluxation also correlated with high degeneration. It is still unclear whether muscle degeneration is causing subluxation (i.e. glenohumeral joint instability), or if subluxation is causing muscle degeneration. Muscle degeneration is associated with maximum muscle force, and muscle force is associated with glenohumeral joint stability and subluxation [25]. Conversely, scapulohumeral subluxation can be associated with loss of function, and thus muscle degeneration. Although the present study has no definitive answer to this question, the triangular empty pattern in the subluxation-degeneration scatter chart might suggest that muscle degeneration induces subluxation with some time delay. When degeneration progresses, subluxation may take some time to appear. Alternatively, we could hypothesize that there is no direct causal relationship between muscle degeneration and subluxation, but only a common cause. This study tends to confirm that anatomical parameters, such as the glenoid version, are more likely to explain scapulohumeral subluxation than rotator cuff muscle degeneration [11,26]. Although the causes of subluxation are still not fully understood, we can assume that shoulders with primary OA and severe SS or IS muscle degeneration should be treated with special care.

This study has a few limitations. First, the quantitative CT method developed here to measure muscle degeneration was semi-automated, and therefore not free of errors and uncertainties. Despite the fact that absolute measurement errors within muscle cross-sectional areas were not assessed using a reference standard (e.g. a CT phantom), the inter- and intra-observer reproducibility for delineation of muscle contours were both excellent. Indeed, although contouring of the estimated healthy muscle areas was certainly the largest potential error source of our method, its impact on reproducibility was minimal. There was also some uncertainty as to the threshold value (in HU) required to automatically separate fat from muscle. We thus verified that a variation of  $\pm 30\%$  of the critical threshold value induced average variations of atrophy and fatty infiltration lower than 5% and 1%, respectively. Furthermore, the applied threshold values were already investigated in detail in earlier studies [13,14]. Secondly, we were not able to completely rule out rotator cuff tendon tears in our patients because only a quarter of them (26.2%) also underwent shoulder MRI, MR arthrography, or CT arthrography prior to arthroplasty. However, none of them

had a full-thickness complete tear and only 2 full-thickness partial SS tears were found upon review. Thirdly, the reproducibility of the quantitative scapulohumeral subluxation measurements was not assessed; it has however recently been proven reproducible and accurate using the same method as in the present study [11]. Finally, our quantitative measurement method was only planar and did not take into account the entire rotator cuff muscle volume. A further 3D quantitative method would provide deeper insights into the volumetric pattern of muscle degeneration.

In conclusion, the new semi-automated CT method presented here allows to quantitatively and reproducibly measure rotator cuff muscle degeneration in shoulders with primary OA. Muscle degeneration, mainly consisting of atrophy, is weakly correlated with scapulohumeral subluxation, which is primarily oriented posteriorly, in patients planned for anatomical TSA. In the era of “big data”, it will become increasingly important to extract maximum data from radiological examinations in a simple, quantitative (i.e. objective), and reliable way. This semi-automated quantitative method addresses this need and may eventually be implemented directly on CT scanners in routine clinical practice, or in surgical planning softwares.

## Funding

This study was partly funded by Tornier (Wright Medical Group, Inc., Memphis, TN, USA) and “Fondation de soutien à la recherche dans le domaine de l’orthopédie-traumatologie”.

## IRB statement

Approval of the institutional ethics committee was obtained, with waiver of informed consent (protocol 505-15).

## Disclosure of interest

The authors declare that they have no competing interest.

## Acknowledgements

The authors thank Caroline Sieger Fernandes for language editing and editorial assistance.

## References

- [1] Lapner PL, Jiang L, Zhang T, Athwal GS. Rotator cuff fatty infiltration and atrophy are associated with functional outcomes in anatomic shoulder arthroplasty. *Clin Orthop Relat Res* 2015;473(2):674–82. <http://dx.doi.org/10.1007/s11999-014-3963-5>.
- [2] Denard PJ, Walch G. Current concepts in the surgical management of primary glenohumeral arthritis with a biconcave glenoid. *J Shoulder Elbow Surg* 2013;22(11):1589–98. <http://dx.doi.org/10.1016/j.jse.2013.06.017>.
- [3] Franklin JL, Barrett WP, Jackins SE, Matsen 3rd FA. Glenoid loosening in total shoulder arthroplasty. Association with rotator cuff deficiency. *J Arthroplasty* 1988;3(1):39–46.
- [4] Wirth MA, Rockwood Jr CA. Complications of total shoulder-replacement arthroplasty. *J Bone Joint Surg Am* 1996;78(4):603–16.
- [5] Goutallier D, Postel JM, Bernageau J, Lavau L, Voisin MC. Fatty muscle degeneration in cuff ruptures. Pre- and postoperative evaluation by CT scan. *Clin Orthop Relat Res* 1994;304:78–83.
- [6] Thomazeau H, Rolland Y, Lucas C, Duval JM, Langlais F. Atrophy of the supraspinatus belly. Assessment by MRI in 55 patients with rotator cuff pathology. *Acta Orthop Scand* 1996;67(3):264–8.
- [7] Oh JH, Kim SH, Choi JA, Kim Y, Oh CH. Reliability of the grading system for fatty degeneration of rotator cuff muscles. *Clin Orthop Relat Res* 2010;468(6):1558–64. <http://dx.doi.org/10.1007/s11999-009-0818-6>.
- [8] Slabaugh MA, Friel NA, Karas V, Romeo AA, Verma NN, Cole BJ. Interobserver and intraobserver reliability of the Goutallier classification using magnetic resonance imaging: proposal of a simplified classification system to increase reliability. *Am J Sports Med* 2012;40(8):1728–34. <http://dx.doi.org/10.1177/0363546512452714>.

- [9] Williams MD, Ladermann A, Melis B, Barthelemy R, Walch G. Fatty infiltration of the supraspinatus: a reliability study. *J Shoulder Elbow Surg* 2009;18(4):581–7, <http://dx.doi.org/10.1016/j.jse.2008.12.014>.
- [10] Walch G, Badet R, Boulahia A, Khoury A. Morphologic study of the glenoid in primary glenohumeral osteoarthritis. *J Arthroplasty* 1999;14(6):756–60.
- [11] Terrier A, Ston J, Farron A. Importance of a three-dimensional measure of humeral head subluxation in osteoarthritic shoulders. *J Shoulder Elbow Surg* 2015;24(2):295–301, <http://dx.doi.org/10.1016/j.jse.2014.05.027>.
- [12] Terrier A, Ston J, Larrea X, Farron A. Measurements of three-dimensional glenoid erosion when planning the prosthetic replacement of osteoarthritic shoulders. *Bone Joint J* 2014;96-B(4):513–8, <http://dx.doi.org/10.1302/0301-620X.96B4.32641>.
- [13] Aubrey J, Esfandiari N, Baracos VE, Buteau FA, Frenette J, Putman CT, et al. Measurement of skeletal muscle radiation attenuation and basis of its biological variation. *Acta physiologica* 2014;210(3):489–97, <http://dx.doi.org/10.1111/apha.12224>.
- [14] Fullerton GD, White DR. Anthropomorphic test objects for CT scanners. *Radiology* 1979;133(1):217–22, <http://dx.doi.org/10.1148/133.1.217>.
- [15] Fuchs B, Weishaupt D, Zanetti M, Hodler J, Gerber C. Fatty degeneration of the muscles of the rotator cuff: assessment by computed tomography versus magnetic resonance imaging. *J Shoulder Elbow Surg* 1999;8(6):599–605.
- [16] Zanetti M, Gerber C, Hodler J. Quantitative assessment of the muscles of the rotator cuff with magnetic resonance imaging. *Invest Radiol* 1998;33(3):163–70.
- [17] Melis B, Nemoz C, Walch G. Muscle fatty infiltration in rotator cuff tears: descriptive analysis of 1688 cases. *Orthop Traumatol Surg Res OTSR* 2009;95(5):319–24, <http://dx.doi.org/10.1016/j.otsr.2009.05.001>.
- [18] Nozaki T, Tasaki A, Horiuchi S, Osakabe C, Ohde S, Saida Y, et al. Quantification of fatty degeneration within the supraspinatus muscle by using a 2-point dixon method on 3-T MRI. *AJR Am J Roentgenol* 2015;205(1):116–22, <http://dx.doi.org/10.2214/AJR.14.13518>.
- [19] Lee YH, Kim S, Lim D, Song HT, Suh JS. MR quantification of the fatty fraction from T2\*-corrected dixon fat/water separation volume-interpolated breathhold examination (VIBE) in the assessment of muscle atrophy in rotator cuff tears. *Acad Radiol* 2015;22(7):909–17, <http://dx.doi.org/10.1016/j.acra.2014.01.011>.
- [20] Doro LC, Ladd B, Hughes RE, Chenevert TL. Validation of an adapted MRI pulse sequence for quantification of fatty infiltration in muscle. *Magn Reson Imaging* 2009;27(6):823–7, <http://dx.doi.org/10.1016/j.mri.2009.01.009>.
- [21] van de Sande MA, Stoel BC, Obermann WR, Tjong a Lieng JG, Rozing PM. Quantitative assessment of fatty degeneration in rotator cuff muscles determined with computed tomography. *Invest Radiol* 2005;40(5):313–9.
- [22] Nardo L, Karampinos DC, Lansdown DA, Carballido-Gamio J, Lee S, Maroldi R, et al. Quantitative assessment of fat infiltration in the rotator cuff muscles using water-fat MRI. *J Magn Reson Imaging JMRI* 2014;39(5):1178–85, <http://dx.doi.org/10.1002/jmri.24278>.
- [23] Kidder JF, Rouleau DM, Pons-Villanueva J, Dynamidis S, Defranco MJ, Walch G. Humeral head posterior subluxation on CT scan: validation and comparison of 2 methods of measurement. *Tech Shoulder Elbow Surg* 2010;11(3):72–6, <http://dx.doi.org/10.1097/BTE.0b013e3181e5d742>.
- [24] Sabesan VJ, Callanan M, Youderian A, Iannotti JP. 3D CT assessment of the relationship between humeral head alignment and glenoid retroversion in glenohumeral osteoarthritis. *J Bone Joint Surg Am* 2014;96(8):e64, <http://dx.doi.org/10.2106/JBJS.L.00856>.
- [25] Terrier A, Larrea X, Malfroy Camine V, Pioletti DP, Farron A. Importance of the subscapularis muscle after total shoulder arthroplasty. *Clin Biomech (Bristol, Avon)* 2013;28(2):146–50, <http://dx.doi.org/10.1016/j.clinbiomech.2012.11.010>.
- [26] Gerber C, Nyffeler RW. Classification of glenohumeral joint instability. *Clin Orthop Relat Res* 2002;400:65–76.