

In vivo longitudinal ^1H Spectroscopic Imaging and Diffusion Tensor Imaging studies at 9.4T in a rat model of chronic liver disease

Cristina Cudalbu¹, Valérie McLin², Olivier Braissant³, Nicolas Kunz^{1,4}, Yohan van de Looij^{1,4}, and Rolf Gruetter^{1,5}

¹Laboratory for Functional and Metabolic Imaging (LIFMET), Ecole Polytechnique Fédérale de Lausanne (EPFL), Lausanne, Vaud, Switzerland, ²Département de l'Enfant et de l'Adolescent, Unité de Gastroentérologie, Hépatologie et Nutrition, Hôpitaux Universitaires de Genève (HUG), Geneva, ³Laboratoire de Chimie Clinique, Département de Pathologie et de Médecine de Laboratoire, Centre Hospitalier Universitaire Vaudois and University of Lausanne, Lausanne, Switzerland, ⁴Division of Child Growth & Development, University of Geneva, Geneva, Switzerland, ⁵Departments of Radiology, Universities of Lausanne and Geneva, Switzerland

Introduction: Chronic liver disease (CLD) in children and adults is characterized by an array of cognitive and fine motor deficits labeled as hepatic encephalopathy (HE) [1,2]. Although, the molecular basis for the neurological disorder in liver failure remains elusive, increasing evidence points to ammonia as a main culprit [1,3]. Increased brain glutamine in astrocytes arises from ammonia detoxification, making the astrocytes the principal target of ammonia neurotoxicity and leading to Alzheimer type II astrocytosis in CLD [1]. To date, no *in vivo* longitudinal Spectroscopic Imaging (^1H -SI) or Diffusion Tensor Imaging (DTI) studies were performed in animal models with CLD. Few studies in human have yielded controversial results [4, 5]. Several fold increase in cerebral glutamine and ammonia levels have been the only consistent observations. In addition, a reduction in brain osmolytes (Ins, Tau, tCho) signals were inconsistently observed. The limited number of studies that detected brain edema in CLD supported the vasogenic edema [4], while in acute liver failure (ALF) cytotoxic brain edema is the main feature [1]. It is unclear how HE in CLD differs from the rapid progression and brain edema observed in ALF, but it is suspected that the osmotic change caused by the glutamine increase is compensated by a decrease of other brain osmolytes (i.e. Ins) [4], even if the mechanisms leading to this effects are poorly understood.

In the present study, we hypothesize that the osmotic imbalance seen in HE can be compensated by a decrease of other osmolytes in order to prevent brain edema in a CLD rat model. Consequently, the aim of this study was to analyze the *in vivo* alterations in brain osmolytes and brain edema using novel, longitudinal ^1H SI and DTI methods at 9.4T.

Methods:

Four Wistar rats (300-350g) were bile duct ligated (BDL) [6] and scanned longitudinally before and after BDL for 8 week (once per week). Experiments were performed on a 9.4T system (Varian/Magnex Scientific) using a home-built 14 mm diameter quadrature ^1H coil as a transceiver. First and second order shims were adjusted using FASTMAP (linewidth of 18-22Hz). Metabolic maps were obtained using the SPECIAL spectroscopic imaging sequence (TR/TE = 2500/2.8 ms) [7, 8]. Maps were constructed using 5×10 voxels with a nominal voxel size of $0.75 \times 0.75 \times 2 \text{ mm}^3$ (1.1 μL). Concentrations of metabolites were calculated by LCModel for individual voxels using water as internal reference. Diffusion tensor acquisitions were done with double spin echo semi-adiabatic 4 shots EPI sequence [9] (FOV: $23 \times 15 \text{ mm}^2$, Acq matrix 128×64 , 5 slices, 1 mm thk, 14 averages, TE/TR = 42/2000 ms). Diffusion gradients ($G_{\text{diff}} = 21 \text{ G/cm}$, $\delta = 3 \text{ ms}$, $\Delta = 20 \text{ ms}$, giving a b-value of 1029 s.mm^{-2}) were applied along 6 directions. Diffusivity values (ADC-apparent diffusion coefficient, FA-fractional anisotropy) were derived from the tensor using a Matlab (Mathworks, Natick, MA) script. ADC was measured in ROIs positioned in: cortex, striatum and hippocampus.

Results and Discussion:

^1H spectra acquired in a voxel of 1.1 μL , exhibited excellent SNR (between 10 to 25) allowing easy separation of Gln from Glu and the observation for the first time of the *in vivo* spatial distribution of 12 metabolites (i.e. Gln, Glu, Cr, PCr, tCho, Ins, Tau, Lac, NAA+NAAG, PE, Glc, GABA) in various brain structures (somatosensory and retrosplenial cortex, hippocampus and a small amount of thalamus) after BDL. Fig 1 shows the maps of Gln, Ins, Tau, tCho acquired at different time points after BDL and superimposed on the anatomical T_{2w} images. The increase in the Gln pool at different time points after BDL was apparent from the maps. Gln started to increase 1 week after BDL (~50%) and continued to increase over time (more than 300% at 8 weeks). Among the other brain osmolytes only Ins, tCho and Tau decreased significantly over time (Fig 1). The decrease of these metabolites was smaller in the first week after BDL (~10%) but reached ~30% and even ~80% for tCho 8 weeks after BDL. It is interesting to note that the sum of the main brain osmolytes (Gln, Ins, tCho, Tau) (Fig 1) was constant over time, meaning that to compensate for the Gln increase these metabolites decreased proportionately. Cr showed a trend of decrease over time, suggesting an osmotic role in astrocytes [3]. The maps of other brain metabolites did not show any visible difference between and after BDL for a period of 8 weeks after ligation and retained their specific spatial distribution patterns (i.e. a higher concentration of Glu and NAA+NAAG in cortex) (data not shown). The semi-adiabatic EPI sequence shows a good coverage of the brain with an excellent SNR (Fig 2). Images were free of susceptibility artifacts as well as major geometric distortions (Fig 2). DTI acquired before BDL shows ADC in the cortex ($7.42 \pm 0.2 \cdot 10^{-4} \text{ mm}^2/\text{s}$), striatum ($7.09 \pm 0.2 \cdot 10^{-4} \text{ mm}^2/\text{s}$), in excellent agreement with literature [8, 9]. Within the first 8 weeks after BDL the ADC values were not significantly different; however they showed a small trend of increase. This finding suggests that in spite of ongoing osmotic regulation, mild edema is noticeable.

We characterized for the first time the *in vivo* and longitudinal progression of HE in a model of CLF by using ^1H SI and DTI and consequently we were able to monitor the brain osmolytes changes and the brain edema. The assessment of HE progression in liver disease is difficult prior to the onset of irreversible symptoms. Therefore the use of *in vivo* longitudinal measurements is mandatory promising tool. With the current, worldwide burden of liver disease, understanding these mechanisms with a view to offer appropriate treatment may in the long term have significant public health impact. **In conclusion**, our preliminary data show that in CLD before the appearance of severe neurological signs, the osmotic imbalance created by the continuous increase of Gln can be compensated by a continuous decrease of other osmolytes with minimal brain edema.

References [1] Norenberg MD et al, *Metab Brain Dis* 2009; [2] Caudle SE et al, *J Pediatr*. 2010 ; [3] Braissant O, *Mol Genet Metab*. 2010; [4] Rovira A et al, *AJNR* 29, 2008; [5] Zwiggmann C, *J Neurosci Res*. 2007; [6] Biecker E et al, *J Pharmacol Exp Ther*. 2005; [7] Mlynárik V et al. *Magn Reson Med*. 59:52, 2008; [8] Cudalbu C et al, *Proc Intl Soc Mag Reson Med* 2010; [9] van de Looij Y et al, *Magn Reson Med*, 2011; [10] Bockhorst KH et al, *J Neurosci Res*, 2009. **Acknowledgements.** Supported by Centre d'Imagerie BioMédicale (CIBM) of the UNIL, UNIGE, HUG, CHUV, EPFL, the Leenaards and Jeantet Foundations; SNF grant 131087.

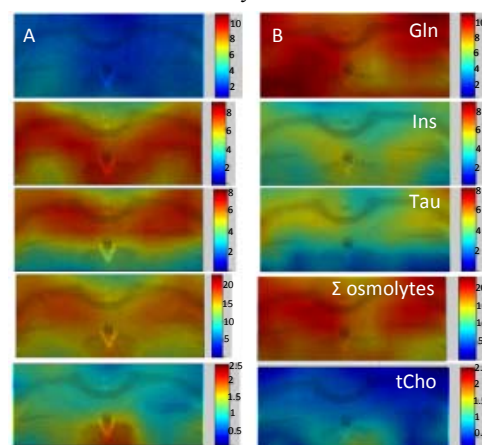


Fig. 1: Metabolic maps of Gln, Ins, Tau, Gln+Ins+Tau+tCho, tCho superimposed on the anatomical T_{2w} images and acquired before (A) and 5 weeks after BDL (B).

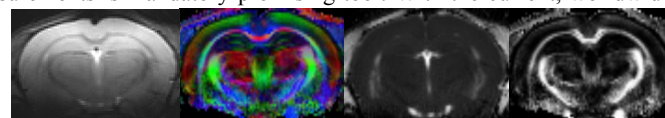


Fig. 2: Images acquired with the semi-adiabatic SE-EPI before BDL. B0 image ($b = 0 \text{ s.mm}^{-2}$), color encoded map, diffusion tensor trace and FA map.