



The non-circular shape of FloWatch[®]-PAB prevents the need for pulmonary artery reconstruction after banding. Computational fluid dynamics and clinical correlations

Antonio F. Corno^{a,*}, Martin Prosi^b, Pierre Fridez^c, Paolo Zunino^b,
 Alfio Quarteroni^c, Ludwig K. von Segesser^d

^a Alder Hey Royal Children Hospital, Eaton Road, Liverpool, L12 2AP, England, UK

^b MOX, Politecnico di Milano, Milano, Italy

^c Ecole Polytechnique Fédérale Lausanne, Lausanne, Switzerland

^d Centre Hospitalier Universitaire Vaudois, Lausanne, Switzerland

Received 19 June 2005; received in revised form 16 September 2005; accepted 17 October 2005; Available online 6 December 2005

Abstract

Objective: To evaluate the differences between non-circular shape of FloWatch[®]-PAB and conventional pulmonary artery (PA) banding. **Methods:** *Geometrical analysis.* Conventional banding and FloWatch[®]-PAB perimeters were plotted against cross-sections. *Computational fluid dynamics (CFD) model.* CFD compared non-circular FloWatch[®]-PAB cross-sections with conventional banding regarding pressure gradients. *Clinical data.* Seven children, median age 2 months (7 days to 3 years), median weight 4.2 kg (3.2–9.8 kg), with complex congenital heart defects underwent PA banding with FloWatch[®]-PAB implantation. **Results:** *Geometrical analysis.* Conventional banding: progressive reduction of cross-sections was accompanied by progressive reduction of PA perimeters. FloWatch[®]-PAB: with equal reduction of cross-sections the PA perimeter remained constant. *CFD model.* Non-circular and circular banding provided same trans-banding pressure gradients for same cross-sections at any given flow. *Clinical data.* Mean PA internal diameter at banding was 13.3 ± 4.5 mm. After a mean interval of 5.9 ± 3.7 months, all children underwent intra-cardiac repair and simple FloWatch[®]-PAB removal without PA reconstruction. Mean PA internal diameter with FloWatch[®]-PAB removal increased from 3.0 ± 0.8 to 12.4 ± 4.5 mm (normal mean internal diameter for the age = 9.9 ± 1.6). No residual pressure gradient was recorded in correspondence of the site of the previous FloWatch[®]-PAB implantation in 6/7 patients, 10 mmHg peak and 5 mmHg mean gradient in 1/7. **Conclusions:** The non-circular shape of FloWatch[®]-PAB can replace conventional circular banding with the following advantages: (a) the pressure gradient will remain essentially the same as for conventional circular banding for any given cross-section, but with significantly smaller reduction of PA perimeter; and (b) PA reconstruction at the time of de-banding for intra-cardiac repair can be avoided. © 2005 Elsevier B.V. All rights reserved.

Keywords: Congenital heart disease; Pulmonary arteries; Pulmonary artery banding; Pulmonary hypertension; Surgery; Ventricular septal defect

1. Introduction

Recent clinical reports considered the pulmonary artery (PA) banding as a palliative approach not only for classical indications such as functionally univentricular hearts [1,2] but also for more controversial situations such as multiple ventricular septal defects [3] and complete atrio-ventricular septal defects [4].

Increasing interest for pulmonary artery banding has been recently dictated by the need for left ventricular retraining in transposition of the great arteries with late referral [5] and in congenitally corrected transposition of the great arteries (=double discordance) [6].

New indications for pulmonary artery banding have been considered in hypoplastic left heart malformations, either as a rescue procedure in critical neonates or as an elective preparation for the subsequent surgical stage, either Norwood procedure or heart transplant [7–9].

The problem most frequently complicating the management of neonates and infants requiring a pulmonary artery banding was the need for an adjustable banding, particularly evident in functionally univentricular hearts and in left ventricular retraining. This need has been solved, at least for neonates and infants, with the clinical availability of a telemetrically controlled, adjustable pulmonary artery banding (FloWatch[®]-PAB, EndoArt, Lausanne, Switzerland), successfully tested in clinical practice in different institutions [10–13] after positive experimental evaluation in animals [14].

Another limit of the conventional pulmonary artery banding was the need for main pulmonary artery reconstruc-

* Corresponding author. Tel.: +44 151 2525713; fax: +44 151 2525643.
 E-mail address: Antonio.Corno@rlc.nhs.uk (A.F. Corno).

tion at the moment of de-banding with intra-cardiac repair [15–18], with extension of the operative duration and risk of residual or recurrent pressure gradient requiring additional interventional procedure or re-operation [16–18].

In this study, we evaluated the need for pulmonary artery reconstruction at the moment of de-banding as a result of the use of the FloWatch[®]-PAB for pulmonary artery banding. A geometrical analysis of the FloWatch[®]-PAB banding shape and the support of computational fluid dynamics (CFD) were used to better understand the observations coming from the clinical practice.

2. Materials and methods

2.1. Geometrical analysis

The banding shape of the FloWatch[®]-PAB implant at different levels of constriction was obtained by a digital camera (Nikon E5700, Nikon Corp., Japan). These pictures were calibrated by using a rectangular reference on each picture. The cross-sectional areas and the perimeters were then obtained from a standard analysis computer program (Mathematica, Wolfram Research Inc., USA). These data were used to plot the FloWatch[®]-PAB perimeters in function of the cross-sections. They were also used as geometrical parameters for the CFD model. It is worth noting that these perimeters are external perimeters with respect to the pulmonary artery wall, and the cross-sectional areas include the arterial wall cross-section. In the following CFD model and the clinical data, all the diameters will be internal diameters and the cross-sectional areas will exclude the arterial wall cross-section.

2.2. Computational fluid dynamics model

Fundamental fluid dynamics or hemodynamics show that the cross-sectional area of a vessel is related to the pressure drop between two different cross-sections of the vessel at hand. According to the fact that the pressure drop along the pulmonary artery is a clinically relevant quantity, we have chosen to quantify by means of CFD the pressure drop across the pulmonary artery in different banding conditions: pulmonary artery before banding, with circular banding, with FloWatch[®]-PAB at different configurations and after FloWatch[®]-PAB removal.

CFD has been applied considering a geometrical model for the pulmonary artery where the proximal section corresponds to the pulmonary valve and the distal section is taken upstream with respect to the pulmonary artery bifurcation. The diameter of the arterial lumen (D) is 18 mm and the length of the pulmonary artery is $4 \times D$, with the position of the banding assumed in the middle of the pulmonary artery. The extent of the contraction region and the expansion region is $1 \times D$. The geometrical shape of the banding was taken from the previously described calibrated pictures, assuming a constant thickness of the pulmonary artery of 0.5 mm inside the FloWatch[®]-PAB narrowing.

To describe the blood flow, the mathematical model employed the time-dependent, three-dimensional, incompressible Navier–Stokes equations [19]. This system of

Example of Grids for the Computational Fluid Dynamics Model

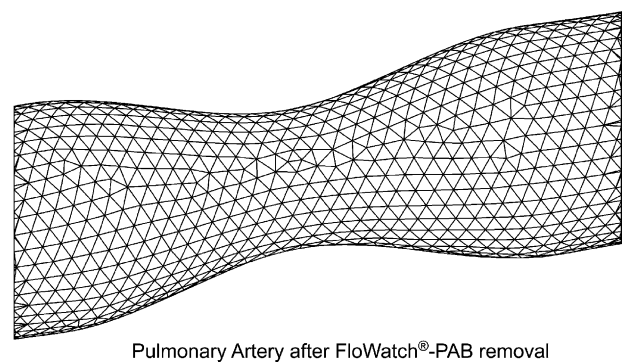
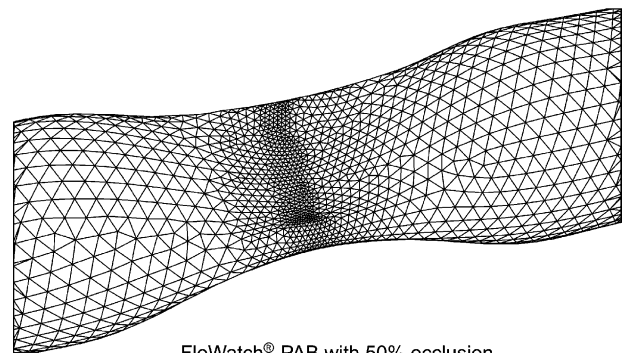


Fig. 1. The geometry of the computational model in the region of the banding with 50% occlusion of FloWatch[®]-PAB (top) and after FloWatch[®]-PAB removal (bottom). The hypothesis of constant perimeter at the banding level was used in both these two situations.

equations must be provided with suitable boundary and initial conditions. At the flow entrance, fully developed velocity profiles are considered. The arterial wall is considered to be rigid and the no-slip condition is applied.

The numerical solution of the time-dependent Navier–Stokes equations was performed by the finite element method. Fig. 1 demonstrates the local high refinement of the finite element subdivision needed to capture the high velocity gradients in case of high cross-sectional restrictions (50% occlusion of FloWatch[®]-PAB).

For a rigorous mathematical definition of this method and its application to fluid dynamics, we refer to previous publications [20] as well for its specific application to blood flow [19].

2.3. Clinical data

Seven children with complex congenital heart defects, most with a late referral (Table 1), underwent pulmonary artery banding with FloWatch[®]-PAB implantation followed by subsequent intra-cardiac repair with de-banding (FloWatch[®]-PAB removal).

In all patients the internal diameter of the main pulmonary artery has been measured with standard surface two-dimensional echocardiography and with intra-operative trans-oesophageal echocardiography in three different

Table 1
Clinical data

Patient	Age	Weight (kg)	Diagnosis
L.P.	2 months	4.2	Multiple ventricular septal defects
A.H.	2 months	3.7	Double inlet single ventricle, transposition of the great arteries
R.V.	2 months	3.2	Transposition of the great arteries
J.B.	7 days	3.2	Ventricular septal defect, aortic stenosis, hypoplastic aortic arch
A.N.	3 years	9.8	Double outlet right ventricle, uncommitted ventricular septal defect, straddling tricuspid valve, anomalous left anterior coronary artery from the right coronary artery, severe pulmonary hypertension
L.S.	6 months	6.2	Transposition of the great arteries
A.S.C.	10 months	6.1	Transposition of the great arteries

periods: (a) before FloWatch[®]-PAB implantation for pulmonary artery banding; (b) before pulmonary artery de-banding (FloWatch[®]-PAB removal); and (c) after pulmonary artery de-banding (FloWatch[®]-PAB removal); in the last occasion a Doppler echocardiography has been associated to measure residual pressure gradients across the main pulmonary artery in the site of the previously implanted banding. The “diameter” before pulmonary artery de-banding is by definition the short axis of the “banana-shape” of the FloWatch[®]-PAB. This measurement should be considered as indicative as this “banana-shape” is not univocally described by a diameter. Nevertheless, we consider this measurement as a reliable measure of the degree of banding and it has been reported because of its clinical relevance.

All values of the diameter of the main pulmonary artery have been recorded, as also recording of the pressure gradients after de-banding.

The study has been conducted after approval by the local institutional review board.

2.4. Statistical analysis

Values have been reported as mean \pm standard deviation. Comparisons were made with Student’s *t*-test. Differences were considered to be significant for $P < 0.05$.

3. Results

3.1. Geometrical analysis

The length of the external perimeter of the banding was plotted against the cross-sectional area of the banding for a conventional circular banding and for the FloWatch[®]-PAB banding (Fig. 2). While with conventional banding the progressive reduction of the cross-sectional area was accompanied by a progressive reduction of the perimeters of the pulmonary artery, with FloWatch[®]-PAB for equal reduction of cross-sectional areas the PA perimeter remained constant.

This is due to the non-circular shape (banana-shape, see Fig. 2) of the FloWatch[®]-PAB banding. This banana-shape allows for a fairly constant perimeter on all the banding range of the device, in contrary to the conventional circular banding. In addition, this constant perimeter is larger than the maximum perimeter of the circular banding for the same range of cross-sectional areas. The constant perimeter of the FloWatch[®]-PAB corresponds to a circular banding of 12.4 mm in diameter, which has a cross-section of 120 mm², while the FloWatch[®]-PAB banding, for the same perimeter, allows a reduction of the cross-sectional area from 72 to 38 mm². Assuming a constant wall thickness of 0.5 mm for the

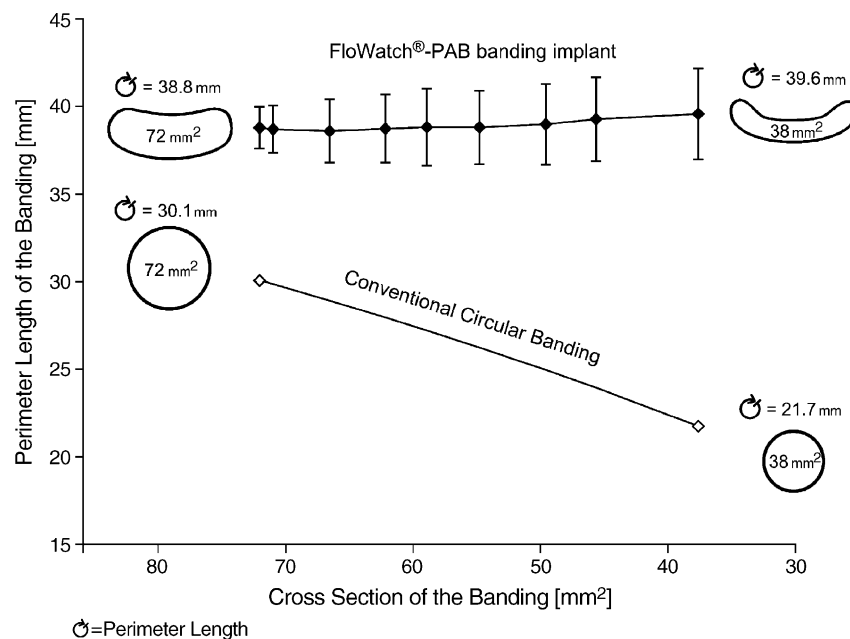


Fig. 2. Geometrical analysis: the length of the external perimeter of the banding plotted against the cross-sectional area of the banding for a conventional circular banding and for the FloWatch[®]-PAB banding. The cross-section range considered is the one accessible to the FloWatch[®]-PAB. The shapes of the extremity of the cross-section range and the exact perimeters at these cross-sections are given at the same scale for both the FloWatch[®]-PAB and the conventional circular banding.

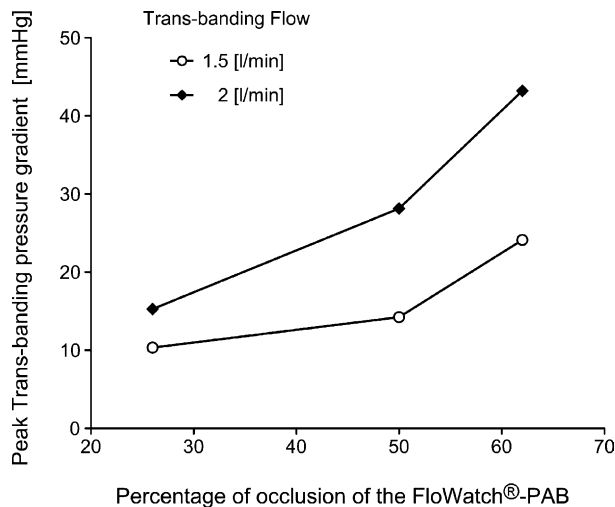


Fig. 3. Computational investigation of the dependence of the pressure gradients across a narrowing of the pulmonary artery induced by the banding and the cross-sectional area at the minimal section, for different percent of occlusion: 26%, 50% and 62%. The measurements were obtained with two different flows: 1.5 and 2.0 L/min.

development of the computational model, the result is a variable luminal cross-sectional area from 52 to 18 mm².

3.2. Computational fluid dynamics model

In order to investigate the influence of the banding shape on the pressure gradient across the banding, several simulations have been carried out in different geometrical configurations. Fig. 3 displays the resulting pressure gradient for three different FloWatch[®]-PAB occlusion levels, resulting in a luminal cross-sectional area of 47 mm² (26% occlusion), 39 mm² (50% occlusion) and 36 mm² (62% occlusion). For each geometrical configuration, two numerical simulations with a different inflow rate (1.5 and 2.0 L/min) have been carried out. The figure points out that the resulting pressure gradients across the banding are more sensitive to varying FloWatch[®]-PAB occlusions in case of a higher flow rate, resulting in a higher slope of the curve, in perfect agreement with Poiseuille's law [19]. The difference of the pressure gradients between FloWatch[®]-PAB and conventional circular banding is shown in Table 2. The differences of the pressure gradients are within 13% for comparable configurations (same luminal cross-sectional area). Thereafter, the computational

Table 2
Difference of the mean trans-banding pressure gradient between FloWatch[®]-PAB and conventional circular banding

	Mean trans-banding pressure gradient [mmHg]	Flow rate [L/min]	Luminal area [mm ²]
FloWatch [®] -PAB with 26% occlusion	15.26	2	47
Corresponding circular banding (neck 7.77 mm)	17.55	2	47
FloWatch [®] -PAB with 50% occlusion	14.23	1.5	39
Corresponding circular banding (neck 7.06 mm)	14.85	1.5	39

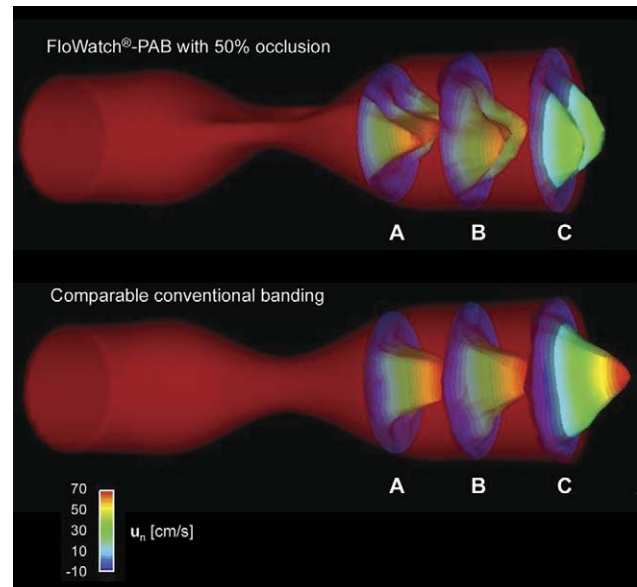


Fig. 4. Comparison of the axial flow velocity between FloWatch[®]-PAB with 50% occlusion (top) and conventional circular banding with the same cross-sectional area (bottom), showing a significant difference of the axial velocity profiles between the two. The special cross-sectional shape of FloWatch[®]-PAB results into two jets downstream (cross-section C), while in the conventional banding a single velocity jet with a higher peak velocity occurs.

results confirm the clinical observation that the pressure gradients in correspondence of the banding are only minimally influenced by the shape of the banding, at least in the simulated range. After FloWatch[®]-PAB removal, we assume that the pulmonary artery reopens to a circular restricted configuration with a restriction luminal perimeter corresponding to the perimeter during the banding process with FloWatch[®]-PAB. This restriction luminal perimeter is 34 mm corresponding to a luminal diameter of 10.86 mm at the restriction neck. Numerical simulations demonstrate that the pressure gradient caused by this restriction is in the range of 2.5 mmHg for a physiologic realistic flow rate of 1.5 L/min after surgical repair.

A comparison of the axial flow velocity with FloWatch[®]-PAB and the conventional circular banding is shown in Fig. 4.

3.3. Clinical data

The mean internal diameter of the pulmonary artery at the time of banding was 13.3 ± 4.5 mm (range 7–20 mm). After a mean interval of 5.9 ± 3.7 months (range 3–14 months), with the mean percentage narrowing of the device set at 53% (range from 25 to 90%, dictated by the initial diameter of the pulmonary artery and the clinical needs), all children underwent intra-cardiac repair and FloWatch[®]-PAB removal. In all patients the declipping of the FloWatch[®]-PAB was immediately followed by spontaneous reopening of the main pulmonary artery. The intra-operative aspect of the wall of the main pulmonary artery was in all cases with very pliable and soft tissues, completely different from the thick, fibrotic ring left in place by conventional pulmonary artery banding. As a consequence, reconstruction of the pulmonary artery was required in no patient. The presence of a thin and pliable pulmonary artery wall has been confirmed in two

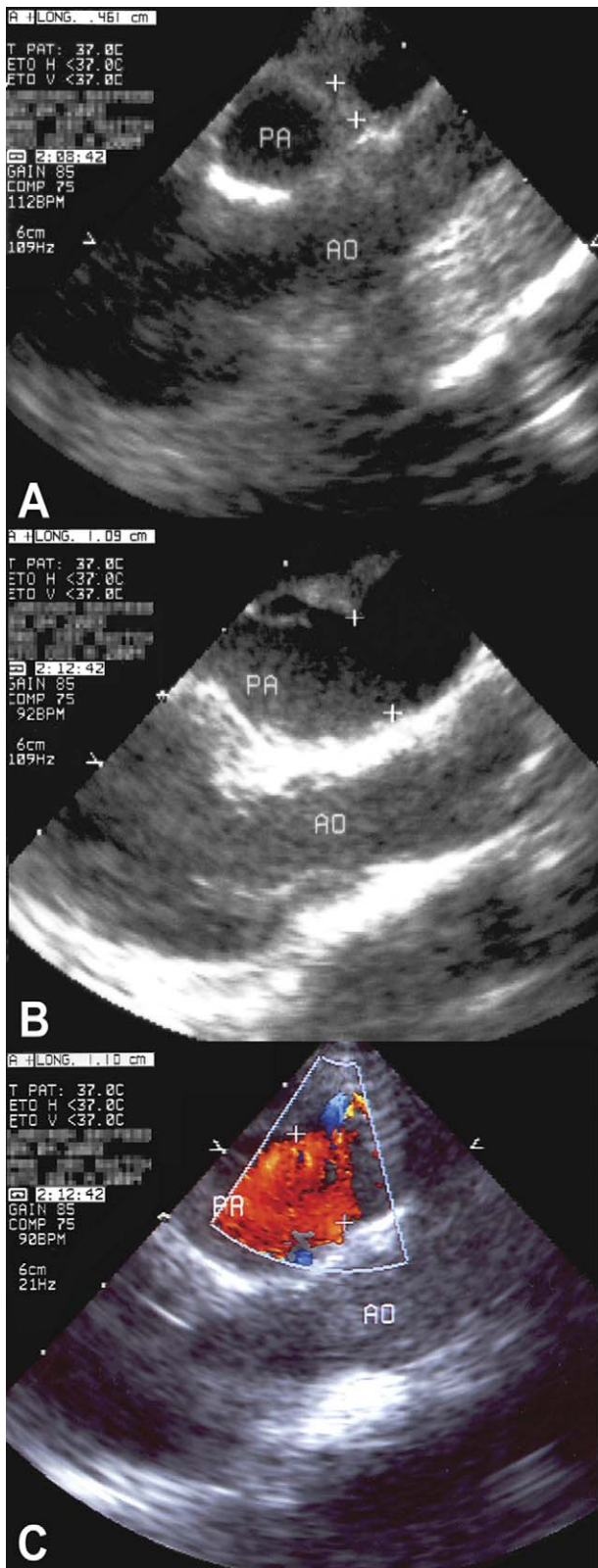


Fig. 5. Intra-operative trans-oesophageal echocardiography, showing the narrowing of the pulmonary artery (A = 0.46 cm) with FloWatch[®]-PAB in situ, the spontaneous reopening of the pulmonary artery (B = 1.09 cm) immediately after unclipping the FloWatch[®]-PAB, and with the colour Doppler (C = 1.10 cm) showing absence of pressure gradient. Ao: aorta; and PA: pulmonary artery.

children where trans-section was required for the intra-cardiac repair (arterial switch).

The mean internal diameter of the main pulmonary artery with simple FloWatch[®]-PAB removal increased from 3.0 ± 0.8 mm (range 3–5 mm) to 12.4 ± 4.5 mm (range 7–20 mm) (Fig. 5).

These values have been compared with the values of the normal internal diameter of the main pulmonary artery in children with the same age: 9.9 ± 1.6 mm (range 8.4–13.0 mm) and a statistical difference could not be demonstrated ($P = 0.30$).

The measured values have been reported in Fig. 6, with the relationship between the recorded pulmonary artery perimeters (Fig. 6A) and the corresponding cross-sectional areas (Fig. 6B), together with the comparison with the normal values for the age.

Even with a relatively small and highly non-homogenous group, there is a significant difference ($P < 0.05$) between the pulmonary artery cross-sectional area with FloWatch[®]-PAB in place in comparison to all other groups. This is relevant because this cross-section include the arterial wall which is not expected to change, thus, the effective lumen cross-sectional area has to change in a very substantial way to ensure this significant difference. As the thickness of the pulmonary artery was not accurately measured, it was impossible to exclude the arterial wall from this cross-sectional area.

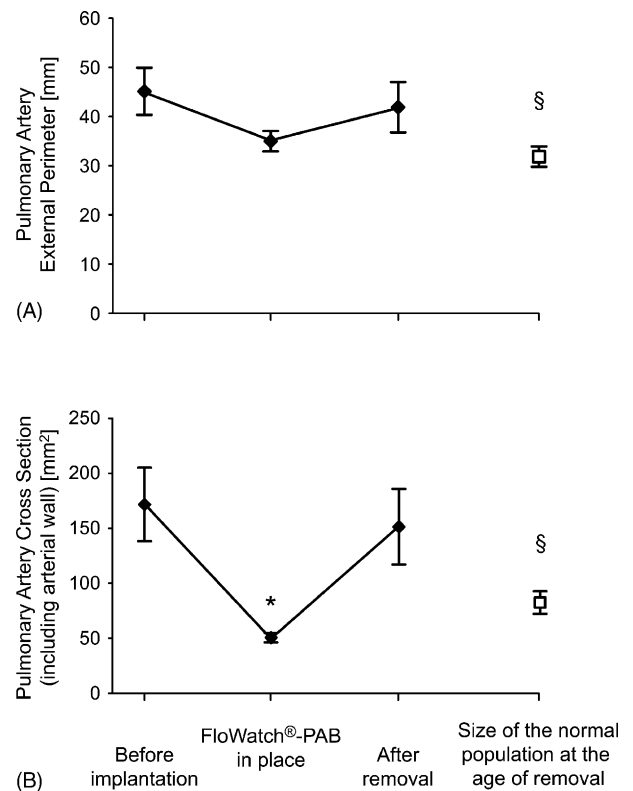


Fig. 6. Clinical data: variations of the pulmonary artery perimeters (A) and the corresponding cross-sectional areas (B), before implantation of FloWatch[®]-PAB, with the device in situ and immediately after explantation, together with the comparison with the normal values for the age. Error bars indicate standard deviation ($n = 7$). Statistically different from all other groups ($^*P < 0.05$). Statistically different from group before implantation ($^{\S}P < 0.05$).

Another point is that the only group with difference in the size of the pulmonary artery from the normal population is the group of patients before banding.

No residual pressure gradient was recorded in correspondence of the site of the previous FloWatch[®]-PAB implantation in six patients, while 10 mmHg peak pressure gradient and 5 mmHg mean gradient were recorded in the last patient. These values remained unchanged during a mean follow-up after FloWatch[®]-PAB removal of 18.2 months (range 14–24 months).

This absence of residual pressure gradient after simple FloWatch[®]-PAB removal, without reconstruction of the pulmonary artery, is in agreement with the very small theoretical values obtained with our CFD model (in the range of 2.5 mmHg for a flow rate of 1.5 L/min).

4. Discussion

The proven clinical availability of a telemetrically controlled adjustable pulmonary artery banding for neonates and infants [10–13] has already extended the potential indications to pulmonary artery banding, particularly because of the possibility of endless adjustments repeated over long term, from the limited classical [1,2] to more controversial indications [3,4]. The horizon of the indications for pulmonary artery banding can be further expanded to more difficult situations [5–9].

In this study, we have observed the possibility of avoiding the pulmonary artery reconstruction at the time of intra-cardiac repair; thanks to the utilization of the adjustable pulmonary artery banding with FloWatch[®]-PAB. Our findings constitute a further improvement in comparison with the generally reported clinical experience with the conventional banding, where reconstruction of the pulmonary artery is the rule, not infrequently accompanied by the need of further surgical and/or interventional treatment because of residual pressure gradient in the correspondence of the pulmonary artery reconstruction [15–18,21].

The reason for the different behaviour of the pulmonary artery when narrowed by a FloWatch[®]-PAB versus a conventional banding could have been found in either the materials used for the banding and/or in the shape of the narrowing.

Since the tissue fibrosis precluding spontaneous expansion after de-banding has been found independently on the materials used for the banding in the literature [15–18,22] as well as in our personal clinical experience, we concentrated our study on the shape of the banding.

While the conventional banding produces a circular narrowing of the main pulmonary artery with the internal shape corresponding to a circular cross-sectional area, due to the shape of FloWatch[®]-PAB the internal shape of the pulmonary artery became a source of banana-shape, close to a crescent shape, and is the fact that this banana-shape is a concave shape which provides its remarkable properties.

The FloWatch[®]-PAB allows for the same reduction of the cross-sectional pulmonary artery area than the conventional circular banding, but with a significantly larger perimeter; thanks to the banana-shape of the circumference. Further-

more, the perimeter remains constant for the entire range of regulation of the banding (Fig. 2).

Our understanding is that after conventional circular banding the substantial reduction of the perimeter of the pulmonary arterial wall is accompanied by anatomical and histological changes with increased thickness, dense fibrosis and loss of elasticity. After removal of the conventional band, the wall of the pulmonary artery remains fixed in the same position and it is impossible to increase the cross-sectional area without changing its diameter. Therefore, a surgical incision/resection with subsequent reconstruction is mandatory, sometimes with residual or recurrent pressure gradient [15–18,21].

Since the banding with FloWatch[®]-PAB obtains the same reduction of cross-sectional area of the conventional circular banding, and therefore the same pressure gradient, without any reduction of the perimeter of the pulmonary artery, the wall of the artery can maintain intact its anatomical properties without any reduction of elasticity. Therefore, the simple FloWatch[®]-PAB removal at the time of intra-cardiac repair is enough to obtain spontaneous and complete expansion of the wall of the pulmonary artery up to a circular cross-sectional area with the same perimeter of the previously banded pulmonary artery, with maintenance of its elasticity and pliability.

In a previously reported experimental study in animals the conventional pulmonary artery banding had been compared with an adjustable, stainless steel “ball and saddle” device [22]. Interestingly, this prosthesis induced a crescent shape of the pulmonary artery narrowing, very similar to the one obtained with the FloWatch[®]-PAB [22]. The authors of this experimental study observed that, while “unbanding with either umbilical or Teflon tape narrowing was difficult because of marked fibrosis and scarring around the circumferential tape”, “unbanding of the ball and saddle prosthesis was readily accomplished and resulted in restoration of the prebanded lumen and abolition of the pressure gradient across the previously banded main pulmonary artery” [22]. The authors also concluded that “we have not and shall not use the currently described ball and saddle prosthesis clinically”, because of the observed “atrophy of the vessel wall beneath the metal band” after a 3-month period of implantation [22].

In our model of adjustable pulmonary artery banding, realised without being aware of the above previous study [22], because of the progresses in the development of biomaterials, structural damages to the wall of the pulmonary artery have been not found, even with the FloWatch[®]-PAB remaining implanted for a mean duration of 6 months, and the range of duration extended up to 14 months. The same phenomenon had already been observed in the previous experimental study in piglets, where the wall of the pulmonary artery maintained a rather intact histology [14]. While we have data from the animal study, at the present time evidence of the maintenance of the histological morphology of the pulmonary artery with FloWatch[®]-PAB is not yet available in patients.

The absence of measurable residual pressure gradients recorded in our patients after simple FloWatch[®]-PAB removal, without reconstruction of the pulmonary artery, is in total agreement with the results obtained with the CFD model.

Furthermore, the results obtained with the CFD model suggest that the non-circular shape of the banding allows for a smaller jet effect than conventional banding (Fig. 4). The CFD also shows, for the same gradient and flow, a faster decrease of the maximal axial velocity; this observation could have a clinical correspondence in a reduced traumatic jet lesion at the level of the pulmonary artery bifurcation.

Despite several studies have previously been reported with the use of the CFD to investigate problems related with surgery of congenital heart defects [23–25], to our knowledge the CFD has never been utilised before to study the effects of different shapes of pulmonary artery banding.

Our observations confirm that CFD can provide valid support to investigate clinical problems, in order to find solutions then validated by the clinical evidence.

5. Conclusions

Based on the results of our study with geometrical analysis and CFD model, with the data confirmed by the clinical evidence, we can conclude that pulmonary artery banding can be performed replacing the conventional circular narrowing with the non-circular shape of FloWatch[®]-PAB, with the following advantages in addition to the ones already recognised to the telemetrically adjustable banding [10–13]:

- (a) the pressure gradient will remain essentially the same as for the conventional circular banding for any given cross-sectional area, but with a reduction of the perimeter of the pulmonary artery significantly smaller; and
- (b) reconstruction of the pulmonary artery at the time of de-banding for intra-cardiac repair can be avoided.

Acknowledgements

Drs. Nicole Sekarski and Marc-André Bernath kindly provided the echocardiographic illustrations. The numerical simulations have been carried out using the finite element library LifeV.

References

- [1] Lee JR, Choi JS, Kang CH, Bae EJ, Kim YJ, Rho JR. Surgical results of patients with a functional single ventricle. *Eur J Cardiothorac Surg* 2003;24:716–22.
- [2] Miura T, Kishimoto H, Kawata H, Hata M, Hoashi T, Nakajima T. Management of univentricular heart with systemic ventricular obstruction by pulmonary artery banding and Damus–Kaye–Stansel operation. *Ann Thorac Surg* 2004;77:23–8.
- [3] Sivakumar K, Anil SR, Rao SG, Shivaprakash K, Kumar RK. Closure of muscular ventricular septal defects guided by en face reconstruction and pictorial representation. *Ann Thorac Surg* 2003;76:158–66.
- [4] Al Qethamy HO, Aboelnazar S, Aizaz K, Al Faraidi Y. Play safe: band the late presenting complete atrioventricular canal. *Asian Cardiovasc Thorac Ann* 2002;10:31–4.
- [5] Corno AF, Hurni M, Payot M, Sekarski N, Tozzi P, von Segesser LK. Adequate left ventricular preparation allows for arterial switch despite late referral. *Cardiol Young* 2003;13:49–52.
- [6] Duncan BW, Mee RB, Mesia CI, Qureshi A, Rosenthal GL, Seshadri SG, Lane GK, Latson LA. Results of the double switch operation for congenitally corrected transposition of the great arteries. *Eur J Cardiothorac Surg* 2003;24:11–9.
- [7] Ishizaka T, Ohye RG, Suzuki T, Devaney EJ, Bove EL. Bilateral pulmonary artery banding for resuscitation in hypoplastic left heart syndrome. *Ann Thorac Surg* 2003;75:277–9.
- [8] Mitchell MB, Campbell DN, Boucek MM, Sondheimer HM, Chan KC, Ivy DD, Pietra B, Mackenzie T. Mechanical limitation of pulmonary blood flow facilitates heart transplantation in older infants with hypoplastic left heart syndrome. *Eur J Cardiothorac Surg* 2003;23:735–742.
- [9] Pizarro C, Norwood WI. Pulmonary artery banding before Norwood procedure. *Ann Thorac Surg* 2003;75:1008–10.
- [10] Corno AF, Sekarski N, von Segesser LK. Remote control of pulmonary blood flow: a dream comes true. *Swiss Med Wkly* 2002;132:423–4.
- [11] Corno AF, Bonnet D, Sekarski N, Sidi D, Vouhé P, von Segesser LK. Remote control of pulmonary blood flow: initial clinical experience. *J Thorac Cardiovasc Surg* 2003;126:1775–80.
- [12] Sekarski N, Fridez P, Corno AF, von Segesser LK, Meijboom E. Doppler guided regulation of a telemetrically operated adjustable pulmonary banding system. *J Am Coll Cardiol* 2004;44:1087–94.
- [13] Bonnet D, Corno AF, Sidi D, Sekarski N, Beghetti M, Schulze-Neick I, Fasnacht M, Le Bret E, Kalangos A, Vouhé PR, von Segesser LK. Early clinical results of telemetric adjustable pulmonary artery banding Flo-Watch[®]-PAB. *Circulation* 2004;110:158–63.
- [14] Corno AF, Sekarski N, Bernath MA, Payot M, Tozzi P, von Segesser LK. Pulmonary artery banding: long-term telemetric adjustment. *Eur J Cardiothorac Surg* 2003;23:317–22.
- [15] Davis Z, McGoon DC, Danielson GK, Wallace RB. Removal of pulmonary artery band. *Isr J Med Sci* 1975;11:110–5.
- [16] Kirklin JW, Appelbaum A, Bargeron LM. Primary repair versus banding for ventricular septal defects in infants. In: Kidd BS, Rowe RD, editors. *The child with congenital heart disease after surgery*. Mount Kisco, NY: Futura Publishing; 1976. p. 3.
- [17] Kouchoukos NT, Blackstone EH, Doty DB, Hanley FL. Ventricular septal defect. In: Kirklin/Barrat-Boyes. *Cardiac Surgery*. 3rd Edition, Philadelphia, PA: Churchill Livingstone, 2003. p. 850–909.
- [18] Backer CL, Mavroudis C. Palliative operations. In: Mavroudis C, Backer CL, editors. *Pediatric cardiac surgery*. Philadelphia, PA: Mosby; 2003. p. 160–70.
- [19] Quarteroni A, Tuveri M, Veneziani A. Computational vascular fluid dynamics: problems, models and methods, computing and visualisation. *Science* 2000;2:163–97.
- [20] Babuvska I, Strouboulis T. *The finite element method and its reliability*. New York: Oxford University Press, 2001.
- [21] Hallman GL, Cooley DA, Bloodwell RD. Two-stage surgical treatment of ventricular septal defect in patients requiring operation during the first year of life. Results of pulmonary artery banding and subsequent open-heart repair. *J Thorac Cardiovasc Surg* 1966;52:476.
- [22] Shane RA, Kimmell GO, Jaques WE, Campbell GS. Adjustable prosthesis for pulmonary artery banding. Comparison with umbilical tape and Teflon bands. *Circulation* 1967;35(Suppl. 1):148–51.
- [23] Rydberg A, Teien DE, Krus P. Computer simulation of circulation in patient with total cavo-pulmonary connection: inter-relationship of cardiac and vascular pressure, flow, resistance and capacitance. *Med Biol Eng Comput* 1997;35:722–8.
- [24] Migliavacca F, Pennati G, Dubini G, Fumero R, Pietrabissa R, Urcelay G, Bove EL, Hsia TY, de Leval MR. Modeling of the Norwood circulation: effects of shunt size, vascular resistances, and heart rate. *Am J Physiol Heart Circ Physiol* 2001;280:H2076–8.
- [25] Lagana K, Dubini G, Migliavacca F, Pietrabissa R, Pennati G, Veneziani A, Quarteroni A. Multiscale modelling as a tool to prescribe realistic boundary conditions for the study of surgical procedures. *Biorheology* 2002; 39:359–64.