

High efficacy of photodynamic therapy on rat endometrium after systemic administration of benzoporphyrin derivative monoacid ring A

P.Mhawech¹, A.Renaud⁴, C.Sene^{3,4}, F.Lüdicke⁴, F.Herrmann⁵, I.Szalay-Quinodoz¹, H.van den Bergh⁶ and A.L.Major^{2,4,7}

¹Department of Pathology, Geneva University Hospital, Geneva, ²Department of Obstetrics and Gynaecology, Geneva University Hospital, Geneva, ³Department of Biology, Faculty of Sciences, University of Geneva, ⁴Fondation pour Recherches Médicales, University of Geneva, ⁵Department of Geriatrics, Geneva University Hospital and ⁶Swiss Federal Institute of Technology, Lausanne, Switzerland

⁷To whom correspondence should be addressed at: Department of Obstetrics and Gynaecology, Geneva University Hospital, 30 Boulevard de la Cluse, 1211 Geneva 14, Switzerland. E-mail: Attila.Major@hcuge.ch

BACKGROUND: The aim of this study was to evaluate the effect of the benzoporphyrin derivative monoacid ring A (verteporfin)-mediated photodynamic therapy (PDT) on rat endometrium and to determine the optimal drug concentration for endometrial ablation. **METHODS:** Five minutes after i.v. injection of different concentrations of verteporfin into 24 female Sprague–Dawley rats, 630 nm light treatment was delivered for 500 s (120 J/cm²) to the left horn of the uterus. The 24 rats were divided into six groups according to the drug dose injected, four rats per group: group I (2 mg/kg), group II (1 mg/kg), and groups III, IV, V and VI with 0.5, 0.25, 0.125 and 0.0625 mg/kg respectively. Four days later, the rat uteri were analysed by light microscopy. **RESULTS:** Endometrial destruction was seen in all six groups, with the most significant result in group I ($P < 0.008$). Conservation of the myometrium was most significant in groups III, IV, V and VI. Acute inflammatory cells in the stromal endometrium were recorded mainly in groups I and II. However, the drug dosage that was most significant in destroying the glands with conservation of the myometrium and not causing severe inflammation was between 0.5 and 0.125 mg/kg. **CONCLUSIONS:** Verteporfin was effective in endometrial ablation in all our animal groups, and the dose range of 0.5–0.125 mg/kg appeared to be adequate. This observation will have to be scaled for clinical application.

Key words: BDP/endometrial ablation/PDT/rat model

Introduction

Hysterectomy is one of the most frequently performed major operations in the Western world. The indications for hysterectomy are numerous and include malignant and benign conditions, with dysfunctional uterine bleeding accounting for ~20% of hysterectomy cases (Lee *et al.*, 1984). This procedure may result in high annual hospitalization costs, morbidity rates ranging from 20 to 40% and mortality from 0.06 to 0.38%, depending on the procedure and the indication (Carlson *et al.*, 1993). In addition to the use of photodynamic therapy (PDT) for macular degeneration as well as many oncological conditions, numerous studies have proven PDT's role in endometrial ablation (Wyss *et al.*, 1994a;b; Gannon *et al.*, 1995; Fehr *et al.*, 1996a;b, 2002; Steiner *et al.*, 1996; Allison *et al.*, 2001; Renno and Miller, 2001; Major *et al.*, 2002). As it can be performed in an ambulatory setting with essentially no side effects, PDT could be an ideal substitute for hysterectomy in treating patients suffering from uterine bleeding dysfunction.

PDT uses the light activation of a photosensitizer to generate highly reactive oxygen intermediates, leading to tissue destruction by apoptosis and/or necrosis (Sickenberg *et al.*, 2000). Various photosensitizers, such as 5-aminolevulinic acid (ALA) and benzoporphyrin derivative (BPD), administered topically or systemically, have been used for endometrial ablation in animal models with good results (Wyss *et al.*, 1994a; b; Gannon *et al.*, 1995; Fehr *et al.*, 1996a;b; Steiner *et al.*, 1996). However, most of these studies targeted the endometrial glands directly by either topical or systemic application of a photosensitizer. In order to accumulate the photosensitizer in the endometrial glands, long intervals between drug administration and light application were needed.

BPD-monoacid ring A (BPD-MA), verteporfin (Visudyne)TM, is a second-generation photosensitizer injected in a liposomal formulation, which has been accepted by many health authorities as a new and effective treatment for macular degeneration. Despite the typical activation of the verteporfin

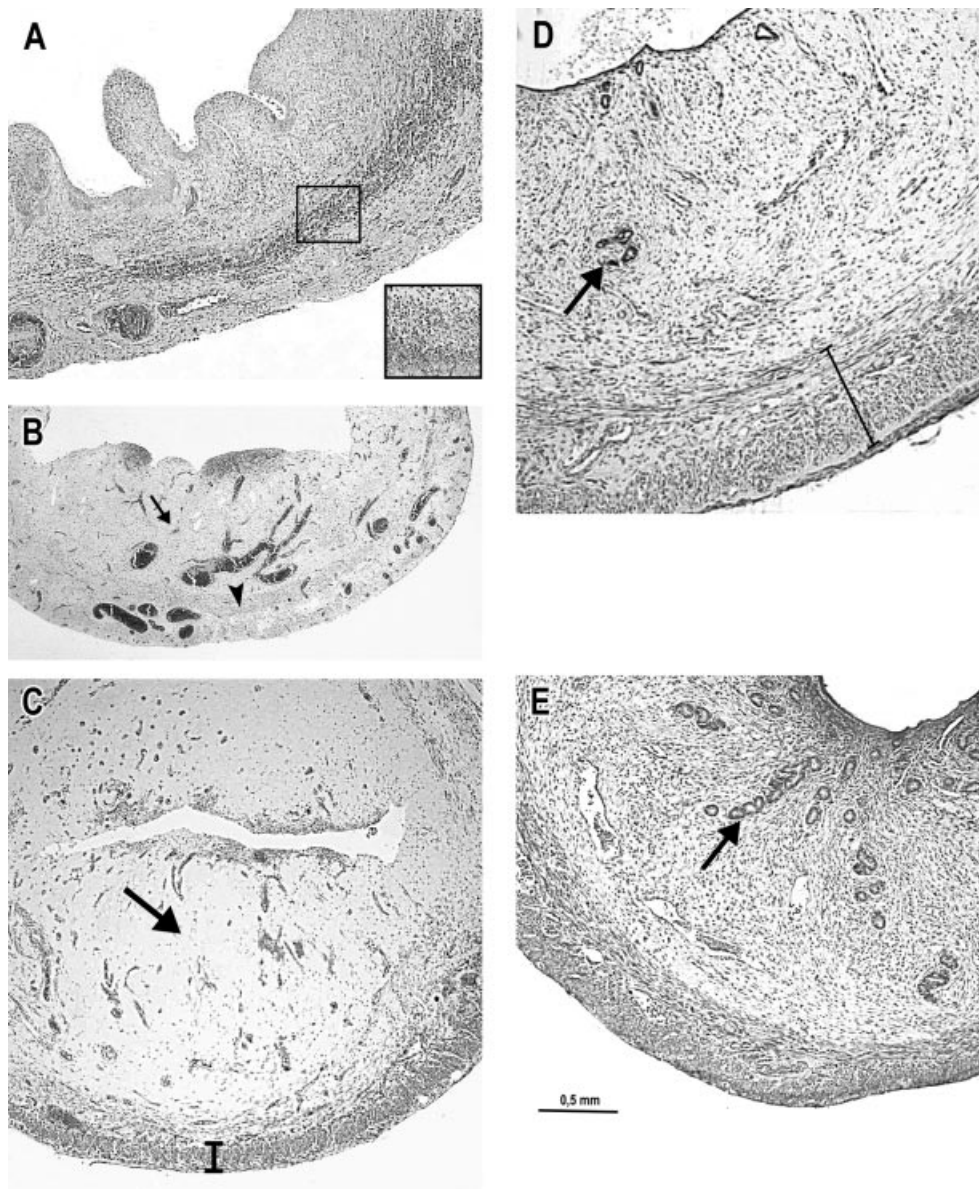


Figure 1. (A) Cross-section of a rat uterus after i.v. injection of verteporfin at 2 mg/kg. There are acute inflammatory infiltrates in the stroma and destruction of the myometrium. The box indicates the acute inflammatory reaction involving polynuclear neutrophils. (B) An example of a rat injected with verteporfin at 1 mg/kg. Note the complete absence of the endometrial glands (arrow) with complete loss of the myometrial thickness (arrow head). (C) At 0.25 mg/kg there is complete absence of the endometrial glands with no inflammation or necrosis (arrow). Half of the myometrium thickness is still conserved (bar). (D) At 0.0625 mg/kg there is incomplete destruction of the endometrial glands (arrow) despite the complete presence of the myometrium (bar). (E) In the normal control as well as in the right horn (internal control) there are normal endometrial glands with no necrosis no inflammation, and normal myometrial thickness. The endometrial glands are indicated by an arrow.

at a wavelength of 690 nm, it can also be activated at 630 nm (Waterfield *et al.*, 1994; Panjehpour *et al.*, 2002). In the present study, because of the thickness of the rat uterus, activation at a wavelength of 630 nm is desirable, since deeper penetration at 690 nm is not necessary. The drug becomes effective within minutes after injection and it is rapidly eliminated within 24 h from the tissues, resulting in a skin photosensitivity that lasts <2 days in general (Richter *et al.*, 1993). In a previous study, we showed that by using tin ethyl etiopurpurin as a photosensitizer we could target the vasculature using a short drug–light interval, resulting in effective photodynamic

therapy (Major *et al.*, 1999a;b). In the present study, we decided to evaluate the structural effect of PDT with a second-generation dye BPD-MA (verteporfin) on the rat uterus by using it in an intravenous injection and with a short drug–light interval of 5 min. This short drug–light interval was chosen based on animal studies showing the great specificity of BPD-MA in targeting the neovasculature when used at a short drug–light interval (Fingar *et al.*, 1999; Major *et al.*, 1999b). In addition, we also planned to determine the optimal concentration of this drug required for selective endometrial tissue destruction.

Materials and methods

Thirty-two female Sprague–Dawley rats weighing 250–350 g were placed in a controlled environment with free access to food and water. The guidelines for animal care and use were approved by the ethics committee of the University Hospital of Geneva and the veterinarian's office of the Canton of Geneva (no. 31.1.1041/2035/l). Verteporfin (Visudyne™; Novartis Pharmaceuticals, Inc., Basel, Switzerland) was used for this study. Rats were anaesthetized by i.m. injection of ketamine (80 mg/kg) and xylazine (10 mg/kg). A catheter through the jugular vein was used to administer the drug, which was diluted in 5% dextrose. We divided our rats into six groups, four in each group, depending on the dose of verteporfin: group I (2 mg/kg), group II (1 mg/kg), group III (0.5 mg/kg), group IV (0.25 mg/kg), group V (0.125 mg/kg) and group VI (0.0625 mg/kg). In addition, eight rats that received NaCl (0.9%) were used as negative controls. Five minutes after drug injection, PDT was carried out. A 3 cm midline incision through the lower abdomen was used to introduce an optical fibre connected to a diode laser operating at 630 nm (Diomed, Cambridge, UK). The light applicator was fitted snugly into the left uterine horn superior to the bifurcation of the uterus. The right horn (control) was shielded from light with gauze soaked with physiological saline kept at body temperature. The light was delivered to the uterine cavity via a 3 cm long, 1.2 mm diameter FLEX DIFFUSER (model FX1; Miravant, Santa Barbara, CA, USA) at a rate of 100 mW/cm of fibre, and the time of exposure was 500 s, resulting in a rate of 120 J/cm²; this was the same for all rats. The abdomens were sutured and the animals returned to their cages. Based on numerous studies showing that major histological changes of the rat endometrium after PDT can be seen as early as 1 day after and remain unchanged 4 days later (Major *et al.*, 1999a; 2002), a 4-day interval between laser exposure and histological examination was chosen. Rats were first anaesthetized with isoflurane (3%) and then euthanized by intracardiac injection of KCl solution (15%). The rat uteri were placed in 4% formaldehyde for fixation and then cut for processing. The specimens were embedded in paraffin and stained with haematoxylin and eosin (HE). The sections were examined by light microscopy. In each rat, HE sections of the left horn were compared with the right horn (internal control). The endometrial glands were counted on a complete cross section at three different levels from the untreated horn and treated uterine horns. The myometrium thickness was measured with a light microscope with a calibrated ocular scale. Measurements of the myometrium from the three ideal cross-sections were registered from the treated and untreated uterine horns. The presence or absence of acute inflammation, as defined by the presence of polynuclear segmented neutrophils seen in the endometrial stroma, was also recorded.

Statistical analysis

Comparisons between the treated and the untreated sides were performed using Student's paired *t*-test for continuous variables (number of glands and myometrium thickness, averaged over three measures for each data point) and Wilcoxon signed-rank test for the binary variable (inflammation status). When the overall differences of continuous response variables were statistically significant, we performed multiple comparisons for each verteporfin concentration while adjusting the appropriate significance levels according to Bonferroni's correction (*P* threshold becomes 0.05/6 = 0.0083). As there were not enough observations to fulfil ANOVA assumptions, we checked for the equality of distribution of the response variables among the different levels of verteporfin concentrations using the Kruskal–Wallis test. Possible trends in dose-effects were evaluated using linear regression with the continuous response measures as the

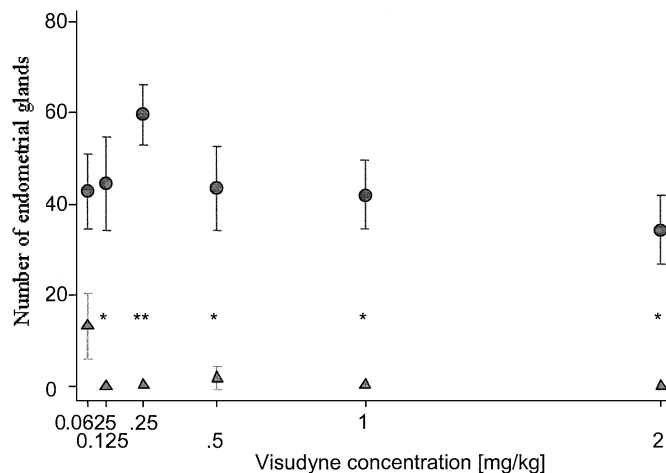


Figure 2. Median and interquartile range for the number of glands between the untreated uterine horn and treated horn in each of the six treatment groups. *P* values after Bonferroni's correction: **P* < 0.008; ***P* < 0.001. Circles represent the untreated horn and triangles the treated horn.

dependent variables and the verteporfin concentration as the predictor. A non-parametric test for trend across ordered group was applied to evaluate the effect of verteporfin concentration on the inflammation status.

Results

On histological examination, there was glandular destruction and myometrial loss in the uterine horns of all rats. We also noticed changes in the wall of the blood vessels with fibrinoid necrosis of the intima and thrombotic occlusions in some of the lumens. In addition, we noted the presence of acute inflammatory cell infiltrates in the endometrial stroma. However, these histological findings differed in the degree of severity depending on the verteporfin dosage (Figure 1A–D). We found a statistically significant difference in the number of endometrial glands between the treated and the untreated horns in all six groups (*P* < 0.0001; Figure 2). When we compared the number of glands between the untreated and treated uterine horns of each rat in all of the six groups, there were significant differences between each of the six groups. However, when taking into consideration all the multiple comparisons, by applying Bonferroni's correction to the *P* values (meaning significance was now accepted when *P* < 0.0083), the group of rats that maintained a significant *P* value were groups I (*P* < 0.0079), II (*P* = 0.0045), III (*P* = 0.0028), IV (*P* = 0.0009) and V (*P* = 0.0050), but not group VI (*P* = 0.0190). In addition, the most evident difference in the number of glands was observed in group IV, as seen in Figure 2. Figure 3 shows the difference in myometrium thickness measured in the untreated and the treated horn of each rat of the six groups. After Bonferroni's correction, a significant difference was seen in groups I (*P* = 0.0070) and II (*P* = 0.0086), but not in groups III (*P* = 0.0100), IV (*P* = 0.0449), V (*P* = 0.0142) and VI (*P* = 0.1849). As for acute inflammatory cells (AIC), they were present in all three measurements (cross section) in groups I and II. In group III, one rat had AIC in one measurement, one rat had AIC in two

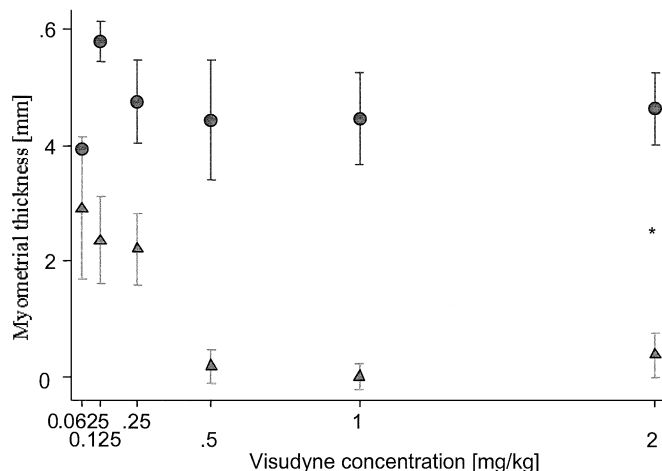


Figure 3. Median and interquartile range for the myometrium thickness measured in the untreated and the treated horn in each of the six treatment groups. *P*-value after Bonferroni's correction: **P* < 0.008. Circles represents the untreated horn and triangles the treated horn.

measurements and two rats had AIC in three measurements. No AIC were registered in any of groups IV, V or VI. In addition, during macroscopic organ dissection we noted adherence of the colon to rat uteri in groups I and II, without organ perforation.

In contrast, the uteri in the control rats and the right untreated horn of each of the 24 rats conserved a normal histology with neither endometrial destruction nor myometrial loss (Figure 1E).

Discussion

Hysterectomy has been considered the treatment of choice for women suffering from dysfunctional uterine bleeding. However, in a substantial percentage of patients, hysterectomy results in morbidity and mortality, leading to a total health cost exceeding US\$5 billion in the USA (Lee *et al.*, 1984; Carlson *et al.*, 1993). Thus, an alternative treatment with fewer side effects and lower cost is needed, and PDT may well fit this profile. PDT has shown promising results in animal models using different photosensitizers, such as BPD-MA or ALA, with topical or systemic administration (Wyss *et al.*, 1994a;b; Gannon *et al.*, 1995; Fehr *et al.*, 1996a;b; Steiner *et al.*, 1996). Angiogenesis is observed not only in malignant tumours, but also occurs in organs such as the ovary and endometrium (Gargett and Rogers, 2001; Kurohane *et al.*, 2001). By binding to the low-density lipoprotein (LDL) receptors and internalization into the cells via the endocytotic pathway, verteporfin can act with a degree of selectively on tissues expressing a high density of LDL receptors. These tissues include those with rapidly proliferating cells such as tumours, proliferating endothelial cells and normal endometrial glands (Sayegh *et al.*, 1995; Renno and Miller, 2001). In addition, PDT can easily be accomplished with a device of very small diameter (≤ 2 mm), thus avoiding the necessity for anaesthesia (such a device was developed in collaboration with the Swiss Federal Institute of Technology). For these reasons, verteporfin-medi-

ated PDT appears to be the ideal means of endometrial ablation in the clinical settings.

Studies evaluating PDT in endometrial ablation have primarily used ALA as the photosensitizer, due to its rapid elimination from the tissue. These studies targeted mainly the cellular compartment (Wyss *et al.*, 1994b; Gannon *et al.*, 1995; Fehr *et al.*, 1996b; Steiner *et al.*, 1996). A few studies have evaluated the effect of BPD-MA-mediated PDT on endometrial tissue using topical application (Wyss *et al.*, 1994a; Hornung *et al.*, 1998). To the best of our knowledge, the present study is the first in which a second-generation photosensitizer, BPD-MA, was administered by i.v. injection followed by PDT only a few minutes after drug administration. We decided to give verteporfin by i.v. injection for two reasons, first to test its use and efficacy in this mode of administration and secondly to determine whether we can avoid intrauterine application, thus making it more practical in the clinical setting in future human application.

Verteporfin used by systemic injection proved to be very effective in endometrial glandular ablation at all concentrations. The optimal drug concentration, defined as that which causes total glandular destruction with minimal loss of the myometrial thickness and minimal inflammatory reaction, seemed to range from 0.25 to 0.125 mg/kg. The lowest dose (0.0625 mg/kg) used, despite the good conservation of the myometrial thickness, was not efficient for total glandular ablation. With the highest concentration (2 and 1 mg/kg), despite their efficacy on glandular destruction, a significant loss of myometrial thickness, severe inflammatory reaction and adherence of the adjacent organ to the uterus was recorded. Nevertheless, a total selectivity in terms of complete destruction of the endometrium without harm to the myometrium has not been observed in the rat model. However, this could have some advantage, as the destruction of a small proportion of the inner myometrium might avoid the possibility of endometrial regeneration. The long-term effect of verteporfin on endometrial ablation needs to be evaluated in further studies. In the human uterus, PDT provides a better chance of selective destruction of the endometrium while conserving the myometrium, due to its thickness. The rather thick myometrium will be protected from complete destruction, even in the absence of complete tissue PDT selectivity, by the penetration depth of the light being set at 630 or even at 690 nm.

In summary, using PDT shortly after verteporfin administration, thereby targeting the endometrial vasculature, results in endometrial ablation with high efficacy. Thus, this therapy may contribute to a new treatment modality for endometrial ablation. Further studies using different drug/light doses and intervals to increase the endometrial tissue selectivity are underway.

Acknowledgements

The authors would like to thank Jacques Belenger, Patrick Bonfils, Johannes Hauser and Michel Sickenberg for their excellent assistance throughout the study. We would like also to thank Ms Jacqueline Bouvier for her technical assistance, Elizabeth Tschanz, and Maryse Ivoll for her review of the manuscript. This work was supported in part by a grant from Roche Research Foundation Basel, Switzerland, by

the Swiss National Science Foundation, Bern, Switzerland, by the Fonds de Recherche, Geneva, Switzerland, by Karl Storz GMBH & Co KG, Tuttlingen, Germany and by Schering AG, Berlin, Germany. Research infrastructure was provided by the Fondation pour Recherches Medicales, Geneva, Switzerland.

References

- Allison, R., Mang, T., Hewson, G., Snider, W. and Dougherty, D. (2001) Photodynamic therapy for chest wall progression from breast carcinoma is an underutilized treatment modality. *Cancer*, **91**, 1–8.
- Bhatta, N., Anderson, R.R., Flotte, T., Schiff, I., Hasan, T. and Nishioka, N.S. (1992) Endometrial ablation by means of photodynamic therapy with photofrin II. *Am. J. Obstet. Gynecol.*, **167**, 1856–1863.
- Carlson, K.J., Nichols, D.H. and Schiff, I. (1993) Indications for hysterectomy. *N. Engl. J. Med.*, **328**, 856–860.
- Fehr, M.K., Tromberg, B.J., Svaasand, L.O., Ngo, P., Berns, M.W. and Tadir, Y. (1996a) Structural and functional effects of endometrial photodynamic therapy in a rat model. *Am. J. Obstet. Gynecol.*, **175**, 115–121.
- Fehr, M.K., Wyss, P., Tromberg, B.J., Krasieva, T., DiSaia, P.J., Lin, F. and Tadir, Y. (1996b) Selective photosensitizer localization in the human endometrium after intrauterine application of 5-aminolevulinic acid. *Am. J. Obstet. Gynecol.*, **175**, 1253–1259.
- Fehr, M.K., Hornung, R., Degen, A., Schwarz, V.A., Fink, D., Haller, U. and Wyss, P. (2002) Photodynamic therapy of vulvar and vaginal condyloma and intraepithelial neoplasia using topically applied 5-aminolevulinic acid. *Lasers Surg. Med.*, **30**, 273–279.
- Fingar, V.H., Kik, P.K. and Haydon, P.S. (1999) Analysis of acute vascular damage after photodynamic therapy using benzoporphyrin derivative (BPD). *Br. J. Cancer*, **79**, 1702–1708.
- Gannon, M.J., Johnson, N., Roberts, D.J.H., Holroyd, J.A., Vernon, D.I., Brown, S.B. and Lilford, R.J. (1995) Photosensitization of the endometrium with topical 5-aminolevulinic acid. *Am. J. Obstet. Gynecol.*, **173**, 1826–1828.
- Gargett, C.E. and Rogers, P.A.W. (2001) Human endometrial angiogenesis. *Reproduction*, **121**, 181–186.
- Henderson, B.W., Vaughan, D., Bellnier, D.A., Van Leengoed, H., Johnson, P.G. and Oseroff, A.R. (1995) Photosensitization of murine tumor, vasculature and skin by 5-aminolevulinic acid-induced porphyrin. *Photochem. Photobiol.*, **62**, 780–789.
- Hornung, R., Fehr, M.K., Tromberg, B.J., Major, A., Krasieva, T.B., Berns, M.W. and Tadir, Y. (1998) Uptake of the photosensitizer benzoporphyrin derivative in human endometrium after topical application in vivo. *J. Am. Assoc. Gynecol. Laparosc.*, **5**, 367–374.
- Kurohane, K., Tominaga, A., Sato, K., North, J.R., Namba, Y. and Oku, N. (2001) Photodynamic therapy targeted to tumor-induced angiogenic vessels. *Cancer Lett.*, **167**, 49–56.
- Lee, N.C., Dicker, R.C., Rubin, G.L. and Ory, H.W. (1984) Confirmation of the preoperative diagnoses for hysterectomy. *Am. J. Obstet. Gynecol.*, **150**, 283–287.
- Major, A.L., Tromberg, B.J., Kimel, S., Tuan Pham, M.S.E., Krasieva, T.B., Berns, M.W. and Tadir, Y. (1999a) Photodynamic therapy of the rat endometrium by systemic and topical administration of tin ethyl etiopurpurin. *J. Gynecol. Surg.*, **15**, 71–80.
- Major, A.L., Kimel, S., Mee, S., Milner, T.E., Smithies, D.J., Simivas, S.M., Chen, Z. and Nelson, J.S. (1999b) Microvascular photodynamic effects determined in vivo using optical doppler tomography. *IEEE J. Selected Top. Quantum Electron.*, **5**, 1168–1175.
- Major, A.L., Rose, G.S., Svaasand, L.O., Ludicke, F., Campana, A. and Van Gemert, M.J.C. (2002) Intraperitoneal photodynamic therapy in the Fischer 344 rat using 5-aminolevulinic acid and violet laser light: a toxicity study. *J. Photochem. Photobiol. B*, **66**, 107–114.
- Panjehpour, M., DeNovo, R.C., Petersen, M.G., Overholt, B.F., Bower, R., Rubinchik, V. and Kelly, B. (2002) Photodynamic therapy using Verteporfin (benzoporphyrin derivative monoacid ring A, BPD-MA) and 630 nm laser light in canine esophagus. *Lasers Surg. Med.*, **30**, 26–30.
- Renno, R.Z. and Miller, J.W. (2001) Photosensitizer delivery for photodynamic therapy of choroidal neovascularization. *Adv. Drug Deliv. Rev.*, **52**, 63–78.
- Richter, A.M., Waterfield, E., Jain, A.K., Canaan, A.J., Allison, B.A. and Levy, J.G. (1993) Liposomal delivery of a photosensitizer, benzoporphyrin derivative monoacid ring A (BPD), to tumor tissue in a mouse tumor model. *Photochem. Photobiol.*, **57**, 1000–1006.
- Sayegh, R.A., Tao, X.J. and Isaacson, K.B. (1995) Immunohistochemical localization of alpha-2 macroglobulin receptor/low-density lipoprotein receptor-related protein, receptor-associated protein, and Gp330 in the human endometrium. *J. Soc. Gynecol. Investig.*, **2**, 748–753.
- Sickenberg, M., Schmidt-Erfurth, U., Miller, J.W., Pourmaras, C.J., Zografos, L., Piguet, B., Donati, G., Laqua, H., Barbazetto, I., Gragoudas, E.S. et al. (2000) A preliminary study of photodynamic therapy using verteporfin for choroidal neovascularization in pathologic myopia, ocular histoplasmosis syndrome, angioid streaks, and idiopathic causes. *Arch. Ophthalmol. (Paris)*, **118**, 327–336.
- Steiner, R.A., Tadir, Y., Tromberg, B.J., Krasieva, T., Ghazains, A.T., Wyss, P. and Berns, M.W. (1996) Photosensitization of the rat endometrium following 5-aminolevulinic acid induced photodynamic therapy. *Lasers Surg. Med.*, **18**, 301–308.
- Waterfield, E.M., Renke, M.E., Smits, C.B., Gervais, M.D., Bower, R.D., Stonefield, M.S. and Levy, J.G. (1994) Wavelength-dependent effects of benzoporphyrin derivative monoacid ring A in vivo and in vitro. *Photochem. Photobiol.*, **60**, 383–387.
- Wyss, P., Tadir, Y., Tromberg, B.J., Tromberg, B.J., Liaw, L., Krasieva, T. and Berns, M.W. (1994a) Benzoporphyrin derivative: a potent photosensitizer for photodynamic destruction of rabbit endometrium. *Obstet. Gynecol.*, **84**, 409–414.
- Wyss, P., Tromberg, B.J., Wyss, M.T., Krasieva, T., Schell, M., Berns, M.W. and Tadir, Y. (1994b) Photodynamic destruction of endometrial tissue with topical 5-aminolevulinic acid in rats and rabbits. *Am. J. Obstet. Gynecol.*, **171**, 1176–1183.

Submitted on February 19, 2003; resubmitted on April 11, 2003; accepted on May 8, 2003