

Ultrasound Measurement of the Fibrous Cap in Symptomatic and Asymptomatic Atheromatous Carotid Plaques

Gérald Devuyst, MD; Patrick Ruchat, MD; Theodoros Karapanayiotides, MD; Lisa Jonasson, MS; Olivier Cuisinaire, PhD; Johannes-Alexander Lobrinus, MD; Marc Puztaszeri, MD; Askenadios Kalangos, MD; Paul-André Despland, MD; Jean-Philippe Thiran, PhD; Julien Bogousslavsky, MD

Background—Fibrous cap thickness (FCT) is an important determinant of atheroma stability. We evaluated the feasibility and potential clinical implications of measuring the FCT of internal carotid artery plaques with a new ultrasound system based on boundary detection by dynamic programming.

Methods and Results—We assessed agreement between ultrasound-obtained FCT values and those measured histologically in 20 patients (symptomatic [S]=9, asymptomatic [AS]=11) who underwent carotid endarterectomy for stenosing (>70%) carotid atheromas. We subsequently measured in vivo the FCT of 58 stenosing internal carotid artery plaques (S=22, AS=36) in 54 patients. The accuracy in discriminating symptomatic from asymptomatic plaques was assessed by receiver operating characteristic curves for the minimal, mean, and maximal FCT. Decision FCT thresholds that provided the best correct classification rates were identified. Agreement between ultrasound and histology was excellent, and interobserver variability was small. Ultrasound showed that symptomatic atheromas had thinner fibrous caps (S versus AS, median [95% CI]: minimal FCT=0.42 [0.34 to 0.48] versus 0.50 [0.44 to 0.53] mm, $P=0.024$; mean FCT=0.58 [0.52 to 0.63] versus 0.79 [0.69 to 0.85] mm, $P<0.0001$; maximal FCT=0.73 [0.66 to 0.92] versus 1.04 [0.94 to 1.20] mm, $P<0.0001$). Mean FCT measurement demonstrated the best discriminatory accuracy (area under the curve [95% CI]: minimal 0.74 [0.61 to 0.87]; mean 0.88 [0.79 to 0.97]; maximal 0.82 [0.71 to 0.93]). The decision threshold of 0.65 mm (mean FCT) demonstrated the best correct classification rate (82.8%; positive predictive value 75%, negative predictive value 88.2%).

Conclusions—FCT measurement of carotid atheroma with ultrasound is feasible. Discrimination of symptomatic from asymptomatic plaques with mean FCT values is good. Prospective studies should determine whether this ultrasound marker is reliable. (*Circulation*. 2005;111:2776-2782.)

Key Words: ultrasonics ■ plaque ■ carotid arteries ■ atherosclerosis ■ cerebrovascular disorders

Until recently, atherosclerosis was considered a progressive disease that ultimately led to “hydraulic” failure. We now have sufficient evidence to consider atherosclerosis a chronic inflammatory disease that leads to an acute clinical event through plaque rupture and thrombosis, rather than an inevitable degenerative process as a consequence of aging. A new concept, which first emerged in acute coronary syndromes, is that of the “unstable” or “vulnerable” atherosclerotic plaque.¹ The frequency of unstable atheroma may be underestimated and their presentation is variable, ranging from erosion to fissure and rupture with focal defects of large areas. Nowadays, cardiologists attribute acute coronary syndromes to rupture of lipid-laden atheroma with thin fibrous

caps (FCs), because most of these plaques are not hemodynamically significant before rupture.¹

The concept of atheroma instability is currently applied in neurology to explain artery-to-artery embolism that originates from the internal carotid artery (ICA).² On histological examination,³ occluding thrombi have been found in the carotid arteries in the absence of plaques that cause flow-limiting stenosis. In patients dying after acute ischemic stroke, the presence of thrombus in the ICAs is associated with carotid plaque rupture, a thin FC, and inflammation.^{4–6} In other series,^{7,8} patients with symptomatic ICA stenosis had a higher frequency of plaque rupture, FC thinning, and FC foam-cell infiltration compared with the asymptomatic group.

Received June 8, 2004; revision received January 25, 2005; accepted February 22, 2005.

From the Department of Neurology (G.D., T.K., P.-A.D., J.B.), Division of Neuropathology (J.-A.L., M.P.), and Department of Cardiovascular Surgery (P.R.), Centre Hospitalier Universitaire Vaudois, Lausanne, Switzerland; Signal Processing Institute (L.J., O.C., J.-P.T.), Swiss Federal Institute of Technology, Lausanne, Switzerland; and Department of Cardiovascular Surgery, Geneva University Hospital (A.K.), Geneva, Switzerland.

Correspondence to Gérald Devuyst, MD, Department of Neurology, Centre Hospitalier Universitaire Vaudois, Rue du Bugnon 46, 1011 Lausanne, Switzerland. E-mail gerald.devuyst@chuv.hospvd.ch

© 2005 American Heart Association, Inc.

Circulation is available at <http://www.circulationaha.org>

DOI: 10.1161/CIRCULATIONAHA.104.483024

Up to now, in vivo diagnosis of FC thinning in symptomatic patients with ICA stenosis was not possible. Such an approach requires an imaging technique that is noninvasive and reliable, allows regular control to assess the evolution of atherosclerotic carotid plaques, and is relatively inexpensive. Noninvasive techniques for the assessment of arterial wall pathology, such as CT angiography⁹ and MRI,¹⁰ are under evaluation. Developments in ultrasound such as high-resolution B-mode imaging, compounded imaging, measurement of shear stress, characterization of plaque motion, and 4D color Doppler flow imaging are promising diagnostic tools for carotid wall disease.¹¹ We evaluated the feasibility of measuring the FC thickness (FCT) of stenosing ICA plaques with a new semiautomated ultrasound system and investigated whether the obtained values could be used to discriminate symptomatic from asymptomatic atheromata.

Methods

Study Design

We validated our method in 22 patients with ICA stenosis (9 symptomatic patients) who underwent carotid endarterectomy by comparing FCT values obtained preoperatively by ultrasound with those measured on the endarterectomy specimens. The neuropathologist (JAL) was blinded to clinical and ultrasound data. Two investigators (GD, OC), blinded to each other's results, performed separate ultrasound measurements 24 hours before surgery on each of the 20 patients. One week before surgery, one of the investigators (GD) performed measurements for each patient for which FCT values were stored but were not accessible to the examiner during or after the examination. An experienced technologist who had never performed FCT measurements was trained and subsequently performed FCT assessment (steps 2 to 4 below) based on the cine-loops (step 1) acquired previously by the investigators from the same 20 patients.

We subsequently recruited consecutive patients with transient ischemic attack or ischemic stroke who were admitted to our department and in whom ultrasound examination within 12 hours after admission showed >70% ipsilateral ICA stenosis. The control group consisted of subjects who underwent exploration for carotid bruits, preoperative screening for heart surgery, or screening for cerebrovascular risk factors, in whom asymptomatic >70% ICA stenosis was found. The degree of ICA stenosis was assessed according to established criteria¹² and was always confirmed by magnetic resonance angiography. Patients with ICA occlusion detected by both ultrasound and magnetic resonance angiography were excluded from the study. All ultrasound investigations were performed by 2 authors (GD, TK). Raw data were saved, and 3 months after the end of the recruitment period, data were processed and FCT was evaluated by 2 authors (GD, OC) blinded to the history of the patient and to each other. To ensure blindness, raw data obtained by GD were subsequently processed by OC, whereas data obtained by TK were processed by GD. The study was approved by the review committee of our institution, and all subjects gave informed consent.

Histology

Endarterectomy specimens were obtained after surgery and fixed in 4% buffered formalin solution. The entire stenotic region located at the bifurcation and the proximal ICA was then decalcified to facilitate specimen sectioning. Subsequently, 3- to 4-mm-thick transverse segments were cut and embedded in paraffin blocks. Two or 3 blocks were obtained for each specimen. From these blocks, a total of 1016 (mean 51, range 31 to 88) transverse histological sections 250 μ m thick were obtained and stained with hematoxylin-eosin and elastica van Gieson. Sections within the site of tightest arterial stenosis were digitized and used for FCT measurement (Figure 1). A total of 247 sections from 20 patients were digitized

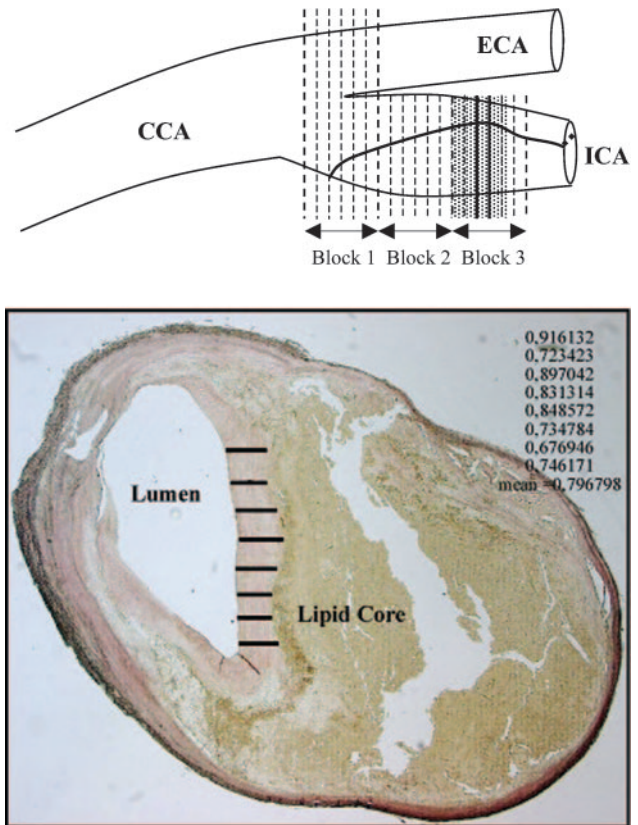


Figure 1. Method of histological measurement of FC. Top, Specimen was embedded in 3 paraffin blocks, and transverse sections 250 μ m thick were obtained from each block (vertical dotted lines). Sections exhibiting site of tightest lumen stenosis (shaded area) were digitized, and for each digitized section, multiple FCT measures were performed with simple length-measurement computer system. Three to 10 FCT measurements were performed for each section depending mainly on size of FC. Bottom, Digitized section corresponding to most stenotic region (between 2 solid vertical lines). In this section, 8 measurements were performed (horizontal solid lines); corresponding values and mean FCT are demonstrated. White crescent in middle of lipid core is disruption artifact (elastica Van Gieson). CCA indicates common carotid artery; ECA, external carotid artery.

(mean 18, range 9 to 25). FCT measurements were performed with a simple length-measurement computer system. Measurements were taken at regular intervals ranging from 150 to 200 μ m and were restricted to regions with clear demarcation of the FC-lipid core interface. For each section, 3 to 10 FCT measurements were performed (Figure 1). The number of FCT measurements fluctuated for each section due to the complex morphology of carotid atherosclerotic plaques (size, shape, and demarcation of the FC-lipid core interface differed substantially among cases). The total number of FCT measurements per specimen ranged from 9 to 198 (mean 115). For each section, a minimal, maximal, and mean value was obtained. The arithmetic mean of the minimal values obtained from each section for a given specimen was considered the minimal FCT for the patient. The same method was applied for the maximal FCT. Finally, the arithmetic mean of all measures for every specimen was obtained.

Ultrasound Technology

In each patient, we performed high-resolution B-mode imaging, color Duplex flow imaging (CDFI), and power Duplex imaging using an ATL 5000 Advanced ultrasound instrument (Phillips

Medical Systems SA) equipped with a large broadband linear probe of 5 to 12 MHz, which has an axial resolution of 300 μm and a lateral resolution of 400 μm . The procedure to explore the FC was very strict and consisted of 4 steps. In the first step, the sonographer saved a cine-loop that contained 150 to 200 frames that documented the atherosclerotic plaque responsible for the ICA stenosis. The cine-loop was then transferred to a personal computer equipped with software (HDI Laboratory, Phillips Medical Systems SA) capable of analyzing each of the frames saved. In the second step, the sonographer selected the CDFI frame that best demonstrated the ICA stenosis and the residual arterial lumen (Figure 2A). The third step consisted of working on the same frame selected previously, but this time in high-definition B-mode (Figure 2B), because in this mode, we obtain far better resolution than in CDFI, and because in CDFI, the FC is frequently obscured by the "blooming artifact." The fourth step consisted of a semiautomated computational procedure to measure FCT.

Ultrasound System for the Measurement of FCT

The FC was defined as a hyperechogenic structure that on CDFI and high-resolution B-mode imaging displayed stronger echoes than the atheromatous carotid plaque on contact with the circulating blood (anechogenic).¹¹ The FC covered an area of weaker echoes that corresponded to lipid accumulation (lipid core). We have developed a system that finds the 2 paths within a specified area that best follow the hypoechogenic-hyperechogenic and hyperechogenic-hypoechogenic boundaries and then measures the distance between them (Figure 2C). The user defines 2 points that specify the exact horizontal location of the paths and the approximate vertical location of the FC. Two boundaries are then detected automatically as the optimal path between the 2 markers with respect to intensity gradient and smoothness. The boundary facing the arterial lumen marks the calculated transition from the hypoechogenic to the hyperechogenic region; the boundary facing the lipid core marks the calculated transition from the hyperechogenic to the hypoechogenic region. If the user is not satisfied with the results, manual corrections can be made by inserting additional restriction points to change the direction of the paths (Figure 2D). Finally, the thickness, defined as the structure between these 2 echogenic lines, is calculated pixel by pixel along the restriction points, and mean, maximal, and minimal FCT values can be obtained simultaneously. Boundary detection is performed with dynamic programming.^{13,14} This is a method that efficiently tries all paths between 2 points and selects the optimal one, ie, the path that optimizes a specified criterion. In our case, this criterion was a weighted sum of several terms. The first one rewards a vertically high-intensity gradient; this term is then weighted according to the method published by Liang et al.¹³ The second term favors a smooth curve: if 2 horizontally adjacent points on the path have a large vertical separation, these points will be penalized by giving the cost term a higher value. The last 2 terms constrain the path to remain close to the manually marked restriction points. A point on the path lying horizontally close to but vertically far from a restriction point will be penalized. There are 2 terms for the restriction points because the vertical influence of the 2 extreme restriction points that define the length of the path is smaller than that of potential additional points set to guide the internal direction of the path.

Statistical Analyses

Agreement between ultrasound and histology for FCT values, interobserver agreement, and repeatability of the method were assessed by Bland-Altman analysis. Fisher exact test for dichotomous variables and 2-sample *t* test for continuous variables were used for the comparison of baseline characteristics between subjects with symptomatic and asymptomatic plaques. The Mann-Whitney test was used for comparison of FCT between the 2 groups. The accuracy of the method in discriminating symptomatic from asymptomatic plaques was assessed by receiver operating characteristic curves for the minimal, mean, and maximal FCT measurement. Bootstrap CIs were calculated for the cutoff points (decision FCT thresholds) that provided the best correct classification rates.

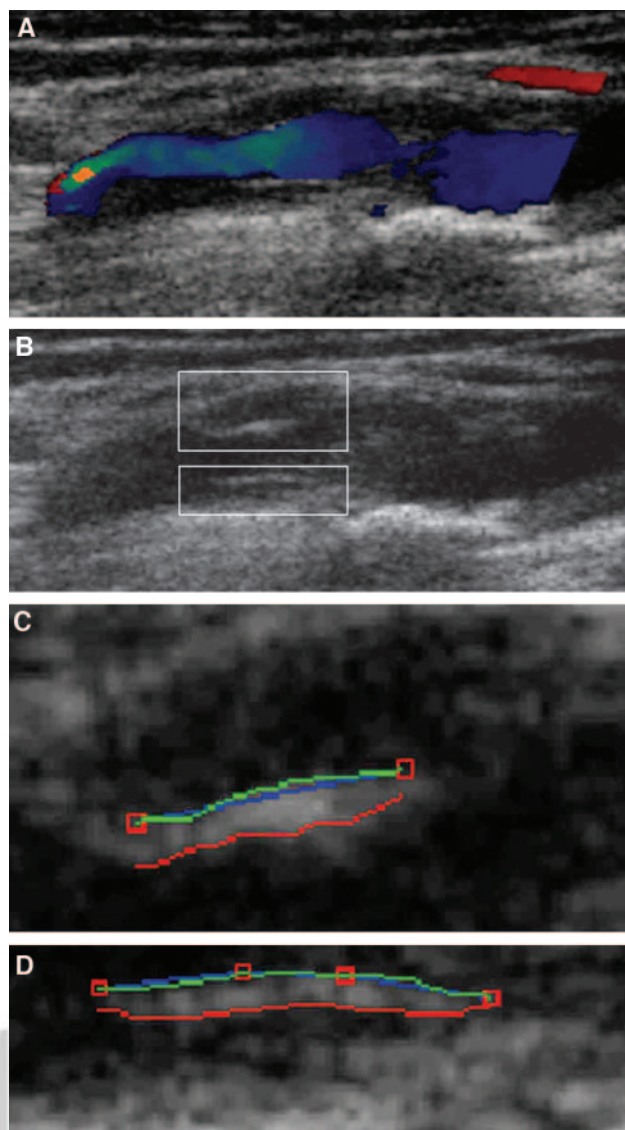


Figure 2. Steps of FCT measurement. A, Sonographer identifies CDFI frame that best depicts plaque with residual arterial lumen. B, Color is removed. On this high-resolution B-mode frame, concentric plaque with its FC can be identified on near (upper white frame) and far (lower white frame) arterial wall. C, Magnification of upper white frame (near wall). User defines 2 markers (red squares) that specify exact horizontal location of paths and approximate vertical location of FC. Blue line is interpolation between adjacent markers. Two boundaries are detected automatically: red line marks calculated transition from arterial lumen to FC, green line marks calculated transition from FC to lipid core. D, Magnification of lower white frame (far wall). Same procedure is repeated, but now green line is facing arterial lumen and red line is facing lipid core. Two additional restriction points were inserted manually to change direction of paths.

Results

The endarterectomy specimen of 1 patient unfortunately had undergone extensive surgical manipulation and was not judged appropriate by the pathologist for reliable assessment of the FC. In another patient, FC measurement was not possible because of intense calcifications with acoustic shadowing. Agreement between histology and ultrasound was excellent for the mean and maximal FCT and fair for the

TABLE 1. Agreement Between Ultrasound and Histology and Between Different Observers

	Agreement, Mean Difference % (Limits of Agreement) (n=20)		
	Minimal FCT	Mean FCT	Maximal FCT
Histology vs ultrasound	-3.4% (-15.3% to 8.1%)	-1.4% (-5.8% to 3.1%)	-1% (-3.2% to 1.3%)
Interobserver (author GD vs author OC)	-2.6% (-8% to 3.6%)	-2.1% (-7.5% to 3.5%)	-1.8% (-7.1% to 4.3%)
Intraobserver (author GD)	-0.8% (-6% to 5.1%); repeatability=21 μm	-0.7% (-4.6% to 4.3%); repeatability=22 μm	-0.9% (-4.1% to 2.9%); repeatability=25 μm
Interobserver (author GD vs technologist)	-4.8% (-8.8% to 5.3%)	-3.6% (-8.4% to 4.9%)	-2.7% (-7.9% to 4.8%)
Intraobserver (technologist)	-1.5% (-6.1% to 5.3%); repeatability=29 μm	-1.6% (-6.6% to 5.3%); repeatability=25 μm	-1.1% (-5.1% to 4.1%); repeatability=23 μm

minimal FCT; interobserver (GD versus OC) and intraobserver (GD) agreement for the method was very good (Table 1; Figure 3). Interobserver agreement between the technologist and GD and intraobserver agreement for the technologist was good (Table 1).

We studied 62 ICA plaques (S=23, AS=39) in 58 consecutive patients. After data processing, FCT evaluation was not possible in 4 patients (S=1, AS=3) due to technical problems related to the morphology of the plaque ie, intense calcifications with acoustic shadows (2 cases) or FC too thin

to measure (2 cases). Manual corrections with insertion of one to three additional restriction points were judged necessary in 32% of the cases. The baseline characteristics of the symptomatic and asymptomatic patients did not differ (Table 2). Twenty patients had an ischemic stroke, 1 had a hemispheric transient ischemic attack, and another had amaurosis fugax.

The obtained values of the minimal, mean, and maximal FCT for symptomatic and asymptomatic atheroma are depicted in Figure 4. Symptomatic plaques had thinner FCs for

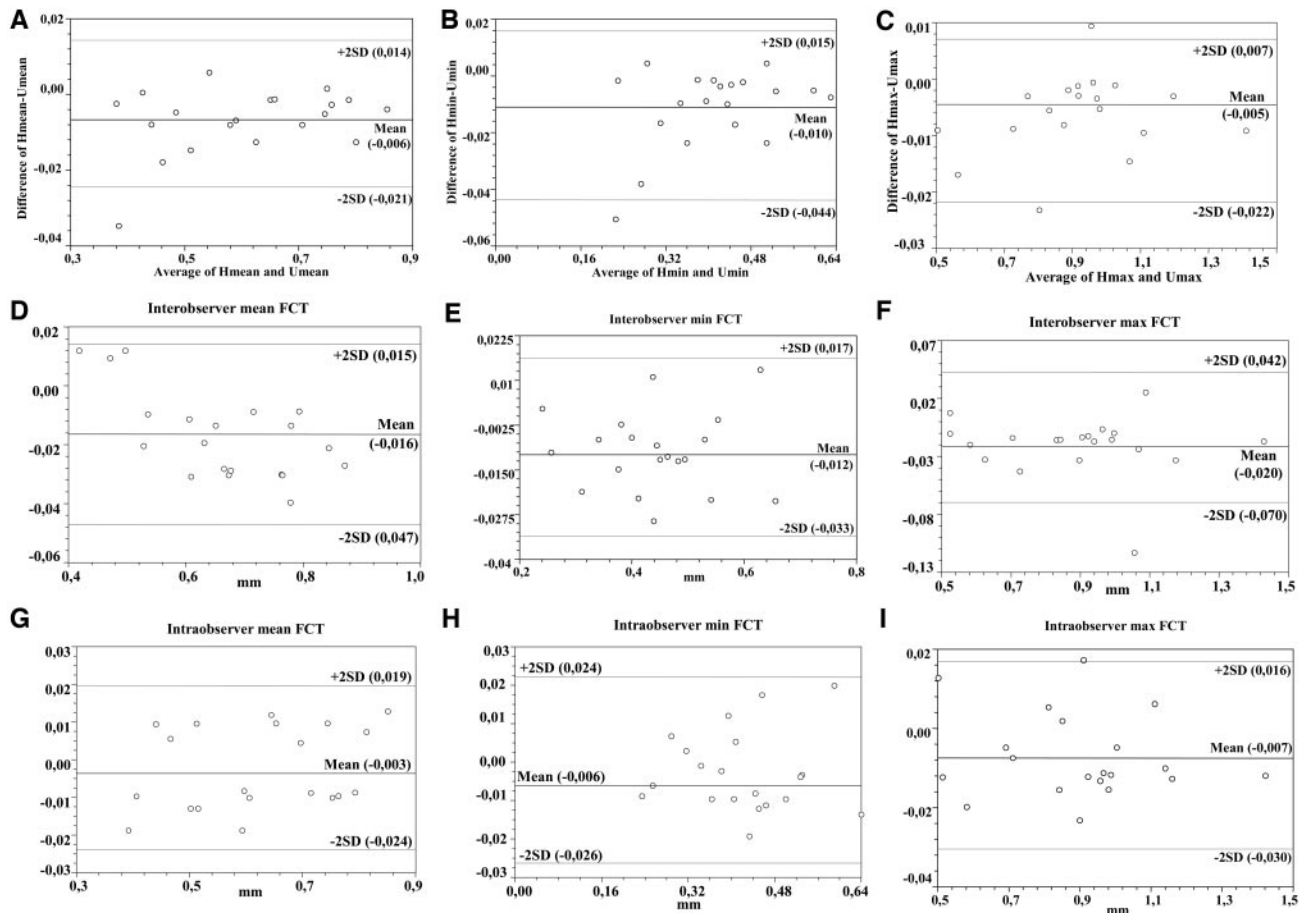


Figure 3. A-C, Bland-Altman graphs with limits of agreement between FCT values (in mm) measured by histology (H) and those obtained from ultrasound (U). For each 20 patients, difference between FCT values obtained by the 2 methods (H-U) is plotted against their average [(H+U)/2]. Graphs for mean (A), minimal (B), and maximal (C) FCT are depicted. D-I, Limits of interobserver (D-F) and intraobserver (G-I) agreement for FCT measurement by ultrasound (n=20). min indicates minimal; max, maximal.

TABLE 2. Baseline Variables of Patients With Symptomatic and Asymptomatic ICA Plaques

Variable	Symptomatic, % (n=21)*	Asymptomatic, % (n=32)	P
Age (mean±SD), y	68±7	71±5	NS
Male sex	56	59	NS
Hypertension	68	70	NS
Diabetes mellitus	16	16	NS
Smoking	84	76	NS
Hypercholesterolemia (>6.5 mmol/L)	64	62	NS
Stenosis >90%	24	22	NS

*One patient with an asymptomatic stenosis of the contralateral ICA is not included.

all kinds of measurements. As depicted by the receiver operating characteristic curves (Figure 5), our method obtains a fair discrimination of symptomatic from asymptomatic plaques when measurement of the minimal FCT is performed (median area under the curve [95% CI] 0.74 [0.61 to 0.87]) and a good discrimination for maximal (0.82 [0.71 to 0.93]) and mean (0.88 [0.79 to 0.97]) FCT measurement. The FTC cutoff points that provided the best correct classification rate of symptomatic plaques were 0.647 mm for mean FCT, 0.924 mm for maximal FCT, and 0.458 mm for minimal FCT (Table 3). The number of pixels that were analyzed to calculate FCT was higher in asymptomatic than in symptomatic plaques (55±11.2 versus 90±15.1; $P<0.003$, Mann-Whitney test).

Discussion

There is growing evidence that the concept of “unstable” plaques is also applicable to carotid atheroma. The relative rarity of borderzone infarcts and the observation of emboli in the retina of patients with amaurosis fugax suggest that plaque rupture may play an important role in brain embolism.¹⁵ Considerable attempts have been made to predict the occurrence of stroke by classifying carotid plaques according to their composition. Whether differences in plaque echogenicity or surface morphology can predict the clinical expres-

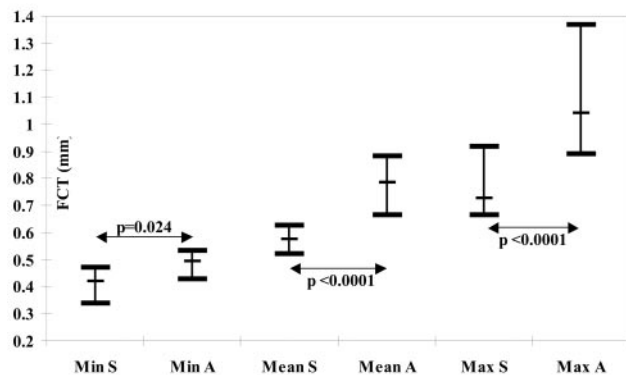


Figure 4. Graph depicting median with quartiles of measured values for minimal (min), mean, and maximal (max) FC thickness in symptomatic (S) and asymptomatic (A) internal carotid plaques. Mann-Whitney probability values are illustrated.

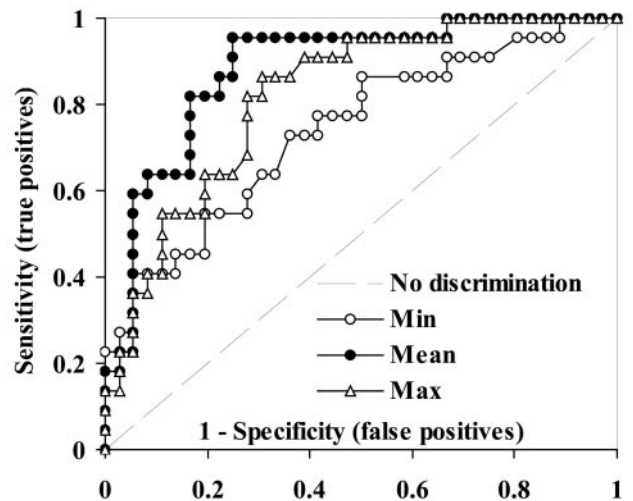


Figure 5. Receiver operating characteristic curves for minimal (min), mean, and maximal (max) FCT measurements. Area under curve measures discrimination, that is, ability to correctly classify symptomatic from asymptomatic plaques. Area of 1 represents perfect test; area of 0.5 represents worthless test. Best discrimination is achieved by measuring mean FCT and worst (but still fair) by measuring minimal FCT.

sion of atheroma is still debated.¹¹ Recent studies have shown that high-resolution MRI can visualize FCT and rupture in vivo.¹⁰ However, the availability of this technique is currently very limited, and the data obtained are qualitative and not quantitative.¹⁰ The present study shows that with the development of a semiautomated system to treat B-mode imaging, we can accurately measure the FCT of carotid plaques. The only 2 manual steps in the procedure are the selection of the CDFI frame to which automated FCT measurement will be applied and the selection of 2 points that specify the location of the paths plus additional restriction points in a third of the cases. This is not difficult for an experienced sonographer, although we must always bear in mind that ultrasound examination is observer dependent. The best compromise must take into consideration both the central and lateral parts of the FC. Caution must also be exercised when one deals with concentric stenoses, because the atheroma with its FC is often visible on both the near and far arterial walls (Figure 2B).

The results of the present study suggest an encouraging correlation between FCT and the clinical expression of carotid atheroma. Symptomatic plaques had much thinner FCs than asymptomatic ones, and this held true regardless of the type of FCT measured (minimal, mean, or maximal). Mean FCT measurement discriminates symptomatic from asymptomatic atheroma well, although not perfectly, with a cutoff value of 0.65 mm attaining the best correct classification rate. The reason that minimal FCT performs the worst in terms of discrimination is that measured values are quite close to the axial resolution of the ultrasound instrument. This was also reflected in the inferior (yet sufficient) degree of agreement between histology and ultrasound for minimal FCT values compared with maximal and mean values.

Attempts to explore the surface of atheromatous carotid plaques with B-mode ultrasonography have already been

TABLE 3. Suggested Cutoff FTC Values for Detection of Symptomatic ICA Plaques

	Minimal FTC	Mean FTC	Maximal FTC
Decision threshold (95% CI),* mm; bootstrap SE	0.458 (0.446–0.471); 0.007	0.647 (0.639–0.654); 0.004	0.924 (0.912–0.935); 0.006
Sensitivity (95% CI),* %; bootstrap SE	72.7 (68.4–77.0); 2.21	81.8 (78.2–85.4); 1.84	77.3 (72.2–82.4); 2.6
Specificity (95% CI),* %; bootstrap SE	63.9 (59.4–68.4); 2.28	83.3 (79.4–87.3); 2.03	72.2 (69.8–74.7); 1.24
Positive predictive value, %	55.2	75	64.3
Negative predictive value, %	79.3	88.2	86.7
Correct classification rate, %	67.2	82.8	75.9

*Bootstrap CIs (1000 iterations).

made with relatively little success.¹⁶ A recent interesting study comparing carotid endarterectomy specimens with preoperative carotid ultrasound results found that the best factors for characterization of carotid plaques were thinning and rupture of the FC¹⁷; however, that study treated FCT as a dichotomous variable (thin: <1 mm, thick: >1 mm), did not focus on FCT measurement, and was performed with an ultrasound probe of 7.5 MHz.

The method of FTC measurement used in the present study has certain limitations. First, there is a contrast-resolution limitation in B-mode; even though modern ultrasound instruments have an axial resolution that ranges from 200 to 600 μm , in a few cases, it is impossible to measure the FC, which is too thin. Similar difficulties are present for calcified or very fibrotic plaques, particularly in cases with complete acoustic shadowing. Second, there is a geometric-resolution limitation; at the moment, we measure structures with a size very close to or even smaller than the maximal resolution of the ultrasound instrumentation that we are using. We therefore run the risk that the FC will be melted together with the background or with other close structures. Ultrasound also has a tendency to shift toward the weaker echo side,¹⁸ which, in the present case, would lead to an artificial enlargement of the FCT because the cap was surrounded by weaker echoes on either side of it (blood in the arterial lumen, and the lipid core). Thus, the FCT value that we measured may be an overestimation of the actual FCT; however, as shown by our validation study, agreement between ultrasound and histology was excellent for maximal and mean FCT, which confirms that the distance measured between the hypoechogenic-hyperechogenic and hyperechogenic-hypoechogenic interface actually corresponds to the FC.

Third, there are problems posed by acoustic anisotropy: the appearance of features will change depending on the angle of insonation, and tissue interfaces may not be well seen unless the ultrasound beam is perpendicular to the interface. Because we measured FCT on a single frame at the region of maximal lumen narrowing, we obtained far better visualization of the central part of the plaque than of its shoulder regions in $\approx 80\%$ of our cases. One could state that plaques having caps that are thick over much of the necrotic core yet thinned (and perhaps prone to rupture) over the shoulder regions may have been misclassified as stable because of inadequate visualization of the distal and trailing ends of the plaque; however, in contrast to the coronaries, carotid plaque rupture appears to occur mostly at the midportion of the plaque rather than at the shoulder area.⁷ Moreover, luminal surface changes have been

shown to occur in the most severely stenotic regions of both symptomatic and asymptomatic carotid plaques, with surface irregularities being notably absent in areas of the plaque distant from the stenosis.¹⁹ A 3D ultrasound technique would probably allow a thorough assessment of the cap. However, 3D ultrasound is not widely available; different techniques and transducers are still under development; it has a clearly inferior axial resolution compared with 2D ultrasound, which is crucial for FCT assessment; it cannot overcome acoustic shadowing and artifacts present in 2D images; and it is further limited by swallowing and respiration artifacts.²⁰ Our purpose was to develop an imaging method applicable to everyday practice and not another research tool with limited clinical applicability.

Fourth, the hypoechogenic structure just beneath the FC was presumed to be the lipid core of the plaque. The only other case in which a structure just beneath the plaque could appear hypoechogenic would be that of an intraplaque hemorrhage; however, what we are interested in is FC thinning, regardless of whether this is due to lipids or blood beneath the FC. Therefore, even if an intraplaque hemorrhage is misdiagnosed as a lipid pool, this does not preclude measurement of the FC as long as the cap is surrounded by hypoechogenic structures that permit accurate detection of its boundaries. In our histological study, we did not identify any cases of important intraplaque hemorrhage. The real problem lies in cases in which a carotid atheroma is highly calcified or fibrous, in which a hypoechogenic structure beneath the FC cannot be identified and therefore FC measurement is not possible. For these reasons, FC measurement was not possible in 1 (5%) of 22 plaques of the validation study and in 4 (6.5%) of 62 plaques of the second data set. At present, we cannot determine whether this percentage would be smaller or bigger in a larger or different series of patients.

Fifth, adherent thrombi in the ICA constitute a rare entity in patients with stroke and may have a different appearance on high-resolution B-mode imaging (ranging from hypoechogenic to hyperechogenic) depending on their consistency and age.²¹ During ultrasound FCT measurements, we did not identify any patients with thrombi in our 2 data sets, and this was confirmed by histology in the validation set; however, ultrasound cannot exclude the presence of microaggregates of platelets and thrombin on the plaque surface, because these are well beyond the resolution of any existing ultrasound instrument. It is highly unlikely that these microaggregates, even if present, could have influenced the measurements.

Sixth, FCT values obtained by histology were on average slightly lower than those obtained by ultrasound, ranging from 1.0% for maximal FCT to 3.4% for minimal FCT (Table 1). Tissue shrinkage during histological processing may account for this small discrepancy. Two studies comparing ultrasound and histology for intima-media thickness measurements in the common carotid artery reported average differences of 4%²² and 14.6%.²³ In the former study, tissue shrinkage was only 2.5%. Our results are concordant with these studies. Although we did not account for tissue shrinkage, the agreement between ultrasound and histology was very good, which suggests that shrinkage was probably minimal. If considerable tissue shrinkage had occurred, a very good agreement between ultrasound and histology would have been possible only if ultrasound had systematically underestimated the actual FCT; however, as mentioned above, ultrasound tends to overestimate rather than underestimate FCT.

Hitherto, a semiautomated ultrasound system to quantify FCT and to investigate the clinical implications of this parameter in symptomatic and asymptomatic ICA atheromata has not been used. Our results are promising in terms of application to stroke prevention; however, additional studies to determine intrasonographer and intersonographer reproducibility are needed before the current technique can be used in clinical trials or in clinical practice. An ICA plaque with an FC thinner than 0.65 mm may help the clinician to identify patients with a higher risk of stroke. Nevertheless, only prospective population-based studies will determine the value of FCT, as evaluated by our method, for predicting the risk of subsequent brain ischemia.

Acknowledgment

This study was funded by the "Génie Biomedical" research program, 1999–2002.

References

- Naghavi M, Libby P, Falk E, Casscells SW, Litovsky S, Rumberger J, Badimon JJ, Stefanadis C, Moreno P, Pasterkamp G, Fayad Z, Stone PH, Waxman S, Raggi P, Madjid M, Zarrabi A, Burke A, Yuan C, Fitzgerald PJ, Siscovick DS, de Korte CL, Aikawa M, Airaksinen KE, Assmann G, Becker CR, Chesebro JH, Farb A, Galis ZS, Jackson C, Jang IK, Koenig W, Lodder RA, March K, Demirovic J, Navab M, Priori SG, Rekhter MD, Bahr R, Grundy SM, Mehran R, Colombo A, Boerwinkle E, Ballantyne C, Insull W Jr, Schwartz RS, Vogel R, Serruys PW, Hansson GK, Faxon DP, Kaul S, Drexler H, Greenland P, Muller JE, Virmani R, Ridker PM, Zipes DP, Shah PK, Willerson JT. From vulnerable plaque to vulnerable patient: a call for new definitions and risk assessment strategies: part I. *Circulation*. 2003;108:1664–1672.
- Hennerici MG. The unstable plaque. *Cerebrovasc Dis*. 2004;17(suppl 3):17–22.
- Torvik A, Svinland A, Lindboe CE. Pathogenesis of carotid thrombosis. *Stroke*. 1989;20:1477–1483.
- Van Damme H, Demoulin JC, Zicot M, Creemers E, Trotteur G, Limet R. Pathological aspects of carotid plaques: surgical and clinical significance. *J Cardiovasc Surg (Torino)*. 1992;33:46–53.
- Ogata J, Masuda J, Yutani C, Yamaguchi T. Rupture of atheromatous plaque as a cause of thrombotic occlusion of stenotic internal carotid artery. *Stroke*. 1990;21:1740–1745.
- Masuda J, Yutani C, Ogata J, Kuriyama Y, Yamaguchi T. Atheromatous embolism in the brain: a clinico-pathologic analysis of 15 autopsy cases. *Neurology*. 1994;44:1231–1237.
- Carr S, Farb A, Pearce WH, Virmani R, Yao JS. Atherosclerotic plaque rupture in symptomatic carotid artery stenosis. *J Vasc Surg*. 1996;23:755–766.
- Bassiouny HS, Sakaguchi Y, Mikucki S, McKinsey JF, Piano G, Gewertz BL, Glagov S. Juxtalumenal location of plaque necrosis and neointima in symptomatic carotid stenosis. *J Vasc Surg*. 1997;26:585–594.
- Oliver TB, Lammie GA, Wright AR, Wardlaw J, Patel SG, Peek R, Ruckley CV, Collie DA. Atherosclerotic plaque at the carotid bifurcation: CT angiography appearance with histopathologic correlation. *AJNR*. 1999;20:897–901.
- Yuan C, Zhang SX, Polissar NL, Echelard D, Ortiz G, Davis JW, Ellington E, Ferguson MS, Hatsukami TS. Identification of fibrous cap rupture with magnetic resonance imaging is highly associated with recent transient ischemic attack or stroke. *Circulation*. 2002;105:181–185.
- Hennerici M, Baezner H, Daffertshofer M. Ultrasound and arterial wall disease. *Cerebrovasc Dis*. 2004;17(suppl 1):19–33.
- Alexandrov A, Norris J. Quantitation and grading of carotid artery stenosis. In: Hennerici M, Meairs S, eds. *Cerebrovascular Ultrasound: Theory, Practice and Future Developments*. 1st ed. Cambridge, UK: Cambridge University Press; 2001:223–236.
- Liang Q, Wendelhag I, Wikstrand J, Gustavsson T. A multiscale dynamic programming procedure for boundary detection in ultrasonic artery images. *IEEE Trans Med Imaging*. 2000;19:127–142.
- Wendelhag I, Gustavsson T, Suurkula M, Gustavsson T. Ultrasound measurements of wall thickness in the carotid artery: fundamental principles and description of a computerized analyzing system. *Clin Physiol*. 1991;11:565–577.
- Rothwell PM. Carotid artery disease and the risk of ischaemic stroke and coronary vascular events. *Cerebrovasc Dis*. 2000;10:21–33.
- Comerota AJ, Katz ML, White JV, Grosh JD. The preoperative diagnosis of the ulcerated carotid atheroma. *J Vasc Surg*. 1990;11:505–510.
- Lammie GA, Wardlaw J, Allan P, Ruckley CV, Peek R, Signorini DF. What pathological components indicate carotid atheroma activity and can these be identified reliably using ultrasound? *Eur J Ultrasound*. 2000;11:77–86.
- Goldstein A. Errors in ultrasound digital image distance measurements. *Ultrasound Med Biol*. 2000;26:1125–1132.
- Bassiouny HS, Davis H, Massawa N, Gewertz BL, Glagov S, Zarins CK. Critical carotid stenoses: morphologic and chemical similarity between symptomatic and asymptomatic plaques. *J Vasc Surg*. 1989;9:202–212.
- Schinke U, Motsch L, Hilker L, Kessler C. Three-dimensional ultrasound observation of carotid artery plaque ulceration. *Stroke*. 2000;31:1651–1655.
- Karapanayiotides TH, Michel P, Bogousslavsky J, Devuyst G. "Hyper-echogenic rim" sign in internal carotid artery thrombus. *Arch Neurol*. 2004;61:773–774.
- Wong M, Edelstein J, Wollmann, Bond MG. Ultrasonic-pathological comparison of the human arterial wall: verification of intima-media thickness. *Arterioscler Thromb*. 1993;13:482–486.
- Persson J, Formgren J, Israelsson B, Berglund G. Ultrasound-determined intima-media thickness and atherosclerosis: direct and indirect validation. *Arterioscler Thromb*. 1994;14:261–264.