

Letter to the Editor

A rare type of fibrillation-like EMG activity



Spontaneous fibrillation potentials in EMG are a sign of denervation of a muscle fiber, as in motor axonal damage, or a part of a muscle fiber, as for example in necrotizing myopathy. Both rhythmic and irregular fibrillations have been described (Buchthal and Rosenfalck, 1966; Partanen and Danner, 1982). The underlying pathophysiology is different in rhythmic fibrillations and irregular fibrillations. Rhythmic fibrillations are a consequence of the slow rhythmic oscillations of an instable muscle membrane potential after denervation: Every depolarization wave reaching the firing threshold elicits a fibrillation potential. Irregular fibrillations are elicited by randomly occurring “fibrillatory origin potentials” (FOPs), arising in highly localized regions (<100 μm) of denervated muscle fibers, possibly associated with T-tubules (Purves and Sakmann, 1974). When a FOP reaches the threshold level and elicits a propagating fibrillation potential spreading to both ends of the denervated fiber, there is a long refractory period (Thesleff, 1982a), which prevents the early activation of a new fibrillation potential. Irregular spontaneous activity at the endplate region is a normal finding, not indicative of pathology, but it should be easily recognised and is the reason why fibrillation activity should be recorded from a number of sites (three) within a muscle before it is considered pathological.

A patient with a third type of fibrillation-like activity, “myokymic fibrillation” is described. “Myokymic fibrillation” is not a sign of denervation of the muscle fiber. The particular property of this type of spontaneous activity is the fact that the refractory time of the muscle fiber is not increased, as it is in fibrillations caused by denervation (Thesleff, 1982a). It should be noted that the term “myokymic fibrillation” is only descriptive, and not connected to the pathophysiology of true myokymia caused by spontaneous activation of motor nerve fibers. “Myokymic fibrillation” is distinctly different from end plate spikes (EPSs): It can be recorded for a long time with a similar bursting firing pattern, when the EMG needle is not moved whereas EPSs slow down (Partanen, 2013).

A 52-year-old woman developed clumsy right lower leg during winter 2015. The situation deteriorated rapidly and the patient expressed widespread muscle denervation in ENMG study in fall 2016 and motor neuron disease was diagnosed. At that time there was also spasticity in the right upper extremity and bilateral lower extremities, as well as clonic reflexes in the lower extremities. There was also weakness of the neck.

A peculiar spontaneous EMG activity, “myokymic fibrillation”, was observed in the right trapezius muscle (Fig. 1). It consisted of sequences of potentials, which lasted ad 6 s. The interpotential intervals tended to be short initially but longer towards the end of a sequence. The potentials were fibrillation-like, i.e. derived

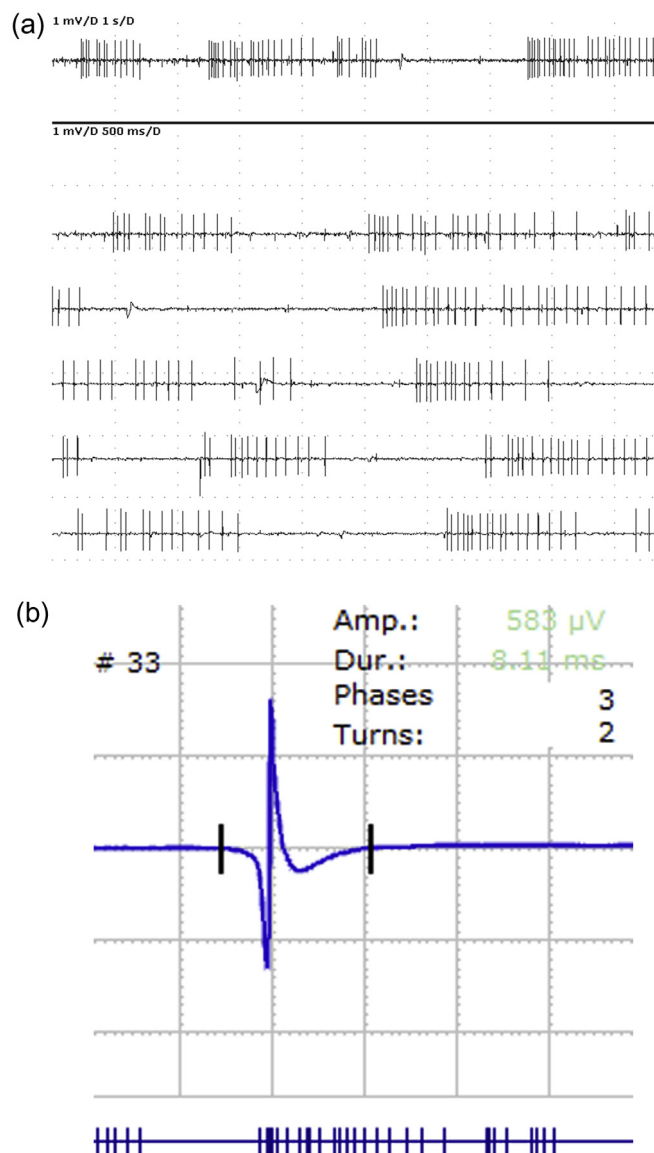


Fig. 1. (a) “Myokymic” fibrillations, apparently elicited by slow-rising “giant MEPPs”. Note the bursting pattern and the high frequency at the presumed peak of the acetylcholine release, and decrease of the frequency towards the end of a sequence. The high frequency is possible because the muscle fiber is not denervated and thus the refractory period after the action potential is normal, contrary to fibrillations after denervation of the muscle fiber. (b) A single averaged potential. The initial positive deflection is 1.2 ms and amplitude 0.6 mV.

from only one muscle fiber, not from a motor unit. The initial positive deflection of a single potential was 1.2 ms and amplitude 0.6 mV (Fig. 1) and thus the wave form differed from that of an EPS (Partanen, 2013). The given muscle showed also signs of ongoing axonal damage: rhythmic fibrillation potentials and also motor unit potential alterations caused by motor nerve sprouting, as well as reduced interference pattern. I conjecture that “myokymic fibrillation” may represent spontaneous release of acetylcholine from a motor nerve terminal, eliciting a “slow-rising giant miniature end plate potential (giant MEPP)” (Thesleff, 1982b; Thesleff and Molgó, 1983; Sellin et al., 1996). This type of transmitter release may occur spontaneously in regenerating motor nerve terminal, but it has also been described after botulin toxin injection or application of 4-aminoquinoline (Thesleff, 1982b). A “Giant MEPP” evidently causes a series of postsynaptic action potentials in the postjunctional muscle fiber, and during the peak of the release the mean frequency of potentials is higher than towards the end of the series when acetylcholine dehydrogenase diminishes the concentration of the transmitter. The muscle fiber is not denervated and thus the refractory period after an action potential is normal.

In our patient this activity may be connected with a regenerating motor nerve terminal (Thesleff and Molgó, 1983). We observed this activity only in the trapezius muscle. In some other patients this activity was expressed in several muscles. However, this kind of spontaneous activity is very rare. Since I learned to distinguish it from other forms of spontaneous activity I have found it at most 1–2 times per year in my ENMG work consisting of about 2000 patients annually. The comparison of the firing pattern and wave form of “myokymic fibrillation” and other types of fibrillations to EPSs was published elsewhere (Partanen, 1999, 2013). In short, in the firing pattern the average proportional consecutive interval difference (APCID) and the minimum interval were different ($p < 0.05$) when “myokymic fibrillation” was compared to EPSs, and EPSs did not show a bursting pattern, as “myokymic fibrillations” did. As to the wave form, the fibrillations had a mean initial positive deflection of 1.6 ms (SE 0.4), whereas 36% of EPSs showed

a mean initial positive deflection of 0.5 ms (SE 0.2) ($p < 0.001$), and the rest had a negative onset.

Conflict of interest

None.

References

- Buchthal, F., Rosenfalck, P., 1966. Spontaneous electrical activity of human muscle. *Electroencephalogr. Clin Neurophysiol.* 20, 321–336.
- Partanen, J., 1999. End plate spikes in the human electromyogram. Revision of the fusimotor theory. *J. Physiol. (Paris)* 93, 155–166.
- Partanen, J.V., 2013. Different types of fibrillation potentials in human EMG. In: Turker, H. (Ed.), *Electrodiagnosis in New Frontiers of Clinical Research*. Intech Open, Rijeka, Croatia. <http://dx.doi.org/10.5772/55352>.
- Partanen, J.V., Danner, R., 1982. Fibrillation potentials after muscle injury in humans. *Muscle Nerve* 5, S70–S73.
- Purves, D., Sakmann, B., 1974. Membrane properties underlying spontaneous activity of denervated muscle fibres. *J. Physiol.* 239, 125–153.
- Sellin, L.C., Molgó, J., Törnquist, K., Hansson, B., Thesleff, S., 1996. On the possible origin of giant or slow-rising miniature end plate potentials at the neuromuscular junction. *Pflügers Arch.* 431, 325–334.
- Thesleff, S., 1982a. Fibrillation in denervated mammalian muscle. In: Culp, W.J., Ochoa, J. (Eds.), *Abnormal Nerves and Muscles as Impulse Generators*. Oxford University Press, New York, pp. 678–694.
- Thesleff, S., 1982b. Spontaneous transmitter release in experimental neuromuscular disorders of the rat. *Muscle Nerve* 5, S12–S16.
- Thesleff, S., Molgó, J., 1983. A new type of transmitter release at the neuromuscular junction. *Neuroscience* 9, 1–8.

Juhani V. Partanen *

Clinical Neurosciences, Clinical Neurophysiology, University of Helsinki and Helsinki University Hospital, Finland

* Address: Department of Clinical Neurophysiology, Jorvi Hospital, P.O. Box 800, 00029 HUS, Finland.
E-mail address: Juhani.v.partanen@hus.fi

Available online 6 March 2017