



Discrimination of Oral Mucosal Disease Inspired by Diagnostic Process of Specialist

著者	Nishi Yusaku, Horio Keiichi, Saito Kentaro, Habu Manabu, Tominaga Kazuhiro
journal or publication title	Journal of Medical and Bioengineering
volume	2
number	1
page range	57-61
year	2013-03
URL	http://hdl.handle.net/10228/5889

doi: [info:doi/10.12720/jomb.2.1.57-61](https://doi.org/10.12720/jomb.2.1.57-61)

Discrimination of Oral Mucosal Disease Inspired by Diagnostic Process of Specialist

Yusaku Nishi and Keiichi Horio

Kyushu Institute of Technology/Graduate School of Life Science and Systems Engineering,
Kitakyushu 808-0196 Japan

Email: nishi-yuusaku@edu.brain.kyutech.ac.jp

Kentaro Saito, Manabu Habu, and Kazuhiro Tominaga

Kyushu Dental College/Department of Oral and Maxillofacial Surgery,
Kitakyushu, 803-8580 Japan

Abstract—A discrimination of oral mucosal diseases is very important in clinical site. Therefore, a development of a screening support system for oral mucosal diseases which supports the diagnosis of clinical dentist is required. In this paper, a discrimination method based on fuzzy inference using four attributes (existence of vitiligos, bulges, granular patterns, and reddening) for oral mucosal diseases is proposed. As the results of the experiment, the discrimination rates of squamous cell carcinoma, leukoplakia and lichen planus were 87%, 70% and 87%, respectively. The results suggest that the proposed method is effective in discriminating oral mucosal diseases.

Index Terms—oral mucosal disease, diagnosis support system, fuzzy inference, intraoral image

I. INTRODUCTION

Oral cancer is a significant health problem throughout the world. This paper focuses on identifying oral cancers at an earlier stage. Oral cancer detection at an earlier stage saves lives. The Japan National Cancer Center estimates 13,900 new cases and 7,100 deaths in Japan in the year 2013 of oral cancer [1]. At human oral mucosa, a wide variety of disorders many occur. Many diseases or lesions have been clinically classified [2]. In particular, there exist lesions that have a potential to develop into oral cancer. Recently, many researchers work on the classification of a cancer and non-cancer [3], [4]. They use a pathology image or X-rays image. The automatic extraction technique of the shape of oral cancer using the X-rays image is suggested [5], [6]. The study of the disease classification based on the form of the nucleus using the pathology image is conducted [7]-[9]. However, such a technique needs time and effort in the clinical site. Therefore, the discrimination is carried out using an intraoral image (Fig. 1) in this paper. The preliminary diagnosis of oral disease is mainly based on ocular inspection and registration of the patient's oral cavity as a digital image. In the ocular inspection, specialized knowledge needed. Thus, we introduce the knowledge of

the specialist into a diagnosis system to supports inexperienced clinical dentists. In this paper, the discrimination method of three clinically significant diseases (Squamous cell carcinoma (SCC), Leukoplakia (LEU), Lichen Planus (LP)) is discussed. SCC (Fig. 1(a)) is oral cancer, then early detection and early treatment are required. LEU (Fig. 1(b)) is called as a precancerous lesion and has high possibility of high canceration. For this disease, follow-up is a necessary. LP (Fig. 1(c)) is not a serious disease. However, it is hard to distinguish LP from LEU. The diagnosis of this system is carried out by modeling the diagnosis method of the oral surgeon. Four attributes (a vitiligo attribute, a bulge attribute, a granule pattern attribute and a reddening attribute) of the disease that an oral surgeon also uses in discrimination are extracted from an intraoral image. The discrimination of the disease was carried out using a fuzzy inference based on extracted attribute features.

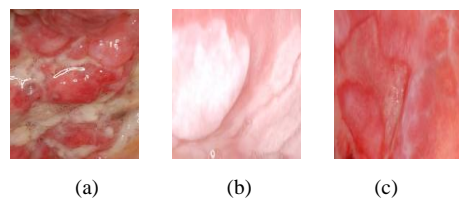


Figure 2. Oral mucosal disease (a) Squamous cell carcinoma (b) Leukoplakia (c) Lichen Planus

II. DATA USED IN THIS PAPER

A. Clinical data

Intraoral images used in this study were provided by Kyushu Dental College. The photographic method is not standardized unlike a CT image and an MR image. Therefore, the intraoral image varies with distance and angle with the lesion area, illumination condition each time. In this study, 30 images were prepared for each disease (SCC, LEU, LP). In addition, 30 images of normal mucosa images were added. Furthermore, a small image of normal part cut out from each image. The total number of intraoral images is 120 pairs. The oral

mucosal disease of each intraoral image was definitively diagnosed by an oral surgeon.

B. Diagnostic test

A diagnosis test of the intraoral image by four oral surgeons was performed to know the attributes which are necessary for the diagnosis of the oral mucosal disease. From the result of the diagnosis test, the common attributes corresponding to each disease were decided. Table I shows the attributes for each disease. “○”, “×” and “-” means that the attribute is “included”, “not included” and “don’t care” in each disease, respectively. In this study, we perform feature extraction in consideration of these attributes and distinguish the oral mucosal disease.

TABLE I. ATTRIBUTE OF ORAL MUCOSAL DISEASE

	Attribute			
	Vitiligos	bulges	Granular Patterns	Reddening
SCC	○	○	○	-
LEU	○	-	×	×
LP	○	×	-	○

III. EXTRACTION OF ATTRIBUTE

In this chapter, feature extraction technique based on an attribute.

A. Extraction of Vitiligo Attribute

At first, a extraction technique of the vitiligo attribute is explained. The gradient intensity $v(x, y)$ of pixel (x, y) is computed based on a gray scale intraoral image, and is calculated by

$$v(x, y) = \sqrt{f_x(x, y)^2 + f_y(x, y)^2}, \tag{1}$$

$$f_x = L(x+1, y) - L(x-1, y), \tag{2}$$

$$f_y = L(x, y+1) - L(x, y-1), \tag{3}$$

where, $L(x, y)$ is a level of the pixel (x, y) . A histograms of gradient intensity is made. Furthermore, the principal component analysis (PCA) was performed for histograms for all images. Fig 2(a) shows the first principal component score (F) in the PCA. From Fig. 2(a), it is shown that the distributions of F of three disease and normal part are different from each other. Therefore, F is employed as vitiligo attribute feature.

B. Extraction of Bulge Attribute

The extraction technique of the bulge attribute is explained. The bulge in the image is expressed by the shadow of the object. However, there is a problem that the change of color is extracted as a shadow in the intraoral image. Therefore, the bulge attribute is extracted by calculating gradient intensity from value images in the HSV color system to extract the information only for bulge effectively. The value image is provided by

$$V(x, y) = \max(R(x, y), G(x, y), B(x, y)) \tag{4}$$

where, $V(x, y)$ is the strength of the light in the pixel (x, y) . $R(x, y)$, $G(x, y)$ and $B(x, y)$ are a level of the RGB components in the original color image. $V(x, y)$ expresses the strength of the light. Therefore, $V(x, y)$ of vitiligo area and oral mucosal area are included in a same plane when their strengths of the light are same, even if the change of a color exists. In other words, it is thought that an image expressing the bulges of the intraoral image is obtained by using a value image. The gradient intensity $v'(x, y)$ in the value image was calculated like the gradient intensity in the vitiligo attribute extraction. Furthermore, the mean of the gradient intensity for whole image was calculated by

$$M = \sum_x \sum_y v'(x, y). \tag{5}$$

Fig. 2(b) shows the distribution of the mean of the gradient intensity in the value image. The gradient intensity of a SCC which is a disease with bulge attribute is bigger than that of other diseases. In addition, the mean of the gradient intensity of a LEU and a LP gradually becomes small. In this study, the bulge attribute is the mean of the gradient intensity in the value image. Therefore, M is employed as bulge attribute feature.




Figure 2. Attribute feature (a)Vitiligo feature (b)Bulge feature (c)Granular pattern feature (d)Reddening feature

C. Extraction of Granular Patterns Attribute

Granular patterns are the characteristic structure of squamous cell carcinoma and are an important element which determines SCC. The intraoral image is converted into the value image to extract granular structure. The granular attribute focus attention on the structure of the disease like a bulge attribute. The gradient intensity of each pixel is calculated with (1). Furthermore, the binarization processing (1, 0) is also performed with the threshold value 20 (Black: 0, White: 1). By these operation, the disease structure in the intraoral image is extracted. In this study, the extraction of the granular patterns attribute is performed by carrying out the opening operation that is one of the morphology operation [10]. Because morphology is processing technique based on the shapes, this technique is suitable

for the feature extraction concerning the shape in an image. At first, the opening operation is explained to suggest granular patterns attribute extraction technique. The set B corresponding to arbitrary small figure and the set X corresponding to 1 in the edge image is regarded. The opening by B of X is expressed by

$$X_B = (X \ominus B^S) \oplus B, \quad (6)$$

where, X_B is the set corresponding to 1 after the opening operation. \ominus, \oplus are Minkowski operation. B^S is origin symmetry set of B . The opening operation removes only the small part which B does not fit into from X and has action to store other parts. Therefore, the number of any small figure in an image is calculated by gradually increasing a small figure. The different size of number of the small figure in an image is calculated by

$$N_i = \frac{A(X_{B_i}) - A(X_{B_{i-1}})}{A(B_i)} \quad (i = 1, 2, \dots, n), \quad (7)$$

where, N_i expresses the number of the i th small figure. $A(X)$ expresses the number of the pixels on the image corresponding to the set in the X . In the extraction of the granular pattern attribute, the set is circular. B_1 is the circle of 11 pixels of diameters. In addition, The $i + 1$ th small figure B_{i+1} is the circle that a diameter is bigger than the small figure B_i by four pixels.

Here, N is summation N_1 to N_9 . Fig. 2(c) shows the distribution of the small figure summation. A value of SCC with granular pattern structure is large in Fig. 2(c). The small figure summation N of LEU and LP without granular pattern structure is small. Concerning a normal mucosa, Some image have large N . The reason is that the image of the tongue is included in a normal mucosal image. The unique structure of the tongue is extracted by this technique. Therefore, N is employed as granular pattern attribute feature.

D. Extraction of Reddening Attribute

The reddening attribute is expressed by the differences of a red strength between disease part and normal part. In this study, the red strength is expressed by saturation image of the HSV color system. The S level $S(x, y)$ in pixel (x, y) of the RGB image is calculated by

$$S(x, y) = \frac{Max - Min}{Max}, \quad (8)$$

$$Max = \max(R(x, y), G(x, y), B(x, y)), \quad (9)$$

$$Min = \min(R(x, y), G(x, y), B(x, y)). \quad (10)$$

Furthermore, the means of the S level for whole images M_d and M_n in the diseases and the normal part image are calculated by

$$M_d = \frac{1}{W \times H} \sum_x^W \sum_y^H S_d(x, y), \quad (11)$$

$$M_n = \frac{1}{W' \times H'} \sum_x^{W'} \sum_y^{H'} S_n(x, y), \quad (12)$$

where, S_d, S_n express the S level in the disease part image, an S level in the normal part image, respectively. W, H, W', H' express the number of pixel of each side in the disease part image and the number of pixel each side in the normal part image, respectively. Furthermore, difference between then D is given by

$$D = M_d - M_n. \quad (13)$$

Fig. 2(d) shows the distribution of the difference of the mean of the S level. Distribution of D of LP with a reddening attribute and D of LEU without a reddening attribute is divided well. Therefore, D is employed as reddening attribute feature.

IV. DISCRIMINATION METHOD

A. Fuzzy Resoning

In this study the fuzzy inference is used for discrimination. Fuzzy inference is a technique for performing identification by quantitative process for the ambiguous nature such as attributes. Therefore, this technique was adopted to be suitable for modeling the diagnosis technique of the oral surgeon.

B. Membership Function

The membership functions are made based on the feature of each attribute to perform the fuzzy inference. The membership function means a degree of that the image includes vitiligo, and is calculated based on vitiligo attribute F as shown in Fig. 3(a). Fig. 3 determined the membership function of each attribute by the mean and dispersion of the distribution of the each attribute feature. The discrimination was performed using these membership functions.

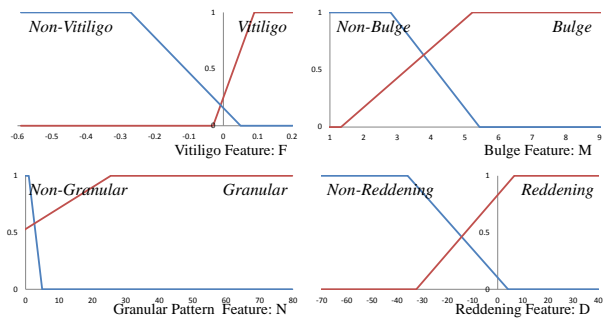


Figure 3. Membership function

C. Rules

A rule is established based on an attribute and the importance of each oral mucosal disease. The rules are

shown Table II. The final discrimination is based on the largest inference result of Rule 1 to 4.

TABLE II. RULES FOR DISCRIMINATION

<p>Rule: 1 If F is "Vitiligo" and M is "Bulge" and N is "Granular" then the image is SCC.</p> <p>Rule: 2 If F is "Vitiligo" and N is "Non-Granular" and D is "Non-Reddening" then the image is LEU.</p> <p>Rule: 3 If F is "Vitiligo" and M is "Non-Bulge" and D is "Reddening" then the image is LP.</p> <p>Rule: 4 If F is "Non-Vitiligo" then the image is Normal Mucosa.</p>
--

V. RESULT

The discrimination experiment was performed by a method of the re-substitution estimate and the 3-fold cross validation. Table III is the discrimination result of the re-substitution estimate. 87 % of SCC images, 83 % of LEU images, 87 % of LP images and 53 % of normal mucosa images were correctly discriminated. Table IV is the discrimination result of the 3-fold cross validation. The discrimination rate of SCC, LEU, LP and normal mucosa is 87%, 70%, 87% and 47%, respectively. The discrimination rate of the normal part is worse than that of diseases because the rules setting considering a risk. Instead, all diseases images are distinguished as a disease of either. In addition, a discrimination rate of the oral mucosal disease is high. Therefore, it is suggested that the result has an enough important result.

TABLE III. DISCRIMINATION RESULT BY RE-SUBSTITUTION ESTIMATE

		Output Disease			
		SCC	LEU	LP	Normal Mucosa
Input Images	SCC	87%	10%	3%	0%
	LEU	17%	83%	0%	0%
	LP	0%	13%	87%	0%
	Normal Mucosa	23%	7%	17%	53%

TABLE IV. DISCRIMINATION RESULT BY 3-FOLD CROSS VALIDATION

		Output Disease			
		SCC	LEU	LP	Normal Mucosa
Input Images	SCC	87%	13%	0%	0%
	LEU	27%	70%	3%	0%
	LP	0%	13%	87%	0%
	Normal Mucosa	23%	7%	23%	47%

VI. CONCLUSION

In this study, we performed attribute feature extraction and discrimination by the fuzzy inference based on the necessary attribute of the diagnosis of the oral surgeon.

The result suggested the effectiveness of the discrimination technique by the attribute extraction. In the future, we introduce the extraction technique of other attributes and consider the rule in the fuzzy inference.

REFERENCES

- [1] Center for Cancer Control and Information Services, "Future prevalence estimates, the number of deaths, the number of national cancer incidence (years 2010-2029)," *Japan Cancer Center*, 2012.
- [2] Michael W. Finkelstein, DDS, MS, "A guide to clinical differential diagnosis of oral mucosal lesions," *dentalcare.com*, 2010.
- [3] P. Wilder-Smith, J. Holtzman, J. Epstein, and A. Le, "INVITED MEDICAL REVIEW Optical diagnosis in the oral cavity: an overview," *Oral Disease*, vol. 16, pp. 717-728, 2010.
- [4] K. Anuradha and K. Sankaranarayanan, "Identification of suspicious regions to detect oral cancers at an earlier stage - A literature survey," *International Journal of Advances in Engineering & Technology*, vol. 3, Issue 1, pp. 84-91, 2012.
- [5] I. Nurtanio, I. K. E. Purnama, M. Hariadi, and M. H. Purnomo, "Cyst and tumor lesion segmentation on dental panoramic images using active contour models," *The Journal for Technology and Science*, vol. 22, no. 3, Aug 2011.
- [6] K. Anuradha and K. Sankaranarayanan, "Detection of oral tumor based on marker - controlled watershed algorithm," *International Journal of Computer Applications*, vol. 52, no. 2, Aug 2012.
- [7] C. G. Loukas, G. D. Wilson, B. Vojnovic, and A. Linney, "An image analysis-based approach for automated counting of cancer cell nuclei in tissue sections," *Cytometry*, A. 55(1), pp. 30-42, Sep 2003.
- [8] R. R. Paul, A. Mukherjee, P. K. Dutta, S. Banerjee, M. Pal, J. Chatterjee, K. Chaudhuri, and K. Mukkerjee, "A novel wavelet neural network based pathological stage detection technique for an oral precancerous condition," *J Clin Pathol*, vol. 58, no. 10, pp. 932-938, Feb 2005.
- [9] N. Mohtasham, N. Mahdavi-Shahri, J. Salehinejad, H. Ejtehadi, M. Torabi-Parizi, and N. Ghazi, "Detection of nucleoproteins in squamous cell carcinoma, and dysplastic and normal mucosa in the oral cavity by methyl green-pyronin staining," *Journal of Oral Science*, vol. 52, no. 2, pp. 239-243, Feb 2010.
- [10] H. Kobatake, *Morphology*, Corona Co., 1996.



Yusaku Nishi received B.E. degree form Kitakyushu National College of Technology, Japan, in 2011.

He is currently a post graduate student at the Graduate School of Life Science and System Engineering, Kyushu Institute of Technology, Japan.



Kentaro Saito received D.D.S. degree from Kyushu Dental College, Japan, in 2003 and 2009, respectively.

He is a post graduate student, Division of Maxillofacial Surgery, Department of Science of Physical Function, Kyushu Dental University.



Manabu Habu received D.D.Sc., and Ph.D. degree from Kyushu Dental College, Japan, in 1998 and 2002, respectively.

He is currently an assistant professor at Division of Maxillofacial Surgery, Department of Science of Physical Function, Kyushu Dental University, Japan.

He is specialized in Oral and Maxillofacial Surgery.



Keiichi Horio received B.E., M.E., and Ph.D. degrees from Kyushu Institute of Technology, Japan, in 1996, 1998, and 2001, respectively.

He is currently an associate professor at the Graduate School of Life Science and Systems Engineering, Kyushu Institute of Technology, Japan.

His research interests include soft computing technology and its applications.



Kazuhiro Tominaga received D.D.Sc., and Ph.D. degree from Kyushu Dental College, Japan, in 1982 and 1986, respectively.

He is currently Professor and Chairman, Division of Maxillofacial Surgery, Department of Science of Physical Function, Kyushu Dental University.

He is specialized in Oral and Maxillofacial Surgery.