

## ARTICLE

# Enostosis (osteopoikylosis, bone islands) in medieval (14-15<sup>th</sup> centuries) skeletons

László G. Józsa<sup>1\*</sup> and Gyula L. Farkas<sup>2</sup><sup>1</sup>Department of Morphology, National Institute of Traumatology, Budapest, Hungary, <sup>2</sup>Department of Anthropology, University of Szeged, Szeged, Hungary

**ABSTRACT** Enostosis (*i.e.* osteopoikylosis, bone islands, etc.) is a focus of mature cortical bone within cancellous bone. Bone islands are often recognized on radiographic pictures taken for other diagnostical purpose. The authors examined x-ray images of 652 long bones and 44 innominate bones of 124 adult skeletons from the 14-15<sup>th</sup> centuries AD. Six cases of enostoses were recognized (2 innominate bones, 2 fibulas, 1 femur head and 1 tibia). The biggest alteration was 22x9 mm, while most of the bone islands were 2-5 mm in size. Histological examination was performed in two cases. Microscopical view of one case showed lamellar (cortical) bone; in the other case woven bone structure was found. Enostosis of archeological bones can only be diagnosed performing routine radiographic examination.

**Acta Biol Szeged 52(2):329-331 (2008)**

**KEY WORDS**enostosis  
osteopoikylosis  
archeological material

Since the earliest description by Stieda in 1905 (*cit.* Greenspan 1995) enostosis or bone island has been variously named and defined in literature. Stieda referred to small, dense, circumscribed shadows inside the cancellous portion of tubular bones as „kompakte Knochenkerne” (compact bone nuclei). Diverse nomenclature of this pathology includes: calcified island in medullary bone, sclerotic bone island, focal sclerosis, hamartous cortical bone, endosteoma, endosteosis, osteopoikylosis, etc. This benign lesion can be diagnosed on the basis of its characteristic radiological features. Accurate identification of the alteration is crucial in the differential diagnosis of other more significant bone lesions such as primary or metastatic tumors. Enostosis of archeological bones can only be diagnosed performing routine radiographic examination.

The aim of this study is to describe our cases recognized on x-ray images taken for other diagnostical purposes.

**Materials Aand Methods****Archeological data**

Bátmonostor-Pusztafalu is the largest medieval cemetery in Hungary situated in the southern part of the Great Hungarian Plain. The total number of individuals found in graves and reduction areas is 3783. The investigated remains derive from the 14-15<sup>th</sup> centuries AD.

**Anthropological data**

Among 3783 skeletons 1510 belong to the infantia I and II age categories. The number of juvenile individuals is 153, while the number of adult males is 1342, which is almost twice the number of the 719 adult female skeletons. Age at death and sex were determined according to classical methods of physical anthropology (Nemeskéri et al. 1960; Ubelaker 1978).

**Radiological examination**

On 652 long bones (femur, tibia, fibula, humerus) and 44 innominate bones of 124 adults (79 male and 45 female) two directional plain film radiography was performed for other diagnostical purposes.

**Histological examination**

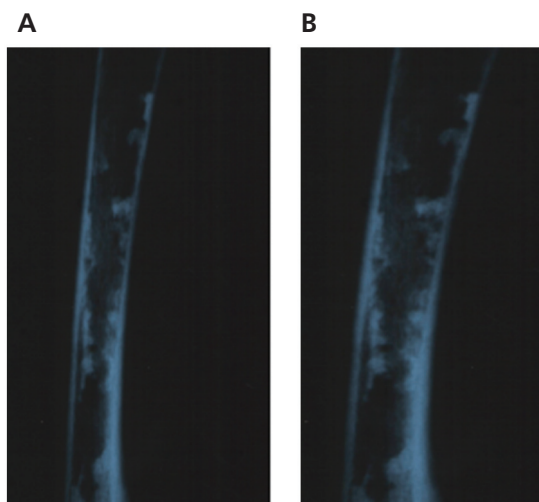
Bone pieces were excised from 3 bones in which enostoses were previously detected with radiological examination. The bone pieces (10x5x5 mm) were decalcified in EDTA solution and embedded in paraffin wax. The 5 µm serial sections were stained with Masson's trichrome and sirius supra red dyes. The preparations were examined with plain light and polarized light microscopes.

**Results**

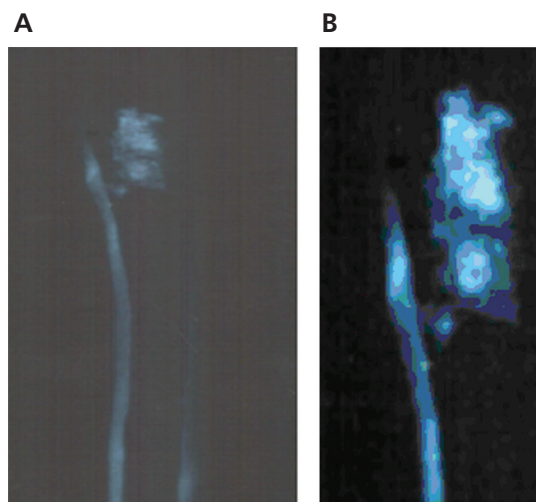
In six cases (two innominate bones, two fibulas, one femoral neck and head and one tibia) bone islands were detected on radiographic pictures. 0.61% of the long bones, 4.5 % of the innominate bones and 5% of the total 124 individuals have been affected by the alteration.

Accepted Okt 28, 2008

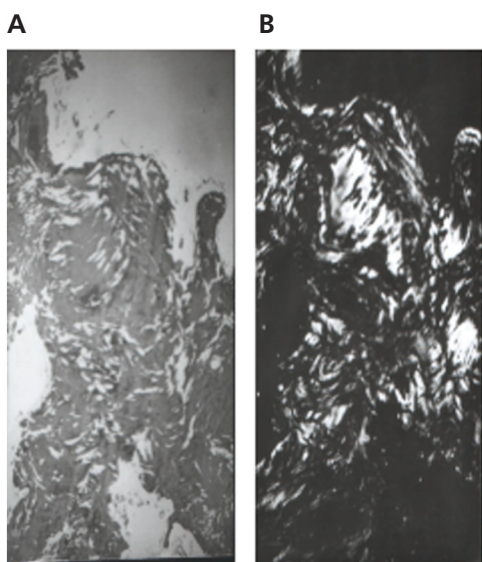
\*Corresponding author. H-3648, Csernely, Tánácsics u. 9., Hungary



**Figure 1.** (A) Radiological picture of the enostosis in the fibula of case 1. (B) 3x magnification of the same site.



**Figure 3.** (A) Radiological picture of the giant bone island (22x9 mm) in the fibula of case 6. (B) 3x magnification of the same site.



**Figure 2.** (A) Histological section of the enostosis of case 1: woven bone structures. Masson's trichrome staining, light microscopy, 200x magnification. (B) Histological section of the same site stained with sirius supra red, polarized light microscopy.

Case 1/ grave no. 120, male, aged 21-40 ys. On the diaphysis of the left tibia a dislocated healed fracture was visible. In the proximal metaphysis of the right fibula eight bone islands of 2-4 mm diameters could be seen on the radiograph (Fig. 1A, Fig. 1B). The histological examination reported woven bone structure in the bone island (Fig. 2A, Fig. 2B).

Case 2/ grave no. 1404/05, male, aged 41-60 ys. On the right acetabulum a fracture with 2 mm diastasis was found.

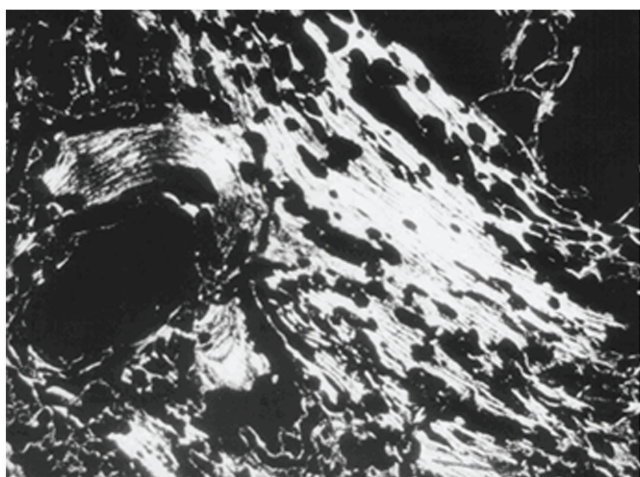
Both on the acetabulum and on the femoral head signs of osteoarthritis were seen. In both innominate bones 4-4 bone islands (2-6 mm in diameter) were detected on the x-ray images.

Case 3/ grave no. 1424, male, aged 41-60 ys. On the posterior surface of proximal metaphysis of the right tibia an osteochondroma of 6x3x3 cm size was found. Within the osteochondroma (exostosis) three bone islands were seen, all oval in shape and 4x3 mm in diameter. On the proximal end of tibia 9 Harris lines were detected. The microscopic examination confirmed the presence of lamellar cortical bone within the cancellous structure of the exostosis.

Case 4/ grave no. 1588, female, aged 41-60 ys. In the right innominate bone seven bone islands were found. Two islands were oval in shape, with diameters of 5x3 mm, while the other five islands were round and 2-3 mm in diameter. In the microscopic picture of the islands typical lamellar cortical bone was seen.

Case 5/ grave no. 1920, male, aged 21-40 ys. Dysplasia coxae congenita and bony ankylosis of the right hip joint was detected. Cervical angle of the right femoral neck was 158 grades, while that of the intact left side was only 130 grades. On the x-ray images within both the head of femur and the innominate bone seven islands were seen, round or oval in shape and 3-4 mm diameter.

Case 6/ grave no. 2586/B, male, aged 21-40 ys. On the diaphysis of right tibia a healed spiral fracture was diagnosed. On the radiographs posttraumatic osteomyelitis could be detected. On the proximal part of the right fibula a 22x9 mm bone island was seen (Fig. 3A, Fig. 3B). Histological examination proved the presence of cortical bone tissue in the structure (Fig. 4).



**Figure 4.** Histological section of the enostosis of case 6: lamellar cortical bone structures. Sirius supra red staining, polarized light microscopy, 100x magnification.

## Discussion

Enostoses (bone islands) are clinically asymptomatic and are often incidental findings on radiographs performed for other diagnostic purposes (Lagier-Nussle 1978; Greenspan et al. 1991). Bone islands exhibit consistent radiographic picture regardless of their location, shape or size. The lesions appear in the spongiosa as round, ovoid or oblong foci of homogeneously dense and sclerotic bone tissue. The majority of bone islands (described as “giant islands”) range from 1 to 10mm in size. The greatest bone island ever found was located in tibia and 50x50x45mm in size (Smith 1993). The pelvis and the femur are preferred sites of involvement, but the lesion may be found anywhere in the skeleton. This alteration, however, is rarely located in the spine or the ribs (Greenspan 1995). Enostosis is familial in some cases (Forgács 1970). In living patients, enostosis can often be diagnosed after CT, MRI examination or scintigraphy. The histological picture of the lesion is a focus of compact (cortical) bone tissue within the spongy part that consists of mature lamellar trabeculae, while occasionally may contain woven (immature, non-lamellar) bone as well. Mirra et al. (1989) referred to it as „misplaced hamartous

cortical bone”, while recent investigations suggest that foci of mature cortical bone within the spongiosa represent areas that failed to resorb during enchondral ossification (Greenspan et al. 1991).

Enostoses are only incidentally diagnosed in modern clinical practice. In addition, according to our best knowledge this lesion has only once been described in paleopathological literature. Lagier et al. (1959) found one case in which the caput humeri (1), the caput femoris (2) and distal epiphysis of the same femur (2) contained bone islands. Enostoses cannot be recognized during macroscopic examination, only with radiological imaging techniques. Paleopathological practice, however, has rarely used radiography as part of the routine examination process. In our material we performed radiographic investigation on each bone showing any macroscopic alteration (healed fracture, periostitis, etc.). As a result of this process we could diagnose enostoses and calculate the prevalences in the sample. Due to incidental recognition of the lesion, exact frequency of enostosis is unknown in the sample, just like in any other recent or archeological populations.

## Acknowledgement

The project was supported by OTKA project no. TO 32824

## References

- Forgács S (1970) Familiäre osteopoikilosis. *Fortschr Geb Roentgenstr Nuklearmed* 112:254-259.
- Greenspan A (1995) Bone island (enostosis): current concept – a review. *Skeletal Radiol* 24:111-115.
- Greenspan A, Steiner G, Knutson R (1991) Bone island (enostosis): clinical significance and radiologic and pathologic correlations. *Skeletal Radiol* 20:85-93.
- Lagier R, Kramar C, Baud CA (1959) Multiple bone islands in a skeleton dating from the neolithic period. *Eur J Radiol* 9:81-82.
- Lagier R, Mbakop A, Bigler A (1984) Osteopoikilosis: a radiological and pathological study. *Skeletal Radiol* 11:161-168.
- Lagier R, Nussle D (1978) Anatomy and radiology of bone island. *Fortschr Roentgenstr* 128:261-269.
- Mirra JM, Picci P, Gold RH (1989) Bone tumors: clinical, radiologic and pathologic correlations. Philadelphia, Lea & Febiger, p. 182.
- Nemeskéri J, Harsányi L, Acsády Gy (1960) Methoden zur Diagnose des Lebensalters von Skelettfunden *Anthrop Anz* 24:70-95.
- Smith J (1993) Giant bone island. *Radiology* 107:35-40.
- Ubelaker DH (1978) Human skeletal remains: Explanation, analysis, interpretation. Aldwine, Chicago.