

ARTICLE

Presynaptic axonal amyloid- β induces caspase-3 activation and neurodegeneration in the postsynaptic neuron

Peter Kasa^{1*}, Henrietta Papp¹, Zsuzsanna Beke¹, David Vadasz¹, Janos Zombori²¹Alzheimer's Disease Research Centre, Department of Psychiatry, and University of Szeged, Szeged, Hungary, and ²Department of Pathology, Elisabeth Hospital, Hodmezovasarhely, Hungary

ABSTRACT It is assumed that the amyloid-beta peptide (A β) contributes to the neurodegeneration in Alzheimer's disease (AD). Activation of an apoptotic pathway may play a key role in this process. The apoptotic signal may be driven by caspases. The presynaptic A β protein may be an activator of caspase-3 and could initiate a series of cascade events, which results in neurofibrillary degeneration in a postsynaptic cell. We report here that the axonic A β in the AD brain may be associated with caspase-3 activation. Our data suggest that caspase-3 in fact has a significant role in the widespread neuronal cell death that occurs in AD brain. A subset of pyramidal cells in hippocampus area CA1 demonstrated widespread accumulation of tau-protein. Individual postsynaptic neurons contained intracellular activated caspase-3 and were co-localized with neurofibrillary tangles. The results presented here support the suggestion that caspase-3 activation may lead to the neuronal cell death associated with AD. However, we are aware that, besides A β , other factors too may initiate a series of events which lead to the development of neurofibrillary tangles in the postsynaptic neurons.

Acta Biol Szeged 48(1-4):1-6 (2004)**KEY WORDS**Alzheimer's disease
amyloid-beta
apoptosis
caspase-3
neurofibrillary tangle

In Alzheimer's disease (AD), the most common type of dementia in advanced age, the loss of cortical and hippocampal neurons and synapses, is accompanied by the extracellular deposition of amyloid-beta peptide (A β) in senile plaques (SPs; Braak and Braak 1991). Paired helical filaments containing hyperphosphorylated tau-protein forms the neurofibrillary tangles (NFTs). The mechanism by which neurodegeneration occurs in AD is not yet understood (Bossy-Wetzel et al. 2004). Some investigators speculate that much of the cell loss may be due to apoptosis, a highly regulated form of programmed cell death (Cotman 1998). The caspases are therefore critical effectors of neuronal apoptosis and may be inappropriately activated in AD (Cowan et al. 2001; Cribbs et al. 2004; Johnson 1994). In particular, the analysis of caspase-3-deficient mice has revealed a decrease in apoptosis in the developing brain, suggesting that caspase-3 is necessary for the apoptosis of developing neurons. In AD brains, the protein level of caspase-3 is also increased (Rohm et al. 2001).

Some reports have indicated that A β (Estus et al. 1997) induces morphological and biochemical changes, with characteristic apoptosis of the neurons. A β deposits have also been shown to be associated with both the presence of dystrophic neurites and the neuronal loss found in severely affected brain regions in AD (Selkoe 2002).

These observations prompted us to investigate the possible

involvement of caspase-3 in A β -induced apoptosis in autopsied human brain hippocampal samples. To study the relationship between presynaptic A β deposition and the activation of caspase-3 in the postsynaptic neuron, we investigated the structural relationships of these proteins in autopsied human brain hippocampal samples.

Materials and Methods

The primary antibodies used in this study were rabbit anti-A β 1-42 affinity-purified polyclonal antibody from Chemicon International Inc. (Temecula, CA, USA), caspase-3 active form (biotin-conjugated, polyclonal rabbit from BD Biosciences Pharmingen, San Diego, CA, USA) and monoclonal anti- τ (tau) antibody produced in mouse (Sigma-Aldrich, St. Louis, MO, USA). Normal goat serum, normal sheep serum and 3,3'-diaminobenzidine tetrahydrochloride (DAB) were from Sigma-Aldrich (St. Louis, MO, USA). Biotin-SP-AffiniPure-sheep anti-mouse IgG (H+L), peroxidase-streptavidin from Jackson (West Grove, PA, USA). Histoclear II and Histomount were from National Diagnostics (Atlanta, GA, USA). All chemicals used were of the highest grade available, from various suppliers.

Immunohistochemistry

Autopsied brain tissues from the hippocampus of 5 neuropathologically confirmed AD cases and 6 non-demented cases displaying no evidence of NFTs were studied. The age

Accepted Oct 21, 2004

*Corresponding author. E-mail: kp@comser.szote.u-szeged.hu

at death was not significantly different for the AD (mean, 69 ± 7.2 years) and the controls (mean, 64 ± 6.8). The autopsied brain tissues used in this study were provided by the Department of Pathology, Elisabeth Hospital, Hodmezovasarhely, Hungary.

Coronal sections 30-µm in thickness were cut with a freezing microtome. Sections were soaked for 20 min in 3% H₂O₂, washed in phosphate-buffered saline (PBS; pH 7.4), treated with 0.1 M PBS containing 2.5% Triton X-100 for 20 min and then incubated with the normal blocking serum for 60 min. The sections were thereafter incubated with the primary antibody at 4°C overnight. The dilutions of the individual antibodies were as follows: Aβ: 1:2000, activated caspase-3: 1:800 and tau: 1:2000. After three 10-min washes in PBS, the brain slices were incubated with the secondary antibody. When single staining was applied for demonstration of the localization either of Aβ or of activated caspase-3, the peroxidase complex was visualized by incubating the sections with 0.05 M Tris-HCl (pH 7.5) containing 0.05% DAB, 0.1% NiCl₂ and 0.005% H₂O₂, resulting in a bluish-black colour. When double-stained sections were prepared (stained either for Aβ and tau or for activated caspase-3 and tau), the samples were developed first in DAB dissolved in 0.05 M Tris-HCl buffer. This staining resulted in a brownish colour. Thereafter, the sections were treated for 30 min with 0.6% H₂O₂ to eliminate the possibility persistent activity of the marker enzyme. After the staining for the second antibody, the peroxidase complex was visualized by incubating the sections in a DAB-NiCl₂ mixture. In these double-stained sections, a brownish colour could be detected in some cell bodies, intermingled with a bluish-black colour (Kasa et al. 2001). Controls were performed to rule out non-specific immunostaining by eliminating the primary or secondary antibody. The sections were next mounted, air-dried, dehydrated in an ethyl alcohol series, cleared in HistoClear, and finally coverslipped using Histomount. Photos were taken under normal light field microscopy conditions (Nikon Microphot-FXA microscope).

Results

To investigate the morphological localization of Aβ in hippocampus area CA1, an affinity-purified polyclonal antibody was used. The immunoreactivity was revealed not only in the SPs (Fig. 1A), but also in the axon varicosities (at the synaptic sites; Fig. 1B) and within the neuronal cell body (Fig. 1C). Some of the stained axon varicosities could be localized near the perikaryon and attached to the primary dendrite of a pyramidal cell (Fig. 1D).

When the samples were double-stained for Aβ and for tau, much to our surprise, a number of Aβ-stained axon varicosities were revealed on the surface of the tau-immunopositive neurons (Figs. 2A, B). It was interesting that the axon varicosities were not uniformly distributed over the dendrite, but

were rather located consecutively, separated by distance of a few microns.

In the control hippocampal samples, very few activated-caspase-3-positive pyramidal cells were detected (Fig. 2C). Similarly, in the area dentate, stained neurons were rarely seen. The most interesting observation concerned the appearance of the staining. It appeared intermittently rather than evenly in the dendrites. In a Braak and Braak stage II AD sample, some tau were immunopositive for activated caspase-3 (Fig. 2E), while many more NFT-positive cells stained for caspase-3 (Fig. 2F) in a severe AD case (Braak and Braak stages V and VI).

To examine a possible relationship between caspase-3 activation and tau-positive neurons, double-labelling experiments were undertaken, using the caspase-3 active form and monoclonal anti-tau antibody as markers for NFT formation. As shown in Fig. 3A, only a subset of neurons was caspase-3-positive, and the number of cells was even lower for which tau could be clearly be seen in the same neuron. The co-localization of caspase-3 and tau was evident within individual neurons (Figs. 3A, B). Figure 3B illustrates a high-magnification image of typical caspase-3 and tau staining in the pyramidal neuron in hippocampus area CA1. Interestingly, the appearance of neurons labelled with caspase-3 was similar to that of those with tau. Other stained samples provided further evidence that not all caspase-3-positive neurons contain tau pathology (Figs. 3C, D). Taken together, these results suggest that caspase-3 activation may occur in only a subset of the tau-bearing neurons. This suggestion is supported in Figs. 3E, F, where many more labelled neurons are present than in Fig. 3D.

Discussion

In this report, we have demonstrated that Aβ is not only present in the SPs and neuronal perikarya, but may also be localized in the axons (Chen et al. 2004). There is experimental evidence suggests that Aβ accumulation in the cells may precede tau formation in the AD brain, and can potentiate the development of NFTs in transgenic mice. Furthermore, Aβ-induced neurodegeneration requires tau expression and the intracellular assembly of pathological tau filaments (Rissman et al. 2004). The appearance of intracellular Aβ is also observed in Down syndrome patients with AD, indicating that intraneuronal Aβ may be a common feature of AD subtypes.

The activation of caspase-3 (Stadelmann et al. 1999; Su et al. 2001) in the postsynaptic dendrite by presynaptic Aβ again precedes the appearance of tau positivity in the pyramidal cells of hippocampus area CA1 in human brain samples. By using antibodies specific for the active form of caspase-3, tau and Aβ, we could underline such a sequence of events. It is suggested that the various caspases (among them caspase-3) are activated only during apoptosis (Rohn et al. 2001; Sal-

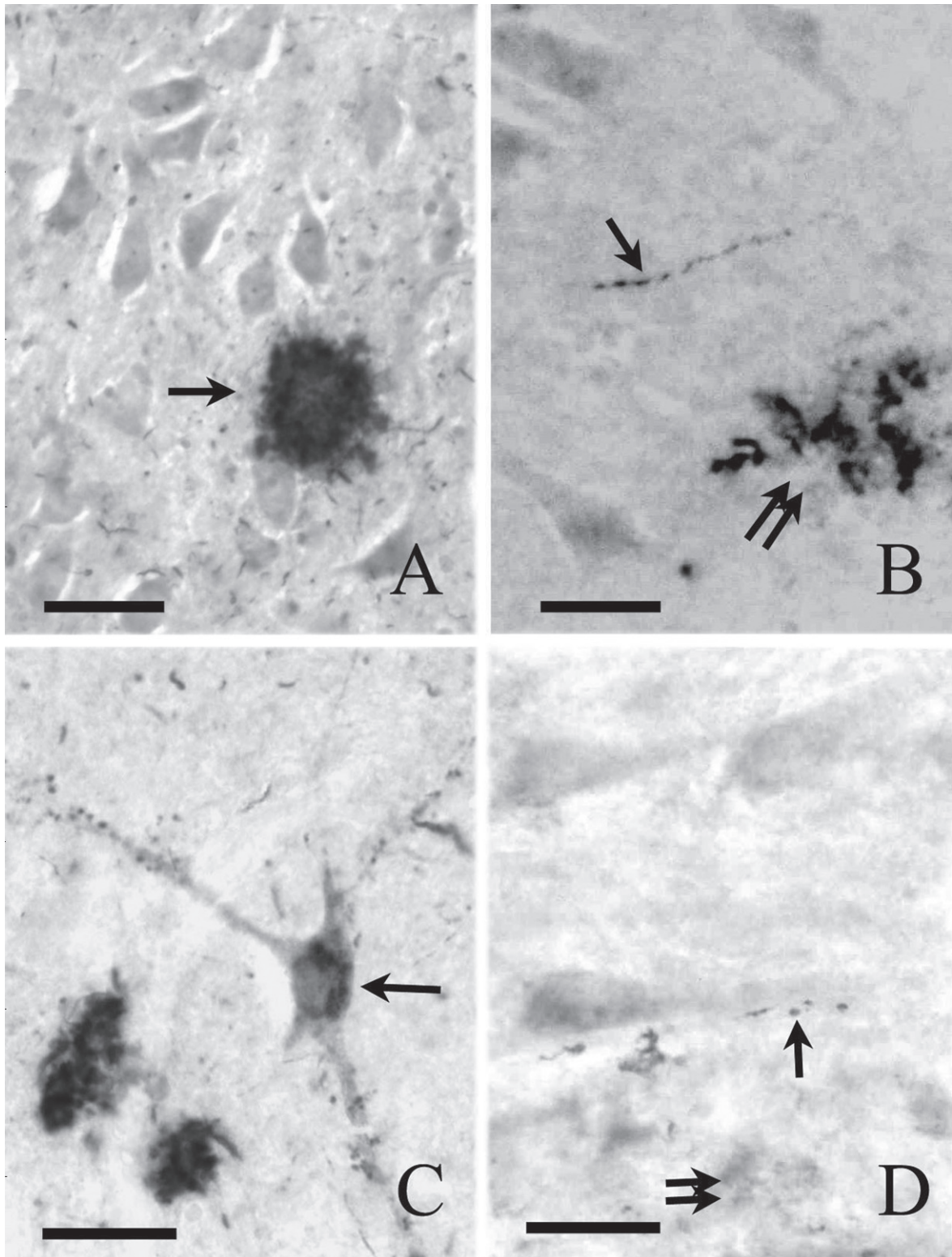


Figure 1. Immunohistochemical localization of A β in hippocampal area CA1. Specific A β staining appears in the SPs (A, arrow), in the axon varicosities (B, arrow) and in the SPs (B, double arrows). In C, specific A β immunoreactivity is present in the perikarya of a neuron (arrow). Some other neurons are covered with A β -positive axon varicosities (arrow), while diffuse staining (double-arrow) is to be seen among the neuropil. Scale bar: 50 μ m

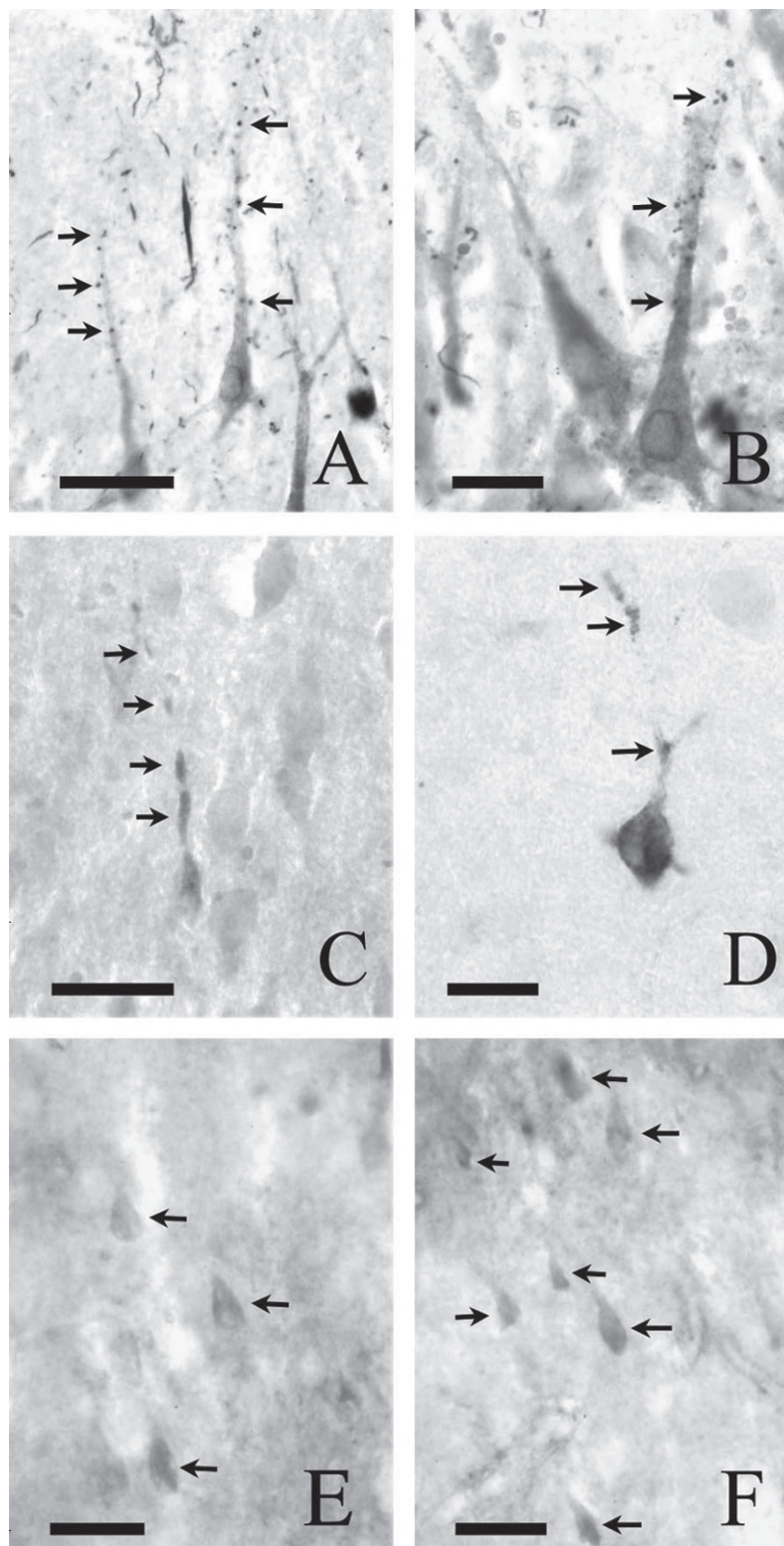


Figure 2. Double-labelling immunohistochemical analysis for $A\beta$ and tau. In A and B, the brownish staining within the neurons indicates the presence of tau, while the black dots (A and B, arrows) on the surface of the pyramidal cells illustrate the $A\beta$ -positive axon varicosities. Figure 2C,D reveal the activated caspase-3 in the dendrites and the cell body in a control sample. The staining pattern appears intermittently in the dendrites (arrows). In contrast, in Braak and Braak stages II (E, arrows) and VI (F, arrows), the caspase-3 appears in the cell bodies. Scale bar = 50 μ m

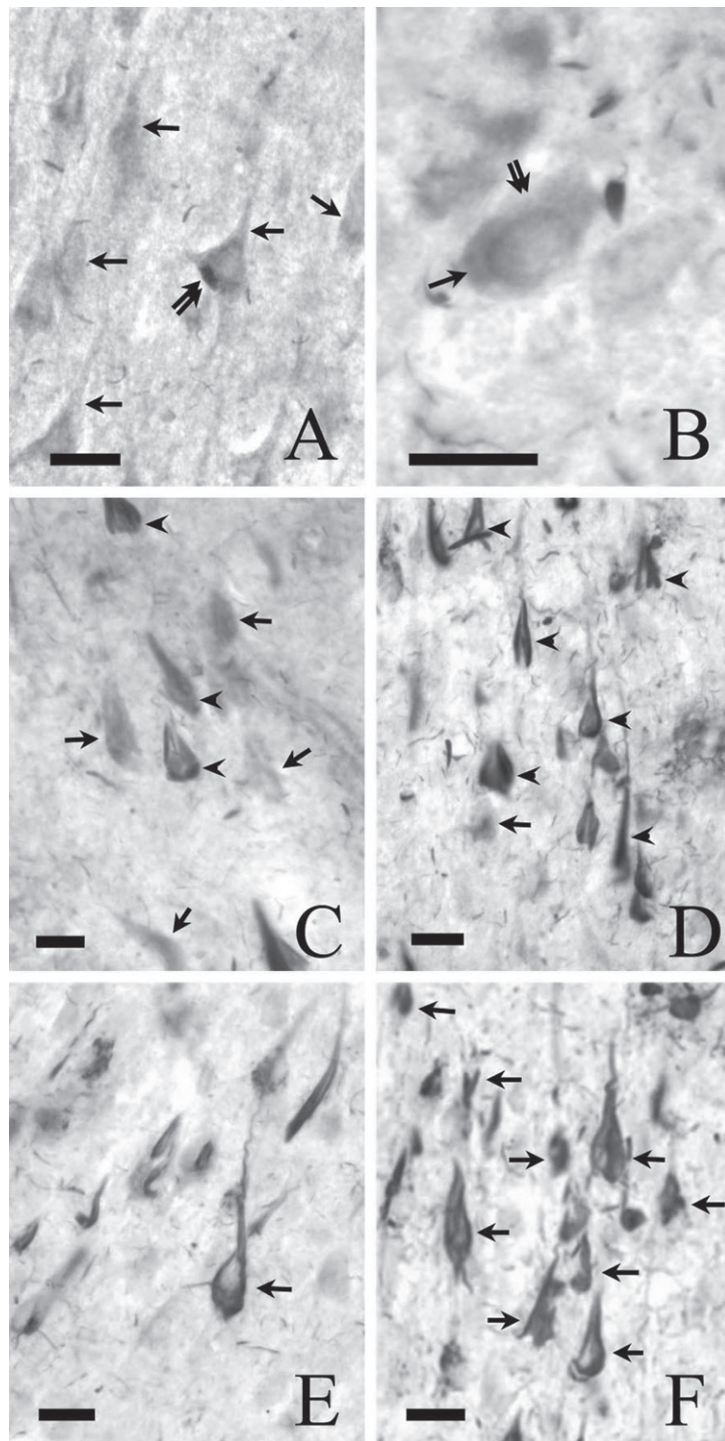


Figure 3. Activated caspase-3 labelling of tau-bearing hippocampal neurons in control samples. A: Double-labelling immunohistochemical analysis for caspase-3 (arrows) and tau (double-arrows) illustrates that only a subset of neurons are caspase-3-positive (bluish-black) and can be clearly differentiated from tau-containing neurons (brownish, double-arrows). B: Co-localization of caspase-3 (arrow) and tau (double-arrow) within a neuron. C and D: Double-immunostaining of a hippocampal tissue section from an early stage of AD (C) and a severe AD case, showing the distribution of caspase-3-positive and tau-stained neurons. In C, the caspase-3-positive neurons (arrows) seem to precede the appearance of tau-positive (arrowheads) cells. The number of tau-positive neurons (arrowheads) increases with disease severity (D), where only a few (arrow) caspase-3-positive neurons can be revealed. A similar distribution of tau-positive neurons can be demonstrated with the specific antibody for tau. In A, the number of stained neurons is lower than in the severe case of AD (F). Scale bar: 25 μ m

znick et al. 1999; Slee et al. 1999); we therefore believe that in our samples some of the neurons die by apoptosis. Accordingly, our results suggest that caspase-3 activation may begin at the synapse and, after a trans-synaptic signal it propagates in the dendrite in a retrograde fashion to the neuronal cell bodies. The A β signal therefore induces a sequence of processes which, among others, ultimately result in caspase-3 activation, tau hyperphosphorylation, apoptosis, neurofibrillary degeneration and finally cell death. We are aware, however, that, even though we have demonstrated that activated caspase-3 and tau formation are present within the same neurons, this does not imply that they must be causally interrelated events. Indeed, we were able to detect only one subset of neurons in which caspase-3 and tau were co-localized. In another subset of nerve cells, either only caspase-3 or only tau was detected. Nevertheless this does not rule out the possibility of a causal relationship between the two processes.

It is interesting to note that, in the control brain, only scattered cells exhibited caspase-3 positivity, while in the earlier stages of AD stage I and II (Braak and Braak 1991) more activated caspase-3 neurons are present than tau-positive nerve cells. In contrast, in the advanced stages of AD stage V and VI (Braak and Braak 1991), more tau-positive structures appear than activated caspase-3 nerve cells.

In conclusion, our data support the suggestion that the presynaptic axonal A β may be an initiator of the death of the postsynaptic neuron. This suggestion is supported by the appearance of caspase-3 positivity in those neurons that are in close contact with A β -positive axon varicosities. The precise mechanisms underlying the A β -induced neuronal degeneration await further elucidation.

Acknowledgments

This work was supported by ETT (Hungary) Grant No 135 04/2003.

References

- Bossy-Wetzel E, Schwarzenbacher R, Lipton SA (2004) Molecular pathways to neurodegeneration. *Nat Med* 10:S2-S9.
- Braak H, Braak E (1991) Neuropathological staging of Alzheimer-related changes. *Acta Neuropathol (Berl)* 82:239-259.
- Chen XH, Siman R, Iwata A, Meaney DF, Trojanowski JQ, Smith DH (2004) Long-term accumulation of amyloid- β , β -secretase, presenilin-1, and caspase-3 in damaged axons following brain trauma. *Am J Pathol* 165:357-371.
- Cotman CW (1998) Apoptosis decision cascades and neuronal degeneration in Alzheimer's disease. *Neurobiol Aging* 19:S29-32.
- Cowan CM, Thai J, Krajewski S, Reed JC, Nicholson DW, Kaufmann SH, Roskams AJ (2001) Caspases 3 and 9 send a pro-apoptotic signal from synapse to cell body in olfactory receptor neurons. *J Neurosci* 21:7099-7109.
- Cribbs DH, Poon WW, Rissman RA, Blurton-Jones M (2004) Caspase-mediated degeneration in Alzheimer's disease. *Am J Pathol* 165:353-355.
- Dickson DW (2004) Apoptotic mechanisms in Alzheimer neurofibrillary degeneration: cause or effect? *J Clin Invest* 114:23-27.
- Estus S, Tucker HM, van Rooyen C, Wright S, Brigham EF, Wogulis M, Rydel RE (1997) Aggregated amyloid-beta protein induces cortical neuronal apoptosis and concomitant "apoptotic" pattern of gene induction. *J Neurosci* 17:7736-7745.
- Gervais FG, Xu D, Robertson GS, Vaillancourt JP, Zhu Y, Huang J, LeBlanc A, Smith D, Rigby M, Shearman MS, Clarke EE, Zheng H, Van Der Ploeg LH, Ruffolo SC, Thornberry NA, Xanthoudakis S, Zamboni RJ, Roy S, Nicholson DW (1999) Involvement of caspases in proteolytic cleavage of Alzheimer's amyloid- β precursor protein and amyloidogenic A β peptide formation. *Cell* 97:395-406.
- Johnson EM Jr (1994) Possible role of neuronal apoptosis in Alzheimer's disease. *Neurobiol Aging* 15 Suppl 2:S187-189.
- Kasa P, Papp H, Pakaski M (2001) Presenilin-1 and its N-terminal and C-terminal fragments are transported in the sciatic nerve of rat. *Brain Res* 909:159-169.
- Rissman RA, Poon WW, Blurton-Jones M, Oddo S, Torp R, Vitek MP, LaFerla FM, Rohn TT, Cotman CW (2004) Caspase-cleavage of tau is an early event in Alzheimer disease tangle pathology. *J Clin Invest* 114:121-130.
- Rohn TT, Head E, Su JH, Anderson AJ, Bahr BA, Cotman CW, Cribbs DH (2001) Correlation between caspase activation and neurofibrillary tangle formation in Alzheimer's disease. *Am J Pathol* 158:189-198.
- Selkoe DJ (2002) Alzheimer's disease is a synaptic failure. *Science* 298:789-791.
- Selznick LA, Holtzman DM, Han BH, Gokden M, Srinivasan AN, Johnson EM Jr, Roth KA (1999) In situ immunodetection of neuronal caspase-3 activation in Alzheimer disease. *J Neuropathol Exp Neurol* 58:1020-1026.
- Slee EA, Adrain C, Martin SJ (1999) Serial killers: ordering caspase activation events in apoptosis. *Cell Death Differ* 6:1067-1074.
- Stadelmann C, Deckwerth TL, Srinivasan A, Bancher C, Bruck W, Jellinger K, Lassmann H (1999) Activation of caspase-3 in single neurons and autophagic granules of granulovacuolar degeneration in Alzheimer's disease. Evidence for apoptotic cell death. *Am J Pathol* 155:1459-1466.
- Su JH, Zhao M, Anderson AJ, Srinivasan A, Cotman CW (2001) Activated caspase-3 expression in Alzheimer's and aged control brain: correlation with Alzheimer pathology. *Brain Res* 898:350-357.