

SYMPOSIUM

Supernumerary occlusal cusps on permanent human teeth⁺Gábor S Kocsis*, Antónia Marcsik¹, Erzsébet L Kókai, Katalin S Kocsis²Department of Dentistry and Oral Surgery, ¹Department of Anthropology, ²Department of English and American Studies, University of Szeged, Szeged, Hungary

ABSTRACT Supernumerary (central) cusps that appear on the occlusal surface of the teeth have already been grouped by many authors. The most comprehensive grouping of central cusps on the premolars is that by Schulze (1987). However, different central cusp forms may occur on the molar teeth, and cusp-like protrusions may also develop on the incisors and the canines. In the present work, plaster casts of the teeth of 500 orthodontic patients (250 males and 250 females) were examined for central cusps at the above departments. The central cusps appeared on the dentition of 47.6% of the investigated Hungarian population. From a total of 13,793 teeth examined, 501 (3.69%) were observed to display a central cusp. The teeth most often affected were the mandibular first premolars (11.6%). A new central cusp form, the "margoid central cusp formation," was noted.

Acta Biol Szeged 46(1-2):71-82 (2002)**KEY WORDS**central occlusal cusps
premolars
molars
incisors
canines
morphological characteristics
population relationship

Central cusps (occlusal supernumerary cusps) are situated between the buccal and lingual cusp tips on the occlusal surface of the premolars and molars, and on the lingual surface of the incisors and canines. The first description was provided by Leigh (1925), who reported an enamel tubercle on the third maxillary right molar of an Eskimo skull. Central cusps have subsequently been described by many authors (Jyojima 1929; Yumikura and Yoshida 1936; Lau 1955; Oehlers 1956; Allwright 1958; Merrill 1964), though in different forms, on premolar, molar, incisor and canine teeth.

Some authors classify an enlarged tubercle on the lingual surface (talon cusp) of the incisors among occlusal central cusps; this is known as the dens evaginatus (Shey and Eitel 1983; Dankner et al. 1996a; Uyeno and Lugo 1996). The different forms of central cusps were grouped on the basis of their location and shapes by Lau (1955), Merrill (1964) and Schulze (1987), with special regard to the premolars.

From an anthropological point of view, the significance of the study of these cusps is that their frequencies differ from population to population. Recognition of the cusps is also important from the aspect of clinical dentistry, because they may be associated with other anomalies, and these phenomena can lead to pathological complications.

Our goal is to review the literature relating to occlusal supernumerary (central) cusps on the different tooth types, and to report data concerning these cusps in a Hungarian sample.

Forms of occlusal central cusps**Premolars**

Most of the forms of occlusal cusps can be observed on premolar teeth. Lau (1955) distinguished two groups: cusps grown out of buccal cusps, and cusps grown out of the middle of the occlusal surface. They can be smooth, grooved, terraced or ridged. Merrill (1964) slightly modified Lau's classification of the second group to include a double lingual cusp as a sub-group, although he had observed it on a lower tooth in one case only. Yip (1974) and Schulze (1987) grouped the Lau and Merrill types into one class, named the dens evaginatus.

Schulze (1987) concluded that central occlusal cusps are mainly characteristic of east Asian populations and that they rarely occur in other populations. He distinguished five different shapes on the premolars. The first and second shapes were described by Schulze himself, whereas the other three shapes were taken from the earlier literature. The shapes are as follows:

1) A cone-like enlargement of the lingual cusp. This is a gradually growing serial characteristic, with the following phases:

- a) A cone-shaped lingual cusp more distinct in the buccal direction;
- b) A significantly enlarged lingual cusp with distinct marginal wrinkles;
- c) A separately developed central cusp on the lingual crown side. The marginal wrinkles merge into a cingulum.

2) A supernumerary cusp, which is similar to the previous (c) shape. The original lingual cusp is clearly seen next to the central cusp. We have re-evaluated a case reported earlier (Kocsis, 1984) and included it in this group: a supernumerary

Accepted March 18, 2002

*Corresponding author. E-mail: kocsiss@stoma.szote.u-szeged.hu†Dedicated to Professor Gyula Farkas on the occasion of his 70th birthday.

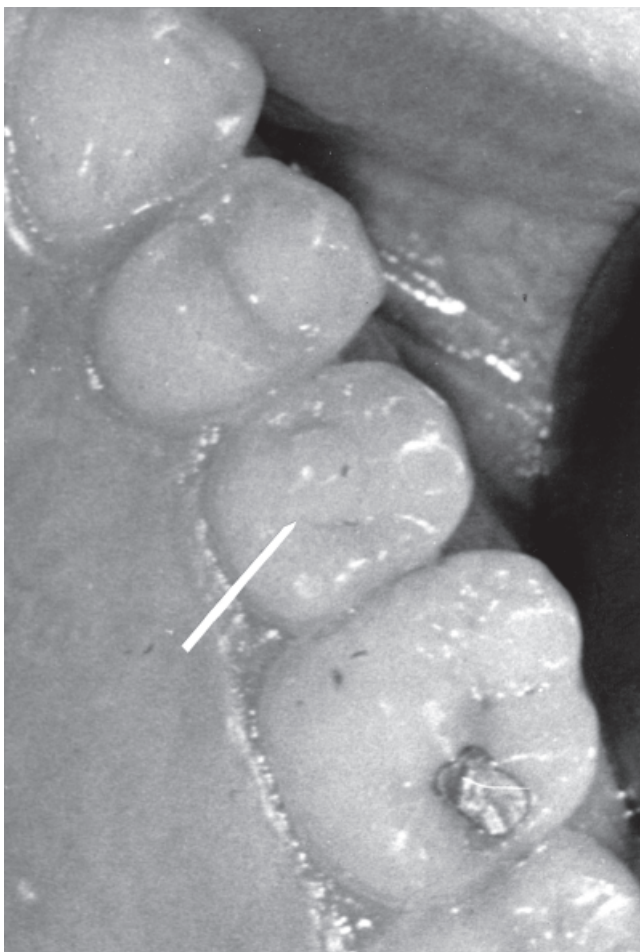


Figure 1. Supernumerary occlusal cusp on the lingual side of the maxillary left second premolar of a Hungarian girl. The central cusp is larger than the normal cusp.

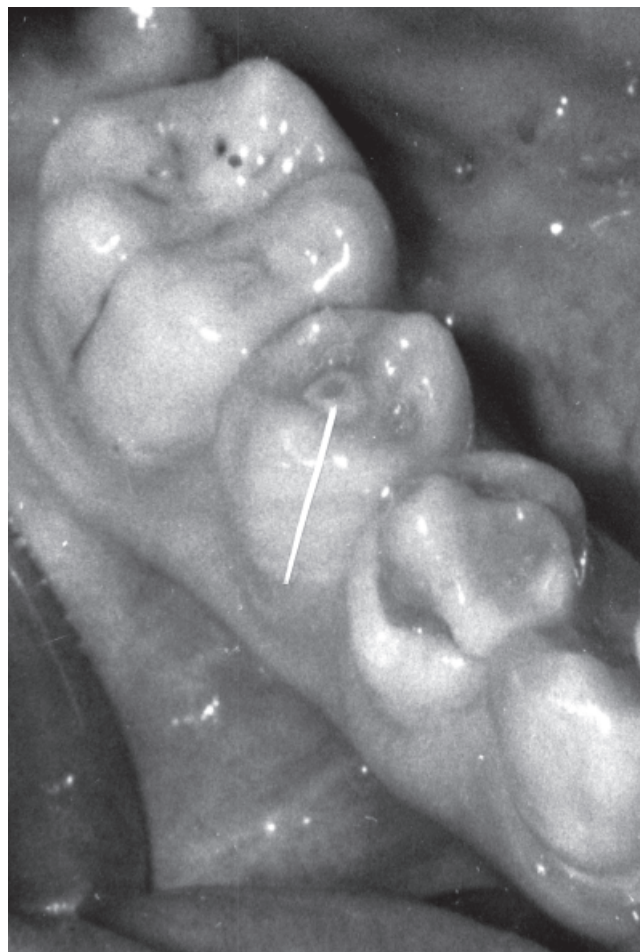

Figure 2. Dens evaginatus on the lower second premolar of a Vietnamese girl. The central cusp is worn, a dentinal island can be seen.

occlusal cusp on the maxillary left second premolar (Fig. 1) of a 12-year-old Hungarian girl. There is no familial history of this trait.

3) The dens evaginatus is the best-known central cusp. It is an extra cusp, a form of a tuberculum arising from the occlusal surface. The term dens evaginatus was recommended by Yip (1974) and it is the most frequently used term today; however, there are other terms: premolar odontomes, occlusal tubercles, or tuberculated premolars (see Scott and Turner 1997). Such occlusal cusp formations were first described by Japanese authors (Jyojima 1929; Matsumura 1934; Yumikura and Yoshida 1936). Kato (1937) reported that they were present in 1.09% of the Japanese population. The types and locations of the dens evaginatus are known from the publications of Lau (1955) and Merrill (1964).

The dens evaginatus appears in different populations of East Asian ancestry, with a frequency of 0.5-4.3% (Table 1). The term “Mongoloid or oriental premolar” reflects its occurrence; it appears with different frequencies in Japanese,

Chinese, Malayan, Eskimo, American Indian and Thai populations (Curzon et al. 1970; Reichart and Tantiniran 1975). A dens evaginatus was found on the premolar of a Vietnamese patient treated in Hungary (Fig. 2). Several authors have described evagination on premolars in Filipinos (Villa 1956; Villa et al. 1959; Poyton and Vizcarra 1965; Senia and Regezi 1974).

As regards Sub-Saharan Africans, the literature mentions only 2 cases (Table 1). In one of these, a dens evaginatus was found by Pearlman and Curzon (1977) on the second left mandibular premolar of a male, while the other case was discovered by Ciechanowski and Sonnenberg (1981), on both mandibular first premolars and the second right premolar of a female. In the latter case, one of the female’s great-grandmothers was partly Cherokee Indian. The teeth of her parents and siblings showed no evidence of this anomaly.

The above form of the dens evaginatus occurs rarely in Europeans (Table 1). Palmer (1973) described it in 4 British males and considered that the accentuated lingual aspect of

Table 1. The prevalence of dens evaginatus in different populations.

Author(s)	Year	Population	No. of affected persons	%
Yumikura and Yoshida	1936	Japanese	17	-
Kato	1937	Japanese	-	1.09
Pedersen	1949	Eskimo (Greenland)	5	0.50
Lau	1955	Chinese	27	1.29
Wu	1955	Chinese	19	1.44
		Chinese	16	1.52
Oehlers	1956	Malays	110	-
Sumiya	1959	Japanese	-	1.88
Merrill	1964	Eskimo (Amerindian)	28	4.30
Oehlers et al.	1967	Chinese (Malays)	43	-
Curzon et al.	1970	Eskimo (Canada)	12	3.00
Yip	1974	Chinese	21	3.60
		Malay	3	1.10
		Indo-europoid	-	-
Reichart and Tantniran	1975	Thai	51	1.01
Goto et al.	1979	Japanese	53	0.12
Lin and Roan	1980	Chinese (Taiwan)	305	3.52
Villa	1956	Filipino	1	-
Villa et al.	1959	Filipino	2	-
Poyton and Vizcarra	1965	Filipino	1	-
Senia and Regezi	1974	Filipino	1	-
Palmer	1973	Caucasian (British)	5	-
Sykaras	1974	Caucasian (Greek)	1	-
Pearlman and Curzon	1977	Negro	1	-
Ciechanowski and Sonnenberg	1981	Negroid	1	-

the buccal cusp on the premolars of the sister of one of the males was also most probably a dens evaginatus. Sykaras (1974) observed this anomaly on the premolars of a Greek female.

Evagination can be associated with other developmental anomalies: invagination, an extra premolar and mesiodens (Yip 1974; Geist 1989) and three-rooted mandibular molars (Senia and Regezi 1974).

The clinical significance of this disorder is that the elevation sooner or later becomes damaged, breaks off or wears away during use of the tooth. In a large majority of the cases, the root canal opens and the pulp chamber becomes infected. As a result of the malocclusion of the teeth, complications can develop: irregular development of the root, or the tooth becomes irregularly positioned and loosens (Allwright 1958; Reichart and Tantniran 1975; Goto et al. 1979).

4) An extra occlusal cusp is situated on the lingual surface of the buccal cusp. It resembles an enamel pearl. Nishijima et al. (1959) described it in Japanese as “several cases of central tubercle on the lingual ridge of buccal cusp of upper bicuspid” (p. 1209). In all probability, the same phenomenon was described by Pedersen (1949), who reported an occlusal pearl on a maxillary second premolar, in 2 cases unilaterally on mandibular second premolars, and bilaterally on a second and a first premolar pair. He stated that “in the East Greenland Eskimo dentition we meet with anatomical features the significance of which, if any, is obscure, ... the occlusal pearl-like excrescences” (p. 214).

5) Kirveskari et al. (1972) described bulging of the lingual aspect of the buccal cusps in Lapps. This was observed on the lingual ridge of the buccal cusps of premolars, and also on the mesiobuccal cusp of molars. It occurs symmetrically and seems to be more frequent on the maxillary teeth and also on the second premolars and first molars. The dentin does not show this bulge. They presumed that it occurs widely in Northern populations. Schulze (1987) also considered it to be population-specific. The same type of central cusp was found by Kutscha (1985) on a premolar in a German population sample. It seems likely that the accentuated lingual ridge of the buccal cusp on the premolars of a British girl mentioned by Palmer (1973) also belongs here.

Marcsik and Kocsis (1986) carried out a survey of 31 skulls from the 8th century (A.D.) in Hungary that encompassed 79 upper and 58 lower premolars. (The data on central cusps are unpublished.) The above-described form of central cusps was found on 7 premolars (5.11%) (Fig. 3).

Molars

The central cusps on the occlusal surface of molar teeth have also been classified as dens evaginatus (Lau 1955; Merrill 1964; Oehlers et al. 1967).

A central tubercle was described by Pedersen (1949) as “a peculiar enamel pearl-like ‘cusp’ on the occlusal surface” (p. 85) on the right upper molar of an Eskimo from Greenland. In his opinion, the case of an American Eskimo reported by Leigh (1925) had the same form.

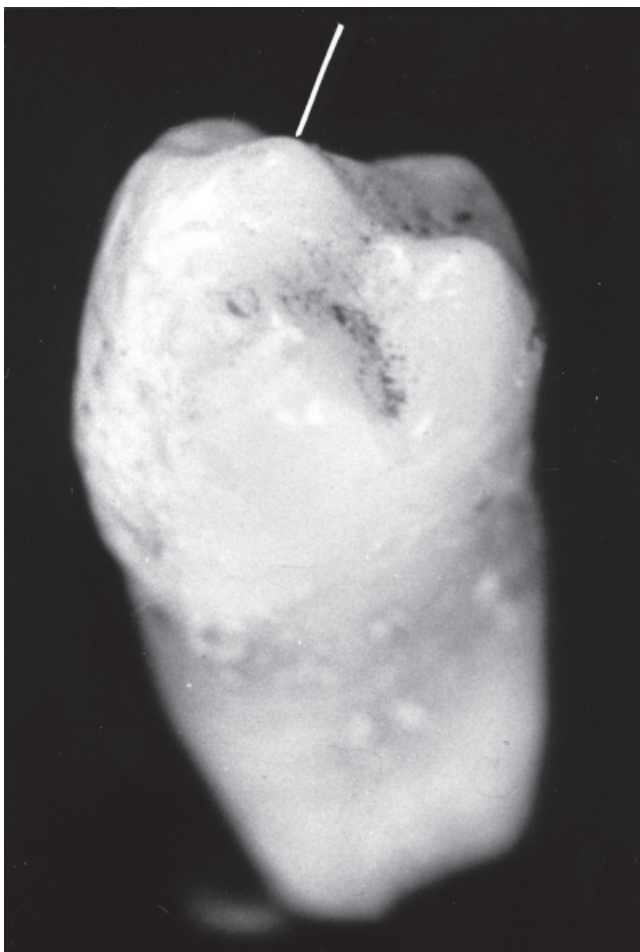


Figure 3. Bulging of the lingual surface of the buccal cusp of a lower right second premolar. Archeological material, 8th century. Juvenile specimen.

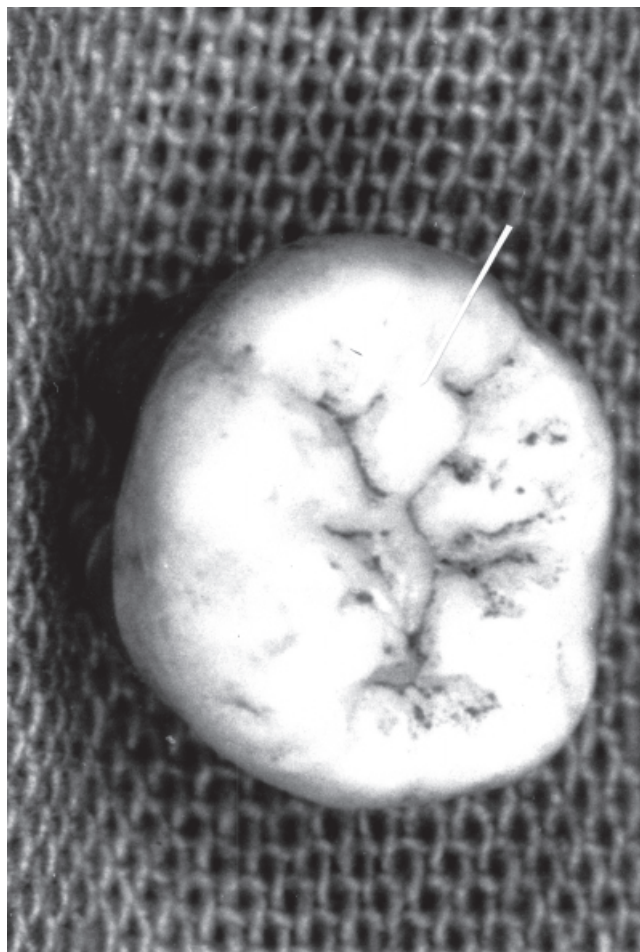


Figure 4. Occlusal enamel pearl on the lower right second molar. Archeological material, 8th century. Juvenile specimen.

Kirveskari et al. (1972) analysed bulging of the lingual aspect of buccal cusps on molars, similar to that on premolars. The third molar was the least affected, and the maxillary first molar and the second premolar were the most commonly affected.

Marsik and Kocsis (1986) examined – from the above mentioned material – 106 upper and 86 lower molars of the 31 skulls, and found that bulging of the lingual aspect of the buccal cusps occurred on 8 maxillary molars (4.16%). Occlusal enamel pearl was found on 2 lower molars (Fig. 4).

Incisors and canines

The dens evaginatus occurs in a similar way on canines and even on incisors; as a result of the vulnerability of the elevation, it has the same clinical significance (Lau 1955; Oehlers 1956; Allwright 1958; Merrill 1964; Goto et al. 1979).

The talon cusp was recently reported as a subclass of the dens evaginatus (Dankner et al. 1996a, b; Uyeno and Lugo 1996), and as an accessory cusp on the lingual (rarely on the buccal; McNamara 1997) surface of the anterior teeth. The first recorded case of a talon cusp originates from 1892, when Mitchell described it as “a process of hornlike shape, curving from the base downward to the cutting edge”. It may form a connection with the incisal edge to produce a T-form or a Y-shaped crown contour (de Jonge 1959; Hattab et al. 1996). This form is referred to in the dental anthropological literature as the “triform variant” (Bailey-Schmidt 1995). If the anomaly appears with occlusion, it has similar clinical significance to that of the dens evaginatus (Uyeno and Lugo 1996). The reported prevalence of talon cusp ranges from 0.06% to 7.7% (Chawla et al. 1983; Sedano et al. 1989). An investigation of 1997 skulls ranging in origin from the Neolithic to the Middle Ages in Hungary revealed anomalies on anterior teeth (Kocsis 1994). In this study the overall

prevalence of lingual tubercles among all of the evaluated maxillary teeth ($n=6,383$) was 2.41%, and the lingual cusps, the talon cusp form occurred on 2 maxillary lateral incisors.

This cusp can arise on primary anterior teeth, too (Henderson 1977; Mader and Kellogg 1985; Chen and Chen 1986; Meon 1990; Rusmah 1991). It can be associated with other dental disorders, such as agenesis, peg-shape, supernumerary teeth, impaction, shovel-shape, bifid cingulum, the dens invaginatus, a labial groove, an accessory cusp or an accessory root on other teeth and the dens evaginatus of posterior teeth (Mader 1981; Natkin et al. 1983; Davis and Brook 1985; Acs 1992; Hattab et al. 1996). The etiology of the talon cusp is unknown. As it occurs with other anomalies of tooth number and size, it may have a multifactorial etiology, involving both genetic and environmental factors (Davis and Brook 1985), which accounts for its occurrence with other features.

Pedersen (1949, p.174) recorded 6 upper canines with enamel pearl on the "inciso-lingual" surface in 4 Eskimo dentitions. They seem to be similar to the cases reported on the anterior teeth by Lau (1955), Allwright (1958) and Goto et al. (1979).

Kirveskari et al. (1972) described bulging of the lingual aspect of the buccal cusps on premolars and molars, which is sometimes found on the lingual aspect of the canine cusp tip, too.

Central cusps in syndromes

A syndromic characteristic is the occurrence of central cusps on both premolars and molars in lobodontia (Robbins and Keene 1964; Shuff 1972; Schulze 1976; Brook and Winder 1979) in an unusual triad: microdontia, taurodontia and dens invaginatus (Casamassimo et al. 1978), and in multiple anomalies of teeth which are similar to lobodontia but differ from it in several ways (Ekman-Westborg and Julin 1974; Reichart and Triadan 1977; Reichart et al. 1978; Miiikada et al. 1995; Ritzau et al. 1997, Yoda et al. 1998). Another case was described in a 5-year-old child from the 15th century as a variant of the Ekman-Westborg-Julin syndrome, but dens evaginatus is not characteristic (Mann et al. 1990).

A case of lobodontia was also reported by Kocsis et al. (1994). In the permanent dentition of a 16-year-old boy, the anomaly affected practically all the teeth (irregular tooth form, hypodontia, delayed tooth eruption and diminished tooth size). Since this publication, the patient's lower left third molar has erupted and has now been examined. On the occlusal surface of the tooth, a large central cusp can be observed, surrounded by more than 10 smaller cusps. The large occlusal cusp is separated from the smaller cusps by a deep groove (Fig. 5).

The talon cusp – dens evaginatus on anterior teeth – appears to be more prevalent in the Rubinstein-Taybi syndrome (Gardner and Girgis 1979), the Mohr syndrome

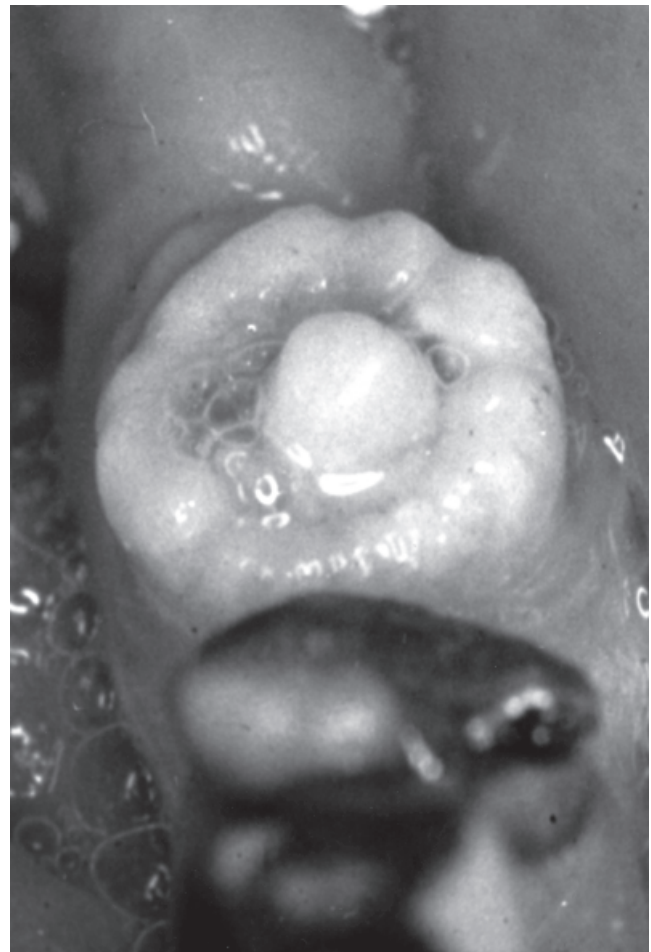

Figure 5. A large central cusp on the lower left third molar of a patient with lobodontia.

(Goldstein and Medina 1974), the Sturge-Weber syndrome (Davis and Brook 1985) or incontinentia pigmenti acromians (Tsutsumi and Oguchi 1991).

The purpose of this study is twofold: 1) determination of the association of cusp types with each other and with specific teeth; 2) identifiable cusp types (those statistically identified) with sex.

Materials and Methods

A total of 500 plaster casts of dentitions were at the authors' disposal for central cusp examination. These study models had been produced at the University of Szeged, from impressions taken from orthodontic patients aged between 12 and 23 years (mean age 14.7 years) in 1997. The ratio of males and females was 1:1.

All of the 500 models used in the present study met the following conditions: all of the permanent teeth (excluding third molars) were present in the dentition to permit con-

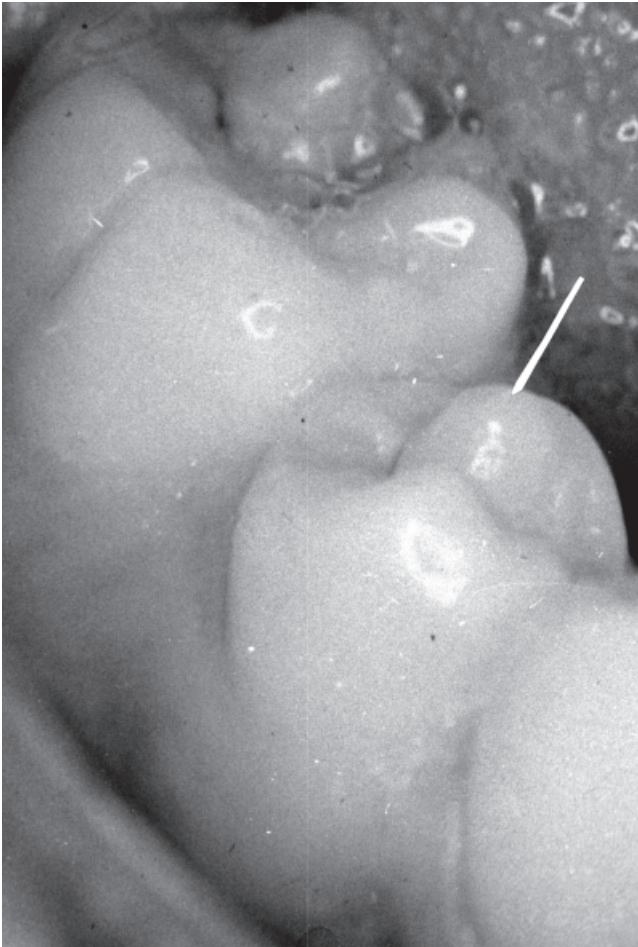


Figure 6. Cone-shaped lingual cusp enlarged in vestibular direction on a lower right second premolar.

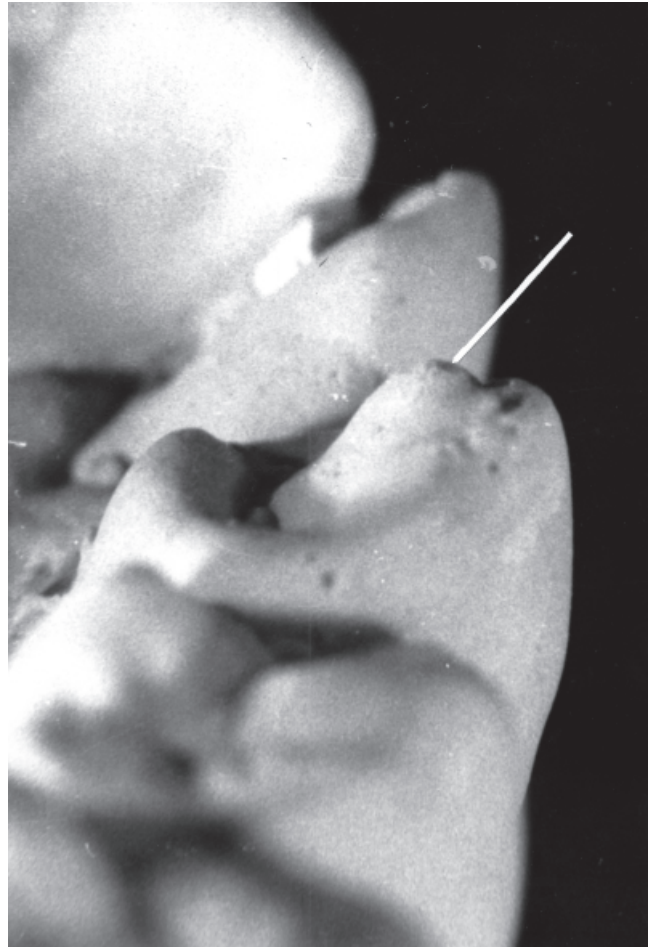

Figure 8. Bulging of the lingual surface of a buccal cusp of a lower second premolar in the investigated sample.

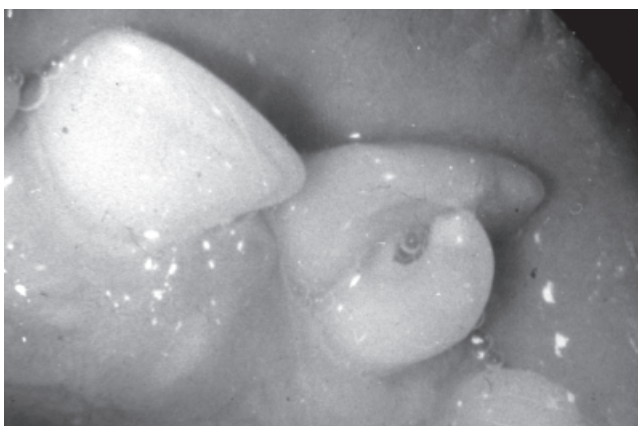

Figure 7. Talon cusp. Marked abnormal cusp on lingual surface of a permanent maxillary central incisor.

firmation of the identity of the teeth, and relevant crown areas (see later) were completely or almost completely intact.

The number of teeth suitable for investigation was less than the number of models could have allowed because third molars, unerupted teeth and filled teeth were excluded. Thus 6,897 teeth for males and 6,896 teeth for females constituted the sample.

On the basis of our literature review, we define central cusp as a supernumerary macrostructure of the tooth surface, representing a cusp formation on the occlusal surface of premolars and molars, and on the lingual surface of canines and incisor teeth. The macrostructure of a central cusp involves not only the strengthening of the original enamel layer of a cusp, but also the presence of a circumscribed, well-defined elevation. The surrounding cusp enamel may sometimes be separated from the cusp by a mild groove. The types of central cusps can be characterized as given below.

Type 1) Registration surface: occlusal. Enlargement or bulging on the buccal surface of a lingual cusp of premolars

Table 2. Frequency of central cusps in a Hungarian sample.

	Males teeth	Females teeth	Total teeth
Lingual conical cusp (type 1)			
premolars	1,984	1,986	3,970
with cusp	22(1.1%)	42(2.11%)	64(1.61%)
molars	1,940	1,931	3,871
with cusp	12(0.61%)	25(1.29%)	37(0.95%)
total posterior teeth	3,924	3,917	7,841
with cusp	34(0.87%)	67(1.71%)	101(1.29%)
Separated lingual cusp (type 2)			
posterior teeth	3,924	3,917	7,841
with cusp	5(0.13%)	1(0.03%)	6(0.08%)
Buccal bulging (type 5)			
all of teeth	6,897	6,896	13,793
with cusp	141(2.04%)	204(2.96%)	345(2.5%)
Lingual tuberculum (type 6)			
max. anterior teeth	1,476	1,483	2,959
with cusp	9(0.6%)	8(0.53%)	17(0.57%)
Margoid (type 8)			
posterior teeth	3,924	3,917	7,841
with cusp	24(0.61%)	26(0.66%)	50(0.64%)

and molars in the faciolingual direction. The lingual cusp is cone-shaped (Fig. 6).

Type 2) Registration surface: occlusal. A separately developed macrostructure can be seen on the lingual crown side on premolars and molars. The original lingual cusp still exists, and the macrostructure can be identified as a supernumerary lobe/central cusp located close to the lingual cusp (Fig. 1).

Type 3) Registration surface: occlusal. A supernumerary cusp on the occlusal surface arising from or near the groove between the original buccal and lingual cusps of premolars and molars. The central cusp type is the dens evaginatus (Fig. 2).

Type 4) Registration surface: occlusal on the posterior teeth, and lingual on the anterior teeth. A pearl-like enlargement is situated on the lingual surface of a buccal cusp in faciolingual direction on premolars and molars (Fig. 4). This central cusp type is the occlusal enamel pearl. It may sometimes occur on canines, too.

Type 5) Registration surface: occlusal on the posterior teeth, and lingual on the anterior teeth. Bulging of the lingual aspect of a buccal cusp on premolars (Fig. 3) and molars, and bulging of the lingual aspect of the central lobe on canines and incisors.

Type 6) Registration surface: lingual. Various degrees of supernumerary cusp formation on the lingual surface of the anterior teeth, developing from the lingual tuberculum or from the cingulum (Fig. 7).

Type 7) Registration surface: occlusal on the posterior teeth, and lingual on the anterior teeth. Occlusal (or lingual) supernumerary macrostructure of teeth in the case of syndromes (Fig. 5).

Types 8) Registration surface: occlusal on the posterior teeth, and lingual on the anterior teeth. This is a new type of central cusp not previously described in the literature.

After these types had been established, definitive registration was performed on the casts. Each individual tooth was examined with the aim of determining a positive or negative result for all types, as well as the common existence of types, and any association with other dental anomalies. The observations were made by visual inspection, and with a magnifying glass at magnification X 8, and a direct light was used.

The association of central cusp types with specific teeth were given by a relative frequency, as well as differences in the distribution of central cusp types between males and females, were determined with chi-square tests. A probability level of 1% was employed as the level of significance.

Results and Discussion

The data revealed that central cusps were present in 47.6% of these 500 Hungarian dentitions: in 148 females (59.2%) and in 90 males (36%).

Four of the forms mentioned in the literature were found in the material investigated:

- 1) a cone-shaped lingual cusp enlarged in the buccal direction (type 1; 101 teeth);
- 2) a separately developed central cusp on the lingual crown side (type 2; 6 teeth);
- 3) bulging of the lingual aspect of the buccal cusp (type 5; 345 teeth);
- 4) an enlarged lingual tubercle on the anterior teeth, including the talon cusp (type 6; 17 teeth).

Table 3. Frequency of central cusps in all tooth types (males).

Teeth	Total	7	6	5	4	3	2	1
No. upper teeth	3,431	474	487	494	500	478	498	500
Lingual conical cusp (type 1) %	2 0.06	-	-	2 0.40	-	-	-	-
Separated lingual cusp (type 2) %	2 0.06	-	-	2 0.40	-	-	-	-
Buccal bulging (type 5) %	81 2.36	12 2.53	15 3.08	30 6.07	12 2.40	12 2.51	-	-
Lingual tuberculum (type 6) % (Talon cusp form)	9 0.26 (1)	-	-	-	-	8 1.67	1 0.20 (1)	-
Margoid (type 8) %	2 0.06	-	-	2 0.40	-	-	0.20	-
No. central cusps	96	12	15	36	12	20	1	-
No. lower teeth	3,466	484	495	490	500	497	500	500
Lingual conical cusp (type 1) %	32 0.92	5 1.03	7 1.41	18 3.67	2 0.40	-	-	-
Separated lingual cusp (type 2) %	2 0.06	-	-	-	2 0.40	-	-	-
Buccal bulging (type 5) %	60 1.73	-	-	16 3.27	25 5.00	19 3.82	-	-
Lingual tub. (type 6)	-	-	-	-	-	-	-	-
Margoid (type 8) %	22 0.63	-	-	1 0.20	21 4.20	-	-	-
No. central cusps	116	5	7	35*	50**	19	-	-

*Simultaneous occurrence of buccal bulging and lingual conical cusp on same tooth in 3 cases

** Simultaneous occurrence of buccal bulging and lingual conical cusp on same tooth in 6 cases

Besides these four types of central cusps, a new cusp form was observed (type 8; 50 teeth). Data on the prevalence of these various central cusps are presented in Tables 2-4.

The most frequent type as regards all types of teeth was the bulging of the lingual aspect of the buccal cusp (type 5; Fig. 8). Its incidence was 2.5%, and it seemed to be more widespread in females (2.96%) than in males (2.04%); the difference between the sexes was significant ($p=0.00059$). The trait generally occurred symmetrically in the dentition, but sometimes with different expressivities on the two sides. It was most frequent on the mandibular first premolars (6.90%) and the maxillary second premolars (6.86%), followed by the maxillary second molars (4.63%). The frequencies on premolars and molars were 5.31% and 2.06%, respectively. As concerns the molars, this anomaly was more developed on the mesiobuccal cusp than on the distobuccal cusp.

In contrast with our results, Kirveskari et al. (1972) considered that this type of central cusp is more frequent on maxillary second premolars and first molars. They mentioned that this anomaly is sometimes found on the lingual aspect of the canine cusp tip. Our results demonstrated that the trait can also occur on cuspids but on incisors, too. In the 8th century sample the prevalence of lingual bulging of the buccal cusp on premolars was 5.12%, while that on molars was 4.16% (Marcsik and Kocsis 1986). These results suggest

that it is a common trait in both past and present populations.

Another frequent trait was the cone-shaped form of the lingual cusp enlarged in the buccal direction (type 1) on premolars (1.61%) (Fig. 6); this central cusp form also occurred on the mesiolingual cusp of molars (0.95%). Altogether, its prevalence on posterior teeth was 1.29% (females: 1.71%, males: 0.87%); the difference between females and males was significant ($p=0.00098$). The lower mandibular second premolars were most commonly affected (5.2%) (Fig. 6).

Among the anterior teeth, the maxillary incisors and canines displayed enlarged (lingual) tubercles (type 6) in 0.57% of the cases. From these central cusps, a talon cusp was found in 3 cases (Fig. 7). Tables 3 and 4, relating to the maxillary anterior teeth, reveal two further prevalences: that of the enlarged lingual cusp, and (in parentheses) that of the talon cusp. It is necessary to distinguish the lingual tubercle from its talon form: the horn-like protuberance of Mitchell (1892), and the "eagle's talon" of Mellor and Ripa (1970). Hattab et al. (1996) suggested a system of lingual cusp classification based on the degree of their formation and extent (talon, semitalon and trace talon). Some authors probably reported mixed cases of the forms, and the frequency therefore presumably varies between 0.06% (Sedano et al. 1989) and 7.7% (Chawla et al. 1983). Other data indicates that the incidence of the dens evaginatus of anterior teeth may

Table 4. Frequency of central cusps in all tooth types (females).

Teeth	Total	7	6	5	4	3	2	1
No. upper teeth	3,448	477	491	497	500	484	499	500
Lingual conical cusp (type 1)	-	-	-	-	-	-	-	-
Separated lingual cusp (type 2)	-	-	-	-	-	-	-	-
Buccal bulging (type 5) %	128 3.71	32 6.71	20 4.07	38 7.65	29 5.80	9 1.86	-	-
Lingual tuberculum (type 6) %	8 0.23	-	-	-	-	-	7 1.40	1 0.20
(Talon cusp form) %	(2) 0.06	-	-	-	-	-	(1) 0.20	(1) 0.20
Margoid (type 8) %	3 0.09	-	3 0.61	-	-	-	-	-
No. central cusps		139	32	23	38	29	9	7 1
No. lower teeth	3,448	478	485	489	500	496	500	500
Lingual conical cusp (type 1) %	67 1.94	17 3.56	8 1.65	33 6.75	9 1.80	-	-	-
Separated lingual cusp (type 2) %	2 0.06	1 0.21	-	1 0.20	-	-	-	-
Buccal bulging (type 5) %	76 2.20	1 0.21	-	17 3.48	44 8.80	12 2.42	2 0.40	-
Lingual tuberculum (type 6)	-	-	-	-	-	-	-	-
Margoid (type 8) %	23 0.67	-	-	-	23 4.60	-	-	-
No. central cusps	168	19	8	51*	76**	12	2	-

*Simultaneous occurrence of buccal bulging and lingual conical cusp on same tooth in 5 cases

**Simultaneous occurrence of buccal bulging and lingual conical cusp on same tooth in 4 cases

vary according to the population examined (Dankner et al. 1996a).

The separately developed central cusp on the lingual crown side (type 2) was the least frequent (5 premolars and 1 molar). Kutscha (1985) originally described this form on premolars, and Schulze (1987) identified it as the type 2 form of central cusp. In Schulze's classification of central cusps on premolars, this form is close to the type 1/3 form. We did not distinguish between the two forms, and it is described in our material as type 2. The case of a Hungarian girl investigated by Kocsis (1984) involves also the same form.

A new central cusp form (type 8) was also recorded. This phenomenon does not seem to have been reported previously in the literature on central cusps. This trait appeared on premolars, forming an enamel crest and binding the buccal enlargement on the lingual cusp and the lingual bulging on the buccal cusp. It therefore involves a type 1 and a type 5 central cusp form connected to each other via an enamel ridge. The dentin layer also displayed this structure. On the molars, it was seen as an enlargement of the transversal crest between the mesiolingual and distobuccal cusps. From a morphological point of view, this condition is similar to the margoid differentiation on the anterior teeth (de Jonge 1959), and the anomaly may therefore be referred to as a "margoid central cusp formation" (Fig. 9). On all the posterior teeth, its prevalence was 0.64%; it was seen most frequently on

mandibular first premolars (4.40%). In the course of the examinations, the simultaneous occurrence of central cusp forms was also recorded. The forms more frequently appeared symmetrically for types 5, 6 and 8, but the other types (1 and 2) more often appeared asymmetrically. The types appeared on various teeth, with the same type (type 5) on premolars and molars on both the upper and lower dentitions. The different types occurred together in one dentition infrequently; type 1 with type 5, type 5 with type 6, or type 5 with type 8. However, an association of different forms on one tooth was found only for bulging of the lingual aspect of the buccal cusps and cone-shaped lingual cusp enlarged in the buccal direction on premolars: this occurred on 18 teeth (10 first and 8 second mandibular premolars) (Tables 3 and 4). This association may be the initial form of type 8 (two central cusp forms without binding).

From the aspect of the associations of the central cusps with other dental abnormalities, it seems that the "margoid central cusp formation" may be connected with compression of the premolar crown in the bucco-lingual direction. Of the 3,970 premolars investigated, 17 mandibular premolar crowns exhibited a compression form, 11 of which were connected with the above-mentioned margoid central cusp.

It was also observed that central cusps figured on the teeth of 2 of the males, among the 17 patients with cleft (5 females and 12 males). Central cusps associated with syndromes were



Figure 9. “Margoid central cusp formation” on a lower left first premolar in the investigated material.

not found either on anterior teeth or in the posterior region of the dentitions examined. These syndromes appear very rarely and did not feature in our patients.

From the total of 13,793 teeth, the number with central cusps was 501 (3.69%). (The total number of central cusps was 519, but in 18 cases types 1 and 5 appeared together on the same tooth.) The teeth most affected were the mandibular first premolars (11.6%), second mandibular premolars, maxillary first premolars, and molars also displayed these traits quite often, they were less frequent on the mandibular incisors.

The male teeth to female teeth ratio relating to central cusps was 212:307 ($p=0.000015$). In both sexes, most of the affected teeth exhibited bulging on the buccal cusp, then cone-shaped lingual cusps and margoid central cusp formation. However, enlarged lingual cusps and separately developed central cusps on the lingual side of the crown were more frequent in males.

The dens evaginatus, a form of central cusp is most frequently discussed in the literature. Population studies of the irregularity and the examination of some families (Merrill 1964; Oka et al. 1964) indicate that the dens evaginatus is inherited autosomal and dominant (Stewart et al. 1978). At the same time, Pearlman and Curzon (1977) regarded it as a developmental aberration. Among the patients investigated, two pairs of identical twins displayed the same of central cusps (types 1, 5 and 6). This suggests a hereditary component in the etiology of the central cusp forms studied.

Conclusion

The “central cusp” is a group term, since the types of central cusps differ, and there are large differences in the frequency, the symmetric occurrence and the infrequent simultaneous appearance of different cusp forms, in one dentition or on one tooth. The traits are connected only through their local-

ization: they occur on the occlusal surface, inside the tip area of the buccal and lingual cusps on the posterior teeth and on the lingual surface of the anterior teeth. The importance of the investigation of the central cusps is in outline as follows.

For dental practice among the central cusps the dens evaginatus and the talon cusp are of significance. The elevation sooner or later becomes damaged and produces a secondary pathology that manifests itself as pulpitis, periodontitis, periostitis, among others.

The dens evaginatus and the talon cusp are the central cusp forms most widely investigated in an effort to learn. The talon cusp has been reported on deciduous teeth, but the deciduous dentition has not yet been investigated with regard to the other cusps. The connection between the talon and some syndromes are well known, and the dens evaginatus on the anterior and on the posterior teeth appears in multiple anomaly forms (e.g., lobodontia), but there has been no description of its appearance in syndromes. Determination of the genetic factors involved in the production of central cusp forms is desirable.

The other traits described in this paper are dental polymorphisms, and their existence enlarge the battery of traits that can be used in descriptions of recent and paleodontological forms of the human dentition. The central cusp forms may be referred to as “non-metric” traits. They occur on all permanent tooth types, and can be used in the examination of population history.

Acknowledgments

This research was supported by the National Scientific Research Foundation (OTKA grant No. T029606), for which the authors are grateful.

References

- Acs G (1992) Shovel incisors, three-rooted molars, talon cusp and supernumerary on one patient. *Paediatr Dent* 13:236-237.
- Allwright WC (1958) Odontomes of the axial core type as a cause of osteomyelitis of the mandible. *Br Dent J* 104:363-365.
- Bailey-Schmidt S (1995) The Triform Variant: I. Definition, classification and population distribution. *Dent Anthropol Newslett* 9:8-9.
- Brook AH, Winder M (1979) Lobodontia – a rare inherited dental anomaly. Report of an affected family. *Br Dent J* 147:213.
- Casamassimo PS, Nowak AJ, Ettinger RL, Schlenker DJ (1978) An unusual triad: microdontia, taurodontia, and dens invaginatus. *Oral Surg Oral Med Oral Pathol* 45:107-112.
- Chawla HS, Tewary A, Gopalakrishnan NS (1983) Talon cusp – a prevalence study. *J Ind Soc Pedo Prev Dent* 1:28-34.
- Chen RJ, Chen HS (1986) Talon cusp in primary dentition. *Oral Surg Oral Med Oral Pathol* 62:67-72.
- Ciechanowski DJ, Sonnenberg EM (1981) Dens evaginatus in a negroid girl: report of case. *J Dent Child* 48:450-452.
- Curzon MEJ, Curzon JA, Poyton HG (1970) Evaginated odontomes in the Keewatin Eskimo. *Br Dent J* 129:324-328.
- Dankner E, Harari D, Rotstein I (1996) Dens evaginatus of anterior teeth. Literature review and radiographic survey of 15,000 teeth. *Oral Surg Oral Med Oral Pathol* 81:472-476.
- Dankner E, Harari D, Rotstein I (1996a) Conservative treatment of dens

- evaginated of anterior teeth. *Endod Dent Traumatol* 12:206-208.
- Davies PJ, Brook AH (1985) The presentation of talon cusp: diagnosis, clinical features, associations and possible aetiology. *Br Dent J* 159:84-88.
- Ekman-Westborg B, Julin P (1974) Multiple anomalies in dental morphology: macrodontia, multituberculism, central cusps, and pulp invaginations. *Oral Surg Oral Med Oral Pathol* 38:217-222.
- Gardner DG, Girgis SS (1979) Talon cusps: a dental anomaly in the Rubinstein-Taybi syndrome. *Oral Surg Oral Med Oral Pathol* 47:519-521.
- Geist JR (1989) Dens evaginatus. Case report and review of the literature. *Oral Surg Oral Med Oral Pathol* 67:628-631.
- Goldstein E, Medina JL (1974) Mohr syndrome or oral-facial-digital II: report of two cases. *J Am Dent Assoc* 89:377-382.
- Goto T, Kawahara K, Kondo T, Imai K, Kishi K, Fujiki Y (1979) Clinical and radiographic study of dens evaginatus. *Dentomaxillofac Radiol* 8:78-83.
- Hattab FN, Yassin OM, Al-Nimri KS (1996) Talon cusp in permanent dentition associated with other dental anomalies: review of literature and reports of seven cases. *J Dent Child* 63:368-376.
- Henderson HZ (1977) Talon cusp: a primary or a permanent incisor anomaly. *J Indiana Dent Assoc* 56:45-46.
- de Jonge ThE (1959) Margoide Differenzierung des "tuberculum dentis". *Dtsch Zahnärztl Zeitschr* 14:520-522.
- Jyojima T (1929) Occlusal anomalous tubercle on premolars. *Nihon no Shikai* 109:257.
- Kato K (1937) Contribution to the knowledge concerning the cone-shaped supernumerary cusp in the center of the occlusal surface on the premolars of Japanese. *Nihon Kyosei-Shika Gakkai Zasshi* 30:28-49.
- Kirveskari P, Hedegard B, Dahlberg AA (1972) Bulging of the lingual aspects of buccal cusps in posterior teeth of skolt lapps from Northern Finland. *J Dent Res* 51:1513.
- Kocsis SG (1994) Macro-morphological developmental anomalies and their prevalence in permanent frontal teeth originating from excavations. Thesis. *Anthrop Közl* 36:85-95.
- Kocsis SG (1984) Dens evaginatus. *Fogorv Szle* 77:142-146.
- Kocsis SG, Szentpetery A, Kocsis A, L-Kokai E (1994) Lobodontia. *Acta Biol Szeged* 40:77-84.
- Kutscha B (1985) Morphologische Variationen und Anomalien im Prämolarenbereich bei 1400 kieferorthopädischen Patienten. Med Diss Berlin.
- Lau TC (1955) Odontome of the axial core type. *Br Dent J* 99:219-225.
- Leigh RW (1925) Dental pathology of the Eskimo. *Dent Cosmos* 67:884-898.
- Lin LC, Roan RT (1980) Incidence of dens evaginatus investigated from three junior middle schools at Kaohsiung City. *Formosan Sci* 34:113-121.
- Mader CL (1981) Talon cusp. *J Am Dent Assoc* 103:244-246.
- Mader CL, Kellogg SL (1985) Primary talon cusp. *J Dent Child* 52:223-226.
- Mann RW, Dahlberg AA, Stewart TD (1990) Anomalous morphologic formation of deciduous and permanent teeth in a 5-year-old 15th century child: A variant of the Ekman-Westborg-Julin syndrome. *Oral Surg Oral Med Oral Pathol* 70:90-94.
- Marcsik A, Kocsis SG (1986) The connections of the anomalies of tooth in paleoanthropological material. Proceedings of the VI. European Meeting of the Paleopathology Association, Madrid. p 237-239.
- Matsumura S (1934) Supernumerary cusp on the occlusal surface of the human premolar. *Nihon Shikagakukai Zasshi* 27:464.
- McNamara T (1997) An unusual talon cusp. *Dent Anthropol Newslett* 11:19.
- Mellor JK, Ripa LW (1970) Talon cusp: a clinically significant anomaly. *Oral Surg Oral Med Oral Pathol* 29:225-228.
- Meon R (1990) Talon cusp in primary dentition - case report. *Sing Dent J* 15:32-40.
- Merrill RG (1964) Occlusal anomalous tubercles on premolars of Alaskan Eskimos and Indians. *Oral Surg Oral Med Oral Pathol* 17:484-496.
- Miikada N, Amano H, Ohyama K, Kuroda T (1995) A case report of macrodontia with unusual tooth shape. 5. European Craniofacial Congress, Copenhagen, Abstract p. 27.
- Mitchell WH (1892) Case report. *Dental Cosmos* 34:1036.
- Natkin E, Pitts DL, Worthington P (1983) A case of talon cusp associated with other odontogenic abnormalities. *J Endodont* 9:491-495.
- Nishijima S, Yoshida S, Kobayashi M, Yutaka K (1959) Several cases of central tubercle on the lingual ridge of buccal cusp of upper bicuspid. *J Osaka Univ Dent Soc.* 4:1207-1212.
- Oehlers FAC (1956) The tuberculated premolar. *Dent Pract Dent Rec* 6:144-148.
- Oehlers FAC, Lee KW, Lee EC (1967) Dens evaginatus (Evaginated odontome). Its structure and responses to external stimuli. *Dent Pract Dent Rec* 17:239-244.
- Oka M, Igarashi S, Tomita R, Tsukano H (1964) Central cusp on the occlusal surface of premolar found in one sister and two brothers and a case of radicular cyst associated with the tubercle. *J Japan Stomat Soc* 14:52.
- Palmer ME (1973) Case reports of evaginated odontomes in Caucasians. *Oral Surg Oral Med Oral Pathol* 35:772-779.
- Pearlman J, Curzon M (1977) An Evaginated Odontome in an American Negro: Report of Case. *J Am Dent Assoc* 95:570.
- Pedersen PO (1949) The East Greenland Eskimo dentition. *Meddelelser on Grönland. Vol. 142. Bianco lunos, Copenhagen.* pp 85, 156, 163, 165, 174, 214.
- Poyton HG, Vizcarra ER (1965) Three evaginated odontomes: case report. *J Can Dent Assoc* 31:439-442.
- Reichart P, Tantiniran D (1975) Dens evaginatus in the Thai. An evaluation of fifty-one cases. *Oral Surg Oral Med Oral Pathol* 39:615-621.
- Reichart P, Triadan H (1977) Kombinierte Zahnformanomalien - ein neues Syndrom? Autoreferat. *Dtsch Zahnärztl Z* 32:733.
- Reichart PA, Triadan H, Lenz H (1978) Polyanomalodontia. *J Oral Pathol* 7:100-108.
- Ritzau M, Carlsen O, Kreiborg S, Brinch-Iversen J, Gorlin RJ, Rasmussen NH (1997) The Ekman-Westborg-Julin syndrome. Report of a case. *Oral Surg Oral Med Oral Pathol Oral Radiol Endod* 84:293-296.
- Robbins IM, Keene HJ (1964) Multiple morphologic dental anomalies: report of a case. *Oral Surg Oral Med Oral Pathol* 17:683-690.
- Rusmah M (1991) Talon cusp in Malaysia. *Aust Dent J* 36:11-14.
- Scott GR, Turner II CG (1997) The anthropology of modern human teeth. Dental morphology and its variation in recent human populations. Cambridge University Press, p 35-37.
- Schulze Ch (1987) Anomalien und Missbildungen der menschlichen Zähne. Quintessenz Verlags GmbH, Berlin pp:94-101.
- Schulze Ch (1976) Erbbedingte Formanomalien sämtlicher Zähne - ein neues Syndrom? *Zahnärztl Welt Rekord* 85:80-84, 178-182.
- Sedano OH, et al. (1989) Clinical orodontal abnormalities in Mexican children. *Oral Surg Oral Med Oral Pathol* 68:300-311.
- Senia ES, Regezi JA (1974) Dens evaginatus in the etiology of bilateral periapical involvement in caries-free premolars. *Oral Surg Oral Med Oral Pathol* 38:465-468.
- Shey Z, Eytel R (1983) Clinical management of an unusual case of dens evaginatus in a maxillary central incisor. *J Am Dent Assoc* 106:346-348.
- Shuff RY (1972) Patient with multiple conical teeth. *Dent Pract* 22:414.
- Stewart RE, Dixon GH, Graber RB (1978) Dens evaginatus (tuberculated cusps): genetic and treatment consideration. *Oral Surg Oral Med Oral Pathol* 46:831-836.
- Sumiya Y (1959) Statistic study on dental anomalies in the Japanese. *J Anthropol Soc Nippon, Jinruigaku Zasshi* 67:215-233.
- Sykaras SN (1974) Occlusal anomalous tubercle on premolars of a Greek girl. *Oral Surg Oral Med Oral Pathol* 38:88-91.
- Tsutsumi T, Oguchi H (1991) Labial talon cusp in a child with incontinentia pigmenti achromians: case report. *Pediatr Dent* 13:236-237.
- Uyeno DS, and Lugo A (1996) Dens evaginatus: a review. *J Dent Child* 63:328-332.
- Villa VG (1956) Chronic periapical abscess with external sinus associated

- with the so-called "Leong's Premolar". *Philippines Med Dent J* 2:19.
- Villa VG, Bunag GA, Ramos AB (1959) Developmental anomaly in the form of an occlusal tubercle with central canal which serves as a pathway of infection to the pulp and periapical region. *Oral Surg Oral Med Oral Pathol* 12:343-348.
- Wu KL (1955) Survey on mid-occlusal tubercle in bicuspid. *China Stomat* 3:294.
- Yip WK (1974) The prevalence of dens evaginatus. *Oral Surg Oral Med Oral Pathol* 38:80-87.
- Yoda T, Ishii Y, Honma Y, Sakai E, Enomoto S (1998) Multiple macrodonts with odontoma in a mother and son - a variant of Eckman-Westborg - Julin syndrome. Report of a case. *Oral Surg Oral Med Oral Pathol Oral Radiol Endod* 85:301-303.
- Yumikura S, Yoshida K (1936) Abnormal cusp on the occlusal surface of the human premolar. *J Japan Stomat Soc* 10:73.