

## PALEOPATHOLOGICAL DIAGNOSIS AND INTERPRETATION OF SERONEGATIVE SPONDYLARTHROPATHIES FROM THE 17TH CENTURY

G. HORVÁTH<sup>1</sup>, E. MOLNÁR<sup>1</sup>, J. KOVÁCS<sup>2</sup>, E. WICKER<sup>3</sup>, J. BÉRATO<sup>4</sup> and GY. PÁLFI<sup>1</sup>

<sup>1</sup>*Department of Anthropology, József Attila University, H-6701 Szeged, P.O.B. 660, Hungary;*

<sup>2</sup>*Department of Radiology, Szeged Hospital, H-6701 Szeged, P.O.B. 455, Hungary;*

<sup>3</sup>*Thorma János Museum, 6400 Kiskunhalas, Köztársaság u. 2., Hungary;*

<sup>4</sup>*Centre de Rhumatologie Gimelli, 83000 Toulon and Centre Archéologique du Var, 14 Bd. de Bazeilles,  
Toulon, France.*

(Received: December 3, 1994)

### Abstract

This paper discusses two possible cases of seronegative spondylarthropathy. The bony remains of two adult male skeletons from a 17th century cemetery at Bácsalmás exhibit erosive and proliferative pathological lesions. The osteoarticular alterations affect the skeletons in numerous locations. The major pathology in both cases is fusion of the lumbar vertebrae by the formation of syndesmophytes. Some thoracic and cervical segments are also affected. Inflammatory changes, in the form of erosive articular (sacroiliac and acromioclavicular joints) or periarticular (humeri and calcanei) lesions, and entesopathies of some ligament or tendon insertions can be detected in both cases. The morphology of the lesions emphasizes ankylosing spondylitis as a form of undifferentiated seronegative spondylarthropathy. In the knowledge of the heritability of the factors which predispose to the disease, and the neighboring location of the two graves in the cemetery, a family relationship may be suggested between the two individuals.

*Key words:* paleopathology, 17th century, seronegative spondylarthropathies, ankylosing spondylitis.

### Introduction

Pathological changes involving the joints are frequently seen in paleopathological material. In addition to the much more common degenerative joint diseases, different types of inflammatory joint disorders can be recognized (ORTNER and PUTSCHAR, 1985).

The group of seronegative spondylarthropathies (SNSA) is an entity distinct from rheumatoid arthritis (RA). Serologically, a common feature of the group is the absence of the rheumatoid factor (an anti-immunoglobulin) from the serum (ROGERS and WALDRON, 1986). Another common serological character is the high association with the histocompatibility antigen HLA-B27 (GÖMÖR and BÁLINT, 1989).

As for the skeletal manifestations, spondylarthropathy represents a subset of arthritis, characterized by erosive joint disease, ossification sites of tendons and

ligaments, and a tendency to spine and sacroiliac fusion. This group of arthropathies includes ankylosing spondylitis (AS), Reiter's syndrome, psoriatic arthritis, entheropathic arthropathies and undifferentiated spondylarthropathies (RESNICK and NIWAYAMA, 1988).

The medical literature and studies of series of documented defleshed bones have provided data for the paleopathological identification of spondylarthropathies (e.g. ORTNER and PUTSCHAR, 1985; Rogers et al., 1987; ROTHSCHILD and WOODS, 1991). AS, characterized by symmetric sacroiliitis, spinal new-bone formation and some typical extraspinal changes, is the best known of the group and has been most frequently diagnosed in archeological specimens. Osteoarcheological collections document the existence of the disease long before the modern era (e.g. STEINBOCK, 1976; KRAMAR, 1980, 1987; ORTNER and PUTSCHAR, 1985; GOMEZ BELLARD and SANCHEZ SANCHEZ, 1989; PÁLFI, 1990; FERENCZ, 1991). We also have data concerning the existence of other forms of spondylarthropathies from prehistorical periods, for example psoriatic arthritis from an Early Holocene African population (DUTOUR et al., 1994).

### Materials and Methods

A paleopathological examination was carried out on 83 skeletons from a 17th century cemetery at Bácsalmás-Homokbánya. The cemetery consisted of 91 graves and was excavated in 1993 by the archeologist of the Thorma János Museum at Kiskunhalas. The coins found in some graves revealed that the cemetery was in use during the 17th century (WICKER, manuscript). Historical data helped with identification of the excavated cemetery (IVÁNYI, 1909; BOROVSKY, 1910). It was used by a Serbian community living at Bácsalmás during the Turkish occupation of Hungary.

The examined skeletons are to be found in the collection of the Department of Anthropology at József Attila University. The majority of the skeletal material is in a good or medium state of preservation.

The sex and age at death were determined with traditional methods used in historical anthropology (FEREMBACH et al., 1979; KNUSSMAN, 1988). The differential diagnosis was based on macromorphological and X-ray methods. Both clinical and paleopathological special literature were used (e.g. ORTNER and PUTSCHAR, 1985; RESNICK and NIWAYAMA, 1988; LE LOET and BRUNO, 1990; BAHK, 1994). Radiological analyses were carried out at the Department of Radiology, Szeged Hospital.

### Results and Discussion

Signs of polyarticular inflammatory processes with proliferative spinal affection were detected in two cases in the skeletal material from the Bácsalmás cemetery. The two cases are presented separately; however, the similarity of the lesions demands a common discussion.

### Descriptions:

*Case No. 1: Grave No. 80. Male skeleton. Aged adult; good state of preservation.*

The anthropological examination revealed that the adult man was at last 70 years old when he died. Besides the typical age-related skeletal changes, the *in vivo* lack of the complete set of teeth, the severe atrophy of the alveolar processes and the typical symmetrical thinness of the parietal bones (identical to that in the case presented by PERROT and BILLARD (1982) in the paleopathological literature) are to be mentioned.

In spite of the advanced age of this individual at death, the only sign of degenerative articular process is the slight secondary osteoarthritis of the left ankle, following a healed fracture of the left medial malleolus.

Bilateral enthesopathic aspects, in the form of erosions and slight new-bone formation at the site of tendon insertions, can be observed on the posterior part of the calcanei and the ischial tuberosities.

Signs of a more advanced stage and bilateral erosive process are to be seen in both sacroiliac joints (Fig. 1). Multiple erosions and remodeled holes are present on the auricular surfaces of the ilia and the sacrum; the process predominates in the ilium.

The major pathological changes of the skeleton are the spinal lesions. As all of the elements of the spine are available, the location of the alterations can be easily recognized.

- Cervical spine: C1-C2: slight marginal osteophyte formation in the median atlanto-axial joint. C3-C7-(T1): erosive changes of the vertebral bodies and some of the apophyseal joints. Advanced stage alterations in segments C5-C6, which display fusion by marginal osseous bridging and ankylosis in the discovertebral and apophyseal joints (Fig. 2).
- Thoracic spine: T1-T7: no pathological changes. T7-T12: localized, erosive discovertebral lesions. Signs of inflammatory processes of the costovertebral joints in segments T9- T12. Collapse of the anterior margin of T11 and bony ankylosis of T11-T12 (Fig. 3a).
- Lumbar-spine: L1-L5: the five lumbar segments are fused in a single block. (Fig. 3b-d). Syndesmophyte-like new-bone formation, with preservation of disc space, is present in segments L2-L3 and L3- L4. Extensive central and peripheral discovertebral lesions are also present in segments L1-L2 and L4-L5 (Fig. 3c).

*Case No. 2: Grave No. 90. Male skeleton. Aged adult; very good state of preservation.*

The age at death of the second subject must have been considerably lower than in the first case (in case No. 2, the man died in his sixties).

The quasi-complete and robust skeleton presents a relatively good state of




Fig. 1: Erosive changes on the two ilia, suggesting bilateral symmetric sacroiliitis. (Case No. 1: Grave No. 80)




Fig. 2: Ankylosis of vertebrae C5-C6 by marginal osseous bridging. (Case No. 1: Grave No. 80)

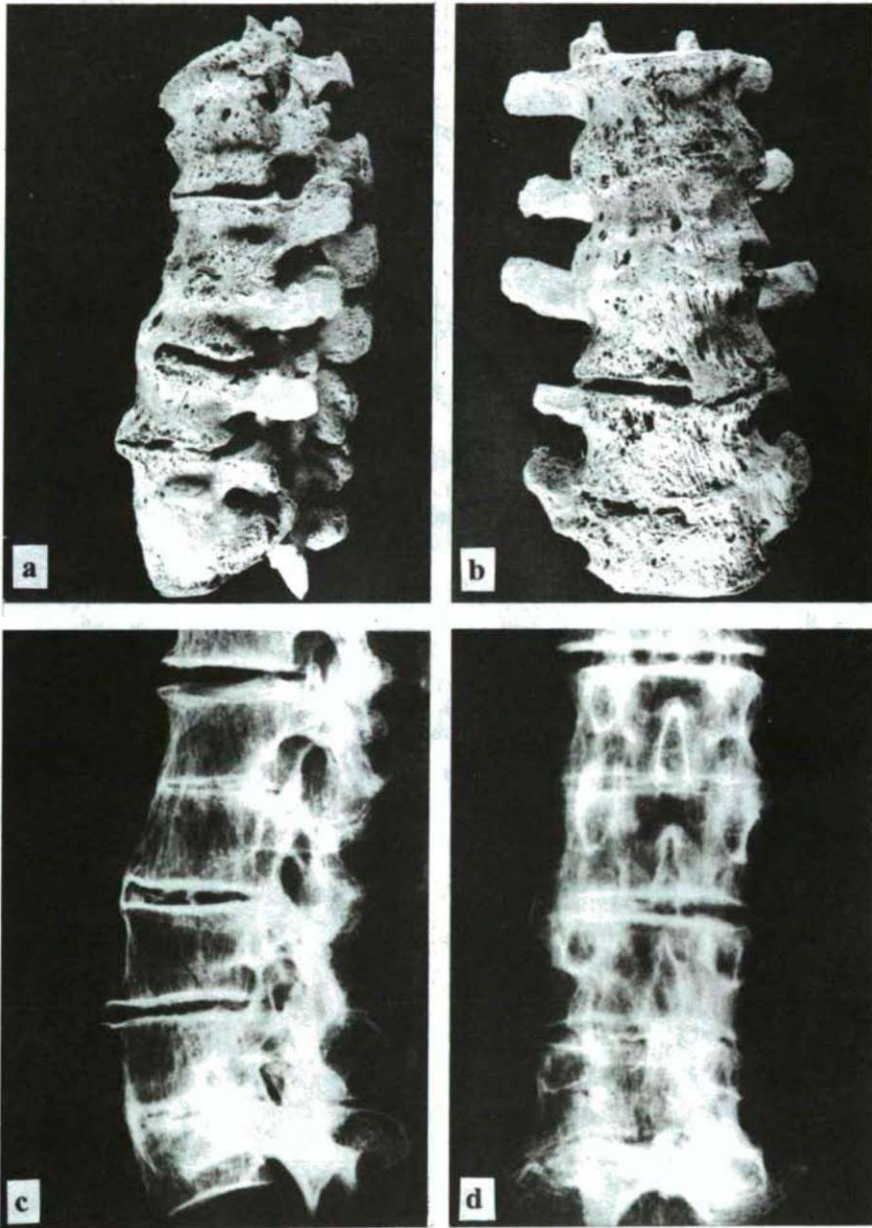


Fig. 3a-d: Lateral and antero-posterior macroscopic (a-b) and X-ray pictures (c-d) of the lumbar and thoracolumbar segments. Syndesmophytosis and ankylosis are to be mentioned. (Case No. 1: Grave No. 80)

mineralization. As for the pathological conditions, a lytic bony response to the abscessed second incisor, canines and second premolar can be observed on the left maxilla. The significant alveolar resorption is indicative of periodontal disease. Lesions due to a previous trauma are seen on the skeletal remains of the left hand. The second and third left metacarpals and the second proximal phalanx exhibit signs of healed fractures, deformation and posttraumatic arthrosis.

Enthesopathic alterations can be observed in several locations. Bilateral abnormalities of the ligament attachments (proliferations and erosions) are detected on the ischial tuberosities, the trochanters of the femurs, the posterior and inferior parts of the calcanei (Fig. 4) and the radial tuberosities.

Bilateral articular and periarticular erosive lesions affect both shoulders (greater tubercles of the humeri and acromioclavicular joint surfaces of the clavicles and scapulae) and wrists. Only a more precise morphological examination can reveal the very slight, early stage alterations of the two side sacroiliac joints.

The most important pathological alterations affected the vertebral column.

-Cervical spine: C1-C2: periarticular osteophytes in the median atlanto-axial joint (atlas), with partial calcification of the apical ligament to the dens (axis). C3-C7: erosive changes and marginal new-bone formation affect the vertebral bodies and apophyseal joints. Segments C4-C6 are most strongly involved (Fig. 5).

-Thoracic spine: No pathological signs between segments T1-T4. T4-T8: erosive lesions in the apophyseal joints. T6-T12: slight, bilateral erosions in the costovertebral joints. The signs of Schmorl's nodes must be mentioned.

-Lumbar spine: L1-L5: ankylosis of the five lumbar segments (Fig. 6a-d). Widespread marginal bony bridges lead to fusion of the vertebral bodies. The intervertebral discs are partially ossified, especially between L1 and L3 (Fig. 6c-d).

### Discussion

The considerable similarity of the morphology and skeletal patterns of the detected lesions in the two cases allow their discussion together.

There are some pathological lesions in both cases, where the morphological character suggest localized independent processes, such as the healed fractures and secondary posttraumatic arthroses (cases 1 and 2), or the dental and periodontal disease in case 2.

The widespread articular and periarticular lesions suggest the possibility of generalized diseases in both cases.

The morphology of the erosive lesions observed in some extraspinal and vertebral locations suggests inflammatory joint (or periarticular) disease (ROTHSCHILD et al., 1990). The affection of the sacroiliac joints, especially in case 1, reveals bilateral sacroiliitis. The alterations predominate in the ilium in both cases. (According to the

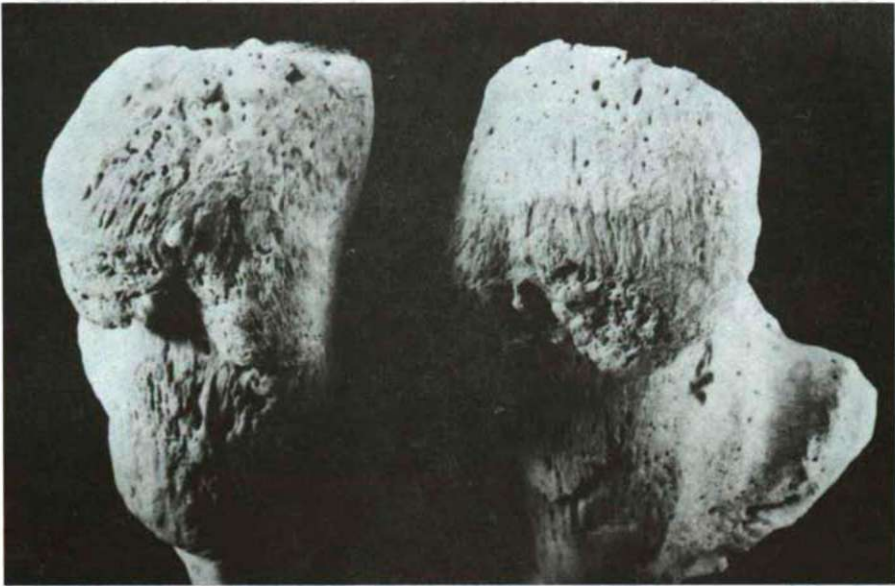

Fig. 4: Enthesopathies on the posterior and inferior parts of the calcanei. (Case No. 2: Grave No. 90)

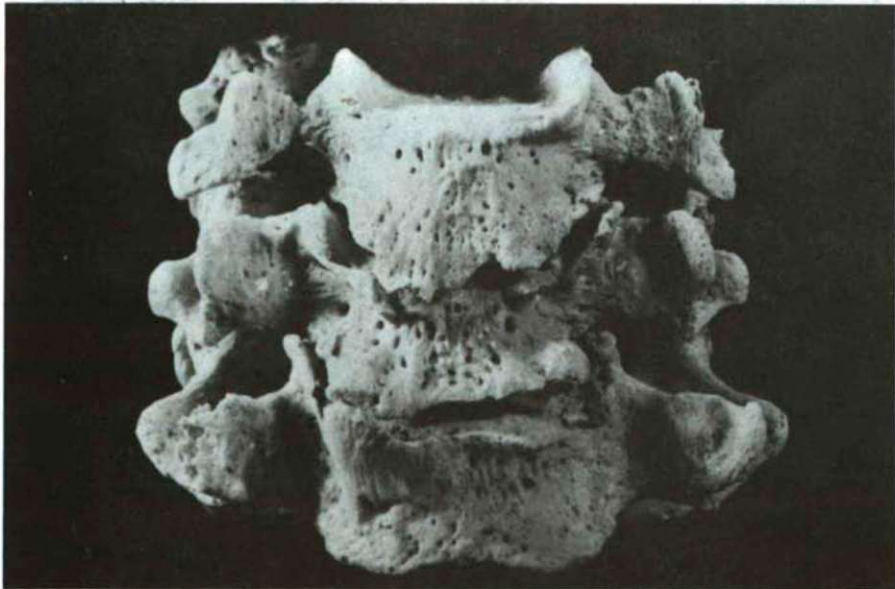

Fig. 5: Marginal proliferative lesions on vertebrae C4-C6. (Case No. 2: Grave No. 90)

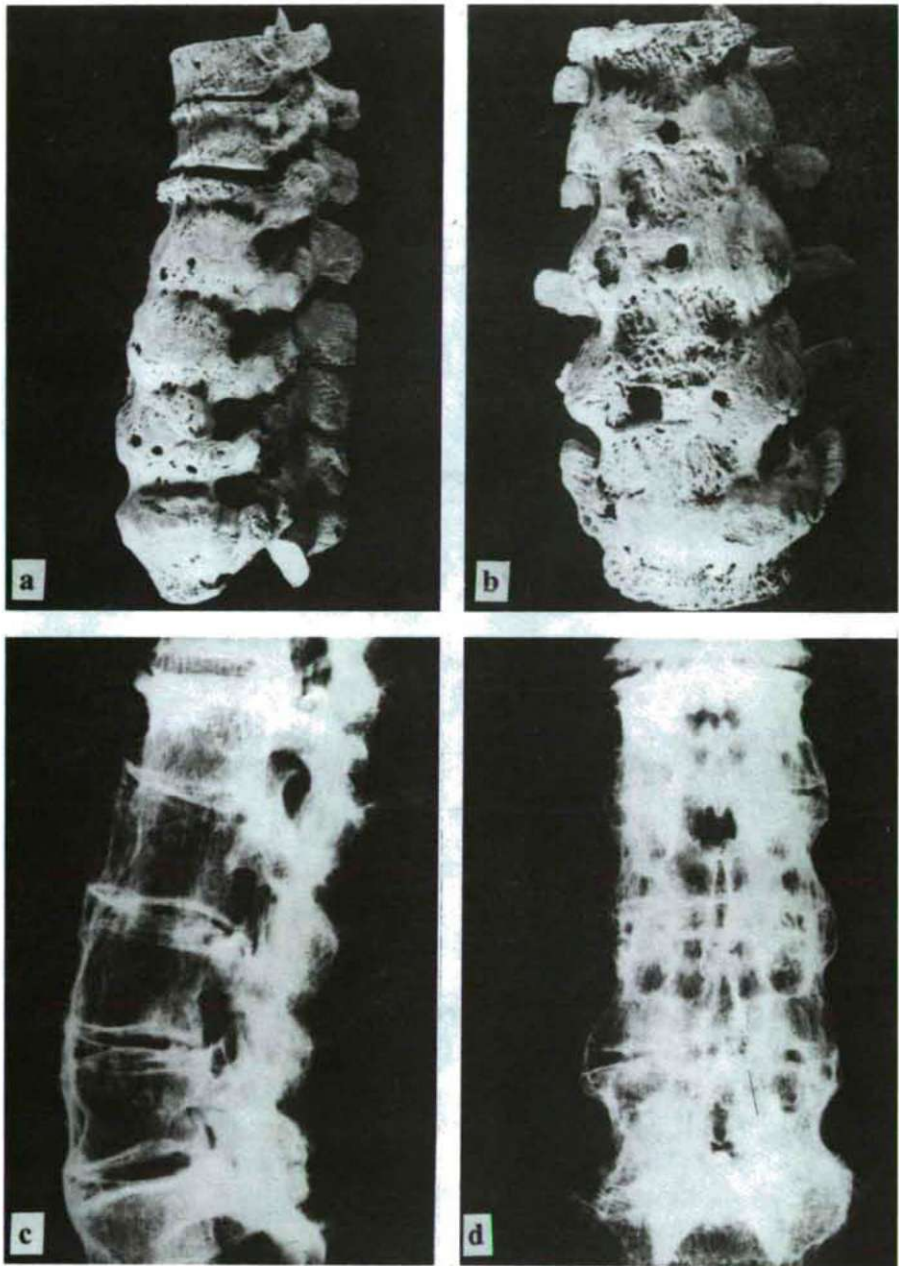


Fig. 6a-d: Lateral and antero-posterior macroscopic (a-b) and X-ray pictures (c-d) of the lumbar and thoracolumbar segments. Syndesmophytosis and ankylosis are must be mentioned. (Case No. 2: Grave No. 90)



literature data (RESNICK and NIWAYAMA, 1988), this phenomenon results from the iliac cartilage being thinner than that of the sacrum.)

The erosive lesions localized to the central subchondral portions of the discovertebral junction are associated with reactive sclerosis. There are no signs, however, of irregular single or multifocal osteolytic lesions, geode-like erosions, irregular destruction of the vertebral bodies, sequestrum formation or abscesses, as in the case of infective spondylitis (BAHK, 1994).

The presence of the proliferative lesions and the para-erosional new-bone formation is in marked contrast to the minimal or absent para-erosional new-bone formation noted in RA (ROTHSCHILD et al., 1990; ROTHSCHILD and WOODS, 1991).

The proliferative lesions are possible consequences of a multifocal enthesopathy. (The enlarged term of entheses is used here according to FOURNIÉ and FOURNIÉ (1992) to denote all of the sites of insertion of ligaments, tendons, capsules and intervertebral discs into the bone.) In the two examined cases, proliferative enthesopathies affect predominantly the intervertebral discs, e.g. the osseous bridging through the anulus fibrosus (syndesmophytes) on the lumbar and cervical spine, the apophyseal joints and some extravertebral ligament insertions.

The enthesopathic character of some extraspinal ligament or tendon insertions can be associated with numerous metabolic, inflammatory, infectious, traumatic or microtraumatic conditions (SIMON et al., 1991). Enthesopathies in the observed and above-mentioned locations (bicipital tuberosity of the radius, trochanters of the femurs and ischial tuberosities) have already correlated with the syndromes of overuse in the paleopathological literature (DUTOIR, 1986; MILLER, 1992; PÁLFI, 1992). In our case, however, the more widespread character of the lesions and their coexistence with the observed inflammatory changes help us to exclude this possibility.

There is an association of proliferative vertebral lesions and extraspinal enthesopathies in cases of diffuse idiopathic skeletal hyperostosis (DISH) (ARLET and MAZIERES, 1985; GÖMÖR and BÁLINT, 1989). In DISH, however, the massive, vertical osteophytes are seen predominantly on the right anterolateral surface of the vertebral bodies of the thoracic spine, and the disc spaces and facet joints are always normal (ROGERS et al., 1987).

According to the morphology and skeletal pattern of the observed erosive and proliferative inflammatory lesions and the specific literature data (ROGERS and WALDRON, 1986; RESNICK and NIWAYAMA, 1988; GÖMÖR and BÁLINT, 1989; ROTHSCHILD and WOODS, 1991; DOUGADOS, 1993; BAHK, 1994), the presumed diagnosis in the examined cases is seronegative spondylarthropathy.

Within the group of SNSA, the classification and the differential diagnosis are often difficult, especially in the early stage or in atypical cases (MAU et al., 1987; ZEIDLER, 1987). The relatively well-developed character of the observed lesions help their more precise diagnosis.

The symmetric sacroiliitis, spinal syndesmophytosis and fusion, and the above-

mentioned extraspinal enthesopathies (e.g. the changes detected on the inferior surface of the calcanei) suggest the diagnosis of AS (RYCKEWAERT, 1980; GRAN et al., 1984; SIMON et al., 1984; FELLMAN, 1985; ROGERS et al., 1987; GÖMÖR and BÁLINT, 1989; LE LOET and BRUNO, 1990).

The symmetric pattern of the sacroiliitis is an important clue in this disease and may permit its differentiation from other disorders, such as psoriasis, Reiter's syndrome, RA and infection (RESNICK and NIWAYAMA, 1988).

As for the syndesmophytosis, the connection of the vertical outgrowths to the vertebral edges allows their differentiation from the paravertebral ossification of psoriasis and Reiter's syndrome (which begins at a distance from the vertebral body and intervertebral disc) (RESNICK and NIWAYAMA, 1988; LE LOET and BRUNO, 1990). In AS, its marked tendency towards chondral-type ossification of fibrosed tissues is of particular importance. This ossification leads to "bamboo spine" deformity by widespread syndesmophytosis and the ossification of multiple intervertebral discs, which result in an undulating spinal contour (BAHK, 1994).

The absence of specific locations which may be expected in such well-developed cases can similarly help the diagnosis. The lack of lesions of the distal interphalangeal joints does not indicate the diagnosis of a psoriatic arthritis (CASALIS, 1985; BAHK, 1994). The presence of the enthesopathies of the calcanei and the detected vertebral erosions, and the lack of sternoclavicular arthritis exclude another type of seronegative arthropathies, spondylarthritis hyperostotica pustulo-psoriatica or SAPHO syndrome (DIHLMANN, 1993; GERSTER et al., 1993; NAGEL et al., 1993).

### Conclusions

The paleopathological analysis and the subsequent differential diagnostic study of the osteoarticular lesions of the two adult male skeletons from graves 80 and 90 reveal that the two individuals suffered from SNSA. The literature data demonstrate that the most probable diagnosis within the group of SNSA is that of ankylosing spondylitis.

The inequality of the stage of involvement in different locations appears important. The well-developed lumbar affections are associated with an early stage (case 1) or a hardly developed sacroiliitis (case 2). These alterations cannot be recognized, especially in the second case, by traditional radiological methods. Our observations accord with the data of DOUGADOS (1993), who describes cases of AS with well-developed syndesmophytosis and only clinically testable sacroiliitis.

Data on the prevalence of AS in modern populations are a little heterogeneous (they vary between 0.05 and 1%), due to racial differences (KELLGREN, 1964; SIMON et al., 1984; BAHK, 1994). A value of around 0.1% is most commonly quoted (RESNICK and NIWAYAMA, 1988). There is a clear male predominance, the disease affecting mainly male populations (SIMON et al., 1984; BAHK, 1994).

There is a strong association between AS and the presence of the histocompatibility antigen HLA-B27; the AS prevalence follows HLA-B27 in a

population (LE LOET and BRUNO, 1990; BAHK, 1994). Clinical studies reveal the association of the classical radiological and pathological changes of AS and several autoantibodies, in both HLA-B27-positive and negative patients (LAKOMEK et al., 1991). Whatever the correct etiological factor of the disease may be, its heritability (the hereditary predisposition to AS) has already been justified (RESNICK and NIWAYAMA, 1988; GÖMÖR and BÁLINT, 1989). Different literature data suggest that the family incidence of AS is 10 to 100 times higher than its incidence in a normal population (KELLGREN, 1964; RYCKEWAERT, 1980; SIMON et al., 1984).

Although the relatively rare case-histories on AS in the paleopathological literature (ORTNER and PUTSCHAR, 1985) are not sufficient to allow calculation of a real prevalence of the disease in ancient times, its frequency does not seem to have been higher than today. The results of previous studies revealed the prevalence of SNSA in adult populations, which was diagnosed in historical series to be either 0 or a value below 1% (BÉRATO et al., 1990; PÁLFI, 1990, 1993; MOLNÁR and MARCSIK, 1994).

It is a little surprising that two well-developed cases were found during examinations of 83 skeletons from Bácsalmás. Analysis of the 54 adult skeletons only clearly showed that the prevalence of AS in the adult population is relatively high, reaching even 3.7%. With regard to the low number of observed cases, we would like to avoid drawing further conclusions. The location of the two affected skeletons in the cemetery is most interesting: the skeletons (Nos 80 and 90) were found in two neighboring graves (WICKER, manuscript). The importance of this fact should not be overestimated, of course, but the neighboring graves together with the hereditary predisposition of the disease and the striking resemblance between the morphology and patterns of the lesions, suggest that there may have been a family relationship between the two individuals. Further biomolecular or paleoserological examinations may clarify this problem.

### Acknowledgements

Thanks are due to our colleagues at the Department of Radiology, Szeged Hospital, for taking the X-rays.

This research was supported by the Hungarian National Research Foundation (OTKA, F 6015), and by the Foundation for Hungarian Higher Education and Research (706/94).

## References

- ARLET, J. and MAZÉRES, B. (1985): La maladie hyperostotique. - *Rev. Méd. Interne*, 6, 553-564.
- BAHK, Y.W. (1994): Combined scintigraphic and radiographic diagnosis of bone and joint diseases. - Springer-Verlag, Berlin Heidelberg, 119-133.
- BÉRATO, J., DUTOUR, O., WILLIAMS, J., ZAKARIAN H. and ACQUAVIVA, P.C. (1990): Epidémiologie des affections rhumatismales dans une population antique. - *Revue du Rhumatisme*, 57, 5, 397-400.
- BOROVSKY, S. (1910): Magyarország vármegyéi és városai: Bács-Bodrog vármegye. - Budapest. 2, 36-41.
- CAZALIS, P. (1985): Rhumatisme psoriasique. - *Encycl. Méd.-Chir., Paris, Appareil locomoteur*, 14-240-A-10, 1-14.
- DIHLMANN, W. (1993): Acquired hyperostosis syndrome (so-called pustular arthro-osteitis). - *Wien Klin. Wochenschr.*, 105, 5, 127-138.
- DOUGADOS, M. (1993): Les critères de spondylarthropathie. - *Synoviale*, No. spécial, mars 1993, 4-8.
- DUTOUR, O. (1986): Enthesopathies (lesions of muscular insertions) as indicators of the activities of Neolithic Saharan populations. - *Am. J. Phys. Anthropol.*, 71, 221-224.
- DUTOUR, O., PANUEL, M. and ROTHSHILD, B.M. (1994): Spondylarthropathies in Early Holocene Saharan population. - *Homo*, 45/Suppl., 44.
- FELLMANN, N. (1985): Diagnostic différentiel de la spondylarthrite ankylosante. - *Méd. Hyg.*, 43, 1000-1008.
- FEREMBACH, D., SCHWIDETZKY, I. and STLOUKAL, M. (1979): Recommendations pour déterminer l'âge et le sexe sur le squelette. - *Bull. et Mém. de la Soc. d'Anthrop. de Paris*, 6, 7-45.
- FERENCZ, M. (1991): Joint diseases in a Medieval cemetery in Hungary. - *Annl. hist.-nat. Mus. natn. hung.*, 83, 277-284.
- FOURNIÉ, B. and FOURNIÉ, A. (1992): Le territoire enthésique, l'enthésite et les spondylarthropathies inflammatoires. - *Rhumatologie*, 44, 8, 169-173.
- GERSTER, J.-C. (1993): Manifestations ostéo-articulaires des pustuloses, acnés et syndromes apparentés. - *Encycl. Méd.-Chir., Paris, Appareil locomoteur*, 14-241-A-10, 1-4.
- GOMEZ BELLARD, F. and SANCHEZ SANCHEZ, J.A. (1989): Spondylarthrite ankylosante: un cas complet. - *J. Paleopath.: Monographic Publication I.*, 117-118.
- GÖMÖR, B. and BÁLINT, G. (1989): Reumatológia. - *Medicina*, Budapest. 161-198.
- GRAN J.T., HUSBY, G., HORDVIK, M., STORMER, J. and ROMBERG-ANDERSEN O. (1984): Radiological changes in men and women with ankylosing spondylitis. - *Ann. Rheum. Dis.*, 43, 570-575.
- IVÁNYI, I. (1909): Bács-Bodrog vármegye földrajzi és történelmi helynévtára. - *Szabadska*, 1909. 13-15.
- KELLGREN, J.H. (1964): The epidemiology of rheumatic diseases. - *Ann. Rheum. Dis.*, 23, 109-122.
- KNUSSMANN, R. (1988): Anthropologie. - *Gustav Fischer Verlag, Stuttgart*. 1, 421-479.
- KRAMAR, Ch. (1980): Un cas de spondylarthrite ankylosante de la Genève médiévale. - *Proceedings of the 3rd European Meeting of the Paleopath. Assoc.*, Caen. 137-140.
- KRAMAR, Ch. (1987): Paléopathologie des maladies rhumatismales. - *Méd. et Hyg.*, 45, 928-935.
- LAKOMEK, H.J. (1991): Ankylosing spondylitis: an autoimmune disease? - *Ann. Rheum. Dis.*, 50, 11, 776-81.
- LE LOET, X. and BRUNO, M.-C. (1990): Spondylarthrite ankylosante. - *Encycl. Méd.-Chir., Paris, Appareil locomoteur*, 14-230-A-10, 1-16.
- MAU, W., ZEIDLER, H., MAU, R., MAJEWSKI, A., FREYSCHMIDT, J. and DEICHER, H. (1987): Outcome of possible ankylosing spondylitis in a 10 years' follow-up study. - *Clin. Rheumatol.*, 6, Suppl. 2, 60-66.
- MILLER, E. (1992): The effects of horseback riding on the human skeleton. - Paper presented at the 1992 Meeting of the Paleopathology Association, Las Vegas, Nevada.
- MOLNÁR, E. and MARCSIK, A. (1994): Paleopathological alterations in an Avar age sample. - *HOMO*, 45/Suppl., 88.
- NAGEL, T., EGER, G., KALDEN, J.R. and MANGER, B. (1993): Arthroostitis pustulosa, spondylarthrit hyperostotica pustulo-psoriatica, SAPHO syndrome: clinical experiences and review of the literature. -

Z. Rheumatol., 52, 6, 390-397.

- ORTNER, D.J. and PUTSCHAR, W.G.J. (1985): Identification of pathological conditions in human skeletal remains. - Smithsonian Institution Press, Washington. 488 pp.
- PÁLFI, Gy. (1990): Spondylarthropathies in Avar age human remains. - Acta Biol. Szeged., 36, 81-94.
- PÁLFI, Gy. (1992): Traces d'activités sur les squelettes des anciens Hongrois. - Bull. et Mém. de la Société d'Anthropologie de Paris, 4, 209-231.
- PÁLFI, Gy. (1993): Maladies, activités et environnements des populations anciennes en Europe Centrale et Occidentale: approche de paléopathologie comparée. - Thèse de Doctorat Nouveau Régime. Université de Provence, Aix-en-Provence. 356p+Annexe.
- PERROT, R. and BILLARD, M. (1982): Un nouveau cas d'amincissement symétrique du pariétal (Église Saint-Sorlin de Serrières, Ardèche, France). - Proceedings of the 4th European Meeting of the Paleopath. Assoc., Middelburg/Antwerpen. 288-295.
- RESNICK, D. and NIWAYAMA, G. (1988): Diagnosis of Bone and Joint Disorders. - Saunders, Philadelphia. 2, 1104-1127.
- ROGERS, J. and WALDRON, T. (1986): The palaeopathology of joint disease with special reference to seronegative spondylo-arthropathies. - Proceedings of the 6th European Meeting of the Paleopath. Assoc., Madrid. 143-147.
- ROGERS, J., WALDRON, T., DIEPPE, P. and WATT, I. (1987): Arthropathies in palaeopathology: The basis of classification according to most probable cause. - J. Arch. Science, 14, 179-193.
- ROTHSCHILD, B.M., WOODS, R.J. and ORTEL, W. (1990): Erosive arthritis in defleshed bones. - Am. J. Phys. Anthropol., 82, 441-449.
- ROTHSCHILD, B. and WOODS, R.J. (1991): Spondylarthropathy: Erosive arthritis in representative defleshed bones. - Am. J. Phys. Anthropol., 85, 125-134.
- RYCKEWAERT, A. (1980): Os et articulations. Rhumatologie. - Flammarion, Paris. 297-308.
- SIMON, L., BLOTMAN, F. and CLAUSTRE, J. (1984): Rhumatologie. Masson, Paris. 221-358.
- SIMON, L., HÉRISSON, Ch. and RODINEAU, J. (1991): Pathologie des insertions et enthésopathies. - Masson, Paris.
- STEINBOCK, R.T. (1976): Paleopathological diagnosis and interpretation. - C.C. Thomas Publisher, Springfield. 433 pp.
- WICKER, E. (manuscript): Ásatási jelentés (Bácsalmás-Homokbánya, XVII. századi temető). - Thorma János Múzeum, Kiskunhalas. Kézirat.
- ZEIDLER, H. (1987): Undifferentiated arthritis and spondylarthropathy as a major problem of diagnosis and classification. - Scand. J. Rheumatol. Suppl., 65, 54-62.