

International Journal of Obstetrics and Gynaecology Research (IJOGR)  
Vol. 3 (2016) No.8, pp. 427-431  
<http://www.ijogr.com/>

# Obstetrical Aspects in Congenital Ichthyosis

<sup>1</sup>Ann-Sophie Page, <sup>2</sup>Isabelle Dehaene, <sup>3</sup>Geert Herman Page

<sup>1,2</sup>University Hospital Ghent, Belgium

<sup>3</sup>Jan Yperman Hospital Ypres, Belgium

Email: [annsophie.page@gmail.com](mailto:annsophie.page@gmail.com), [isabelle.dehaene@gmail.com](mailto:isabelle.dehaene@gmail.com), [geert.page@skynet.be](mailto:geert.page@skynet.be)

## Abstract

*We present a case of congenital ichthyosis because obstetrical literature is scarce and most obstetricians could need a reminder and update. Congenital ichthyosis (CI) comprises a variety of skin disorders characterised by abnormal keratinization of the epidermis, which are mostly transmitted in an autosomal recessive manner. This condition is rare (seven per million people) with various clinical neonatal expressions and diversified prognosis, from self-healing to lethal. Even less severe phenotypes have significant associated morbidity and mortality. CI babies are often born prematurely and are at highest risk for complications during the postnatal period. CI, while fairly rare, is a condition well described in the literature, mainly from the neonatal point of view. We describe a case in which congenital ichthyosis was diagnosed after birth, and summarise the present literature with particular attention on obstetric implications as the prenatal diagnosis, genetic and ultrasound testing, perinatal complications and care for future pregnancies.*

## Keywords

*Congenital Ichthyosis, perinatal complications, ultrasound*

## I. Patients and Methods

The case was a 31-year-old woman, gravida 2, para 0, with previous one spontaneous abortion. Her antepartum course was uncomplicated. First trimester screening results and 20-week sonographic findings were reported as normal. Pregnancy went uneventful and labor started at week 39+5. On admission to the delivery ward, an external cardiotocography (CTG) showed small decelerations and poor quality registration of the fetal heart rate (FHR). Monitoring with Fetal scalp electrode (FSE) was attempted but was unsuccessful. Several different electrodes and different CTG machines were used, but no FHR registration could be detected. External CTG was then performed, but with inadequate quality. No fetal blood sampling was performed. The woman had a spontaneous delivery of a girl, birthweight 3000g, Apgar scores 1/9 and 5/9 and normal umbilical cord gas-status.

Physical examination of the girl showed a thick keratin-coated skin with fissures and restricted movement of hands and feet. There was eclabium (eversion of the lips) and

bilateral ectropion [Figure 1]. The clinical diagnosis was congenital ichthyosis.

The girl was transferred to a neonatal intensive care unit where she was treated with antibiotics, and placed in a well-humidified incubator. Two weeks later the skin was almost normal and the infant was discharged with paediatric and dermatological follow-up. Genetic testing revealed a mutation in the ALOX12B gene. Both parents carried a different mutation in the ALOX12B gene.

After follow-up of twenty four months, the baby had a normal psychomotor development and the dermatologic findings were consistent with an ichthyosiform erythrodermia. Without awaiting the results of genetic testing and rejecting options of prenatal diagnostics, the couple became pregnant again after 2 years. This second pregnancy was followed by more thorough ultrasound examination, including 4D technique. No 2D ultrasound markers of CI were noted and 4D images showed normal facial morphology and normally moving limbs and fingers [Figure 2]. Indeed, this baby was born without CI.

## II. Discussion

### Diagnosis

Congenital ichthyosis is a rare and devastating disorder [1-2]. The appearance of the neonate can be shocking to parents and health care providers, suspicion of this disorder may help prepare them. An early sonographic diagnosis is difficult to establish, due to both, the late development of the phenotype at mid gestation and the rarity of the disease itself [3].

Most constant sonographic findings are: a large gaping mouth and protruding tongue, aplasia of the nose and bulging eyes [3]. Other characteristic findings are dysplastic or swollen hands and feet, fixed flexed extremities and short digits [4]. Additional hints may be the presence of growth restriction, restricted fetal movements, polyhydramnios and the “snowflake sign”, reflecting hyper-echogenic particles in the amniotic fluid [3,4].

In summary, facial dysmorphism and abnormal extremities may raise the suspicion of CI.

3D -4D ultrasound displays facial morphology and extremities in a better way[4].

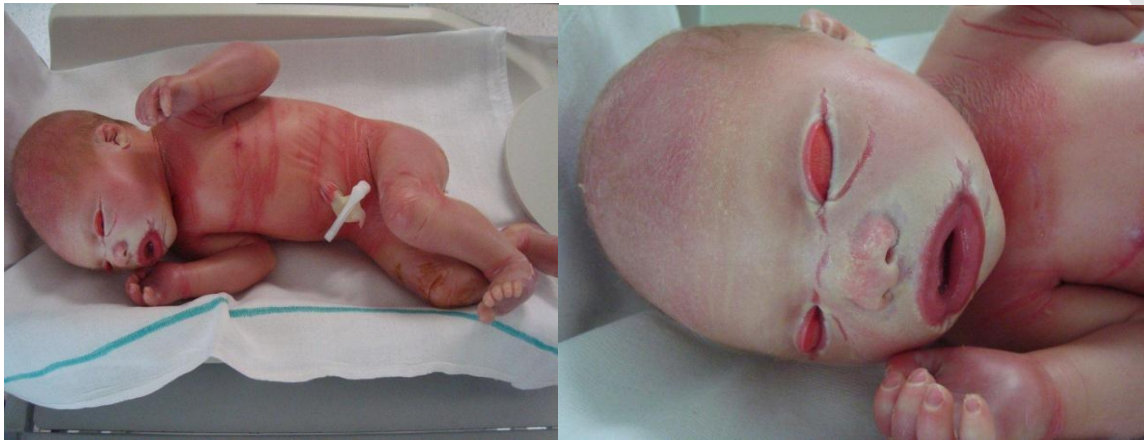In the neonatal period, a likely diagnosis can often be made on clinical grounds alone. In cases where a diagnosis is uncertain or for confirmation of suspected diagnosis, genetic testing can be performed. Testing for mutations known to cause ichthyosis is available in most commercial genetic testing laboratories. Genetic diagnosis becomes particularly useful in the setting of future family planning [1]. Recurrence should be

ruled out in a subsequent pregnancy, using ultrasound and molecular testing provided the mutation has been identified [2].

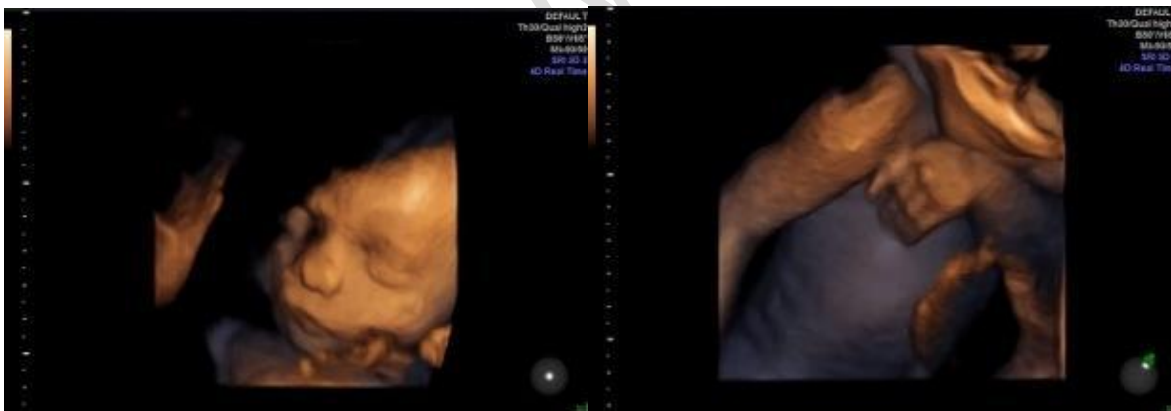
### Intrapartum and perinatal care

This case demonstrates a cause of inadequate internal CTG registration. During delivery, the cause was unexplained and a technical cause was suspected. Inadequate quality CTG by FSE is related to a defective electrode or detachment or misplacement of the electrode, and reapplication will solve the problem [5]. Yet, two cases were described in the literature in which internal FHR monitoring consistently failed during labor and it was unexplained. It was evident in postpartum; found to be ichthyosis [6]. The cause of the inadequate internal CTG registration was most probably a poor contact of the FSE due to the thickness and tightness of the membrane.

Beyond complications of prematurity, impaired barrier function serves as the primary source of morbidity and mortality during the neonatal period. Complications include disrupted thermoregulation, dehydration, electrolyte imbalances and susceptibility to infections [1]. Therefore, the presence of a pediatrician at the delivery and admission to a specialised neonatal intensive care unit is required. Considerations relevant to the neonatal care are described elsewhere.



**Figure 1:** Physical examination of the neonate showed a thick keratin-coated skin with fissures. Restricted moving of hands and feet was noticed. There was eclabium (eversion of the lips) and bilateral ectropion.



**Figure 2:** The second pregnancy was followed by more thorough ultrasound examination, including 4D technique. No 2D ultrasound markers of CI were noted and 4D images showed normal facial morphology and normally moving limbs and fingers.

### III. References

- [1]. Craiglow BG. Ichthyosis in the newborn. *Seminars in Perinatology* 2013; 37: 26-31.
- [2]. Tourette C, Tron E, Mallet S et al. Three-dimensional ultrasound prenatal diagnosis of congenital ichthyosis: contribution of molecular biology. *Prenatal Diagnosis* 2012; 32:498-500.
- [3]. Berg C, Geipel A, Kohl M et al. Prenatal sonographic features of Harlequin ichthyosis. *Arch Gynecol Obstet* 2003; 268:48-51.
- [4]. Vohra N, Rochelson B, Smith-Levitin M. Three-dimensional sonographic findings in congenital ichthyosis. *J Ultrasound Med* 2003; 22:737-739.
- [5]. Royal College of Obstetricians and Gynaecologists. The use of electronic fetal monitoring. Evidence-based clinical guidelines; no.8. London: RCOG Press, 2001.
- [6]. Andersen BR, Lebech M et Borch K. Failure to perform intrapartum electronic fetal monitoring due to ichthyosis, a fetal skin disease. *Acta Obstet Gynecol Scand* 2005; 84:1209-1210.