CANINE HERPESVIRUS DURING PREGNANCY AND NEWBORN PUPPIES

Meritxell Guart Pallarès
Barcelona, june 2017

OBJECTIVES

The study is focused on the disease caused by canine herpes virus and how it affects bitches during pregnancy and puppies born from affected bitches. Therefore, it will be focused on the reproductive problems caused by this virus.

It also wants to assess whether vaccination against herpes is really necessary and effective or not during pregnancy or childbirth.

ETIOLOGY

Canine herpesvirus-1 (CHV-1) is classified under the order *Herpesvirales*, family *Herpesviridae*, subfamily *Alphaherpesvirinae*, genus *Varicellovirus*.

It is quickly inactivated in the environment. It is stable at pH 6.5-7.5 and at low temperatures of around -70ºC. Nevertheless, it is destroyed easily with a pH below 5 and easily inactivated at 20ºC. The virus is readily inactivated at temperatures greater than 40ºC.

EPIDEMIOLOGY

CHV-1 was first described in the mid-1960s as the causative agent of a fatal septicemic disease of puppies.

The virus seems to be present worldwide in domestic and wild dogs. Serologic surveys have shown a relatively high prevalence of CHV-1 in household and colony-bred dogs.

Transmission occurs by direct contact with oronasal or genital secretions.

Belgium	45,8
England	88
Netherlands	39.3
Spain	74,8
United States	6
GLOBAL	0.5-81

Prevalence of antibody (%)

PATHOGENIC AND CLINICAL SIGNS

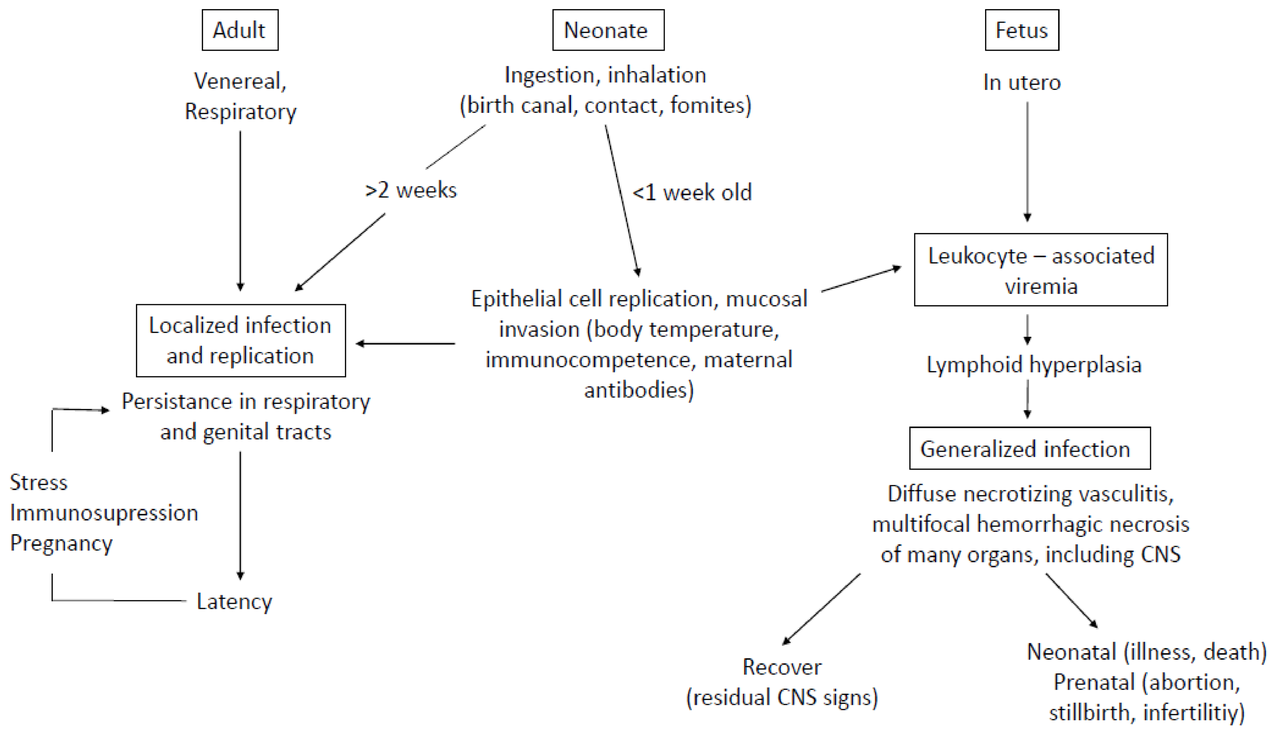

Fig. 1. Pathogenesis of CHV infection (Greene 2012).

AGE	CLINICAL SIGNS
Pups 1-3 week-old	Generalized visceral lesions. Multifocal areas of hemorrhage and necrosis in organs such as lungs, liver, brain, gingival mucous, gastrointestinal tract, bladder and kidney. Spleen and lymph nodes increased in size. Meningoencephalitis or not suppurative ganglioneuritis.
Pups more 4 week-old	Infection can take the form of unapparent or a mild rhinitis or pharyngitis. Unapparent carrier animals.
Transplacental infection	Virus reaches the endothelial cells of the placenta and the umbilical vein, leading to thrombosis in the vessels. We found necrosis of the placenta. Fetal injuries are similar to the findings of a puppy less than 3 weeks.
Adults	Problems concerning the respiratory tract or skin lesions. In females lymphoid hyperplasia and hyperemia in the vaginal mucosa. In male-like lesions at the base of the penis and the foreskin.

TECHNIQUES OF DIAGNOSTIC

Histopathology	Intranuclear inclusion bodies, scattered, irregular, called type A Cowdry. Has no sensitivity or specificity as a diagnostic method.
Virus isolation	Good diagnostic method. It is based on the ability of virus replication in cell cultures. In cells infected by viruses seen the growth of cell formation and rounded form plaques around necrotic tissue.
Serology	ELISA and hemagglutination inhibition. It gives false positives or negatives in asymptomatic males or females.
Real-time PCR	The most sensitive and specific method. Obtaining quick results. Can detect underlying infection or low intensity, being useful to detect carriers or animals with latent disease.

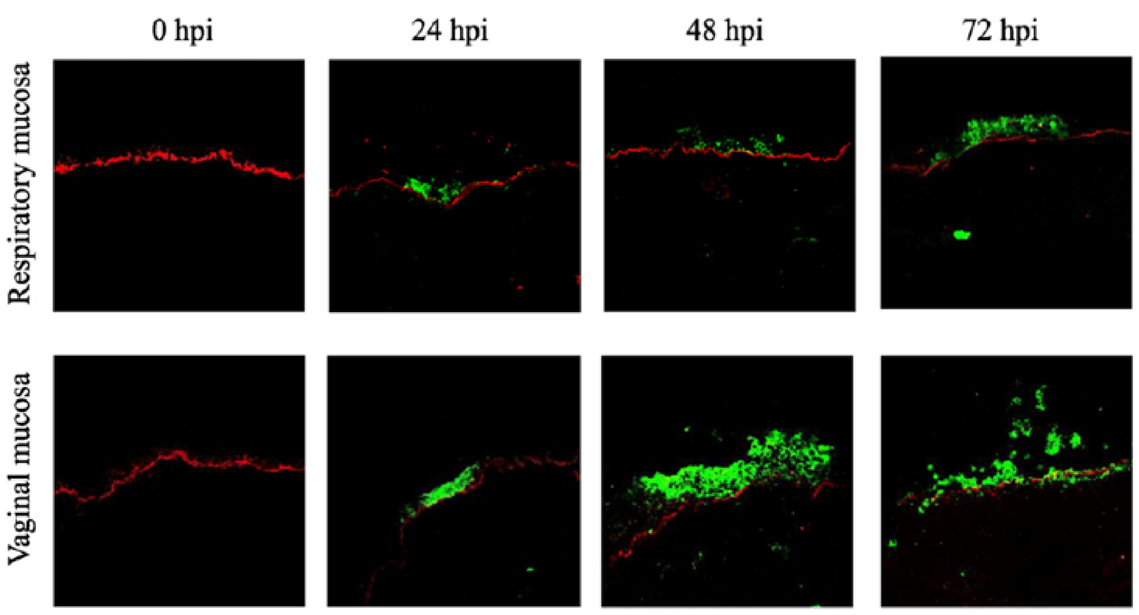

Fig. 2. Confocal photomicrograph of CHV-1 infected canine respiratory and vaginal mucosa explants at 0, 24, 48 and 72 hpi. Viral antigen positive cells are stained Green (Li *et al.* 2016).

VACCINES

EURICAN HERPES 205

1) First injection: during heat or 7-10 days after the breeding date.
2) Second injection: 1 to 2 weeks before the date of delivery.
3) Revaccination: during each pregnancy with the same pattern vaccine.

Once vaccinated, bitches will pass antibodies to their pups through the colostrum. When pups make contact with the virus, the infection will not develope or will develope in a much milder form.

TREATMENT, CONTROL AND PROPHILAXI

- Keep the puppies under a heat lamp to keep their body temperature fall and replicate virus.
- Vaccinate puppies with hiperimmune serum.
- Caution during breeding to minimize the risk of contagion.

An inactivated subunit vaccine is commercially available in Europe.

CONCLUSIONS

The CHV-1 is a viral disease prevalent today. Its affinity for the upper respiratory tract and genital mucous facilitates an easy spread both male and female during intercourse and childbirth, newborn and between puppies.

Real-time PCR have shown good sensitivity and specificity in diagnosis.

The canine herpesvirus vaccine is effective at preventing the clinical manifestations of the spread of the disease.

FACULTAT DE VETERINÀRIA

Bibliography

Greene CE. 2012. Infectious diseases of the dog and cat. 4th ed. St. Louis, Mo.: Elsevier/Saunders. p. 48-54.

Li Y, Negussie H, Qiu Y, Reddy VRAP, Mateusen B, Nauwynck HJ. 2016. Early events of canine herpesvirus 1 infections in canine respiratory and genital mucosae by the use of ex vivo models [Internet]. [consultat 22 novembre 2016]. 105:205–208. Disponible a: http://linkinghub.elsevier.com/retrieve/pii/S003452881630042X

UAB Universitat Autònoma de Barcelona