

# Outpatient Management of Cholesteatoma with Canal Wall Reconstruction Tympanomastoidectomy

Richard Kao, MD; Todd Wannemuehler, MD; Charles W. Yates, MD; Rick F. Nelson, MD, PhD 

**Objectives:** The postoperative wound infection rate for canal wall reconstruction (CWR) tympanomastoidectomy with mastoid obliteration in the treatment of chronic otitis media with cholesteatoma has been reported to be 3.6%. Postoperative administration of 24–48 hours of intravenous antibiotics has been recommended. We aim to determine the infection rate of CWR with postoperative outpatient oral antibiotics.

**Study Design:** Institutional review board—approved retrospective case review.

**Setting:** Tertiary referral center.

**Patients:** Retrospective review of consecutive patients who underwent CWR tympanomastoidectomy with mastoid obliteration at a single institution from 2014 to 2016.

**Main Outcome Measure:** Patient characteristics (age, sex) were calculated. Rate of postoperative complications and infections within 1 month of surgery were calculated. Comparison to previous published infection rates with postoperative intravenous antibiotics.

**Results:** 51 patients underwent CWR followed by outpatient oral antibiotics with a mean age of 25.9 years (16 patients were less than 10 years old). There were no postoperative wound infections. Outpatient antibiotics showed non-inferiority to IV antibiotic historic controls (0% vs. 3.6%; 95% confidence interval [CI], 0–6.09%;  $p = 0.03$ ). One patient had small postoperative wound dehiscence with CSF leak that was managed conservatively. One patient developed *Clostridium difficile* colitis on postoperative day 2.

**Conclusions:** The infection rate after CWR tympanomastoidectomy with use of outpatient antibiotics is low and is non-inferior to a historic cohort treated with inpatient intravenous antibiotics. A larger randomized controlled trial is warranted.

**Key Words:** Canal wall reconstruction, cholesteatoma, antibiotics, outpatient, tympanomastoidectomy.

**Level of Evidence:** 4.

## INTRODUCTION

Canal wall reconstruction tympanomastoidectomy with mastoid obliteration (CWR) for the treatment of chronic otitis media with cholesteatoma is a technique that has a low recurrence rate and preserves the ear canal anatomy.<sup>1,2</sup> The primary goals of any surgical treatment of cholesteatoma are to eradicate the cholesteatoma and create a dry ear with a low chance of cholesteatoma recurrence. The secondary goals include maximizing hearing and limiting lifetime mastoid cavity cleanings and water restrictions.

Traditionally, canal wall up (CWU) and canal wall down (CWD) have been the most common procedures used to treat cholesteatoma. CWU has the advantage of

preserving normal ear canal anatomy and middle ear space. The disadvantage of CWU is the high rate of recurrent cholesteatoma ranging from 40–60% in children and 20% in adults.<sup>3–8</sup> The major advantage of CWD is the increased exposure and the relatively low rate of cholesteatoma recurrence of 7–17%.<sup>9–11</sup> The major disadvantage is the need for lifelong mastoid bowl cleanings, risk of mastoid bowl infections, limitations on water activities and typically worse conductive hearing results. In contrast, CWR combines the advantages of both CWU and CWD without the need for mastoid bowl cleanings and, most importantly, a low rate of recurrent disease (~2.6% requiring conversion to CWD or subtotal petrossectomy and ~12% residual disease at second look).<sup>2</sup>

The CWR procedure involves harvesting bone pâté that is used to obliterate the mastoid cavity during canal reconstruction (Fig. 1A). Early in the development of the CWR technique, the rate of postoperative wound infection of the mastoid was as high as 14.4%.<sup>1</sup> Possible causes for the high postoperative infection rate included: 1) bacterial contamination of the bone pâté from the mastoid air cells during harvesting, 2) inadequate postoperative antibacterial treatment, or 3) non-viable or acellular bone pâté. Subsequently, the technique was modified to harvest bone pâté without contamination of diseased mastoid air cells, wash the pâté with bacitracin solution, and administer 24–48 hours of postoperative

This is an open access article under the terms of the Creative Commons Attribution-NonCommercial-NoDerivs License, which permits use and distribution in any medium, provided the original work is properly cited, the use is non-commercial and no modifications or adaptations are made.

From the Department of Otolaryngology—Head and Neck Surgery, Indiana University School of Medicine, Indianapolis, Indiana, U.S.A.

Editor's Note: This Manuscript was accepted for publication 2 October 2017.

Send correspondence to Rick F. Nelson, MD, PhD, Department of Otolaryngology—Head and Neck Surgery, Indiana University Health, 355 W. 16th St., Suite 3200, Indianapolis, IN 46202 Email: ricnelso@iupui.edu

DOI: 10.1002/liv.2.116

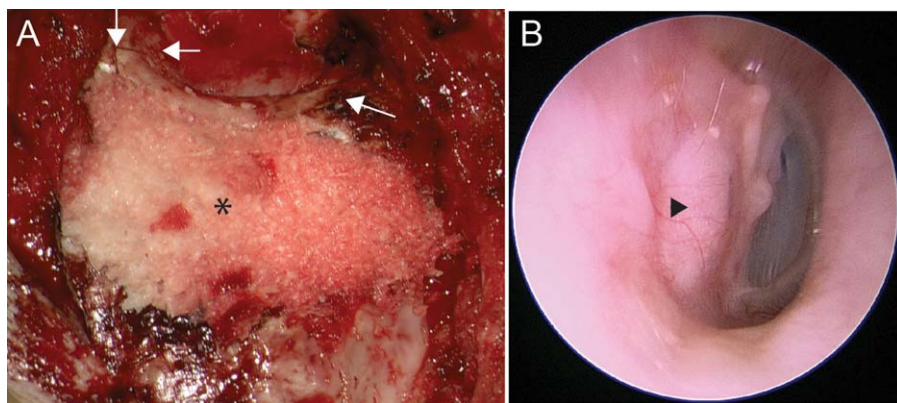


Fig. 1. Representative Canal Wall Reconstruction. (A) The reconstructed ear canal is seen with the two superior cuts and the inferior compound miter cut (white arrows). The mastoid is filled with bone p $\hat{a}$ t $\acute{e}$  (\*). (B) Representative transcanal view of reconstructed ear canal after second look tympanoplasty with ossicular reconstruction and cartilage graft (arrowhead).

intravenous (IV) antibiotics. Subsequently, the infection rate decreased to 3.6%.<sup>1,2</sup> Thus, it has been recommended that patients be admitted after CWR for administration of IV antibiotics. However, the need for postoperative admission can discourage surgeons from performing CWR and potentially increase hospital costs.

Traditionally after CWR, patients have been treated empirically to cover *Pseudomonas aeruginosa* with 24 to 48 hours of IV levofloxacin and piperacillin-tazobactam (Zosyn, Pfizer Corporation, New York, New York) followed by outpatient oral levofloxacin for 2 weeks.<sup>1</sup> Patients younger than 18 years are treated with Zosyn without levofloxacin. Penicillin-allergic patients were typically treated with 24–48 hours of IV clindamycin with or without levofloxacin, followed by outpatient oral clindamycin for 2 weeks. Additionally, levofloxacin may be substituted with ciprofloxacin depending on availability.<sup>2</sup>

While it is recognized that a regimen of antibiotics is recommended after CWR procedures for cholesteatoma,<sup>1</sup> there exists a paucity of literature investigating the necessity of admission for IV antibiotic administration in postoperative management protocols. This study seeks to determine the efficacy and safety of an outpatient antibiotic regimen following CWR for cholesteatoma to obviate the need for postoperative hospital admission.

## MATERIAL AND METHODS

Institutional review board (IRB) exemption through the Indiana University Office of Research Compliance Human Subjects Division was obtained for the planned retrospective review prior to initiating patient identification or chart review (IRB number 1608119193, Principle Investigator RFN). Electronic medical records and operative notes were reviewed retrospectively to obtain: 1) patient age, 2) gender, 3) surgical side, 4) intraoperative antibiotic(s), 5) postoperative antibiotic(s), 6) postoperative infections, and 7) postoperative complications.

Patients were treated with CWR if they had: 1) cholesteatoma involving the antrum and/or mastoid, 2) an intact posterior ear canal wall (either primary or after previous CWU at another institution), and 3) limited dural exposure from cholesteatoma disease. These criteria were the same inclusion criteria as historical controls.<sup>1,2</sup> There was no treatment bias made preoperatively based on severity of infection.

Inclusion criteria for the current study included: 1) having received tympanomastoidectomy with CWR for cholesteatoma and 2) having received only oral antibiotics after the operation. Subjects were excluded if they received any postoperative IV antibiotics. These subjects received IV antibiotics as they were unable to tolerate oral medications due to nausea and/or emesis.

Rate of infection was quantified, and statistical analysis was performed. Non-inferiority binomial testing was conducted using SAS v9.4 (SAS Institute, Cary, North Carolina). For all analyses,  $p < 0.05$  was selected as the criterion for statistical significance.

## Surgical Technique

The post-auricular area is shaved, prepped with Chloraprep (Becton, Dickinson and Company, Franklin Lakes, NJ) and injected with 1% lidocaine with 1:100,000 epinephrine (weight-adjusted for pediatric patients). The skin and hemi-face are then prepped with betadine and the patient is draped. The post-auricular incision is made at the hairline down to the temporalis fascia. An anterior based periosteal (Palva) flap is elevated. In revision cases, the flap is not elevated to prevent exposure of mastoid contents. Bone p $\hat{a}$ t $\acute{e}$  is harvested in all cases with a 6 mm 2-Flute otologic bur (Stryker Corporation, Kalamazoo, Michigan) from the temporal or occipital cortex using an inline suction collector (Sheehy Bone Dust Collector, Grace Medical, Memphis, Tennessee). The bone p $\hat{a}$ t $\acute{e}$  is soaked in 50,000 units of bacitracin during the case. No Penrose drain was placed as had previously been described.<sup>1,2</sup> The palva flap and subcutaneous layers were closed with 3-0 Vicryl sutures and the skin was closed with 4-0 subcuticular Monocryl sutures. The incision was covered with Dermabond (Ethicon Inc., Somerset, New Jersey). Thus, the patient did not need to perform postoperative wound care. The Dermabond was typically removed at the 1-month visit. The remainder of the procedure has been previously described.<sup>1</sup>

All patients receive intraoperative IV antibiotics prior to skin incision. In most cases, the patients are administered IV Zosyn or IV ciprofloxacin.

## Postoperative Management

After the procedure, patients are treated with a 7- or 10-day course of oral antibiotics as well as pain control. Adults are most often prescribed a fluoroquinolone (ciprofloxacin) and children are most often prescribed sulfamethoxazole-trimethoprim. If the patient is allergic to these antibiotics, an alternative antibiotic is appropriately prescribed. Patients are then seen in

clinic 1 week after the operation for examination and ear canal pack removal. Subsequently, patients are given otic drops (ofloxacin or ciprofloxacin-dexamethasone) to use daily and then examined again in 1 month after the operation. Postoperative complications, if present, are noted at these visits.

## RESULTS

A total of 55 patients underwent CWR from October 2014 to May 2017. All patients who presented with a cholesteatoma that extended into the antrum or mastoid and an intact posterior canal wall were treated with CWR with mastoid obliteration with bone pâté (Fig. 1A). Most patients have undergone second look tympanoplasty with ossicular reconstruction and cartilage graft at 6 months after CWR (Fig. 1B).

In our series, two patients initially presented with cholesteatoma and lateral semicircular canal dehiscence and were included. Four patients were excluded from the study because they received IV antibiotics postoperatively due to inability to tolerate oral medications in the postoperative period. Therefore, 51 patients ( $n = 51$ ) who had undergone CWR tympanomastoidectomy including mastoid obliteration were identified and included in this analysis. The mean age was  $25.9 \pm 21.4$  years (standard deviation, range 3–67).

Sixteen subjects were less than 10 years of age. There were nearly equal distributions of operative sides (25 right; 26 left) and gender (28 males; 23 females). Nearly all subjects received anti-pseudomonal antibiotics intraoperatively (Table I). The most common intraoperative antibiotics were Zosyn ( $n = 36$ ; 70.5%), ciprofloxacin ( $n = 6$ , 11.7%), and ciprofloxacin with Zosyn ( $n = 1$ , 2.0%). Those with penicillin allergies received clindamycin ( $n = 1$ , 2.0%) or clindamycin with ciprofloxacin ( $n = 2$ , 3.9%). Seven patients (13.7%) did not receive preoperative anti-pseudomonal antibiotics, but received cefazolin instead.

A vast majority of patients were discharged the same day as their procedure on an outpatient basis ( $n = 45$ , 88.2%, Table I). Of those requiring observation, the most common reason was due to the operative case ending after 5 p.m. and nausea and vomiting (five of six patients). One patient required observation due to congenital aortic and pulmonary artery stenosis. Postoperative oral antibiotics were given to all patients even the patients that required observation overnight. The most common antibiotic given was sulfamethoxazole/trimethoprim ( $n = 28$ ; 54.9%) followed by ciprofloxacin or levofloxacin ( $n = 20$ , 39.2%). In most cases, adults were prescribed fluoroquinolones, and pediatric patients were prescribed weight-based sulfamethoxazole/trimethoprim (8–10 mg/kg/day divided every 12 hours). The most common duration of oral antibiotics was 7 days.

There were no postoperative surgical site infections in this series (Table I).

We compared our findings with a historic cohort where the reported infection rate was 3.6% when patients were given 24–48 hours of IV antibiotics in the postoperative period.<sup>2</sup> Outpatient antibiotics showed noninferiority to IV antibiotic historic controls (0% vs. 3.6%; 95% CI, 0–6.09%;  $p = 0.03$ ).

Notable non-infectious complications included one patient who had small postoperative wound dehiscence with CSF leak that was successfully managed conservatively with additional skin sutures. Intraoperatively for this patient, the superior canal wall cut resulted in a dural tear that was managed with a temporalis muscle plug and replacement of the canal bone. One patient, taking sulfamethoxazole/trimethoprim, developed *Clostridium difficile* colitis on postoperative day 2 which resolved with oral ciprofloxacin and metronidazole. Two pediatric patients developed postauricular dermatitis likely related to 2-Octyl Cyanoacrylate, commonly known as Dermabond. This resolved following removal of the Dermabond and use of oral diphenhydramine.

## DISCUSSION

CWR tympanomastoidectomy represents a unique surgical technique to manage cholesteatoma.<sup>1</sup> It provides increased visualization of the middle ear, anterior epitympanum, and sinus tympani during extirpation of cholesteatoma. The rates of recurrent cholesteatoma are significantly lower than found in CWU tympanomastoidectomy, and it concurrently preserves the normal ear canal anatomy.<sup>2</sup> Thus, it has the potential to improve healthcare costs and quality of life by avoiding lifetime mastoid cavity cleanings and water restrictions.

The major modifications of CWR technique in the past decade include harvesting bone pâté without contamination of diseased mastoid air cells, washing the pâté with bacitracin solution, and administering 24–48 hours of postoperative IV antibiotics. These methods were utilized to address possible bacterial contamination of the bone pâté being replaced into the mastoid, and the infection rate dropped to 4.5%<sup>1</sup> and most recently to a rate of 3.6%.<sup>2</sup> In this 2014 study,<sup>2</sup> it is important to note that some patients received up to 48 hours of intravenous antibiotics and some patients received oral antibiotics based upon surgeon preference; therefore this infection rate of 3.6% represents a mixed cohort. Yet, postoperative admission for administration of IV antibiotics over the first 24–48 postoperative hours remains the most common practice.<sup>2</sup> Because of this, surgeons may be discouraged from performing this procedure on an outpatient basis.

The most common bacteria isolated from postoperative CWR infections are *P. aeruginosa* methicillin-resistant *Staphylococcus aureus* (MRSA), *Enterobacter cloacae*, *Staphylococcus epidermidis* and mixed flora.<sup>1</sup> *P. aeruginosa* is a gram-negative rod with facultative anaerobic metabolism and is commonly seen in the outer ear.<sup>12</sup> Antibiotics that are known to be effective against *P. aeruginosa* include aminoglycosides (gentamicin), fluoroquinolones (ciprofloxacin, levofloxacin), cephalosporins (cefepime, ceftazidime), certain penicillins (ticarcillin, piperacillin), carbapenems (meropenem, imipenem), polymyxins (polymyxin B), and monobactams (aztreonam).<sup>13</sup> The only oral anti-pseudomonal antibiotics are aminoglycosides (gentamicin) and fluoroquinolones (ciprofloxacin, levofloxacin). The toxicities of gentamicin, including cochleovestibular toxicity resulting in hearing

TABLE 1.  
Canal Wall Reconstruction Tympanomastoidectomy for Cholesteatoma Patients

Patient	Age	Side	Gender	Intra-Operative Antibiotics	Postoperative Antibiotics (Type, Dose in mg, Frequency, Duration)	Post-operative Infection	Other Postoperative Complications	1 Day OBS
1	38	L	F	CEFAZOLIN	CIPROFLOXACIN 500 BID 10d	N		Y
2	15	R	M	PIPERACILLIN/TAZOBACTAM	CEPHALEXIN 500 BID 7d	N		N
3	9	R	M	PIPERACILLIN/TAZOBACTAM	SULFAMETHOXAZOLE/TRIMETHOPRIM BID 10d	N	Dermatitis from Dermabond	N
4	7	R	F	PIPERACILLIN/TAZOBACTAM	SULFAMETHOXAZOLE/TRIMETHOPRIM w BID 7d	N		N
5	8	L	F	CLINDAMYCIN	SULFAMETHOXAZOLE/TRIMETHOPRIM w BID 7d (PENICILLIN ALLERGY)	N		N
6	13	R	M	PIPERACILLIN/TAZOBACTAM	SULFAMETHOXAZOLE/TRIMETHOPRIM w BID 7d	N		Y
7	56	R	M	PIPERACILLIN/TAZOBACTAM	CIPROFLOXACIN 500 BID 7d	N	1 cm wound dehiscence, small CSF leak	Y
8	7	R	F	PIPERACILLIN/TAZOBACTAM	SULFAMETHOXAZOLE/TRIMETHOPRIM w BID 7d	N	Dermatitis from Dermabond	N
9	19	L	F	CIPROFLOXACIN	LEVOFLOXACIN 750 daily 7d	N		N
10	61	L	M	PIPERACILLIN/TAZOBACTAM	CIPROFLOXACIN 400 BID 7d	N		N
11	12	R	M	PIPERACILLIN/TAZOBACTAM	SULFAMETHOXAZOLE/TRIMETHOPRIM w BID 7d	N		N
12	17	R	F	PIPERACILLIN/TAZOBACTAM	SULFAMETHOXAZOLE/TRIMETHOPRIM 400 BID 7d	N	C. difficile infection on POD2	N
13	16	R	M	CEFAZOLIN	CIPROFLOXACIN 500 BID 7d	N		N
14	15	L	M	CEFAZOLIN	SULFAMETHOXAZOLE/TRIMETHOPRIM 400 BID 7d	N		N
15	8	R	M	CEFAZOLIN	SULFAMETHOXAZOLE/TRIMETHOPRIM 800 BID 7d	N		N
16	65	L	M	CEFAZOLIN + PIPERACILLIN/TAZOBACTAM	CIPROFLOXACIN 500 BID 7d	N		Y
17	7	R	M	CIPROFLOXACIN	SULFAMETHOXAZOLE/TRIMETHOPRIM 400 BID 7d	N		Y
18	35	L	F	CIPROFLOXACIN	CIPROFLOXACIN 500 BID 7d	N		N
19	7	L	M	PIPERACILLIN/TAZOBACTAM	SULFAMETHOXAZOLE/TRIMETHOPRIM w BID 7d	N		N
20	7	R	M	PIPERACILLIN/TAZOBACTAM	CEPHALEXIN w TID 7d	N		N
21	16	R	F	CEFAZOLIN	SULFAMETHOXAZOLE/TRIMETHOPRIM 400 BID 7d	N		N
22	51	R	F	CLINDAMYCIN + CIPROFLOXACIN	CIPROFLOXACIN 750 BID 7d	N		N
23	31	R	F	CLINDAMYCIN + CIPROFLOXACIN	CIPROFLOXACIN 500 BID 7d	N		N
24	15	R	M	PIPERACILLIN/TAZOBACTAM	SULFAMETHOXAZOLE/TRIMETHOPRIM 400 BID 7d	N		N
25	67	R	M	PIPERACILLIN/TAZOBACTAM + CEFAZOLIN	CIPROFLOXACIN 500 BID 7d	N		N
26	8	L	M	CEFAZOLIN	AZITHROMYCIN w daily 7d (SULFA ALLERGY)	N		N
27	51	L	F	CEFAZOLIN	SULFAMETHOXAZOLE/TRIMETHOPRIM 400 7d	N		N
28	18	L	F	PIPERACILLIN/TAZOBACTAM	CIPROFLOXACIN 500 BID 7d	N		N
29	28	L	M	CIPROFLOXACIN + PIPERACILLIN/TAZOBACTAM	CIPROFLOXACIN 500 BID 7d	N		N
30	7	R	F	CIPROFLOXACIN	SULFAMETHOXAZOLE/TRIMETHOPRIM w BID 7d	N		Y
31	56	L	F	PIPERACILLIN/TAZOBACTAM	CIPROFLOXACIN 500 BID 7d	N		N
32	7	L	M	PIPERACILLIN/TAZOBACTAM	SULFAMETHOXAZOLE/TRIMETHOPRIM w BID 7d	N		N
33	4	R	M	PIPERACILLIN/TAZOBACTAM	SULFAMETHOXAZOLE/TRIMETHOPRIM w BID 7d	N		N

TABLE 1.  
(Continued)

Patient	Age	Side	Gender	Intra-Operative Antibiotics	Postoperative Antibiotics (Type, Dose in mg, Frequency, Duration)	Post-operative Infection	Other Postoperative Complications	1 Day OBS
34	4	L	F	PIPERACILLIN/TAZOBACTAM	SULFAMETHOXAZOLE/TRIMETHOPRIM w BID 7d	N	Patient pulled pack out POD1; Ear wick placed	N
35	65	L	M	PIPERACILLIN/TAZOBACTAM	SULFAMETHOXAZOLE/TRIMETHOPRIM w BID 7d	N		N
36	11	R	F	PIPERACILLIN/TAZOBACTAM	SULFAMETHOXAZOLE/TRIMETHOPRIM w BID 7d	N		N
37	7	R	M	PIPERACILLIN/TAZOBACTAM	SULFAMETHOXAZOLE/TRIMETHOPRIM w BID 7d	N		N
38	17	R	F	PIPERACILLIN/TAZOBACTAM	SULFAMETHOXAZOLE/TRIMETHOPRIM 800 BID 10d	N		N
39	61	L	F	PIPERACILLIN/TAZOBACTAM	SULFAMETHOXAZOLE/TRIMETHOPRIM 800 BID 10d	N		N
40	22	L	F	PIPERACILLIN/TAZOBACTAM	SULFAMETHOXAZOLE/TRIMETHOPRIM 800 BID 7d	N	Patient pulled pack out POD<7, Ear wick placed	N
41	10	L	M	PIPERACILLIN/TAZOBACTAM	CLINDAMYCIN w QID	N		N
42	3	L	F	PIPERACILLIN/TAZOBACTAM	SULFAMETHOXAZOLE/TRIMETHOPRIM 800 BID 7d	N	ED for lethargy and poor PO. Patient pulled pack out POD <2, Ear wick placed	N
43	65	L	M	PIPERACILLIN/TAZOBACTAM	CIPROFLOXACIN 500 BID 7d	N		N
44	11	R	F	PIPERACILLIN/TAZOBACTAM	SULFAMETHOXAZOLE/TRIMETHOPRIM w BID 7d	N		N
45	47	L	F	CIPROFLOXACIN + METRONIDAZOLE	LEVOFLOXACIN 750 daily 10 d	N	Took Cipro 6 doses and stopped due to nausea, started taking clindamycin for total 5d on her own, also given levofloxacin	N
46	67	R	M	PIPERACILLIN/TAZOBACTAM	CIPROFLOXACIN 500 BID 14d	N		N
47	34	L	M	PIPERACILLIN/TAZOBACTAM	CIPROFLOXACIN 500 BID 7d	N		N
48	5	R	M	PIPERACILLIN/TAZOBACTAM	SULFAMETHOXAZOLE/TRIMETHOPRIM w BID 7d	N		N
49	27	L	M	PIPERACILLIN/TAZOBACTAM	LEVOFLOXACIN 500 daily 14d	N		N
50	51	R	F	PIPERACILLIN/TAZOBACTAM	CIPROFLOXACIN 500 BID 7d	N		N
51	35	R	M	PIPERACILLIN/TAZOBACTAM	CIPROFLOXACIN 500 BID 14d	N		N

BID = twice daily

W = weight-based;

sulfamethoxazole/trimethoprim: 8–10 mg/kg/day divided every 12 hours

azithromycin: 10 mg/kg daily

cephalexin: 25–50 mg/kg/day divided every 8 hours

POD = postoperative day number

loss, vestibular dysfunction, and renal toxicity; make it unfavorable for use in prophylaxis. Thus, oral ciprofloxacin and levofloxacin, which have the same bioavailability as IV formulations, have become popular choices in oral antibiotic coverage of *P. aeruginosa* infections.<sup>14,15</sup> Yet, fluoroquinolones are not recommended in children due to the risk of arthropathy and tendinopathy.<sup>16</sup> Therefore, there are limited options for anti-pseudomonal prophylaxis and treatments in children.

Community-acquired methicillin-resistant *Staphylococcus aureus* (MRSA) is typically sensitive to sulfamethoxazole/trimethoprim and clindamycin.<sup>17</sup> MRSA resistance to clindamycin varies widely from 12 to 76 percent across the United States,<sup>18</sup> and thus clindamycin may not be a reliable antibiotic in MRSA coverage. Sulfamethoxazole/trimethoprim is effective at treating not only gram-positive bacteria (*Staphylococcus aureus*, *Streptococcus pneumoniae*), but also gram-negative bacteria (*Haemophilus influenzae*, *Klebsiella pneumoniae*). For these reasons, it is effective in treating chronic otitis media<sup>19</sup> and acute otitis media in the pediatric population.<sup>20</sup>

In this study, we administered IV anti-pseudomonal antibiotics preoperatively in the majority of patients. In children, we most commonly used a weight-based oral sulfamethoxazole/trimethoprim regimen postoperatively. While sulfamethoxazole/trimethoprim does not cover *Pseudomonas* sp., it is an optimal oral antibiotic for most community acquired MRSA. In adults, we most commonly used oral ciprofloxacin, which has the same bioavailability as the IV formulation.

Nearly all patients presenting to our facility with cholesteatoma underwent CWR, unless there was very limited attic disease or the posterior canal wall was unable to be reconstructed as noted on preoperative imaging. There was no bias for choosing CWR as a surgical method based on severity of infection, nor was there bias in choosing postoperative antibiotics. Any variability in postoperative antibiotic regimen was due to medication allergies and drug interactions. Most importantly, variability in antibiotics did not produce any differences in postoperative infection rates.

This selection process is identical to those of our historical controls.<sup>1,2</sup> In fact, two of the patients in our series had lateral semicircular canal fistulas due to extensive cholesteatoma preoperatively. Of note, neither of these patients experienced sensorineural hearing loss and both had no residual disease at second look.

While our case series showed a postoperative infection rate of 0% with the use of only oral antibiotics in the postoperative period, these data do not indicate that outpatient antibiotics are better than IV antibiotics. Simply, our data demonstrate that the infection rate is very low when CWR is performed with outpatient oral antibiotics. Surgeons may use their discretion to treat patients with IV antibiotics in the postoperative period based upon the extent of infection.

The causes of postoperative infection are certainly multifactorial. Prior to employing the outpatient antibiotic regimen, it is important to consider the patient's home environment and whether they are capable of adhering to aseptic wound care instructions. In our case

series, all subjects reported to have taken their oral antibiotics course. In our series, the wound is sutured with absorbable sutures and covered with dermabond without the use of a Penrose drain. Thus, patient-directed wound care is not needed. All subjects returned for their 1-week and 1-month follow-up appointments.

Another technical modification, in addition to those discussed above, was the exclusive use of 2-Flute otologic burs. Bone pâté harvested with these burs results in larger chip size, higher osteoblast cellular content and thus high bone viability.<sup>21</sup> This may facilitate decreased postoperative infection rates and wound healing, but future studies are needed.

Placing all CWR patients in observation (24 hours) or inpatient (48 hours) status for IV antibiotics has the potential to add additional cost to the hospital and patient. In contrast, treatment of a CWR wound infection could be costly with multiple days of IV antibiotics. Thus, outpatient management must not sacrifice infection risk for potential cost savings incurred by postoperative hospital stays for postoperative IV antibiotics. Our study suggests that postoperative IV antibiotics are not necessary, as the infection rate is not inferior with outpatient oral antibiotic regimens.

In addition, hospital admissions are prohibited from outpatient surgery centers, which may dissuade some surgeons from performing CWR. Our results suggest that CWR tympanomastoidectomy for cholesteatoma could be safely performed on an outpatient basis.

There are limitations to this study. This study compared infection rates to historical controls from another institution. The ideal study to compare post-operative intravenous versus oral antibiotic regimens in CWR tympanomastoidectomy would be a prospective randomized control trial. More importantly, the data presented here demonstrate that even without a historic control comparison, the postoperative infection rate is very low when patients are managed on an outpatient basis. Second, the findings presented here are based upon analysis of outcomes at a single institution under two surgeons. While our patient population varied in age and socioeconomic status, it is possible that these results may not be generalizable to all patients and all situations.

## CONCLUSIONS

Here we show that the infection rate of CWR tympanomastoidectomy with mastoid obliteration is low when performed on an outpatient basis. The infection rate is not inferior to those cases managed with postoperative intravenous antibiotics in a historical cohort. A larger prospective trial is warranted.

## ACKNOWLEDGEMENTS

We would like to thank George Eckert and James Slaven for their help with statistical analysis.

## BIBLIOGRAPHY

1. Gantz BJ, Wilkinson EP, Hansen MR. Canal wall reconstruction tympanomastoidectomy with mastoid obliteration. *Laryngoscope* 2005;115:1734-1740.

2. Walker PC, Mowry SE, Hansen MR, Gantz BJ. Long-term results of canal wall reconstruction tympanomastoidectomy. *Otol Neurotol* 2014;35:954–960.
3. Syms MJ, Luxford WM. Management of cholesteatoma: status of the canal wall. *Laryngoscope* 2003;113:443–448.
4. Dodson EE, Hashisaki GT, Hobgood TC, Lambert PR. Intact canal wall mastoidectomy with tympanoplasty for cholesteatoma in children. *Laryngoscope* 1998;108:977–983.
5. Shohet JA, de Jong AL. The management of pediatric cholesteatoma. *Otolaryngol Clin North Am* 2002;35:841–851.
6. Sheehy JL, Brackmann DE, Graham MD. Cholesteatoma surgery: residual and recurrent disease. A review of 1,024 cases. *Ann Otol Rhinol Laryngol* 1977;86:451–462.
7. Ueda H, Nakashima T, Nakata S. Surgical strategy for cholesteatoma in children. *Auris Nasus Larynx* 2001;28:125–129.
8. Cody DT, McDonald TJ. Mastoidectomy for acquired cholesteatoma: follow-up to 20 years. *Laryngoscope* 1984;94:1027–1030.
9. Palva T. Surgical treatment of chronic middle ear disease. II. Canal wall up and canal wall down procedures. *Acta Otolaryngol* 1987;104:487–494.
10. Black B, Gutteridge I. Acquired cholesteatoma: classification and outcomes. *Otol Neurotol* 2011;32:992–995.
11. Vartiainen E. Ten-year results of canal wall down mastoidectomy for acquired cholesteatoma. *Auris Nasus Larynx* 2000;27:227–229.
12. Neu HC. The role of *Pseudomonas aeruginosa* in infections. *J Antimicrob Chemother* 1983;11(Suppl B):1–13.
13. Karlowsky JA, Jones ME, Thornsberry C, Evangelista AT, Yee YC, Sahm DF. Stable antimicrobial susceptibility rates for clinical isolates of *Pseudomonas aeruginosa* from the 2001–2003 tracking resistance in the United States today surveillance studies. *Clin Infect Dis* 2005;40(Suppl 2):S89–98.
14. Wise R, Andrews JM, Marshall G, Hartman G. Pharmacokinetics and inflammatory-fluid penetration of moxifloxacin following oral or intravenous administration. *Antimicrob Agents Chemother* 1999;43:1508–1510.
15. Belforti RK, Lagu T, Haessler S, et al. Association between initial route of fluoroquinolone administration and outcomes in patients hospitalized for community-acquired pneumonia. *Clin Infect Dis* 2016;63:1–9.
16. Bradley JS, Arguedas A, Blumer JL, Saez-Llorens X, Melkote R, Noel GJ. Comparative study of levofloxacin in the treatment of children with community-acquired pneumonia. *Pediatr Infect Dis J* 2007;26:868–878.
17. Kim SH, Kim MG, Kim SS, Cha SH, Yeo SG. Change in detection rate of methicillin-resistant *Staphylococcus aureus* and *Pseudomonas aeruginosa* and their antibiotic sensitivities in patients with chronic suppurative otitis media. *J Int Adv Otol* 2015;11:151–156.
18. Moellering RC Jr. Current treatment options for community-acquired methicillin-resistant *Staphylococcus aureus* infection. *Clin Inf Dis* 2008;46:1032–1037.
19. van der Veen EL, Rovers MM, Albers FW, Sanders EA, Schilder AG. Effectiveness of trimethoprim/sulfamethoxazole for children with chronic active otitis media: a randomized, placebo-controlled trial. *Pediatrics* 2007;119:897–904.
20. Leiberman A, Leibovitz E, Piglansky L, et al. Bacteriologic and clinical efficacy of trimethoprim-sulfamethoxazole for treatment of acute otitis media. *Pediatr Inf Dis J* 2001;20:260–264.
21. Roth AA, Tang PC, Ye MJ, Mohammad KS, Nelson RF. Improved autologous cortical bone harvest and viability with 2Flute otologic burs. *Laryngoscope* 2017 [Epub ahead of print].