

University of New England DUNE: DigitalUNE

Biomedical Sciences Faculty Publications

Biomedical Sciences Faculty Works

2-16-2015

Posterior Approach To Kidney Dissection: An Old Surgical Approach For Integrated Medical Curricula

Frank J. Daly

University of New England, fdaly@une.edu

David L. Bolender

Medical College of Wisconsin

Deepali Jain

Michigan State University

Sheryl Uyeda

SUNY Upstate Medical University

Todd M. Hoagland

Medical College of Wisconsin

Follow this and additional works at: http://dune.une.edu/biomed_facpubs



Part of the [Endocrine System Commons](#), and the [Urogenital System Commons](#)

Recommended Citation

Daly, Frank J.; Bolender, David L.; Jain, Deepali; Uyeda, Sheryl; and Hoagland, Todd M., "Posterior Approach To Kidney Dissection: An Old Surgical Approach For Integrated Medical Curricula" (2015). *Biomedical Sciences Faculty Publications*. 6.
http://dune.une.edu/biomed_facpubs/6

This Article is brought to you for free and open access by the Biomedical Sciences Faculty Works at DUNE: DigitalUNE. It has been accepted for inclusion in Biomedical Sciences Faculty Publications by an authorized administrator of DUNE: DigitalUNE. For more information, please contact bkenyon@une.edu.

ASE-14-0094.R1
Descriptive article

**Posterior Approach to Kidney Dissection:
An Old Surgical Approach for Integrated Medical Curricula**

Frank J. Daly^{1*}, David L. Bolender², Deepali Jain³, Sheryl Uyeda⁴, Todd M. Hoagland²

¹Department of Biomedical Sciences, University of New England College of Osteopathic Medicine, Biddeford, Maine

²Department of Cell Biology, Neurobiology and Anatomy, Medical College of Wisconsin, Milwaukee, Wisconsin

³Department of Surgery, Grand Rapids Educational Partners, Michigan State University College of Human Medicine, Grand Rapids, Michigan.

⁴Department of Surgery, State University of New York Upstate Medical University, Syracuse, New York.

Running title: Posterior Approach to Kidney Dissection

*Correspondence to: Dr. Frank Daly, Department of Biomedical Sciences, Stella 428, University of New England College of Osteopathic Medicine, Biddeford, ME 04005. USA. E-mail:

fdaly@une.edu

ABSTRACT

Integrated medical curricular changes are altering the historical regional anatomy approach to abdominal dissection. The renal system is linked physiologically and biochemically to the cardiovascular and respiratory systems, yet anatomist often approach the urinary system as part of the abdomen and pelvic regions. As part of an integrated curriculum, the renal system must be covered relatively quickly after the thorax in the cadaver lab, often without the opportunity to fully appreciate the rest of the abdominal contents. This paper provides dissection instructions that follow the one of the historical surgical approaches for nephrectomy, including preservation of the posterior abdominal wall neurovasculature. Dissection procedures were developed for first year medical students, intending this posterior approach to the kidneys to be their first introduction to the renal system. It has been successfully implemented with first year medical students at the University of New England, College of Osteopathic Medicine. Utilizing this posterior approach to the kidney enabled the study of the anatomy of the kidneys, suprarenal glands and renal vessels, as well as the muscles of the lumbar spine, while maintaining the integrity of the anterior abdominal wall and peritoneal cavity for future gastrointestinal and reproductive system-based dissections.

Key words: gross anatomy education, medical education, medical curriculum; integrated anatomy curriculum, anatomy integration; renal system dissection; kidney dissection,

INTRODUCTION

Teaching cadaver-based gross anatomy in an integrated curriculum is becoming more prevalent in medical education in the United States (Drake et al., 2009, 2014). A variety of challenges, strengths and drawbacks to working within this type curriculum has been well documented. Congdon (1930) claimed that integrating the systems prevents duplication of efforts and favors a clear grasp of the material for the most mature type of medical student. Van der Veken and colleagues came to a similar conclusion 80 years later (Van der Veken et al, 2009). Integration of the basic and clinical sciences leads to a higher level of mastery of clinical knowledge and a steeper learning curve while mastering basic knowledge (Van der Veken et al, 2009).

Authors caution that integration and curricular reform can be complicated and time intensive in the planning stages for the faculty (Drake, 1998, Craig et al., 2010; Bolender et al., 2013). Some anatomists are critical of the effectiveness of integrated self-directed learning (Monkhouse and Farrell, 1999), while others, who focus on learning theory, are strong advocates of integrating disciplines and self-directed learning to enhance the overall education (Harden, 2000; Larkin and McAndrew, 2013).

Care needs to be taken when examining the basic science needs of the student physicians. Surgeons (Older, 2004; Hinduja et al., 2005) and anatomists (Pabst 2009; Davis et al., 2014) emphasize the need for a strong anatomy foundation. However, the best methods for teaching anatomy vary greatly (Kerby et al., 2001; Johnson et al, 2012). There is no consistent method for the best approach to teaching anatomy in an integrated curriculum. Implementation of systems-based gross anatomy instruction within a regionally-based dissection course is often difficult and has not been well documented. This work attempts to address that issue by describing the

approach taken at the University of New England College of Osteopathic Medicine (UNECOM) in regards to how to dissect the renal system in close temporal proximity to the cardiac and respiratory systems, prior to dissection of the abdomen and gastrointestinal system.

UNECOM curriculum

In 2012, UNECOM revised its curriculum to morph the individual discipline based courses into two integrated courses. Most of the basic science courses (biochemistry, immunology, microbiology, pathology, pharmacology and physiology) were brought together into a single course, Osteopathic Medical Knowledge (OMK). Gross anatomy, embryology and histology were joined with clinical skills and osteopathic manipulative medicine to create the only other course in the first year curriculum, Osteopathic Clinical Skills (OCS). These two courses allow for integration of the basic sciences with each other and with the clinical sciences, similar to what others have recommended (Drake, 1998; Cooke et al., 2010; Craig et al., 2010).

It was in coordination with the academic dean and all departments that a systems-based curriculum was undertaken, with emphasis on following a modified physical diagnosis protocol for driving the sequence of the systems-based curriculum. The sequence of systems for the entire first academic year is covered in the following order: wellness, body defenses/adaptation, neuromusculoskeletal, respiratory, cardiovascular, renal, gastrointestinal, endocrine, and reproductive. During the 12 weeks (2 examination periods), the neuromusculoskeletal system is the main focus driving the curriculum of the OMK and OCS courses, allowing anatomists to work in the extremities, clinicians to work on physical diagnosis of the limbs, and the other basic scientists to build a foundation of cell function, adhesion and communication. This curricular

approach is located between the multidisciplinary and interdisciplinary levels of integration described by Harden (2000).

Covering the cardiovascular, respiratory and renal systems in close temporal proximity is not a sequence that is unique to UNECOM. Other institutions have been using this sequence as part of their integrated curricula for years (Moqattash et al, 1995; Smith and McManus, 2015). Some programs have integrated anatomy in a regional dissection of the body with a significant benefit in that the dissection mirrors in the approach taken during physical examinations (Klement et al., 2011).

Yet as Benninger and colleagues (2014) states, anatomy does not come in discrete packets. The physiologically linked systems are not easily approached from a regional anatomical dissection (Congdon, 1930; Congdon et al., 1953; Klement et al., 2011; Bolender et al., 2013). Until recently, published anatomy dissection guides have been based upon a regional approach (Clemente, 2010; Tank, 2013). New, web-based dissectors (Gould et al., 2011; Tank, 2013) allow for individual instructors to develop new dissection procedures, but they are still limited in the order that systems can be dissected. Typically, the anterior abdominal wall and the entire gastrointestinal system must be dissected prior to dissection of the renal system.

Current approaches to nephrectomy are performed under laparoscopic guidance (Clayman et al, 1991) and while useful, it does not provide the best learning experiences for students in their first introduction to the renal system (Ahmed et al., 2011). Others have found that in an integrated systems-based medical curriculum, anatomy is best taught using prosections rather than the regional approach of dissection (Larkin and McAndrew, 2013), although the vast majority of anatomists would still advocate for dissection (Congdon, 1930; Monkhouse and Farrell, 1999; Older, 2004; Reeves et al., 2004; Böckers et al., 2010; Ahmed et al., 2011; Larkin

and McAndrew, 2013; Bergman et al., 2014). In reality, the way that anatomy is being taught is really a combination of approaches, including: dissection, prosection, computer-assisted learning, clinical anatomy, and imaging (Raftery, 2006; Sugand et al., 2010; Johnson et al., 2012). This paper provides instruction on older surgical approaches to the kidneys that does not require prior dissection of the entire abdominal cavity.

RENAL DISSECTION

Traditionally, cadaveric dissections of the renal system are approached from an anterior direction for convenience as part of a regional dissection of the abdomen, typically after the gastrointestinal system has been dissected. As part of an integrated curriculum driven by systems, the kidney offers a unique challenge when it is juxtaposed with the cardiac and respiratory systems prior to gastrointestinal system study. Though generally considered an organ of the urogenital system, the kidney's inherent role in the cardiovascular system, as well as its involvement in regulation of fluid and acid-base status and its close structural relationship with the adrenal gland complicates the positioning of this organ adjacent to anatomically associated systems versus physiologically associated systems. Further, its anatomical location in the retroperitoneal space, along the posterior abdominal wall coupled with its intimate structural relationship with pelvic structures complicates the student's task.

Integral to a complete renal dissection is an understanding of the retroperitoneal structures and clinical implications of their anatomy. The distinction between peritoneal and retroperitoneal regions can seem abstract to students and can be difficult to distinguish, particularly by students participating in their first dissection from an anterior approach. Additionally, students often have not yet explored the pelvis which precludes discussion of the reproductive systems and the renal system's embryological ties to these systems.

In light of these drawbacks and faced with a transition to a systems-based, more clinically oriented curriculum, the authors considered a posterior approach to the kidney. As the kidney would now be introduced in relation to the cardiovascular system rather than to its anatomical neighbors in the abdomen, a posterior approach to dissect the kidney prior to the abdominal dissection seemed to be the best solution to this problem. It was important to preserve the renal system's structural and functional relationships to the abdominal and pelvic contents for future study. As students within the UNECOM curricula have already dissected the back muscles during the neuromusculoskeletal system, using a posterior approach to the kidney allows for isolated exploration of the kidney without opening the anterior abdominal wall prematurely.

There was some discussion as to whether dissection should proceed on the left or the right of the cadaver. The authors anticipated the dissection would be easier on the left side due to better development of the anterior pararenal space (Lei et al., 1990), although clinical correlations related to this approach may be compromised (Kimura and Araki, 1996). Yet, the presence of the liver on right limits the anterior pararenal space, which also contains the head of the pancreas and the relatively short ascending colon (Lei et al., 1990). It was decided that, although there is less space for dissection on the right, students would preserve more clinically relevant structures by dissecting the left kidney from an anterior approach later in the course. The right kidney was dissected from a posterior approach, similar to open nephrectomy.

There are a few different surgical approaches to open nephrectomy, depending upon the condition of the kidneys to be removed. Han and colleagues (2010), when removing healthy kidneys from live donors for transplant, transect the intercostal muscles between the 11th and 12th ribs, anterior to and immediately superior to the 12th rib. This provided the live donors with shorter recovery and rehabilitation time. Novick (1980) recommends avoiding transecting the

abdominal musculature or resection of the 12th rib. Instead, he details incision of the lumbodorsal (thoracolumbar) fascia and the 12th rib costovertebral ligament when performing nephrectomy on patients with end-stage renal disease. These individuals had significantly smaller kidneys which allowed for this less invasive approach.

Because in the anatomy lab, there is no concern for the body donor's recovery from dissection, removal of the overlying musculature is recommended by the authors to augment visualization of the kidneys in the retroperitoneal area. The removal of rib 12 is also recommended to further enhance access to the apical pole of the kidneys and the adrenal glands.

RECOMMENDED LABORATORY EXERCISES

There are a few exercises that should accompany a dissection of the kidney, depending upon resources; review of structures associated with the kidney (by students as study time), study of surface anatomy of the lumbar region, and imaging of the kidneys, via x-ray, ultrasound, CT and MRI. Each of these exercises (except ultrasound) was part of the student's experience at UNECOM, although not necessarily always the anatomist's responsibility. With anatomy being part of the osteopathic clinical skills course, osteopathic clinicians take primary teaching responsibility for both surface anatomical relationships of the kidneys as well as various imaging modalities. Both surface anatomy and imaging small group sessions were performed as part of a clinical skills lab (outside of cadaver lab dissection time) and an osteopathic manual medicine lab (again outside of cadaver lab dissection time).

REVIEW OF RENAL STRUCTURES

Verify that the posterior surface of each kidney is related, through the renal fat and fascia, to the diaphragm, psoas major muscle, quadratus lumborum muscle, and transversus abdominis

muscle. The superior pole of the right kidney is near the 12th rib. The nerves that supply the abdominal wall and the lumbar plexus of nerves that innervate the lower limb are best appreciated in relation to the posterior abdominal wall. The lumbar nervous plexus lies in close proximity to the pararenal fat of surrounding the kidney. The branches of the lumbar plexus will be visible while removing the kidney and should be studied again from inside the abdominal cavity. Often the subcostal nerve emerges through the fibers of the thoracolumbar fascia to extend along a course that is superficial to the transversus abdominis muscle. The peripheral branches of the nerve lie inferior and lateral to the 12th rib.

SURFACE ANATOMY OF THE LUMBAR REGION

The posterior approach to the kidney enables the students to become familiar with the surface anatomy of the kidneys and to identify the renal angles prior to dissection. Outline the boundaries of both kidneys in the right and left lumbar (flank) regions from a posterior orientation. Have a peer lie prone and locate ribs 11 and 12. The left kidney (5 cm x 7.5 cm) lies deep to ribs 11 and 12 and is centered on the junction between the transpyloric line and the left scapular line. The hilum of the left kidney and the renal arteries are located at L2 vertebral level. The right kidney sits almost entirely below the transpyloric line on the right scapular line. It is approximately the same size as the left kidney, but it is located about 2.5 cm more inferior.

The kidneys are retroperitoneal organs that lie within the pararenal fat of the posterior abdominal wall. To reach them from a posterior approach, a variety of back and posterior abdominal wall musculature must be identified and removed. The subcutaneous latissimus dorsi is easily palpated, but the underlying serratus posterior inferior is often difficult to detect. Deep to these are the erector spinae (iliocostalis, longissimus and spinalis) muscles whose lateral border is readily determined. The external abdominal oblique, internal abdominal oblique and

transversus abdominis muscles form the lateral part of the posterior abdominal wall. The posterior aponeurosis of these muscles contributes to the thoracolumbar fascia. Deep to these back muscles is the quadratus lumborum, located between the iliac crest and the 12th rib, immediately lateral to the transverse processes of lumbar vertebrae. Immediately anterior to the quadratus lumborum muscle is the pararenal fat and the kidneys in the retroperitoneal space.

CLINICAL EXAMINATION

Clinical examination of the kidneys by palpation necessitates prior knowledge about the renal angle and the surface anatomy of the kidney. The clinical examination of the kidneys by the ballottement method is typically performed on supine patients (or student peers) (Chandrasekhar, 2006; Bickley, 2009). The procedure is briefly outlined here.

Student physicians (with freshly washed hands) should use both hands to attempt to palpate the kidneys.

1. Student physicians place their hand in their peer's upper quadrant lateral and parallel to rectus abdominis muscle.
2. While applying deep pressure with the anterior hand, the student physician attempt to palpate (ballotte) the kidney with the posterior hand, inferior to the 12th rib at the costophrenic angle.
3. While pressing hands firmly together, the student physician has their peer to take a deep breath in further attempt to feel the moving inferior pole (firm, smooth, round mass) of the kidney. In thin peers, this motion is easiest to detect.
4. Exhalation by the peer allows the kidney to shift back to its normal position, which can also be detected by the student physician.

IMAGING THE KIDNEYS

Because both kidneys are embedded in thick perirenal fat and usually have no calcified structures located within the organ, they can be difficult to visualize on abdominal plane films. Typically, only the outline of the inferior and lateral margins of the kidney can be seen, lateral to the body of L3 vertebra and the edge of the psoas major muscle. Kidneys are significantly easier to visualize in either CT or MRI. The kidneys lie lateral to the vertebral column between vertebral levels T12 and L3, anterior to quadratus lumborum and lateral to psoas major in the posterior abdominal wall. It is relatively straightforward to follow the renal vasculature from the abdominal aorta and inferior vena cava directly to the hilum of the kidney. Both CT and MRI allow for internal structures of the kidney to be inspected, including the renal calyces, cortex, columns, and pyramids.

STRUCTURE LISTS

The authors would like to strongly suggest that faculty should provide a list of structures to be dissected, identified and preserved as part of this posterior approach to the kidney (Appendix 1). Documentation of the usefulness of structure lists has been detailed in work of Hofer and colleagues (2011). The structure list has improved dissection quality (Hofer et al., 2011) and near-peer teaching (Evans and Cuffe, 2009) in other's work and it has a strong effect at UNECOM as well. In the first year that this posterior approach to the kidneys was performed at UNECOM (Spring 2013), there was no structure list to guide the students' dissections. Most of the students removed at least some of the neurovascular bundles of the posterior abdominal wall. Only three dissections of 31 were able to preserve the subcostal, ilioinguinal and iliohypogastric nerves, as well as the subcostal and superior lumbar arteries. This past year (spring 2014), with hard-copy dissection instructions, in addition to their dissector (Tank, 2013)

and a detailed list of structures, students were more consistently able to preserve the vessels and nerves of the posterior abdominal wall as they removed the kidneys.

POSTERIOR APPROACH TO THE KIDNEY DISSECTION INSTRUCTIONS

This posterior approach to the kidney is intended to follow dissection of the superficial and deep back. If these dissections are done, start the dissection from step 5. If the back is not dissected, refer to a complete dissector for detailed back dissection instructions.

1. Use a scalpel to make a vertical skin incision between the external occipital protuberance and the coccyx. Make a horizontal skin incisions between left acromion and right acromion. Make a second horizontal incision inferior to the left rib 12 and right rib 12. Make two curved incisions 2.5cm inferior to the iliac crests from coccyx to the axillary lines. (Figure 1)
2. Remove the skin to expose the underlying extrinsic back muscles (Figure 1).

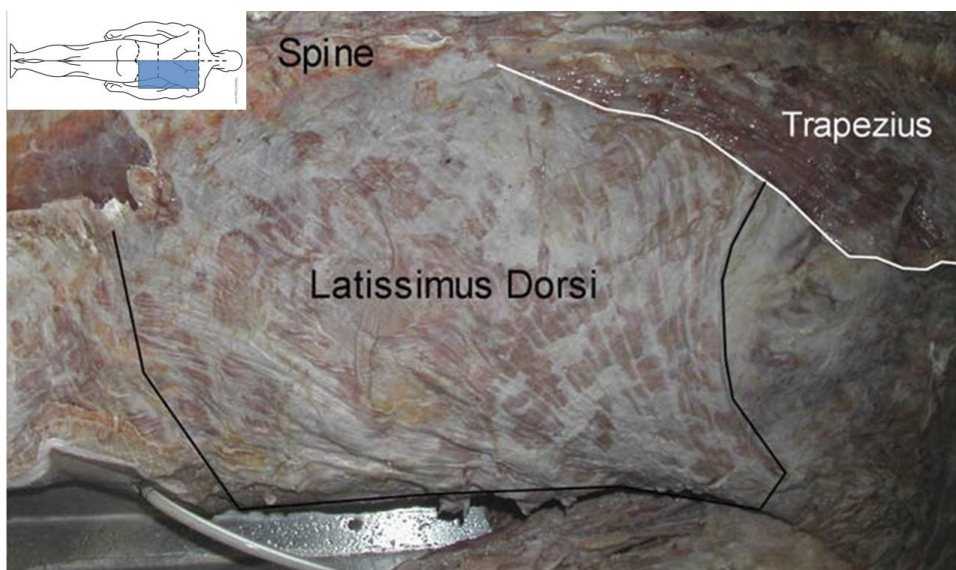


Figure 1. Superficial muscles of the back after removal of the skin. Inset line drawing shows location of photograph in shaded region and original incision locations for skin removal.

3. Detach the inferior superficial back muscles (trapezius and latissimus dorsi) from their medial attachments. Reflect trapezius superiorly and latissimus dorsi inferiorly (Figure 2).

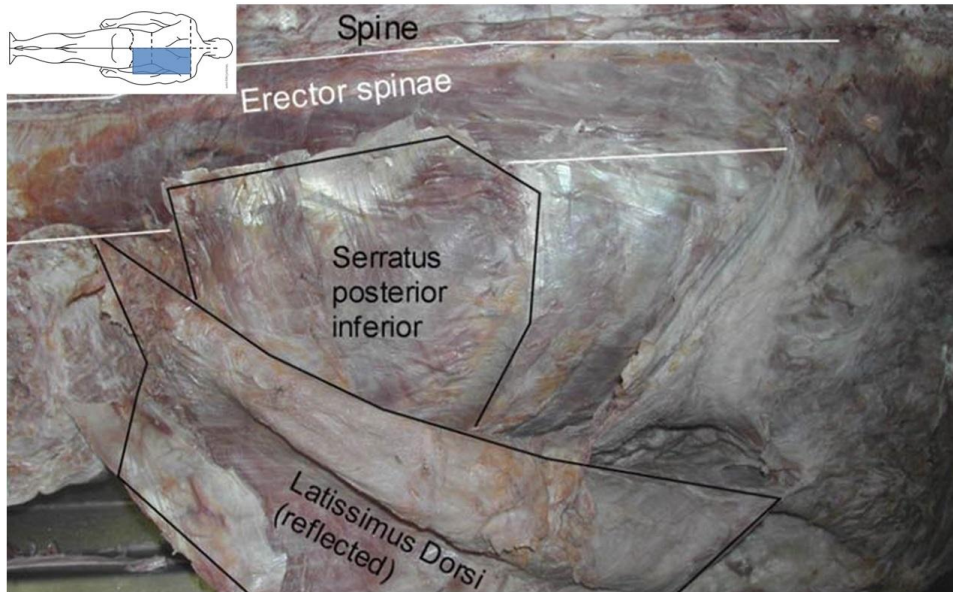


Figure 2. Intermediate muscles of the inferior back. Latissimus dorsi is reflected revealing serratus posterior inferior and erector spinae muscles.

4. Detach serratus posterior inferior from its medial attachment and reflect the muscle laterally.
5. Reflect the erector spinae muscles (iliocostalis, longissimus, and spinalis) superiorly to expose the middle layer of thoracolumbar fascia (Figure 3).
6. Carefully remove the middle layer of thoracolumbar fascia from the underlying investing fascia of the quadratus lumborum. The middle layer of thoracolumbar fascia should remain attached laterally to prevent rupture into the peritoneal cavity (Figure 4).
7. Identify the right quadratus lumborum muscle (Figure 4). Clean and gently mobilize the lateral border of quadratus lumborum and identify the pararenal fat pad.

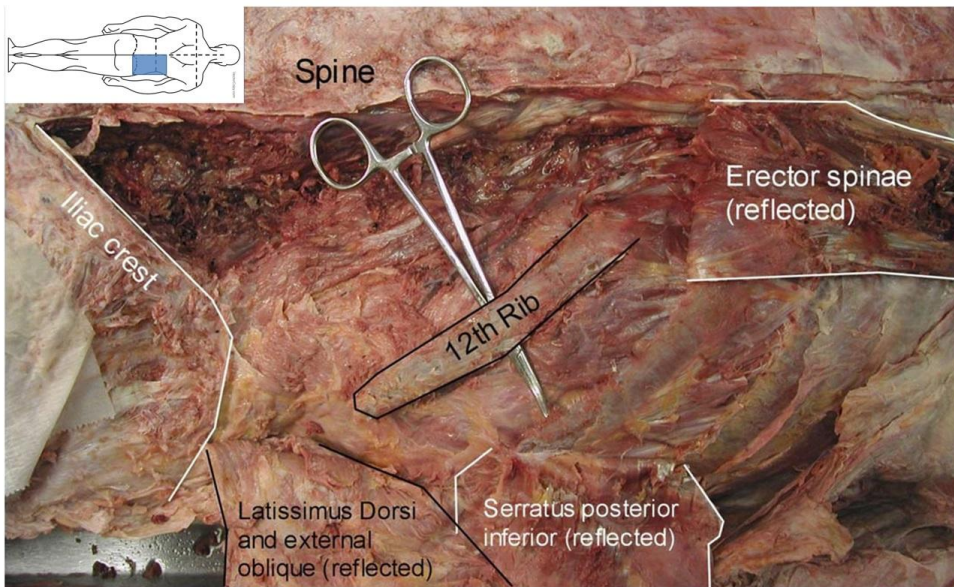


Figure 3. Reflection of the erector spinae muscle and elevation of 12th rib. The trapezoidal boundaries of the 12th rib, the lumbar vertebral spines and the iliac crest define the route of access to the retroperitoneal region and the kidney. Inset line drawing shows location of photograph in shaded region now at higher magnification.

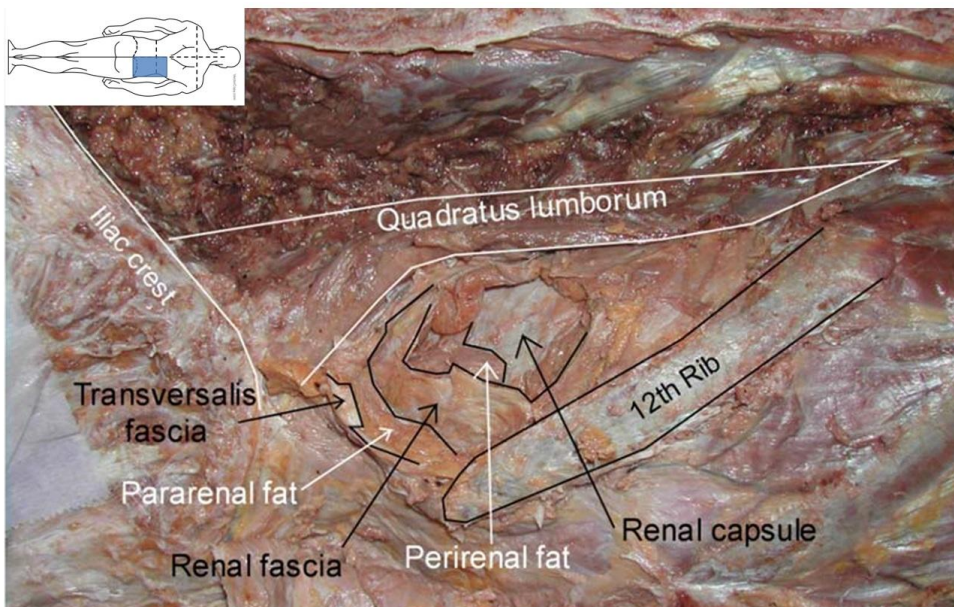


Figure 4. Fascia and fat of retroperitoneal region surrounding the kidney, from superficial to deep: transversalis fascia (middle layer of thoracolumbar fascia), pararenal fat, (Gerota's) renal fascia, perirenal fat, renal capsule. The boundaries of quadratus lumborum are outlined.

8. Carefully remove the quadratus lumborum, in small pieces, to expose the lumbar plexus deep to this muscle.
9. Identify the lateral border of the psoas major muscle and the several branches of the lumbar plexus that emerge from that location.
10. Use blunt dissection to remove the retroperitoneal fascia / fat from the posterior abdominal wall lateral to the psoas major muscle (Figure 5).

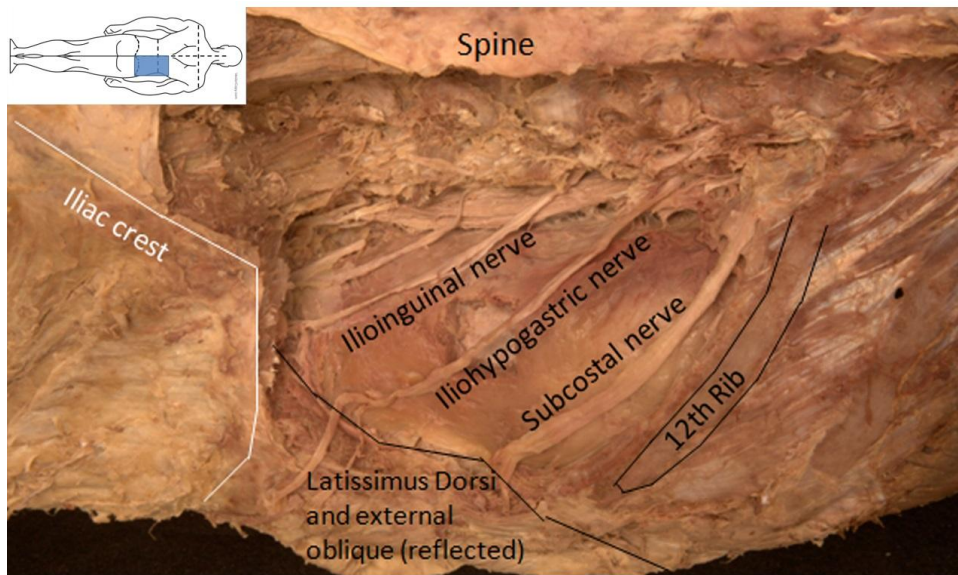


Figure 5. Vertical flipped left retroperitoneal region showing the position of the posterior abdominal wall nerves. The position of the nerves has been maintained while preserving the deeper retroperitoneal structures, including the pararenal fat.

11. Palpate rib 12 and locate the subcostal nerve 1 cm inferior to the rib. Find the iliohypogastric and ilioinguinal nerves 2.5 cm inferior to the subcostal nerve and find the lateral cutaneous nerve of the thigh 2.5 cm inferior to the iliohypogastric and ilioinguinal nerves.
14. Dissect through Gerota's renal fascia to expose and remove the perirenal fat.

15. Rib 12 can be removed, allowing for greater access to the kidney (Figure 6). Make an incision superior to rib 12, from the costovertebral angle to the lateral tip of the rib, through the external intercostal, internal intercostal and subcostal muscles.

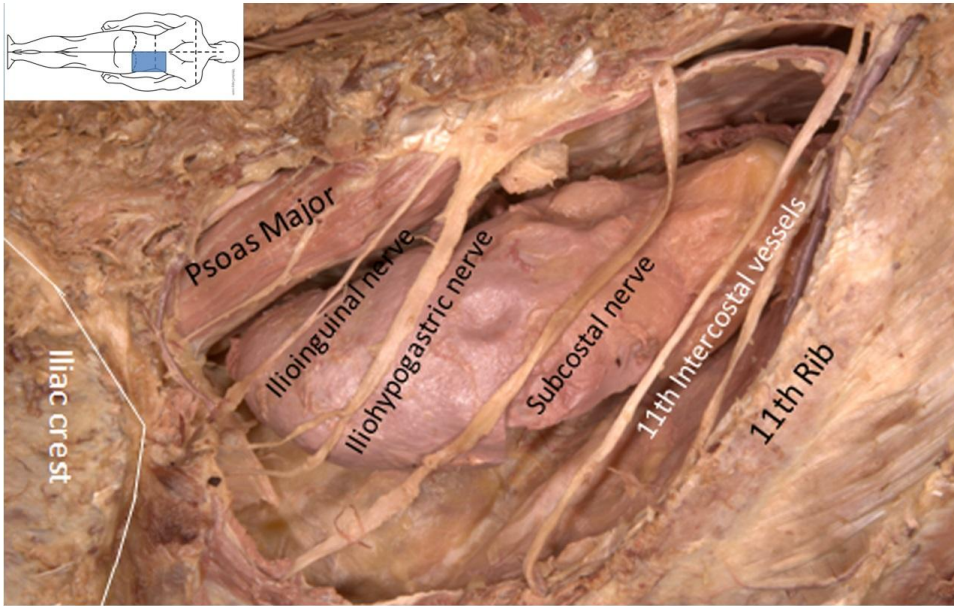


Figure 6. Vertical flipped left retroperitoneal region after resection of the 12th rib showing the position of the posterior abdominal wall nerves. The position of the nerves has been maintained while deeper structures (quadratus lumborum, pararenal fat,

16. Dislocate the costovertebral joint and remove rib 12 using a rib cutter after cutting the attachment of the diaphragm into the internal surface of the rib.
17. Carefully dissect between the kidney and the suprarenal gland to separate the organs.
18. Move the kidney and suprarenal gland toward the posterior midline without cutting the renal vasculature. Continue to use blunt dissection to remove the remaining perirenal fat and renal fascia.
19. Identify the renal pelvis and dissect the ureter from the posterior abdominal wall.

20. Dissect and clean the right renal blood vessels to the inferior vena cava.
21. Cut the ureter, renal artery, and renal vein proximal to where the vessels begin branching.
22. Remove the kidney and divide it into anterior and posterior halves by splitting it longitudinally along its lateral border and use the renal pelvis as the hinge.

DISCUSSION

The initial dissection was done without written instructions by two 4th year Medical College of Wisconsin students (authors DJ and SU). These students were then asked to write up instructions for the posterior approach to the kidney that the first year medical students in a system-based curriculum would be required to follow. In writing the dissection instructions, care was taken to make sure the procedure described would avoid damage to structures belonging to the gastrointestinal system.

Using the posterior approach outlined above (with some modifications from the original directions), first year Osteopathic Clinical Skills students at UNECOM were able to successfully localize the kidneys in the retroperitoneal region without entering the peritoneal cavity. This was done within the normally scheduled three-hour laboratory session. The muscles of the posterior abdominal wall were clearly identified and preserved, however many of the nerves were destroyed during dissection. The physician authors (D.J. and S.U.) also lost the iliohypogastric nerve during their initial dissection. The first year of this approach at UNECOM resulted in nerve loss in most (28 of 31) dissections. The second year of this posterior approach to the kidney dissection at UNECOM yielded better results. The students, following hard copy instructions, and a structure list, had significantly better preservation of the posterior abdominal

nerves. This was the only time that new dissection instructions were added to physical copies of Grant's Dissector (Tank, 2013) utilized in the dissection laboratory. Having completed the thoracic dissection prior to this dissection allowed some retraction of the liver and diaphragm to give better access to the superior pole of the kidney.

Overall, the dissections were complete and osteopathic clinical skills faculty were able to thoroughly examine the students on all aspects of the kidney and associated structures that were covered in previous years. Students were competent in their knowledge of the structures surrounding the upper urinary system. Unfortunately, only the highest performing students took advantage of this initial renal dissection as a stepping off point for future abdominal dissections. At UNECOM, the subsequent abdominal dissections correlate with the gastrointestinal system only. Few students had a strong interest in revisiting the kidneys and their relationships. The osteopathic clinical skills course, of which the anatomical dissection is a part, is cumulative and comprehensive course as it progresses. The typical student knows that there is little chance of running into a detailed kidney or adrenal gland related question in subsequent examinations, especially because there are also neuromusculoskeletal, cardiovascular and respiratory questions that will be covered on subsequent exams, in addition to the kidney and any new material. With respect to the kidney and the urinary tract, students should be able to: describe the embryological development, follow the formation of urine and movement of blood associated with the kidney, outline the structure of the urinary system, interpret a KUB (kidney, ureter and bladder) plain film, recognize renal structures on CT and MRI images, assess lumbar back pain, and perform renal osteopathic physical exam. UNECOM students are comprehensively, but randomly, tested on this material on all subsequent clinical skills examinations in the remainder of their first year and the entire second year of the curriculum.

As medical education becomes more integrated across disciplines and more closely associated with relevant clinical medicine (Kulasegaram et al, 2013), anatomical courses of study must consider function as well as form. Structures need to be introduced in systems that are occasionally unrelated to their regional location. This disciplinary integration is designed to enable students to better understand the anatomy, physiology, biochemistry and pathophysiology of each organ system. In order to allow integration of the cardiovascular, respiratory and renal systems, without compromising the peritoneal cavity, a posterior approach to dissection of the kidney was successfully implemented in a medical school curriculum. The authors found this method allowed unrestricted access to the retroperitoneal region and the kidney, as long as the deep back had been previously dissected.

The authors found this approach allowed clear demarcation between the intraperitoneal and retroperitoneal regions, although the contents of the peritoneal cavity were not visualized at this point. From a clinical perspective, this posterior approach to the kidney introduces students to the historical surgical procedures used for nephrectomy and adrenalectomy. Current surgical procedures for nephrectomy use laparoscopic techniques for trained physicians already familiar with the neurovasculature and fascial planes of the retroperitoneal region. The older, posterior approach to kidney removal presented here allows the student, often for the first time, to become comfortable with the regional anatomy. The authors found this approach to be advantageous over an anterior dissection in that it allowed independent exploration of the kidney to better study form with function and a clearer understanding of the peritoneal regions of the abdomen.

The major advantage of this posterior approach to the kidney is that it allows for earlier presentation of the urinary system in close temporal positioning to the cardiac and respiratory systems, prior to study of the gastrointestinal system. It allows for access to the retroperitoneal

space without compromise of the intraperitoneal cavity and disruption of most of the abdominal contents. The osteopathic medical knowledge (basic science) course directors are satisfied that the renal system, with its physiological links to other systems, can be covered completely significantly earlier than a traditional regional approach to the abdomen would allow.

There are two major drawbacks to this posterior approach to the kidney. First is that the abdominal relationships between the gastrointestinal system and renal system cannot be presented as a complete abdominal physical examination would emphasize. Each of the systems is covered separately, even though the physician's examination of the abdomen would include all systems located there. This cannot be easily resolved based upon the current curriculum and the burden is placed upon subsequent courses and the students themselves to assimilate this information. The second drawback to this approach is initial restricted access to the right kidney. Because of the location of the undissected liver, the access to the hilum of the right kidney and to the adrenal gland is somewhat compromised. Removal of the right 12th rib was critical in successfully removing the kidney with intact vasculature in the hilum. Additionally, this approach is problematic in learning the relationships of the renal structures to those of the abdomen and pelvis. It falls short in illustrating the location of the kidney in the abdomen and its associated vasculature and urinary drainage (ureter) through the abdomen and into the pelvis. Fortunately, the bilateral nature of the body offers an elegant solution in that the renal structures can be again dissected when the abdomen is opened from an anterior direction.

CONCLUSION

It's the authors' opinion that integrating cadaveric dissection into a systems-based curriculum in order to juxtapose the renal and cardiorespiratory systems is possible using a

posterior approach to the right kidney. This allows students to understand renal anatomy as well as preserve the left kidney to be explored during the abdominal dissection, as time allows. The posterior approach to kidney dissection allows the urinary organs to be studied in coordination with other disciplinarily related systems, as well as to maintain the anatomical relationships discovered during regional approaches to anatomy. We found the posterior approach to the kidney dissection for an integrated systems-based curriculum to be advantageous when done on the right while preserving the left side for traditional dissection from an anterior abdominal approach.

ACKNOWLEDGEMENTS

The authors wish to thank the individuals who donated their bodies for the advancement of education and research. Additionally, they wish to thank Mr. Joel Talsma for providing some of the photographs included in this work.

NOTES ON CONTRIBUTORS

FRANK DALY, Ph.D., is an associate professor in the Department of Biomedical Sciences at the University of New England, College of Osteopathic Medicine in Biddeford, Maine. He teaches human gross anatomy, histology and embryology in an integrated first-year medical Osteopathic Clinical Skills course and the same courses to first-year dental students.

DAVID L. BOLENDER, Ph.D., is an associate professor in the Department of Cell Biology, Neurobiology and Anatomy at the Medical College of Wisconsin, Milwaukee, Wisconsin. He teaches clinical human anatomy, human development, and cell and tissue biology.

DEEPALI JAIN, M.D., is a third-year resident in the General Surgery Residency Program in Grand Rapids Medical Education Partners and Michigan State University College of Human Medicine, Grand Rapids, Michigan. She worked on this project as a fourth year medical student while taking an advanced anatomy elective course at the Medical College of Wisconsin.

SHERYL UYEDA, M.D., is a fourth-year resident in the Department of Surgery at State University of New York Upstate Medical University, Syracuse, New York. She worked on this project as a fourth year medical student while taking an advanced anatomy elective course at the Medical College of Wisconsin.

TODD HOAGLAND, Ph.D., is an associate professor in the Department of Cell Biology, Neurobiology and Anatomy at the Medical College of Wisconsin in Milwaukee, Wisconsin. He is course director and teaches in Clinical Human Anatomy and teaches histology in an integrated curriculum.

LITERATURE CITED

Ahmed K, Rowland S, Patel VM, Ashrafian H, Davies DC, Darzi A, Athanasiou T, Paraskeva PA. 2011. Specialist anatomy: Is the structure of teaching adequate? *Surgeon* 9:312–317.

Benninger B, Matsler N, Delamarter T. 2014. Classic versus millennial medical lab anatomy. *Clin Anat* 27:988–993.

Bergman EM, Verheijen IW, Scherpbier AJ, Van der Vleuten CP, De Bruin AB. 2014. Influences on anatomical knowledge: The complete arguments. *Clin Anat* 27:296–303.

Bickley LS. 2009. *Bates' Guide to Physical Examination*. 10th Ed. Philadelphia, PA: Lippincott, Williams & Wilkins. 964 p.

Böckers A, Jerg-Bretzke L, Lamp C, Brinkmann A, Traue HC, Böckers TM. 2010. The gross anatomy course: An analysis of its importance. *Anat Sci Educ* 3:3–11.

Bolender DL, Ettarh R, Jerrett DP, Laherty RF. 2013. Curriculum integration = course disintegration: What does this mean for anatomy? *Anat Sci Educ* 6:205–208.

Chandrasekhar AJ. 2006. Screening Physical Exam: Kidneys. Loyloa University Medical Education Network. Chicago, IL. URL: <http://www.meddean.luc.edu/lumen/meded/medicine/pulmonar/pd/pstep49.htm> [accessed 15 December 2014].

Clayman RV, Kavoussi LR, Figenschau RS, Chandhoke PS, Alabala DM, 1991. Laparoscopic nephroureterectomy: Initial clinical case report. *J Laparoendosc Surg* 1:343–349.

Clemente CD. 2010. Clemente's Anatomy Dissector. 3rd Ed. Baltimore, MD: Lippincott, Williams & Wilkins. 464 p.

Congdon ED. 1930. An attempt to improve the methods of anatomical teaching, including the organization of the dissection to an unusual degree by systems and the bringing of the developmental, gross, and microscopic anatomy of individual organs together in the schedule. *Anat Rec* 45:323–337.

Congdon ED, Hooker D, Huber JF, Kampmeier OF. 1953. A symposium on the closely correlated or integrated course in anatomy. *Anat Rec* 117:805–828.

Cooke M, Irby DM, O'Brien BC. 2010. *Educating Physicians: A Call for Reform of Medical School and Residency*. 1st Ed. San Francisco, CA: Jossey-Bass. 320 p.

Craig S, Tait N, Boers D, McAndrew D. 2010. Review of anatomy education in Australian and New Zealand medical schools. *ANZ J Surg* 80:212–216.

Davis CR, Bates AS, Ellis H, Roberts AM. 2014. Human anatomy: Let the students tell us how to teach. *Anat Sci Educ* 7:262–272.

Drake RL. 1998. Anatomy education in a changing medical curriculum. *Anat Rec* 253:28–31.

Drake RL, McBride JM, Lachman N, Pawlina W. 2009. Medical education in the anatomical sciences: The winds of change continue to blow. *Anat Sci Educ* 2:253–259.

Drake RL, McBride JM, Pawlina W. 2014. An update on the status of anatomical sciences education in united states medical schools. *Anat Sci Educ* 7:321–325.

Evans DJ, Cuffe T. 2009. Near-peer teaching in anatomy: An approach for deeper learning. *Anat Sci Educ* 2:227–233.

Gould DJ, Franklin SR, MacPherson BR. 2011. *Thieme Dissector*. 1st Ed. Georg Thieme Verlag KG, Stuttgart, Germany. URL: <http://www.dissector.thieme.com/Account/Login.aspx> [accessed 13 September 2014].

Han WK, Lee HY, Jeon HG, Joo DJ, Rha KH, Yang SC. 2010. Quality of life comparison between open and retroperitoneal video-assisted minilaparotomy surgery for kidney donors. *Transplant Proc* 42:1479–1483.

Harden RM. 2000. The integration ladder: A tool for curriculum planning and evaluation. *Med Educ* 34:551–557.

Hinduja K, Samuel R, Mitchell S. 2005. Problem-based learning: Is anatomy a casualty? *Surgeon* 3:84–87.

Hofer RE, Nikolaus OB, Pawlina W. 2011. Using checklists in a gross anatomy laboratory improves learning outcomes and dissection quality. *Anat Sci Educ* 4:249–255.

Johnson EO, Charchanti AV, Troupis TG. 2012. Modernization of an anatomy class: From conceptualization to implementation. A case for integrated multimodal-multidisciplinary teaching. *Anat Sci Educ* 5:354–366.

Kimura K, Araki T. 1996. Images in clinical medicine. Nutcracker phenomenon. *N Engl J Med* 335:171.

Kerby J, Shukur ZN, Shalhoub J. 2011. The relationships between learning outcomes and methods of teaching anatomy as perceived by medical students. *Clin Anat* 24:489–497.

Klement BJ, Paulsen DF, Wineski LE. 2011. Anatomy as the backbone of an integrated first year medical curriculum: Design and implementation. *Anat Sci Educ* 4:157–169.

Kulasegaram KM, Martimianakis MA, Mylopoulos M, Whitehead CR, Woods NN. 2013. Cognition before curriculum: Rethinking the integration of basic science and clinical learning. *Acad Med* 88:1578–1585.

Larkin TA, McAndrew DJ. 2013. Factors influencing students' decisions to participate in a short "dissection experience" within a systemic anatomy course. *Anat Sci Educ* 6:225–231.

Lei QF, Marks SC Jr, Touliopoulos P, Raptopoulos V. 1990. Fascial planes and compartments of the posterior abdomen: The perirenal and pararenal pathways. *Clin Anat* 3:1–15.

Monkhouse WS, Farrell TB. 1999. Tomorrow's doctors: Today's mistakes? *Clin Anat* 12:131–134.

Moqattash S, Harris PF, Gumaa KA, Abu-Hijleh MF. 1995. Assessment of basic medical sciences in an integrated systems-based curriculum. *Clin Anat* 8:139–147.

Novick AC. 1980. Posterior surgical approach to the kidney and ureter. *J Urol* 124:192–195.

Older J. 2004. Anatomy: A must for teaching the next generation. *Surgeon* 2:79–90.

Pabst R. 2009. Anatomy curriculum for medical students: What can be learned for future curricula from evaluations and questionnaires completed by students, anatomists and clinicians in different countries? *Ann Anat* 191:541–546.

Raftery AT. 2006. Anatomy teaching in the UK. *Surgery* 25:1–2.

Reeves RE, Aschenbrenner JE, Wordinger RJ, Roque RS, Sheedlo HJ. 2004. Improved dissection efficiency in the human gross anatomy laboratory by the integration of computers and modern technology. *Clin Anat* 17:337–344.

Smith CF, McManus B. 2015. The integrated anatomy practical paper: A robust assessment method for anatomy education today. *Anat Sci Educ* 8:63–73.

Sugand K, Abrahams P, Khurana A. 2010. The anatomy of anatomy: A review for its modernization. *Anat Sci Educ* 3:83–93.

Tank PW. 2013. *Grant's Dissector*. 15th Ed. Baltimore, MD: Lippincott, Williams & Wilkins. 288 p.

Van der Veken J, Valcke M, De Maeseneer J, Schuwirth L, Derese A. 2009. Impact on knowledge acquisition of the transition from a conventional to an integrated contextual medical curriculum. *Med Educ* 43:704–713.

Appendix 1. List of structures seen in posterior approach to kidney dissection.

Abdominal Wall

Fatty (superficial) layer of subcutaneous fascia
(Camper's fascia)

Membranous (deep) layer of subcutaneous fascia
(Scarpa's fascia)

Investing abdominal fascia

Transversalis fascia

Thoracolumbar fascia

 Anterior layer (quadratus lumborum fascia)

 Middle layer

 Posterior layer

Pararenal fat body

Renal fascia (Gerota's)

Perirenal fat capsule

Parietal peritoneum

 Retroperitoneal space

Muscles:

External oblique

Internal oblique

Transversus abdominis

Latissimus dorsi

Serratus posterior inferior

Iliocostalis

Longissimus

Spinalis

Semispinalis

Multifidus

Rotatores

Quadratus lumborum

Psoas major

Bone & ligaments:

Vertebral column

Lumbar vertebrae

 Vertebral body

 Transverse process

 Spinous process

Ilium

 Iliac crest

 Iliolumbar ligament

Ribs

 Rib XI & XII

 Costal groove

Peripheral Nerves:

Intercostal nerves (T11-T10)

Subcostal nerve (T12)

Ilio-inguinal nerve (L1)

Iliohypogastric nerve (L1)

Genitofemoral nerve (L1-L2)

Lateral femoral cutaneous nerve (L2-L3)

Superior mesenteric plexus

Greater / lesser / least splanchnic nerves

Sympathetic trunk

Anterior / Posterior vagal trunks

Aorticorenal ganglia

Renal plexus

Vasculature:

Abdominal aorta

Posterior intercostal arteries & veins

Lumbar arteries & veins

Hemi- / azygos veins

Renal arteries & veins

Renal Segmental arteries

Superior segmental artery

Anterior superior segmental artery

Anterior inferior segmental artery

Inferior segmental artery

Posterior segmental artery

Suprarenal arteries & veins

Left testicular / ovarian veins

Superior mesenteric artery

Kidney

Superior / inferior pole

Renal hilum

Renal sinus

Renal fibrous capsule

Renal cortex

Renal medulla

Renal pyramids

Renal columns

Renal papillary duct openings

Minor calyces

Major calyx
(superior/middle/inferior)

Renal pelvis

Ureter (abdominal part)

Adrenal Gland

Adrenal cortex

Adrenal medulla

Other structures

Spleen

Hilum

Visceral surface

Splenorenal ligament

Liver

Visceral surface

Diaphragm

Costal part

Lumbar part

Left & right crus

Lateral arcuate ligament

Medial arcuate ligament

Subphrenic space

Morrison's hepatorenal recess

Lumbar (pre-aortic / lateral aortic) lymph nodes

Superior mesenteric lymph nodes

Cisterna chyli