


Accepted Manuscript

Outcomes of microsurgical clipping of recurrent aneurysms after endovascular coiling

Anan Shtaya, MD, MRCS, PhD, Debayan Dasgupta, MB BS, John Millar, FRCR,
Owen Sparrow, FRCS, Diederik Bulters, FRCS (SN), Jonathan Duffill, FRCS (SN)



PII: S1878-8750(18)30120-7

DOI: [10.1016/j.wneu.2018.01.077](https://doi.org/10.1016/j.wneu.2018.01.077)

Reference: WNEU 7275

To appear in: *World Neurosurgery*

Received Date: 28 November 2017

Revised Date: 9 January 2018

Accepted Date: 11 January 2018

Please cite this article as: Shtaya A, Dasgupta D, Millar J, Sparrow O, Bulters D, Duffill J, Outcomes of microsurgical clipping of recurrent aneurysms after endovascular coiling, *World Neurosurgery* (2018), doi: 10.1016/j.wneu.2018.01.077.

This is a PDF file of an unedited manuscript that has been accepted for publication. As a service to our customers we are providing this early version of the manuscript. The manuscript will undergo copyediting, typesetting, and review of the resulting proof before it is published in its final form. Please note that during the production process errors may be discovered which could affect the content, and all legal disclaimers that apply to the journal pertain.

Outcomes of microsurgical clipping of recurrent aneurysms after endovascular coiling

Anan Shtaya MD, MRCS, PhD^{1,2*}, Debayan Dasgupta MB BS^{1*}, John Millar FRCR¹, Owen Sparrow FRCS¹, Diederik Bulters FRCS (SN)¹ and Jonathan Duffill FRCS (SN)¹

¹Wessex Neurological Centre, University Hospital Southampton, Southampton, UK.

²Neurosciences Research Centre, St George's University of London, London, UK.

*Shared first authorship.

Post publication corresponding author:

Diederik Bulters

Wessex Neurological Centre

University Hospital Southampton,

Southampton, SO166YD, UK.

dbulters@nhs.net

Key words: Intracranial aneurysm/surgery, Residual and Recurrent Aneurysms, Cerebral Revascularisation/adverse effects, microsurgery/adverse effects, Treatment Outcome.

Running head (3-5 words): Clipping of recurrent coiled aneurysms

Author Disclosures:

Authors reports no disclosures or conflict of interest.

Funding: This study was completed with no dedicated funds.

Abstract

Object: The outcomes of microsurgery of previously coiled aneurysms are poorly described and little is known about what factors predict poor outcome. Therefore, we set out studying our case series to identify predictors of poor outcome following microsurgery for previously coiled recurrent aneurysms.

Methods: A retrospective cohort study from a prospectively maintained vascular database reviewing presentations, recurrent aneurysms measurements, surgery and outcomes of microsurgical clipping of recurrent previously coiled intracranial aneurysms.

Results: 39 patients (mean age 49 years, range 22-70 years) underwent microsurgical clipping of 40 previously coiled intracranial aneurysms. One patient suffered seizures, one transient neurological worsening and one hyponatraemia, none of whom had long-term sequelae. Two patients suffered postoperative infarcts giving an overall incidence of permanent morbidity of 5.1%. There were no deaths or rebleeds on follow up.

In three patients, an attempt was made to remove the coil ball. These included the two patients with infarct and one with transient deficit. These patients had larger aneurysms (1106mm^3 vs 135mm^3 , $p=0.005$), with larger coil balls (257mm^3 vs 52mm^3 , $p=0.01$) and wider necks (7.09mm vs 2.69mm , $p=0.02$) but smaller remnant heights (1.59mm vs 1.99mm , $p=0.04$). They were also more likely to have prolapsing coil loops ($3/3$ vs $3/27$, $p=0.016$).

Conclusions: Our study demonstrates good clinical outcomes from microsurgical clipping of recurrent aneurysms. In the vast majority of cases, clips can be applied primarily. Coil ball removal was associated with increased morbidity and should only be considered as a second line option and its likely need identified before surgery.

Introduction

Endovascular treatment is increasingly used for both ruptured and unruptured cerebral aneurysms, particularly following the International Subarachnoid Aneurysm Trial (ISAT). However, long term follow up of endovascularly treated aneurysms is known to reveal recurrence of aneurysms in up to 20%.¹ In the ISAT² trial 17.4% of patients who were treated with coiling required further procedures due to recurrence or incomplete occlusion of the aneurysms. The 10-year follow up of the ISAT cohort has revealed that the risk of aneurysmal re-bleeding, although low, is still higher than those treated with surgical clipping³. The CARAT⁴ study has demonstrated a re-rupture rate of up to 17.6% during a mean follow up of 4 years when coiling is suboptimal and less than 70% of the aneurysm was

occluded. It therefore remains essential to monitor for aneurysm recurrence and have a strategy for treatment.

Two obvious questions remain; when, and how to intervene. In relation to the indication for intervention, it has been shown that growing aneurysm recurrence, rather than coil compaction, carries higher risk of re-rupture – this must be considered when deciding on further treatment of recurrent aneurysms⁵⁻⁷. Similarly, size of the patent portion of the aneurysm is important. Both of these may influence the outcomes of any treatment offered.

Re-treatment of aneurysms can be either endovascular or microsurgical. The indications for surgery vary widely based on experience and expertise, and are likely to be tailored to individual aneurysm anatomy. Surgery for these cases has been reported to be more challenging than surgery of previously untreated aneurysms^{8,9,10,11}. However, series reporting outcome remain limited to date and there has been no systematic analysis of predictors of poor outcome.

Our aim was therefore to assess clinical outcomes following microsurgical clipping of recurrent previously coiled aneurysms, and assess which preoperative and intraoperative factors may predict poor outcome to help improve patient selection.

Patients and methods

This retrospective cohort study is registered as an audit with our institutional approval. Patients undergoing surgery following previous endovascular treatment of an aneurysm between November 2006 and January 2013 were identified from our prospective neurovascular database. Case notes, electronic documents, cerebral angiograms, neuroradiology reports, and clinical outcomes were retrospectively reviewed. Aneurysm recurrences were identified following initial coiling on follow up cerebral catheter angiograms and/or magnetic resonance angiograms (MRAs). We discussed all recurrent cases at our Neurovascular multi-disciplinary meeting (MDT) to consider treatment options.

The decision to proceed with surgery was categorised into two groups:

- a) Endovascular treatment believed to result in suboptimal occlusion.
- b) Patient preference for surgery (despite reasonable chance of endovascular occlusion).

For this classification, endovascular treatment consists of direct coiling or balloon assisted coiling. We would normally recommend surgery if stent placement was anticipated for anterior circulation aneurysms. There were no posterior circulation aneurysms in this series in view of our more aggressive endovascular management in these locations utilising stenting. Initial catheter angiogram outcomes were categorised by interventional neuroradiologists as complete occlusion, incomplete occlusion, persistent interstitial filling and aneurysm neck

remnant. Mechanism of recurrence was classified into four categories: coil compaction, neck recurrences, aneurysmal regrowth, and recurrence due to a combination of these based on the angiogram reports.

All intraoperative or postoperative complications were reviewed. All patients were followed up in clinic at 3 months after surgery and as clinically indicated thereafter. The mean available follow-up time after clipping was 36 months (range 3–60 months). Outcome was assessed on the Modified Rankin Scale. This was dichotomised to good outcome (mRS 0–2) or poor outcome (mRS 3–6) and was assessed before surgery and at three-month follow-up.

The post-coiling, pre-clipping Digital Subtraction Angiograms (DSAs) and Magnetic Resonance Angiograms (MRAs) demonstrating the recurrences were retrieved and systematically analysed, in order to attempt to establish whether any features of the recurrent aneurysms were predictors of whether intra-operative coil removal prior to clipping would be required, and of poor outcomes following clipping.

Seven measurements of the recurrent aneurysms were taken (Figure 1):

1-3 Maximum diameter of the aneurysm in the x, y, and z planes orientated to the configuration of the aneurysm.

4-5 Minimum and maximum remnant height on either side of the neck of the aneurysm (h_1 & h_2).

6 Width of the neck of the aneurysm.

7 Maximum parent vessel diameter.

We additionally recorded a) whether there were coil loops present outside the main coil ball in the remnant, and b) whether these prolapsed across the neck of the aneurysm.

The aneurysms were modelled onto the shape of a cylinder, and using the x,y,z measurements, this allowed modelling to derive the height of the assumed cylindrical aneurysm, the diameter and therefore the radius. This was used to derive the volume of the aneurysm, using the equation $V=\pi r^2 h$.

The volume of the remnant was then derived by using the formula for a volume of a cylindrical segment:

$V = 0.5 \pi r^2 (h_1+h_2)$ ¹⁰. These volumes allowed us to derive an estimated coil ball volume, by subtracting the remnant volume from the total aneurysmal volume.

Measurements were reviewed by a consultant vascular neurosurgeon (DB) and a consultant interventional neuroradiologist (JM), and then correlated with the clinical outcome using the dichotomised Modified Rankin Scale. Statistical analysis was performed using Mann Whitney and Chi square tests as appropriate, p value <0.05 was considered significant.

Results

Population

39 patients underwent microsurgical clipping of recurrent cerebral aneurysms after previous endovascular coiling between November 2006 and January 2013. 20 were females and 19 were males (Table 1). The mean age was 49 (range, 22–70) years (Table 1). The mean interval between coiling and clipping was 76 weeks (range 4-374).

Aneurysms involved the anterior communicating artery (ACOM) in 15 cases, middle cerebral artery (MCA) in 12 cases, internal carotid artery (ICA) in 2 cases, posterior communicating artery (PCOM) in 9 cases and anterior cerebral artery (ACA) in 2 cases. 7 patients had one additional unruptured aneurysm (Table 1). In 3 patients, 2 additional aneurysms were diagnosed. All additional aneurysms were within the anterior circulation. The mean aneurysm diameter before endovascular treatment and after the initial rupture was 5.3 mm (range 1.9–14mm) (Table 1). All patients initially presented with ruptured aneurysms. World Federation of Neurosurgical Societies (WFNS) grade at initial presentation was grade I in 23 patients (59%), grade II in 8 patients (20.5%) and grades III and IV in 3 patients each (Table 1). 2 patients had their initial treatment at another centre, hence initial WFNS grade was unavailable.

The angiographic outcomes of the initial coiling procedure were described as follows: 21 cases were classed as having an aneurysm neck remnant¹², 9 as persistent interstitial filling, 8 as incomplete occlusion and 2 patients as complete occlusion. Raymond-Roy occlusion classification after initial embolisation is presented in Table 1. Data was not available for 2 patients who had undergone endovascular coiling at other centres. The mechanisms of recurrence were thought to be coil compaction in 22 aneurysms, neck recurrence in 12 cases, of which aneurysmal regrowth was noted in 7 aneurysms, and a combination of these mechanisms was noted in 6 aneurysms. None of these suffered a rebleed. However, the MDT recommended preventative treatment of the residual aneurysm due to changing appearances of the remnant deemed at risk of further rupture.

The MDT recommendation was for surgical clipping in 21 patients as endovascular treatment was thought likely to result in suboptimal occlusion. In recurrent anterior circulation aneurysms unsuitable for endovascular treatment, our MDT usually opt for surgery rather than stent assisted coiling. We believe surgery would result in less complication than reported in literature with stent assisted coiling^{13, 14}. The other 18 patients were deemed suitable for either surgical or endovascular treatment but patients opted for surgery.

Outcomes

38 patients had a good mRS of 0-2 pre operatively. 37 were graded either 0 or 1, the remaining two patients had sustained a previous left middle cerebral artery (MCA) territory infarction, one with residual mild right sided weakness with an mRS of 2, and the other had a residual dysphasia and right-sided weakness, with an mRS of 3.

All 39 patients had their previously coiled aneurysm clipped. In three cases an attempt was made to remove the coil ball – in two cases the sac was opened to remove the entire coil ball and in one the dome and coil ball was amputated to increase the working space without entering the patent portion of the aneurysm. These three patients were all in the group of 21 patients whom had been considered unsuitable for endovascular treatment. 10 patients had additional anterior circulation aneurysms clipped during the same operation. The mean length of hospital stay was 3.2 days (range 1-13 days).

Post-operatively 2 patients suffered an infarct and crossed from good outcome to poor outcome with an mRS of 3 and 4. These two cases encompass important learning points and will be discussed separately. One patient developed seizures post-operatively and another had transient hyponatremia. Both were treated with no long-term sequelae. All other patients were unchanged giving an incidence of permanent morbidity of 5.1%. There were no haemorrhages or deaths during a mean follow up of 36 months (range 3-60 months).

Surgical Technique

All recurrent aneurysms in this series were in the anterior circulation. Microsurgical clipping was performed through a standard pterional approach. Generally, the aneurysm and both its proximal and distal arterial segments were microsurgically exposed (Figure 2). Temporary clipping of the parent vessel was used if deemed necessary. A permanent clip was then placed across the neck of the aneurysm. The base of the aneurysm was visualised to ensure optimal occlusion of the aneurysm without sliding of the clip or narrowing of the parent artery (Figure 3). Earlier in the series, Doppler ultrasound was used to evaluate the intraluminal blood flow before and after applying the clip. This was used in 24 cases. Later in the series, intraoperative isocyanine-green (ICG) angiography was used to evaluate the extent of intraluminal blood flow at the neck of the aneurysm. This was used in 8 patients. 7 cases were clipped without intraoperative check of the blood flow. This was earlier in the series when a Doppler probe was not available and prior to the adoption of ICG angiography. None of these seven patients suffered a complication.

The first line approach was to place a clip below the coil ball without removal of coils. This was possible in 36 cases. In 3 cases, insufficient aneurysmal neck was seen, and the surgeon had to open the aneurysm dome to remove the coil ball in order to apply the clip. Successful

clipping of the aneurysm was verified when there was no bleeding from the clipped aneurysm on aspiration with a fine needle.

Case 1

64-year-old male, with WFNS grade 1 SAH due to a ruptured left 14mm anterior communicating artery aneurysm (ACOM). Initial results revealed some residual filling at the neck of the aneurysm; however, the body and dome of the aneurysm were well occluded. Follow up cerebral angiogram revealed significant coil compaction and enlargement of the neck remnant (Figure 4). This was re-coiled. The results were not satisfactory and it was decided to proceed with microsurgical clipping. The patient had a right pterional craniotomy and a clip was placed across the neck of the aneurysm. Intraoperative Doppler was used to assess blood flow and a reduction in blood flow in A1/A2 on the left side was noted. The aneurysm wall was atheromatous. The aneurysm was transected, the coil ball was cut, and coils were removed, allowing space to apply the clip, achieving an apparently good position. However, optimal blood flow was not restored fully as evaluated with intraoperative Doppler and unfortunately, the patient developed right-sided upper and lower limb weakness with left anterior cerebral artery (ACA) territory infarction demonstrated on CT scan. The patient stayed under neurosurgical care for 9 days before being transferred to his local hospital for further rehabilitation. He was last seen 7 months later when his mRS was 3. His weakness at this time was persistent, with some improvement in his right upper limb, but no improvement in weakness in right lower limb.

Case 2

44-year-old female who presented with a WFNS grade II SAH. She was found to have a 6 mm ruptured right MCA bifurcation aneurysm treated with endovascular coiling. Immediate post coiling images demonstrated a small neck remnant. She recovered well, became pregnant and had a baby, and as a result, her follow up MRA was delayed to just over one year rather than our usual policy of 6 months. The follow up MRA revealed coil compaction, which was confirmed on cerebral angiogram to be due to an enlarging neck remnant (Figure 5). The case was discussed at the Neurovascular MDT and was felt that this case was not optimal for re-coiling, and proceeded to surgery. Intraoperative Doppler ultrasound was used to assess blood flow through the MCA and its main branches. The aneurysm neck was not optimal for the application of a clip. Despite trying different clips no acceptable configuration could be found. It was therefore decided to cut the coil ball and the atheromatous aneurysm was transected. The clip was positioned and flow was satisfactory. However, the patient woke up with severe left sided face, upper, and lower limb weakness. She was taken back to

theatre. The clip and flow were checked with no change in Doppler flow. Patient stayed under neurosurgical care for 13 days before transfer to her local hospital for further rehabilitation. She was last seen 6 months later when her mRS was 3. Her lower limb weakness at this time had significantly improved and was mobilising with the aid of a walking stick, but had ongoing weakness in her left arm, and some residual left-sided facial weakness.

Case 3

69-year-old female patient who presented with a SAH due to a ruptured left MCA aneurysm treated with endovascular coiling. Immediate post-coiling images and follow-up cerebral angiogram demonstrated persistent filling of the aneurysm and incomplete coiling (Figure 6). Following the haemorrhage and coiling, the patient had a residual expressive dysphasia but no motor weakness, and an mRS of 3.

The case was discussed at the neurovascular MDT, and the decision was made given the unsatisfactory outcome of the coiling to proceed with microsurgical clipping. Despite attempting multiple configurations of different sized clips, intraoperative ICG angiography demonstrated poor filling in one of the downstream branches of the MCA. The view was hampered the coil ball, and so the aneurysm dome and coils were transected and so the distal aneurysm fundus was removed leaving the patent portion and proximal coil ball intact such that the neck of the aneurysm could be more easily visualised. 2 clips were then applied across the neck of the aneurysm, and ICG angiography demonstrated good flow at this point. However, the patient awoke with a worsening of her expressive dysphasia, and a new right sided weakness post-operatively. This was a transient weakness that fully resolved with the patient returning to baseline by three-month follow up. Its cause was ascribed to prolonged intraoperative temporary occlusion time of the proximal MCA, but given that the coil ball removal was partial, the remaining coils precluded a good quality CT scan image, and we cannot rule out an infarct. The patient was last seen 12 months following the operation, when her mRS remained 3 due to the expressive dysphasia which persists following clipping.

Aneurysm Characteristics

As discussed above, of the 39 patients, two required coil ball removal and crossed from an mRS of 0-2 to a bad outcome (mRS 3-4) at three-month follow up, and a third patient who also had a dome resection and partial coil ball removal pre-operatively had an mRS of 3 who deteriorated neurological post clipping but returned to the same pre-clipping mRS of 3 at the three-month follow up mark.

Scans were available for 30 of these patients, including the three who had attempts at surgical coil removal. The remaining scans were no longer retrievable. The aneurysm measurements and characteristics are summarised in table 2.

Our results suggest that the aneurysm volume, the remnant volume, the coil ball volume and the aneurysm neck width are significantly larger in the group that needed the coil ball removal when compared to the group that did not require coil ball removal and correlated with poor outcome. However, although there was a clear association, there was no threshold that could be identified that reliably predicted the need for coil ball removal.

We also observed that prolapsing coil loops on DSA prior to operation was associated with poor outcome ($P = 0.016$, Chi square 5.8). Of the three cases with poor outcomes, two had coil loops in the neck of the aneurysm, as opposed to only 3 of the 27 with good outcomes ($P = 0.25$, Chi square 1.3).

Discussion

In this series, we observed a 5.1% transient and further 5.1% permanent complication rate following surgical treatment of recurrent previously coiled ruptured aneurysms. The two patients who suffered permanent sequelae crossed over from good outcome to poor outcome after microsurgical clipping. Although these cases are disappointing, this is less frequent than has been reported in literature^{9-11, 15}. There could be many reasons for this, relating to either patient selection or surgical technique.

Dorfer et al reported morbidity of 15.6% in their surgical group¹¹. In this study, combined endovascular and surgical case series of 52 patients were treated surgically. This included parent artery occlusion or trapping under bypass protection in 5 cases, deliberate clipping of the basilar artery trunk in 2 cases, and aneurysm wrapping in one case. In another study of 43 patients 33 aneurysms were clipped directly, 7 unclippable aneurysms were bypassed, and 3 were wrapped¹⁶. They reported 7% mortality and 9 % of poor outcome. Furthermore, Nakamura et al reported 33% of poor outcomes in their series and had 6.7% mortality rate¹⁵. In this study we note that all recurrent aneurysms were in the anterior circulation. However, in 67% of cases coils were partially or completely removed. This may suggest a strong correlation between coil removal and increase in morbidity, which was also highlighted by Romani et al⁸. In the latter Finnish study, a review was conducted on 81 patients who had 82 previously coiled aneurysms that recurred. 15 patients were operated on within 1 month of coiling and the rest had their surgery at later stage. 29% of the aneurysms were posterior circulation. 14 patients had incidental unruptured aneurysms. The coil ball was partially or completely removed in 35% of patients. They reported 12% poor outcomes which included

7% mortality. Furthermore, Zhang et al reported their experience of surgical clipping of 38 cases. They reported 8% mortality and about 87% good outcome. However, we note that their series included 14 posterior circulation recurrent aneurysms. Their surgical approach included bypass, aneurysm trapping and in 9 cases coil extraction was performed.

Although the values differ, these papers are consistent with our data. We report lower than average complication rates. This may be due to a number of factors. It is notable that we only treated anterior circulation aneurysms. This is due to aggressive endovascular treatment of posterior circulation recurrences due to our perception of increased risk of surgery for these patients as seen in other series. In agreement with our results, there has been a report of clipping 10 anterior circulation recurrent aneurysms with good outcome⁹. We did not clip any recurrences early after coiling and SAH as in some series. Most importantly, we believe that avoiding removal of the coil ball should be the surgical objective. There are many factors to this. Fortunately, it is our experience that with careful intraoperative assessment and consideration of different clip strategies, it is more frequently possible than might be expected; the actual frequency may be related to surgical technique or different clip models and width of blades (all clips in this series Yasargil clips, manufactured by Aesculap and supplied by B. Braun Medical Ltd, UK) but in practice most well selected cases should accept direct clipping.

Our experience was similar to the Helsinki group that removal of coils is more difficult to perform and associated with poorer outcomes.⁸ We have therefore attempted to identify factors that predict need for coil removal and thus poor outcome. From this, it is apparent that increasing coil ball size and aneurysm remnant size are significant factors. We also observed that a wider neck width of the aneurysm appears to be a significant factor in predicting the need for coil removal and poor outcome. In addition, cases that required coil removal had a smaller remnant height and greater neck width. We also noted a non significant trend for smaller parent vessel size in cases that required coil removal, presumably, as just slight impingement on the parent vessel is more likely to lead to occlusion. Prolapsing coil loops was also a strong predictor of poor outcome.

Unfortunately no thresholds could be identified which could definitively predict the need for coil ball removal and these features can only contribute to, but not define, the complex decision as to suitability for surgery. This may be a fundamental feature of the surgical problem. However, as at the time of the surgery the magnitude of the risks of coil removal were not necessarily appreciated, it is also possible that in light of the available evidence greater attempts at avoiding surgical removal of coils could have resulted in some cases

proceeding with simple clipping without complication. In any event given the very poor results in this subgroup it would appear that if faced by the unanticipated need to remove coils intra-operatively, that surgeons would need to have to consider whether changing strategy to stent coiling would be safer.

It is notable that only 2 patients in this series had undergone a second coiling procedure before clipping, indeed Case 1 (discussed above) was one of these. Recurrent coiling will increase the size of the coil ball and reduce the flexibility of the aneurysm neck increasing the complexity of later surgical treatment when it may be better treated surgically at first recurrence. Therefore, while endovascular coiling may be the first line approach following SAH, this decision making is more complex for recurrent aneurysms. In our experience, the threshold for performing surgery rather than endovascular coiling should be lower in recurrent aneurysms. However, in cases where aneurysms are in the posterior circulation or it is anticipated that the coil ball will need to be removed, the additional risks of microsurgery may be greater than those associated with the more aggressive endovascular approaches necessary to achieve satisfactory stable obliteration of the aneurysm.

Conclusion

Our result of surgical treatment following endovascular coiling of recurrent cerebral aneurysms suggests that microsurgical treatment in the anterior circulation is safe and effective. It suggests that more have a neck amenable to direct surgical clipping than may be expected, and that clipping with coil removal has worse outcomes than simple clipping. It also suggests that while a lower threshold for surgery may be appropriate for aneurysm recurrence, this threshold should be raised for recurrent posterior circulation aneurysms or those where coil removal is likely to be needed. This may be anticipated in larger aneurysms arising from narrower parent vessels with larger coil balls, smaller remnant heights, smaller coil to remnant ratios and prolapsing coil loops.

Conflict of interest

The authors declare that they have no competing interests.

References

1. Petr O, Brinjikji W, Thome C, *et al.* Safety and efficacy of microsurgical treatment of previously coiled aneurysms: a systematic review and meta-analysis *Acta Neurochir (Wien)* 2015: 157; 1623-1632
2. Molyneux A, Kerr R, Stratton I, *et al.* International Subarachnoid Aneurysm Trial (ISAT) of neurosurgical clipping versus endovascular coiling in 2143 patients with ruptured intracranial aneurysms: a randomised trial *Lancet* 2002: 360; 1267-1274

3. Molyneux AJ, Birks J, Clarke A, *et al.* The durability of endovascular coiling versus neurosurgical clipping of ruptured cerebral aneurysms: 18 year follow-up of the UK cohort of the International Subarachnoid Aneurysm Trial (ISAT) *Lancet* 2015: 385; 691-697
4. Investigators C Rates of delayed rebleeding from intracranial aneurysms are low after surgical and endovascular treatment *Stroke* 2006: 37; 1437-1442
5. Dorfer C, Standhardt H, Gruber A, *et al.* Direct percutaneous puncture approach versus surgical cutdown technique for intracranial neuroendovascular procedures: technical aspects *World Neurosurg* 2012: 77; 192-200
6. Sluzewski M, van Rooij WJ, Beute GN, *et al.* Late rebleeding of ruptured intracranial aneurysms treated with detachable coils *AJNR Am J Neuroradiol* 2005: 26; 2542-2549
7. Ringer AJ, Rodriguez-Mercado R, Veznedaroglu E, *et al.* Defining the risk of retreatment for aneurysm recurrence or residual after initial treatment by endovascular coiling: a multicenter study *Neurosurgery* 2009: 65; 311-315; discussion 315
8. Romani R, Lehto H, Laakso A, *et al.* Microsurgical technique for previously coiled aneurysms *J Neurosurg Sci* 2011: 55; 139-150
9. Konig RW, Kretschmer T, Antoniadis G, *et al.* Neurosurgical management of previously coiled recurrent intracranial aneurysms *Zentralbl Neurochir* 2007: 68; 8-13
10. Zhang YJ, Barrow DL, Cawley CM, *et al.* Neurosurgical management of intracranial aneurysms previously treated with endovascular therapy *Neurosurgery* 2003: 52; 283-293; discussion 293-285
11. Dorfer C, Gruber A, Standhardt H, *et al.* Management of residual and recurrent aneurysms after initial endovascular treatment *Neurosurgery* 2012: 70; 537-553; discussion 553-534
12. Mascitelli JR, Moyle H, Oermann EK, *et al.* An update to the Raymond-Roy Occlusion Classification of intracranial aneurysms treated with coil embolization *J Neurointerv Surg* 2015: 7; 496-502
13. Muller M, Brockmann C, Afat S, *et al.* Temporary Stent-Assisted Coil Embolization as a Treatment Option for Wide-Neck Aneurysms *AJNR Am J Neuroradiol* 2017: 38; 1372-1376
14. Cheung NK, Chiu AH, Cheung AK, *et al.* Long-term follow-up of aneurysms treated electively with woven stent-assisted coiling *J Neurointerv Surg* 2017
15. Nakamura M, Montibeller GR, Gotz F, *et al.* Microsurgical clipping of previously coiled intracranial aneurysms *Clin Neurol Neurosurg* 2013: 115; 1343-1349
16. Waldron JS, Halbach VV, Lawton MT Microsurgical management of incompletely coiled and recurrent aneurysms: trends, techniques, and observations on coil extrusion *Neurosurgery* 2009: 64; 301-315; discussion 315-307

Figure legends

Figure 1: Aneurysms measurements. The figure demonstrates the maximum diameter of the aneurysm in the x, y, and z planes orientated to the configuration of the aneurysm. The minimum and maximum remnant height on either side of the neck of the aneurysm (h1 & h2). The width of the neck of the aneurysm and the maximum parent vessel diameter.

Figure 2: Illustrative surgical view of a previously coiled MCA aneurysm of one of the selected patients. M1= Segment 1 of the middle cerebral artery. M2= Segment 2 of the middle cerebral artery.

Figure 3: Post clipping view demonstrating that despite relatively small remnant sufficient space was available to accept a clip without compromising the parent vessels.

Figure 4: Cerebral angiogram demonstrating left anterior communicating artery aneurysm with coil compaction and enlarged neck remnant (arrow).

Figure 5: Cerebral angiogram demonstrating right MCA aneurysm with enlarged neck remnant (arrow).

Figure 6: Cerebral angiogram demonstrating left MCA aneurysm with aneurysm filling and incomplete coil occlusion (arrow).

Table 1: Characteristics of patients and aneurysms at initial presentation.

ACOM: anterior communicating artery, ICA: internal carotid artery, ACA: anterior cerebral artery, MCA: middle cerebral artery, PCOM: posterior communicating artery.

* 2 patients were coiled elsewhere and WFNS grade is not available. ** Data is available for 32 aneurysms. *** 2 patients were embolised elsewhere hence; no initial Raymond-Roy classification is available.

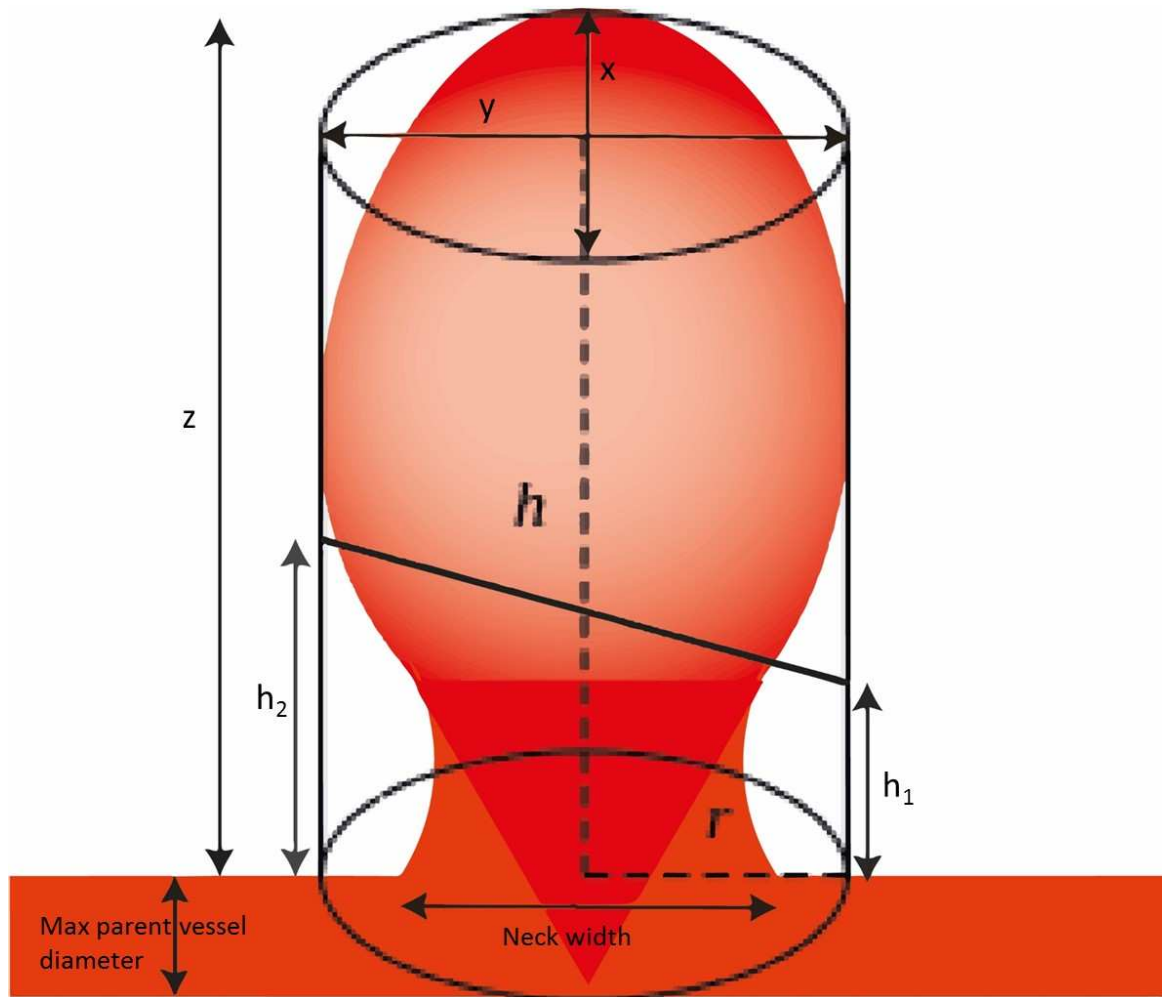
Table 2: Summary of the mean measurements and aneurysm characteristics calculated from DSAs of recurrent aneurysms prior to clipping. †: Chi square test was used. Mann Whitney test was applied for the rest of the table's statistics. $P < 0.05$ is considered significant.

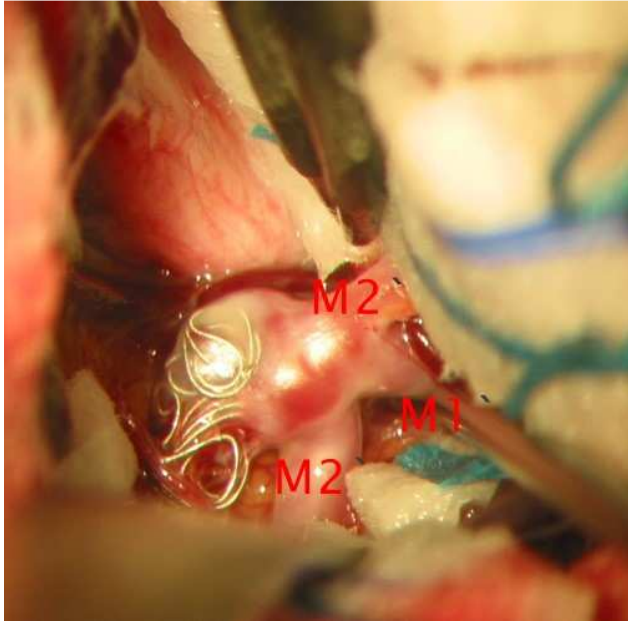
Table 1: Characteristics

Total patients (n)	39
Mean age (year, mean \pm SEM)	49.07 \pm 1.75
Male (n, year; mean \pm SEM)	19, 48.42 \pm 2.6
Female (n, year; mean \pm SEM)	20, 51.75 \pm 2.55
Presentation Ruptured/Unruptured (n, (%))	39 (100)
WFNS grade at presentation	
WFNS I (n, (%))	23 (59)
WFNS II (n, (%))	8 (20.5)
WFNS III (n, (%))	3 (7.7)
WFNS IV (n, (%))	3 (7.7)
WFNS V (n, (%))	0
N/A* (n, (%))	2 (5.1)
Aneurysm location (n)	40
ACOM (n)	15
ICA (n)	2
ACA (n)	2
MCA (n)	12
PCOM (n)	9
Aneurysm size at initial presentation (n) **	32
Mean \pm SEM (mm)	5.31 \pm 0.44
Size	
<7 mm (n)	24
7-12 mm (n)	7
13-24 mm	1
Raymond-Roy Occlusion Classification after initial embolisation	
Class I (n)	2
Class II (n)	19
Class III a (n)	9
Class III b (n)	8
N/A***	2

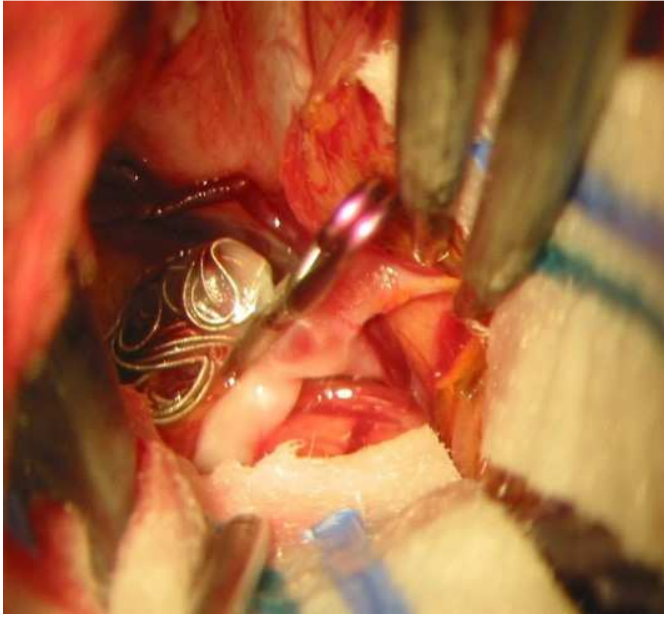
Table 2

	Coil removal needed (n=3)	No coil removal needed (n=27)	P value
Aneurysm Volume (mean)	1106 mm ³	135 mm ³	0.005
Remnant Volume (mean)	257 mm ³	52 mm ³	0.01
Coil ball Volume (mean)	848 mm ³	83 mm ³	0.003
Coil to Remnant ratio	3.26	1.74	0.06
Minimum remnant height (mean)	1.59 mm	1.99 mm	0.04
Neck Width (mean)	7.09 mm	2.69 mm	0.02
Maximum Parent Vessel Diameter (mean)	1.88 mm	2.43 mm	0.15
Number with Coil loops in remnant	3 (100%)	3 (11.1%)	0.016†
Number with Coil Loops across neck	2 (66.7%)	9 (33.3%)	0.25†

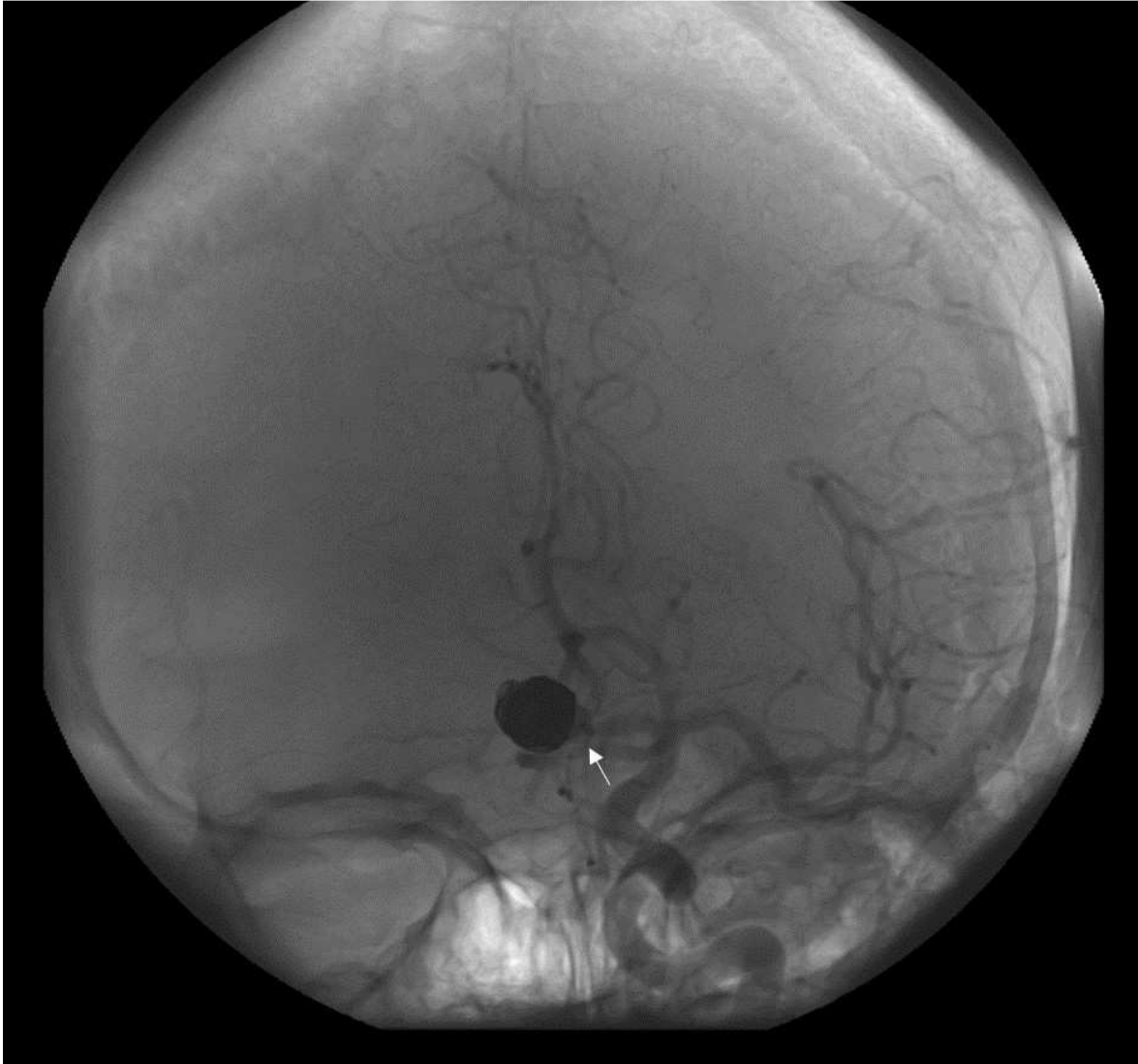




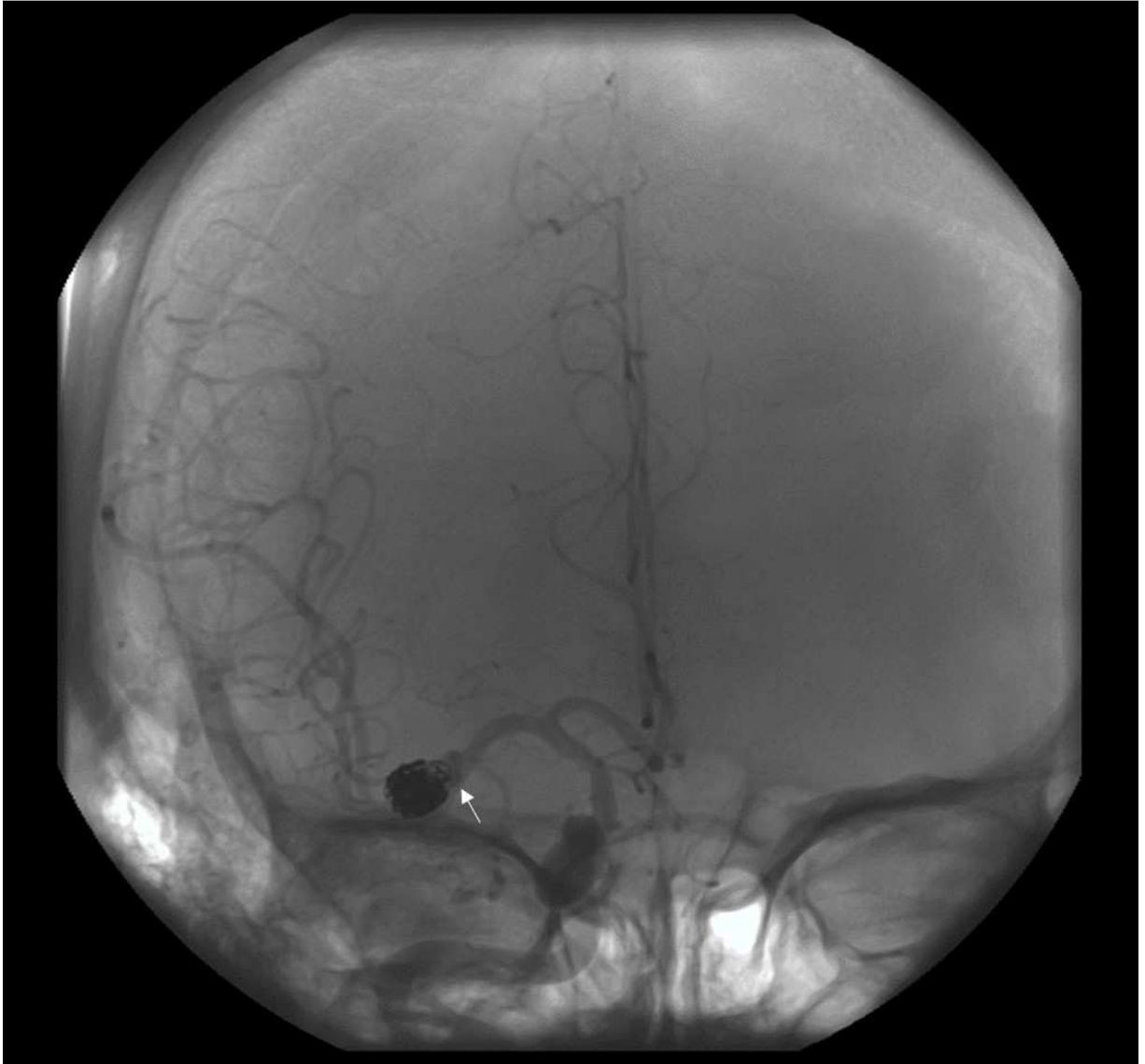
ACCEPTED MANUSCRIPT



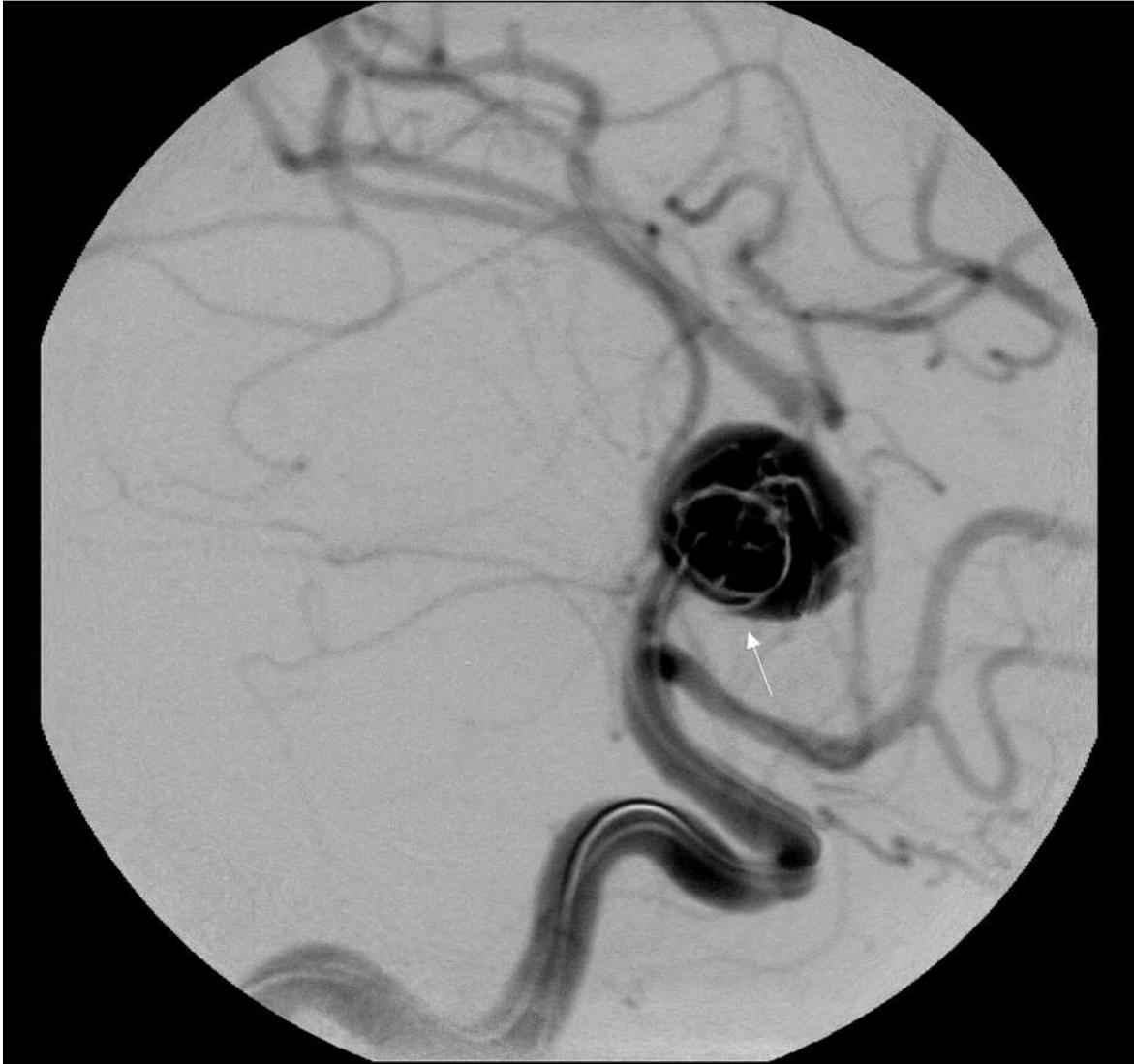ACCEPTED MANUSCRIPT



ACCEPTED



ACCEPTED



ACCEPTED

Highlights:

Manuscript title: Outcomes of microsurgical clipping of recurrent aneurysms after endovascular coiling

- Microsurgical clipping of previously coiled and recurred anterior circulation intracranial aneurysms series with good outcome (mRS 0-2) in 95%.
- Cutting and removal of coil balls was associated with neurological deficits.
- The patients who had coil ball cut had significantly larger aneurysms, with larger coil balls and wider necks but smaller remnant heights. They also had prolapsing coil loops.
- Coil ball removal should only be considered as a second line option and its likely need identified before surgery.

Abbreviation:

SAH: Subarachnoid haemorrhage.

ISAT: International Subarachnoid Aneurysm Trial.

MRI: Magnetic resonance imaging.

MRA: Magnetic resonance angiogram

MDT: Multi-disciplinary meeting

mRS: Modified Rankin scale.

ACOM: Anterior communicating artery.

MCA: Middle cerebral artery.

ICA: Internal carotid artery.

PCOM: Posterior communicating artery.

ACA: Anterior cerebral artery.

WFNS: World Federation of Neurosurgical Societies.

ICG: Isocyanine-green.

Conflict of interest

All authors have none to declare.

Author Disclosures:

Anan Shtaya- Reports no disclosures.

Debayan Dasgupta - Reports no disclosures.

John Millar - Reports no disclosures.

Owen Sparrow - Reports no disclosures.

Diederik Bulters- Reports no disclosures.

Jonathan Duffill- Reports no disclosures.

Funding

This case report was completed with lack of dedicated funding.