

# Thrombolysis in a Stroke Patient on Dabigatran Anticoagulation: Case Report and Synopsis of Published Cases

Waltraud Pfeilschifter<sup>a</sup> Mario Abruscato<sup>b</sup> Susanne Hövelmann<sup>c</sup>  
Horst Baas<sup>b</sup>

<sup>a</sup>Goethe University Hospital, Department of Neurology, Frankfurt am Main, and Departments of <sup>b</sup>Neurology and <sup>c</sup>Radiology, Klinikum Hanau, Hanau, Germany

## Key Words

Anticoagulation · Atrial fibrillation · Stroke · Thrombolysis · Fibrinolytic · Hemorrhage

## Abstract

We present the case of an aphasic 77-year-old stroke patient with left distal M1 occlusion who received rt-PA for thrombolysis while on oral anticoagulant treatment with dabigatran (150 mg b.i.d.). Coagulation parameters were normal (thrombin time 20 s, aPTT 20 s, INR 1.08) and the patient improved from an NIHSS of 15 to 5 within 24 h with sonographic evidence of M1 recanalization. She did not develop intracranial bleeding complications but showed unusually large diffuse skin ecchymoses. In our report, we give an overview of all reported cases of thrombolysis under dabigatran anticoagulation and discuss the questions of medication adherence under novel oral anticoagulants (NOA) and the safety of NOA in terms of secondary intracerebral hemorrhage after stroke.

## Introduction

For more than 50 years, treatment with vitamin K antagonists had been the only therapeutic option to prevent strokes and other embolic events in patients with atrial fibrillation (AF). In 2009, three large phase III trials of three novel oral anticoagulants, the direct thrombin inhibitor dabigatran and the factor Xa inhibitors rivaroxaban and apixaban, showed non-inferiority concerning efficacy and safety of these drugs in comparison to warfarin. While the individual phase III trials of each of the novel oral anticoagulants (NOA)

Dr. Waltraud Pfeilschifter  
Klinikum der Goethe Universität, Klinik für Neurologie  
Theodor-Stern-Kai 7  
DE-60590 Frankfurt am Main (Germany)  
E-Mail [w.pfeilschifter@med.uni-frankfurt.de](mailto:w.pfeilschifter@med.uni-frankfurt.de)

were not powered to detect a difference in stroke risk or mortality, a meta-analysis of these trials (RE-LY [1], ROCKET-AF [2] and ARISTOTLE [3]) demonstrated a significant decrease of stroke risk and mortality under NOA in comparison to warfarin [4]. The most important benefits of the novel drugs in comparison to warfarin are their predictable pharmacokinetic profiles which render regular coagulation tests unnecessary and less pronounced drug-drug and drug-food interactions. However, they are problematic in situations of medical emergency, where a rapid assessment of the coagulation status is mandatory because they are not readily detected by standard coagulation tests [5].

### Case Presentation

We report the case of a 77-year-old woman with arterial hypertension and paroxysmal AF, who had been started on dabigatran 5 months before. In a telephone conversation with her daughter on a Sunday morning, she reported that she was doing fine but had experienced palpitations two days earlier – and then suddenly fell silent. The immediately notified emergency medical services found a confused patient with global aphasia, brachiofacial paresis of the right side, and right hemineglect. The NIHSS upon admission fluctuated between 11 and 15 and CT scan showed early infarct signs in the left temporoparietal region, and a left hyperdense middle cerebral artery (MCA) sign (fig. 1a). CT angiography confirmed distal M1 occlusion (fig. 1b). The daughter, who reported that her mother independently and reliably took her medication, knew of a ‘blood pressure tablet’ and intermittent use of flecainide. She negated warfarin, ASA or any alternative blood thinner. Coagulation parameters were normal [thrombocytes 181/nl (140–440), INR 1.08 (<1.31), aPTT 20 (26–36), thrombin time 20 (14–21)], and the creatinine level was slightly elevated at 1.0 mg/ml (0.4–0.9 mg/dl). Coagulation assays were performed with Thromborel S<sup>®</sup> (INR), Pathrombin SL<sup>®</sup> (aPTT) and BC Thrombin Reagent<sup>®</sup> (thrombin time) on a BCS XP coagumeter (reagents and coagumeter from Siemens Healthcare Diagnostics, Marburg, Germany). The patient received 60 mg rt-PA 1.5 h after symptom onset and rapidly improved to an NIHSS of 7. Later, a list of the patient’s current medication appeared which documented the prescription of dabigatran. The family doctor later confirmed this and estimated the patient’s medication adherence as good. The patient continued to improve functionally to an NIHSS of 5 within the next hours and CT follow-up the next day revealed an infarct in the anterior part of the MCA territory (fig. 1c). There was no sign of hemorrhagic transformation on MRI (fig. 1d, e), but the patient developed extended superficial ecchymoses of the whole body (fig. 1f, g), which gradually resolved without sequelae over two weeks. Duplex sonography after thrombolysis showed regular blood flow in the left MCA and moderate carotid atherosclerosis without relevant stenoses. We detected sinus rhythm in two subsequent ECGs. Transthoracic echocardiography found no structural abnormalities of the heart. The patient was discharged to rehabilitative care on day 9 with an NIHSS of 4. Due to the large extent of the infarct, anticoagulation was not taken up during the initial hospitalization and the patient was discharged with ASA. We recommended the evaluation of tolerability and medication adherence during rehabilitation and to restart the patient accordingly on oral anticoagulation. At three months’ follow-up, the patient was living independently at home with her husband. She showed no motor or sensory deficits but severe motor aphasia with fairly good speech comprehension. Nevertheless, she was not able to coherently state her medication adherence prior to her stroke. Her anticoagulation regime had been changed to rivaroxaban.

## Discussion

This is another report of thrombolysis for stroke under oral anticoagulation with dabigatran without secondary intracerebral hemorrhage. For now, there are six case reports of thrombolysis in stroke under dabigatran treatment. In one additional case, the physicians abstained from thrombolysis because the last intake of 150 mg dabigatran was 2.5 h prior to stroke onset [6]. One patient with several risk factors for hemorrhagic transformation (diabetes mellitus with hyperglycemia upon presentation and a large perfusion deficit on CT) who received thrombolysis suffered a fatal secondary intracerebral hemorrhage after thrombolysis despite normal coagulation parameters [7]. Five other patients received rt-PA without intracranial hemorrhagic complications (table 1), but one patient also developed skin ecchymoses [8–12]. These cases indicate that thrombolysis might be safe if the aPTT is in the normal range, indicating that little dabigatran is present. Of course, general risk factors for thrombolysis-associated hemorrhage as hyperglycemia, severe strokes and large perfusion deficits or extensive early infarct signs have to be taken into consideration.

A stroke under anticoagulant therapy represents an ‘anticoagulation failure’. The most sensitive test to detect the presence of dabigatran is the thrombin time. In the case of our patient, the normal thrombin time clearly argues for the omission of at least one dose, because in the steady state a slight prolongation of the thrombin time should be expected even at trough level. Furthermore, the aPTT reagent used by our institution has been shown to be the most sensitive among three different commercially available aPTT reagents to detect dabigatran activity in a clinical trial of deep vein thrombosis prophylaxis after hip or knee surgery, still detecting a significant difference to trough concentrations at 12 h after 220 mg Pradaxa in a once daily dosing regime [13 and E. Lindhoff-Last, personal communication]. A normal aPTT measured with this reagent further supports that the patient has most probably missed at least one dose. So far, there has been very little information on medication adherence under NOA. Interestingly, there was a significantly greater discontinuation rate in both dabigatran arms in comparison to the warfarin arm (21% and 21% vs. 17% after 2 years,  $p < 0.001$ ) in the RE-LY trial [1]. The main reasons were ‘patient’s decision’ and ‘gastrointestinal symptoms’. It can be assumed that these factors weigh even more profoundly on medication adherence in daily clinical practice than in a carefully selected study population with regular follow-up. Under warfarin treatment with regular coagulation monitoring, patients and physicians receive a regular feedback on medication adherence. We should establish similar ‘check-ups’ under NOA treatment to assure medication adherence and evaluate comedications and undesired drug reactions.

Interestingly, all cases of stroke under dabigatran reported so far do not show relevant alterations of the aPTT (table 1), which is the second sensitive standard coagulation assay that is influenced by dabigatran. Inadequate dosing for stroke prevention or omission of at least one dose was reported in four of the seven cases [6, 7, 10, 11]. It would be very interesting to know the actual anticoagulant activity at the time of thrombolysis. Experimental studies in murine stroke models have shown that effective dabigatran anticoagulation with plasma levels up to 400 ng/ml does not lead to an increase in secondary intracerebral hemorrhage after rt-PA application [14] or to an increase of spontaneous HT in case of a continued [15] or early-initiated [16] anticoagulation after experimental stroke. Of course, these data from animal studies cannot be translated into clinical practice, but they point towards the possibility that NOA might be safer than warfarin in terms of intracerebral hemorrhage, especially after a stroke. One possible consequence might be the opportunity to start early anticoagulation after a cardioembolic stroke. To further explore this, it would be

of utmost interest to obtain the actual anticoagulant activity in patients who suffer a stroke under NOA.

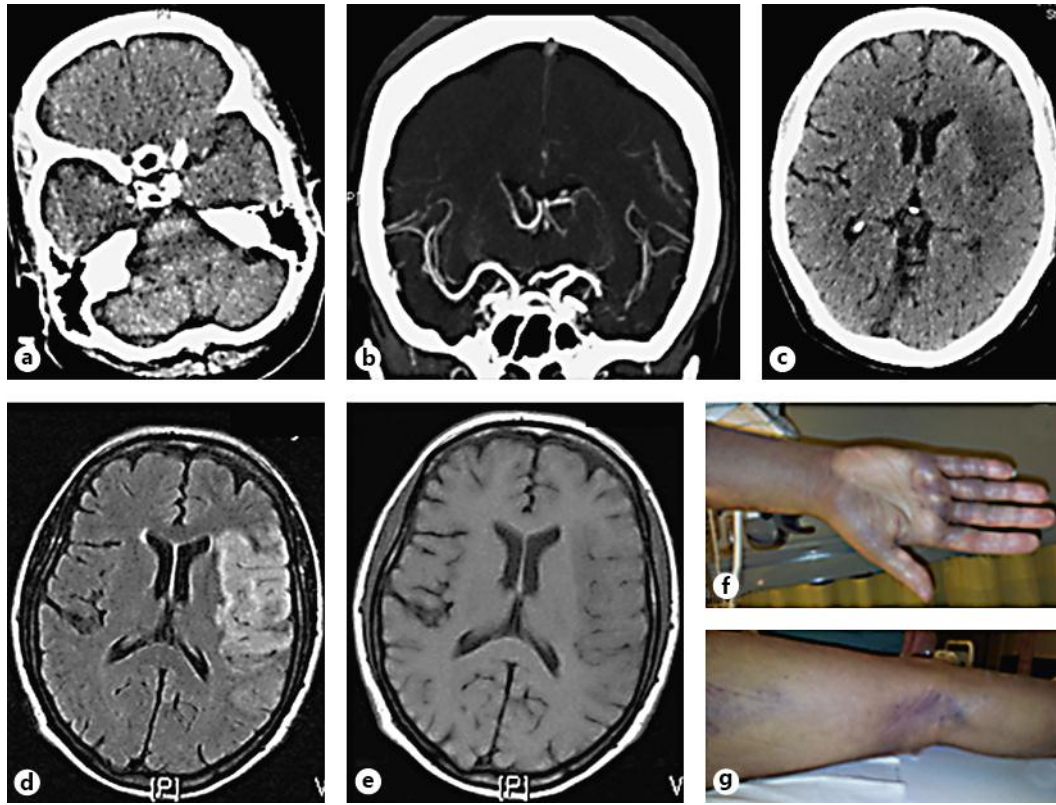
## References

- 1 Connolly SJ, Ezekowitz MD, Yusuf S, Eikelboom J, Oldgren J, Parekh A, Pogue J, Reilly PA, Themeles E, Varrone J, Wang S, Alings M, Xavier D, Zhu J, Diaz R, Lewis BS, Darius H, Diener HC, Joyner CD, Wallentin L; RE-LY Steering Committee and Investigators: Dabigatran versus warfarin in patients with atrial fibrillation. *N Engl J Med* 2009;361:1139–1151.
- 2 Patel MR, Mahaffey KW, Garg J, Pan G, Singer DE, Hacke W, Breithardt G, Halperin JL, Hankey GJ, Piccini JP, Becker RC, Nessel CC, Paolini JF, Berkowitz SD, Fox KA, Califf RM; ROCKET AF Investigators: Rivaroxaban versus warfarin in nonvalvular atrial fibrillation. *N Engl J Med* 2011;365:883–891.
- 3 Granger CB, Alexander JH, McMurray JJ, Lopes RD, Hylek EM, Hanna M, Al-Khalidi HR, Ansell J, Atar D, Avezum A, Bahit MC, Diaz R, Easton JD, Ezekowitz JA, Flaker G, Garcia D, Geraldes M, Gersh BJ, Golitsyn S, Goto S, Hermosillo AG, Hohnloser SH, Horowitz J, Mohan P, Jansky P, Lewis BS, Lopez-Sendon JL, Pais P, Parkhomenko A, Verheugt FW, Zhu J, Wallentin L; ARISTOTLE Committees and Investigators: Apixaban versus warfarin in patients with atrial fibrillation. *N Engl J Med* 2011;365:981–992.
- 4 Capodanno D, Capranzano P, Giacchi G, Calvi V, Tamburino C: Novel oral anticoagulants versus warfarin in non-valvular atrial fibrillation: A meta-analysis of 50,578 patients. *Int J Cardiol* 2012, E-pub ahead of print.
- 5 van Ryn J, Stangier J, Haertter S, Liesenfeld KH, Wienen W, Feuring M, Clemens A: Dabigatran etexilate – a novel, reversible, oral direct thrombin inhibitor: interpretation of coagulation assays and reversal of anticoagulant activity. *Thromb Haemost* 2010;103:1116–1127.
- 6 Chong CA, Chiu L: Dabigatran and acute stroke thrombolysis. *Cerebrovasc Dis* 2010;30:202.
- 7 Casado Naranjo I, Portilla-Cuenca JC, Jiménez Caballero PE, Calle Escobar ML, Romero Sevilla RM: Fatal intracerebral hemorrhage associated with administration of recombinant tissue plasminogen activator in a stroke patient on treatment with dabigatran. *Cerebrovasc Dis* 2011;32:614–615.
- 8 De Smedt A, De Raedt S, Nieboer K, De Keyser J, Brouns R: Intravenous thrombolysis with recombinant tissue plasminogen activator in a stroke patient treated with dabigatran. *Cerebrovasc Dis* 2010;30:533–534.
- 9 Matute MC, Guillán M, García-Caldentey J, Buisan J, Aparicio M, Masjuan J, Alonso de Lecifiana M: Thrombolysis treatment for acute ischaemic stroke in a patient on treatment with dabigatran. *Thromb Haemost* 2011;106:178–179.
- 10 Sangha N, El Khoury R, Misra V, Lopez G: Acute ischemic stroke treated with intravenous tissue plasminogen activator in a patient taking dabigatran with radiographic evidence of recanalization. *J Stroke Cerebrovasc Dis* 2012;21:917.e5–e8.
- 11 Marrone LC, Marrone AC: Thrombolysis in an ischemic stroke patient on dabigatran anticoagulation: a case report. *Cerebrovasc Dis* 2012;34:246–247.
- 12 Lee VH, Connors JJ, Prabhakaran S: Intravenous thrombolysis in a stroke patient taking dabigatran. *J Stroke Cerebrovasc Dis* 2012;21:916.e11–e12.
- 13 Mani H, Hesse C, Stratmann G, Lindhoff-Last E: Rivaroxaban differentially influences ex vivo global coagulation assays based on the administration time. *Thromb Haemost* 2011;106:156–164.
- 14 Pfeilschifter W, Bohmann F, Baumgarten P, Mittelbronn M, Pfeilschifter J, Lindhoff-Last E, Steinmetz H, Foerch C: Thrombolysis with recombinant tissue plasminogen activator under dabigatran anticoagulation in experimental stroke. *Ann Neurol* 2012;71:624–633.
- 15 Bohmann F, Mirceska A, Pfeilschifter J, Lindhoff-Last E, Steinmetz H, Foerch C, Pfeilschifter W: No influence of dabigatran anticoagulation on hemorrhagic transformation in an experimental model of ischemic stroke. *PLoS One* 2012;7:e40804.
- 16 Gliem M, Hermesen D, van Rooijen N, Hartung HP, Jander S: Secondary intracerebral hemorrhage due to early initiation of oral anticoagulation after ischemic stroke: an experimental study in mice. *Stroke* 2012;43:3352–3357.

**Table 1.** Synopsis of the seven published cases of stroke under dabigatran in the therapeutic time window

Reference	Age years, sex	Dabigatran indication and dose	Interval last dose to thrombolysis	NIHSS upon admission	aPTT s	INR	Therapeutic decision	Outcome (NIHSS)	Future OAC therapy
De Smedt et al. [8]	46, f	AF (RELY-ABLE extension study), dose not indicated, b.i.d.	7 h	19	35	1.2	thrombolysis	improvement (12 at discharge)	warfarin
Chong and Chiu [6]	75, f	AF (RE-LY-trial), dose unknown, b.i.d., off dabigatran for 3 days in preparation for surgery	i.n.a.	8	34	1.1	no thrombolysis	improvement (2 at discharge)	n.i.
Matute et al. [9]	76, f	DVT prophylaxis after surgery, 220 mg o.d.	15 h	4	31	1.0	thrombolysis	improvement (0 at discharge)	n.i.
Casado Naranjo et al. [7]	62, m	AF, 110 mg b.i.d., patient not in steady state prior to stroke (3 doses)	6 h	18	37	1.3	thrombolysis	fatal intracerebral hemorrhage	–
Sangha et al. [10]	51, m	AF, 150 mg b.i.d.	18 h	6	31	1.1	thrombolysis	improvement (2 at 6 months)	warfarin
Marrone and Marrone [11]	73, m	AF, 110 mg b.i.d.	7 h	14	38	1.1	thrombolysis	improvement (7 next day)	dabigatran 110 mg b.i.d.
Lee et al. [12]	64, m	AF, i.n.a.	i.n.a.	i.n.a.	38	1.1	thrombolysis	i.n.a., CCT: no hemorrhage	i.n.a.

o.d. = Once daily; b.i.d. = twice daily; i.n.a. = information not available; n.i. = not indicated.



**Fig. 1.** **a** Cranial CT on admission shows a hyperdense left MCA. **b** Distal left MCA occlusion was confirmed by CT angiography. **c** CT follow-up 24 h after thrombolysis showed a frontoparietal MCA infarction. **d, e** MRI without signs of gross hemorrhagic transformation. **f, g** Extended superficial ecchymoses of the skin after thrombolysis under dabigatran.