



Constrained liners, dual mobility or large diameter heads to avoid dislocation in THA

Olivier Guyen

- Dislocation remains a common cause of failure after total hip arthroplasty. The limitations of existing approaches to address instability have led to the development of powerful options: constrained liners, dual mobility and large heads. These implant-related options have proven to be very efficient, but have raised concerns.
- With constrained liners, restricted range of motion (ROM) is responsible for impingement leading to high likelihood of failure, depending on the design, with various failure modes.
- Improvements of the bearing materials have addressed some of the concerns about increased volumetric wear of conventional polyethylene and offer an option to reduce instability: large diameter heads have the advantage of increased ROM before impingement, increased head-neck ratio, and jump distance. Highly cross-linked polyethylene helps address the risk for increased wear, and also large heads provide improved stability without the risk of mechanical failures observed with constrained liners. However, the increase of the head size remains limited as reducing the thickness of the liner may lead to fractures. In addition, the jump distance decreases as the cup abduction increases.
- The dual mobility concept simultaneously attempts to address head-neck ratio, constraint, and jump distance. Despite the need for longer follow-up, concerns raised about potential increased wear and intra-prosthetic dislocation with first generation implants have been addressed with modern designs.
- With a dramatic increase of the head-neck ratio whilst reducing the risk of mechanical failure or excessive wear, dual mobility THA outperforms large diameter heads and constrained liners at 10 years follow-up. For these reasons, dual mobility continues to gain interest worldwide and is becoming the most popular option to manage instability.

Keywords: total hip arthroplasty; instability; dislocation; constrained liners; large diameter heads; dual mobility; tripolar constrained implant

Cite this article: Guyen O. Constrained liners, dual mobility or large diameter heads to avoid dislocation in THA. *EFORT Open Rev* 2016;1:197-204. DOI: 10.1302/2058-5241.1.000054.

Introduction

Despite the fact that total hip arthroplasty (THA) is commonly reported with successful results, instability remains a disappointing complication and one of the most common reasons for revision. Prevalence of instability has been reported ranging from 0.2% to 7% after primary procedures and can reach 10% and even more after revision surgery.¹

Despite numerous surgical options which have been proposed, treatment of instability remains a challenge, and highly variable success rates have been reported. Re-operation for instability is known to carry the highest likelihood of failure of any re-operation after THA² with re-dislocation rates ranging from 20% to 40%.^{3,4}

With better understanding of the causes of dislocation and development of improved and powerful technologies over the last decade, improved rates of prevention of instability or restoration of stability are anticipated. Selection of the implant is one of the critical steps to prevent unstable THA. Three main options that provide some protection against dislocation have emerged: constrained liners, dual mobility implants, and use of large diameter femoral heads.

A literature review of each of these options follows with particular attention to the clinical results, and advantages and disadvantages are identified.

Constrained liners

The use of constrained liners has been reported with encouraging results in restoring stability in revision THA for recurrent dislocation. Therefore, constrained implants gained interest in the late 1990s and have become one of the most popular options worldwide to treat instability. Many manufacturers have produced various commercial implants, but there are two prevailing designs of constrained liners. In the first, the liner extends beyond a hemisphere with polyethylene extended around the rim and with an inner diameter of the opening that is smaller than the prosthetic head. Reduction of the head within the liner is achieved through mechanical expansion of the inner diameter of the rim. An external metal ring is locked to the liner to prevent it from re-expanding (Fig. 1).

In the second design, the constrained tripolar implant (Stryker Howmedica Osteonics, Rutherford, NJ) consists of a bipolar component locked into an outer polyethylene liner during the manufacturing process. The opening of

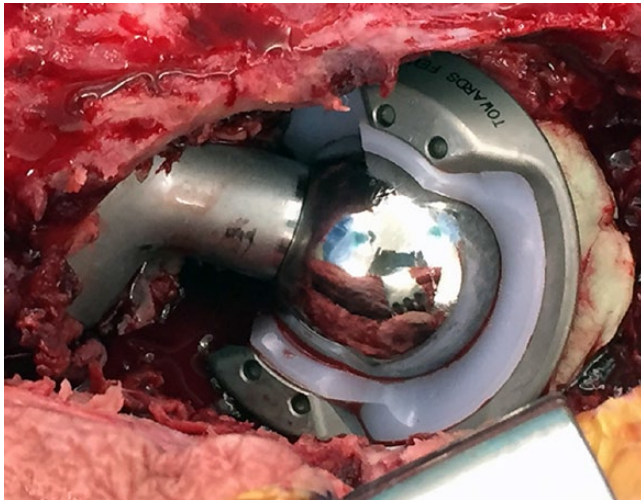


Fig. 1 An example of a constrained system using an external metal ring locked to the liner in order to avoid mechanical re-expansion of the liner once the head is within the socket.

the liner has an embedded metallic locking ring. The bipolar component consists of a 22 mm, 28 mm, or 32 mm prosthetic head that snaps into a polyethylene shell with a polished cobalt-chrome backing. It is free to rotate, but is locked in place by a second inner retaining ring (Fig. 2).

A literature review of the use of constrained implants reported a mean rate of dislocation of 10%, and a mean reoperation rate, for reasons other than dislocation, of 4%, at a mean follow-up of 51 months (range 24 to 124 months).⁵

Efficacy of constrained devices has been shown to be design-dependent. Dislocation rates have been reported ranging between 4.5% and 29% with the S-ROM cup.^{6,7} The tripolar constrained design provided better short-term results with dislocation rates ranging from 2.9% to 3.5%,⁸ and 6% to 7% at ten years.^{9,10}

Berend et al¹¹ reported a ten-year follow-up of 667 constrained THAs with an overall dislocation rate of 17.5%.

Limitations of constrained implants

Both designs of constrained implants result in a restricted range of motion (ROM) and have a greater prevalence of impingement of the femoral neck on the cup. Impingement is responsible for high stress transmission to multiple interfaces, leading to liner damage, locking mechanism failure, dislocation and loosening (Fig. 3).

Unacceptably high failure rates have been reported with the use of constrained devices. Berend et al¹¹ reported a long-term failure rate of 42.1% with the tripolar constrained implant, while Labek et al¹² reported a 100% failure rate using the Duraloc constrained inlay (Depuy/Johnson and Johnson, Warsaw, IN). Survival at 10.2 years was 90% with the tripolar constrained implant using component failure as the end-point, and 68% for all modes of failure.¹⁰ A review of the failed tripolar constrained




Fig. 2 The complex design of the constrained tripolar implant (Stryker Howmedica Osteonics, Rutherford, NJ), involving numerous parts, is shown. The bipolar component (22, 28 or 32 mm head snapped into a polyethylene shell with a polished cobalt-chrome backing and locked in place by a retaining ring) is locked into an outer polyethylene liner with an embedded metallic locking ring during the manufacturing process.

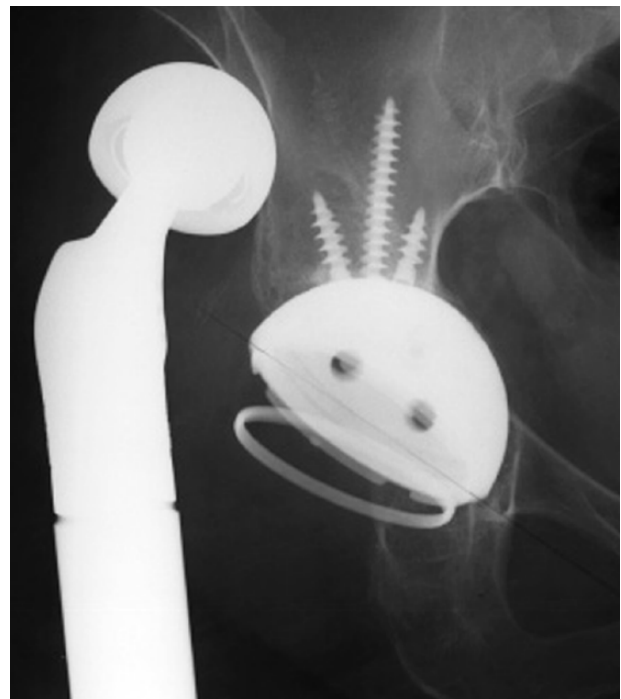


Fig. 3 An example of a locking mechanism failure of a constrained tripolar implant.

implants at the Mayo Clinic found an average time to failure of only 28.4 months, with a total failure rate of 11%.¹³ Five different modes of failure had been identified. Because of the complexity of the design, mechanical failures were found at most of the device interfaces. Impingement was involved in the occurrence of all types of mechanical failure.

A modified design of constrained device has been proposed, with strategically positioned polyethylene cut-outs to provide significant improvements in ROM in flexion, internal rotation, extension and external rotation.¹⁴ A 12% re-dislocation rate and a 3% rate of revision for cup aseptic loosening at only 1.8-year follow-up has been reported in a series of patients treated for recurrent dislocation with this device.¹⁵

Dual mobility

Dual mobility is a concept first introduced by Bousquet in the late 1970s. Such a system combines both the large head articulation and low friction arthroplasty concepts. In a dual mobility articulation, the interposition of a mobile ultra high molecular weight polyethylene (UHMWPE) component between the prosthetic head and the highly polished inner surface of an outer metal shell provides two bearings (inner between the prosthetic head and the polyethylene component, and outer between the polyethylene component and the outer metal shell).

In so doing, the dual mobility system provides a greater effective head size and improved head-to-neck ratio (Fig. 5). Dual mobility is therefore expected to improve the ROM to impingement and joint stability. Laboratory studies have confirmed this assumption and have emphasised the advantages of dual mobility over conventional implants.^{16,17} Computer simulation studies have demonstrated greater posterior jump distance with dual mobility implants than with standard hemispherical fixed bearings.¹⁸

With dual mobility systems, *in vitro* motion preferentially occurs at the inner bearing and the outer bearing engages at the extremes of motion. Analysis of retrieved implants has shown wear patterns at the outer surface of the mobile UHMWPE component, confirming that mobility *in vivo* occurs at the two bearings.^{19,20} Better understanding of the biomechanics of dual mobility has led to improvements of the original design and modern, newer-generation implants have become available, with enhanced cementless cup fixation, optimised geometry, and improved bearing materials (Fig. 6).

The use of either a dual layer coating of hydroxyapatite and titanium plasma spray, or a porous metal coating with modern dual mobility implants (stainless steel or cobalt-chromium outer shell) has improved mid-term survivorship.²¹ Long-term survivorship of modern dual mobility implants are promising but are not yet available.

In addition, specific designs have been developed in order to secure the press-fit fixation in cases with limited bone stock (Fig. 7). In cases with severe bone loss, the use of cemented dual mobility implants into a cage is a reliable option to consider.²²

Various newer geometries with subtle modifications of the original cylindrospherical design of the cup have been offered by manufacturers during recent years: hemispherical, subhemispherical, or anatomical cups are currently available in order to improve the prosthetic ROM free of

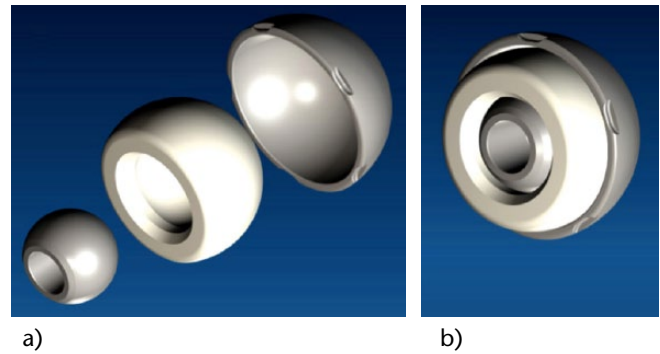


Fig. 4 The dual mobility concept: exploded view (a) and assembled view (b). The mobile polyethylene component between the prosthetic head and the inner surface of the metal cup provides two bearings (inner between the prosthetic head and the polyethylene component, and outer between the polyethylene component and the outer metal shell).

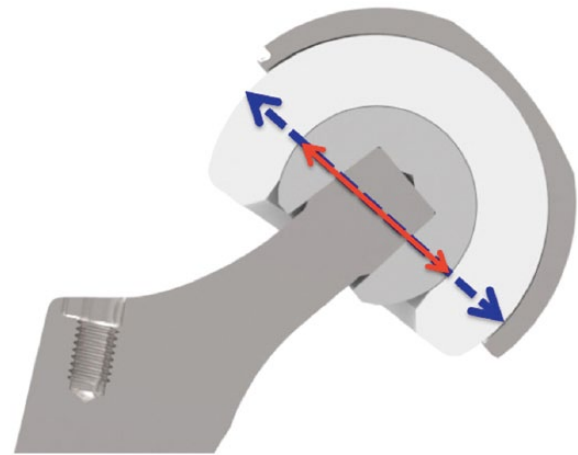


Fig. 5 The dual mobility concept : the prosthetic head (22.2 mm or 28 mm) is snapped into the mobile UHMWPE component and is free to rotate, and the outer surface of the mobile component articulates against the outer metal shell. Therefore the head-to-neck ratio is increased as the mobile polyethylene component increases the effective head size which actually corresponds to the outer diameter of the mobile polyethylene component.

impingement, and to avoid psoas tendon-to-cup impingement.

As dual mobility systems have raised concerns regarding the potential for increased polyethylene wear, highly cross-linked polyethylene, has recently been introduced. Results of *in vitro* wear tests support the use of highly cross-linked polyethylene, with a significant reduction in wear of at least 85% under adverse conditions and over 97% under pristine conditions when compared with a single articulation hip with conventional polyethylene.²³ Even in cases with excessive cup abduction, *in vitro* wear patterns of dual mobility implants using highly cross-linked polyethylene compare favourably with conventional implants.²⁴ Clinically, encouraging reports with the use of highly cross-linked polyethylene are emerging; however, follow-up remains limited to date.²⁵⁻²⁷

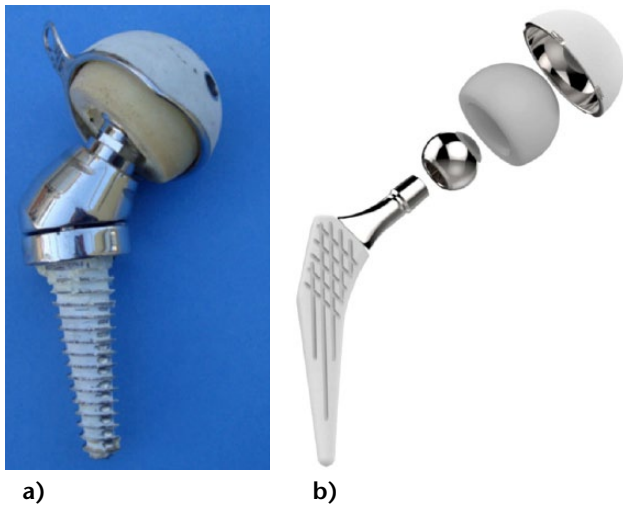


Fig. 6 Evolution of the design of dual mobility systems: from the original Bousquet's design (a) to modern design (b) with optimised neck/chamfer and cup geometry. Note the thin and highly polished neck of the femoral component to limit wear at the third joint.




Fig. 7 Examples of specific designs of dual mobility systems for revision cases are shown. According to the bony conditions, (a) the press-fit fixation of the dual mobility implant can be improved with the use of pegs and supra-acetabular screws, or (b) with a hook and flanges possibly combined with a modular cup for screw fixation and a Cobalt-Chrome liner.

Clinical reports on the use of first-generation dual mobility implants have emphasised the efficiency of the concept in preventing instability.^{28,29}

Over the past ten years, the number of clinical reports with the use of modern designs of dual mobility implants both for primary and revision procedures has risen. Most of these studies are observational. In primary procedures, the use of dual mobility systems has been reported with low dislocation rates, ranging from 0% to 4.6% both in patients at risk for dislocation and in non-selected patients (Table 1). Unlike conventional implants, the cumulative risk for dislocation does not increase with time with dual mobility systems.²⁹

Dual mobility has also been reported with remarkably low dislocation rates in revision THA, ranging from 0% to 1.4% at short- to mid-term follow-up.⁴⁰⁻⁴³ In the challenging situation of unstable THA, revision is known to carry a high

probability of failure.² Reports on the use of modern dual mobility systems in such situations have demonstrated the efficacy of dual mobility to restore stability, with short- to mid-term re-dislocation rates ranging from 0% to 5.5% (Table 2).

Limitations of dual mobility systems

With an additional bearing, dual mobility systems have raised concerns of whether or not wear might be increased compared to a conventional bearing. Clinical reports on the use of the first generation of dual mobility implants have shown encouraging results, with global survival rates as high as 81% at 15 years, 75% at 20 years, and 74% at 22 years.²⁹ In addition, wear measurements from retrieved first-generation dual mobility implants have confirmed low wear rates.²⁰ With improved designs of modern dual mobility systems, six-year survivorship has been reported as high as 100%, but no long-term survivorship data are yet available.⁵²

As described previously, highly cross-linked polyethylene has been introduced to optimise wear resistance in dual mobility. However, to date, despite encouraging early results, the long-term benefit of highly cross-linked polyethylene has not been clinically demonstrated.

Intra-prosthetic dislocation (IPD) is another potential limitation of dual mobility systems.⁵³ This specific failure mode has been revealed with the experience of the first generation of implants, and occurs when the prosthetic head dislodges from the mobile polyethylene component. An incidence of 2% to 4% of such a complication with the first generation of implants had been reported.^{28,29} As the main mechanism for such a complication results from polyethylene wear at the retentive rim of the polyethylene component, IPD is typically a long-term complication. With substantial improvements of the head/neck geometry, recent reports have demonstrated a dramatic decrease of the incidence of IPD ranging from 0% at 6 years⁵² to 0.28% at 10 years³⁶ with the newer generation of implants using conventional polyethylene.

The recent introduction of highly cross-linked polyethylene with modern designs has raised concerns regarding the possibility of increased risk of IPD, because of the potentially reduced mechanical properties and fatigue strength of irradiated polyethylene.⁵⁴ Damage in the retentive area may lead to IPD. For this reason, despite encouraging early clinical results at between two and five years' follow-up,²⁶ and because sporadic reports of early IPD have recently emerged,^{55,56} the long-term benefit of highly cross-linked polyethylene in dual mobility systems is not yet clinically demonstrated.

Large diameter heads

Although dislocation is multi-factorial, head size has been recognised to have a strong influence on stability. Increasing the head size results in an increase of the head-to-neck

Table 1. Dual mobility implants in primary total hip arthroplasty

Year	Authors	Study	No. hips	Patients	Follow-up	Dislocation rate	Survivorship
2015	Vigdorichik et al. ²⁵	Multicentre retrospective	485	Unselected	Min 2yrs	0%	–
2015	Epinette et al. ²⁷	Prospective comparative	143	Unselected	2-6 yrs	0%	100% at 4.1 yrs
2014	Caton et al. ³⁰	Retrospective comparative	105	Unselected	Min 10 yrs	0.9%	97.9% at 10 yrs
2014	Epinette et al. ²⁶	Prospective multicentre	437	Unselected	2-5 yrs	0%	99.7% at 4 yrs
2014	Bensen et al. ³¹	Retrospective	175	At risk for dislocation	–	4.6%	–
2014	Vasukutty et al. ³²	Retrospective	65	At risk for dislocation	Mean 5 yrs	0%	100% at 5 yrs
2013	Sanders et al. ³³	Retrospective	10	At risk for dislocation	Mean 3.2 yrs	0%	–
2013	Leclercq et al. ³⁴	Multicentre prospective	200	Unselected	10-13 yrs	0%	99% at 10 yrs
2013	Prudhon et al. ³⁵	Retrospective	105	At risk for dislocation	Mean 7.5 yrs	0.9%	95% at 10 yrs
2013	Combes et al. ³⁶	Retrospective multicentre	2480	Unselected	Min 7 yrs	0.6% (0.28% IPD*)	93% at 10 yrs
2012	Hamadouche et al. ³⁷	Retrospective multicentre	168	Unselected	5-8 yrs	2% (IPD*)	94.2% at 7 yrs
2008	Bauchu et al. ³⁸	Retrospective multicentre	150	Unselected	Mean 6.2 yrs	0%	97.4% at 7.1 yrs
2007	Guyen et al. ³⁹	Retrospective	167	At risk for dislocation	Mean 3.4 yrs	0%	96.4% at 5 yrs

*IPD: intra-prosthetic dislocation.

Table 2. Dual mobility implants in revision procedures for instability

Year	Authors	Study	No. hips	Follow-up	Dislocation rate
2015	Van Heumen et al. ⁴⁴	Retrospective	50	2.5 yrs	0%
2014	Jakobsen et al. ⁴⁵	Retrospective	56	3.6 yrs	1.8%
2013	Saragaglia et al. ⁴⁶	Retrospective	29	3.8 yrs	3.4%
2012	Mertl et al. ⁴⁷	Retrospective multicentre	180	7.7 yrs	4.8%
2012	Hailer et al. ⁴⁸	Retrospective multicentre	228	2 yrs	2%
2011	Leiber-Wackenheim et al. ⁴⁹	Retrospective	59	8 yrs	1.7%
2010	Hamadouche et al. ⁵⁰	Retrospective	51	4.3 yrs	4.3%
2009	Guyen et al. ⁵¹	Retrospective	54	Mean 4 yrs	5.5% (2 IPD*)

*IPD: intra-prosthetic dislocation.

ratio, improvement of the range of motion to impingement, and an increase in the amount of displacement required before the head dislocates.⁵⁷ This has led to an increasing use of large diameter prosthetic heads over the last decade.⁵⁸ Multiple studies have emphasised the benefit of large heads in reducing dislocation rates. However, the use of larger head sizes has raised concerns regarding wear. Advances in bearings (hard-on-hard bearings, and highly cross-linked polyethylene) with improved wear properties have led to renewed interest in the use of large heads, and have expanded prosthetic head options from the traditional sizes of 22 mm, 28 mm and 32 mm to diameters as large as 60 mm. Crowninshield et al.⁵⁹ have demonstrated an almost linear increase in the prosthetic ROM free of impingement with an increase in the femoral head diameter from 22 mm to 40 mm. In addition, the displacement required for dislocation substantially increased with the head size. However, increasing cup abduction greatly reduces the stability advantage of larger femoral heads, and may lead to increased tensile stress at the periphery of the polyethylene, material deformation, implant failure and dislocation. Despite an increase in ROM to impingement with increasing head size from 22 mm to 38 mm, Burroughs et al.⁶⁰ did not observe a significant benefit going from 38 mm to 44 mm in terms of prosthetic impingement.

Other clinical studies with large femoral head sizes have been reported with reduced dislocation rates. Lombardi et al.⁶¹ reported a dislocation rate as low as 0.05% in a

series of 2020 THAs using greater than 36 mm heads. Stroh et al.⁶² reported a significantly higher rate of dislocation with small diameter heads (1.8%) compared to the large diameter heads (0% with 36 mm or 40 mm diameters).

In a prospective randomised clinical trial comparing dislocation rates between revision THAs using 36 mm and 40 mm head diameters on one hand, with 32 mm head diameter on the other, Garbuz et al.⁶³ reported a significantly reduced dislocation rate with the larger heads (1.1% versus 8.7%).

Lachiewicz et al.⁶⁴ reported a 4% rate of early dislocation using 36 mm and 40 mm diameter heads in a series of 122 primary hip arthroplasties performed in patients presumed at high risk for dislocation.

Available larger diameter material combinations include metal or ceramic on highly cross-linked polyethylene and metal-on-metal. The use of large head metal-on-metal bearings has been largely abandoned as national joint registries have shown significantly higher failure rates.^{65,66}

Large ceramic heads are available commercially in sizes up to 48 mm. Ceramic-on-ceramic bearings have extremely low wear rates, and ceramic-on-polyethylene bearings are also reported with attractive low wear rates.

Limitations of big heads

Despite the finding that large femoral heads have clearly decreased the risk of instability, they have raised some

concerns regarding potential downsides. Larger diameter heads are responsible for increased volumetric wear. Reduced thickness of the polyethylene with larger head size may also lead to early failure, because of increased stress within the material. Development of highly cross-linked polyethylene has partly diminished these concerns with significant improvement of wear resistance.⁶⁷ However, concerns regarding the potential for mechanical failures and fractures with thinner polyethylene liners remain as sporadic cases have been reported.^{68,69}

In addition, large metal heads have raised concerns regarding the potential adverse local tissue reactions (ALTR) secondary to corrosion and metal release at the head-neck taper junction.⁷⁰ Increasing the head size generates large torsional forces at the trunnion-head junction, and significantly increases the maximal principal stress in the neck medial area, regardless of the material used for the head (Cobalt-Chrome or Alumina).⁷¹ These torsional forces potentiate tribocorrosion⁷² and probably lead to ALTR.

The use of large heads has also been reported with potential anterior hip pain and groin pain secondary to impingement against the iliopsoas muscle or tendon.^{73,74} The recent introduction of anatomically-contoured heads to address this potential disadvantage of big heads has not been evaluated as yet.

Summary

Constrained liners, dual mobility and large diameter femoral heads are powerful and efficient options to prevent or to treat THA instability. Before choosing one implant, the arthroplasty surgeon should be aware of the design concept, the advantages, disadvantages and outcome data. He also has to keep in mind that the surgical techniques remain critical whatever the selected implant.

Constrained liners have been reported not only with inconsistent results on stability related to the design of the constraining device but also with a high risk for mechanical failure because of high stress transmission. Large diameter heads require the use of alternate bearings such as highly cross-linked polyethylene or ceramic in order to address the concern about increased wear. However, thickness of the liner and risk for fracture of polyethylene or ceramic remains a concern. The dual mobility concept simultaneously attempts to address head-neck ratio, constraint, and jump distance. Unlike those reports regarding the use of constrained devices and large heads, recent reports show no evidence of increased wear nor risk for mechanical failure with modern designs of dual mobility at 10 years' follow-up. Dual mobility therefore continues to gain interest worldwide and is becoming one of the most popular current options to manage unstable THA.

AUTHOR INFORMATION

Department of Orthopaedic Surgery, Lausanne University Hospital, Lausanne, Switzerland.

Correspondence should be sent to Olivier Guyen, Department of Orthopaedic Surgery, CHUV-Orthopedic Hospital, Avenue Pierre Decker 4, CH- 1011 Lausanne, Switzerland.

Email: olivier.guyen@chuv.ch

CONFLICT OF INTEREST

None declared.

FUNDING

The author or one or more of the authors have received or will receive benefits for personal or professional use from a commercial party related directly or indirectly to the subject of this article.

LICENCE

© 2016 The author(s)

This article is distributed under the terms of the Creative Commons Attribution-NonCommercial 4.0 License (<http://www.creativecommons.org/licenses/by-nc/4.0/>) which permits non-commercial use, reproduction and distribution of the work without further permission provided the original work is attributed.

REFERENCES

1. **Patel PD, Potts A, Froimson MI.** The dislocating hip arthroplasty: prevention and treatment. *J Arthroplasty* 2007;22(suppl 1):86-90. PMID:17570285.
2. **Berry DJ.** Unstable total hip arthroplasty: detailed overview. *Instr Course Lect* 2001;50:265-74.
3. **Daly PJ, Morrey BF.** Operative correction of an unstable total hip arthroplasty. *J Bone Joint Surg [Am]* 1992;74:1334-43. PMID:1429788.
4. **Fraser GA, Wroblewski BM.** Revision of the Charnley low-friction arthroplasty for recurrent or irreducible dislocation. *J Bone Joint Surg [Br]* 1981;63B:552-5. PMID:7298683.
5. **Williams JT Jr, Ragland PS, Clarke S.** Constrained components for the unstable hip following total hip arthroplasty: a literature review. *Int Orthop* 2007;31:273-7. PMID:16927089.
6. **Anderson MJ, Murray WR, Skinner HB.** Constrained acetabular components. *J Arthroplasty* 1994;9:17-23. PMID:8163971.
7. **Lombardi AV Jr, Mallory TH, Kraus TJ, Vaughn BK.** Preliminary report on the S-ROM constraining acetabular insert: a retrospective clinical experience. *Orthopedics* 1991;14:297-303. PMID:2020628.
8. **Khan RJ, Fick D, Alakeson R, et al.** A constrained acetabular component for recurrent dislocation. *J Bone Joint Surg [Br]* 2006;88:870-6. PMID:16798987.
9. **Bremner BR, Goetz DD, Callaghan JJ, Capello WN, Johnston RC.** Use of constrained acetabular components for hip instability: an average 10-year follow-up study. *J Arthroplasty* 2003;18(suppl 1):131-7. PMID:14560423.
10. **Goetz DD, Bremner BR, Callaghan JJ, Capello WN, Johnston RC.** Salvage of a recurrently dislocating total hip prosthesis with use of a constrained acetabular component. A concise follow-up of a previous report. *J Bone Joint Surg [Am]* 2004;86-A:2419-23. PMID:15523012.
11. **Berend KR, Lombardi AV Jr, Mallory TH, Adams JB, Russell JH, Groseth KL.** The long-term outcome of 755 consecutive constrained acetabular components in

- total hip arthroplasty examining the successes and failures. *J Arthroplasty* 2005;20(suppl 3):93-102. PMID:16214009.
12. **Labek G, Brabec E, Frischhut S, Krismer M.** High failure rate of the Duraloc Constrained Inlay. *Acta Orthop* 2009;80:545-7. PMID:19916686.
 13. **Guyen O, Lewallen DG, Cabanela ME.** Modes of failure of osteonics constrained tripolar implants: a retrospective analysis of forty-three failed implants. *J Bone Joint Surg [Am]* 2008;90:1553-60. PMID:18594105.
 14. **Burroughs BR, Golladay GJ, Hallstrom B, Harris WH.** A novel constrained acetabular liner design with increased range of motion. *J Arthroplasty* 2001;16(suppl 1):31-6. PMID:11742448.
 15. **Vest Andersen A, Grete Kjersgaard A, Solgaard S.** Trilogy-constrained acetabular component for recurrent dislocation. *ISRN Orthopedics* 2013, DOI:10.1155/2013/629201.
 16. **Guyen O, Chen QS, Bejui-Hugues J, Berry DJ, An KN.** Unconstrained tripolar hip implants: effect on hip stability. *Clin Orthop Relat Res* 2007;455:202-8. PMID:17279045.
 17. **Chen Q, Lazennec JY, Guyen O, Kinbrum A, Berry DJ, An KN.** Technical note: validation of a motion analysis system for measuring the relative motion of the intermediate component of a tripolar total hip arthroplasty prosthesis. *Med Eng Phys* 2005;27:505-12. PMID:15990067.
 18. **Heffernan C, Banerjee S, Nevelos J, et al.** Does dual-mobility cup geometry affect posterior horizontal dislocation distance. *Clin Orthop Relat Res* 2014;472:1535-44.
 19. **Geringer J, Boyer B, Farizon F.** Understanding the dual mobility concept for total hip arthroplasty: investigations on a multiscale analysis-highlighting the role of arthrofibrosis. *Wear*. 2011;271:2379-85.
 20. **Adam P, Farizon F, Fessy MH.** Analyse de surface après explantation de 40 cupules rétentives en polyéthylène à double mobilité. [Dual articulation retentive acetabular liners and wear: surface analysis of 40 retrieved polyethylene implants]. *Rev Chir Orthop Reparatrice Appar Mot* 2005;91:627-36. PMID:16327667. [Article in French]
 21. **Massin P, Orain V, Philippot R, Farizon F, Fessy MH.** Fixation failures of dual mobility cups: a mid-term study of 2601 hip replacements. *Clin Orthop Relat Res* 2012 Jul;470:1932-40.
 22. **Wegrzyn J, Pibarot V, Jacquel A, Carret JP, Béjui-Hugues J, Guyen O.** Acetabular reconstruction using a Kerboul cross-plate, structural allograft and cemented dual-mobility cup in revision THA at a minimum 5-year follow-up. *J Arthroplasty* 2014;29:432-37. PMID:23849510.
 23. **Loving L, Lee RK, Herrera L, Essner AP, Nevelos JE.** Wear performance evaluation of a contemporary dual mobility hip bearing using multiple hip simulator testing conditions. *J Arthroplasty* 2013;28:1041-6. PMID:23434106.
 24. **Loving L, Herrera L, Banerjee S, et al.** Dual mobility bearings withstand loading from steeper cup-inclinations without substantial wear. *J Orthop Res* 2015;33:398-404. PMID:25421305.
 25. **Vigdorchik JM, D'Apuzzo MR, Markel DC, et al.** Lack of early dislocation following total hip arthroplasty with a new dual mobility acetabular design. *Hip Int* 2015;25:34-8. PMID:25655740.
 26. **Epinette JA, Béracassat R, Tracol P, Pagazani G, Vandebussche E.** Are modern dual mobility cups a valuable option in reducing instability after primary hip arthroplasty, even in younger patients? *J Arthroplasty* 2014;29:1323-8. PMID:24444567.
 27. **Epinette JA.** Clinical outcomes, survivorship and adverse events with mobile-bearings versus fixed-bearings in hip arthroplasty - a prospective comparative cohort study of 143 ADM versus 130 trident cups at 2 to 6-year follow-up. *J Arthroplasty* 2015;30:241-8. PMID:25449593.
 28. **Philippot R, Camilleri JP, Boyer B, Adam P, Farizon F.** The use of a dual-articulation acetabular cup system to prevent dislocation after primary total hip arthroplasty: analysis of 384 cases at a mean follow-up of 15 years. *Int Orthop* 2009;33:927-32. PMID:18521598.
 29. **Boyer B, Philippot R, Geringer J, Farizon F.** Primary total hip arthroplasty with dual mobility socket to prevent dislocation: a 22-year follow-up of 240 hips. *Int Orthop* 2012;36:511-8. PMID:21698430.
 30. **Caton JH, Prudhon JL, Ferreira A, Aslanian T, Verdier R.** A comparative and retrospective study of three hundred and twenty primary Charnley type hip replacements with a minimum follow up of ten years to assess whether a dual mobility cup has a decreased dislocation risk. *Int Orthop* 2014;38:1125-9. PMID:24737147.
 31. **Bensen AS, Jakobsen T, Krarup N.** Dual mobility cup reduces dislocation and re-operation when used to treat displaced femoral neck fractures. *Int Orthop* 2014;38:1241-5. PMID:24441666.
 32. **Vasukutty NL, Middleton RG, Young P, et al.** A double mobility acetabular implant for primary hip arthroplasty in patients at high risk of dislocation. *Ann R Coll Surg Engl* 2014;96:597-601. PMID:25350182.
 33. **Sanders RJ, Swierstra BA, Goosen JH.** The use of a dual-mobility concept in total hip arthroplasty patients with spastic disorders: no dislocations in a series of ten cases at midterm follow-up. *Arch Orthop Trauma Surg* 2013;133:1011-6. PMID:23632783.
 34. **Leclercq S, Benoit JY, de Rosa JP, Tallier E, Leteurtre C, Girardin PH.** Evora® chromium-cobalt dual mobility socket: results at a minimum 10 years' follow-up. *Orthop Traumatol Surg Res* 2013;99:923-8. PMID:24176671.
 35. **Prudhon JL, Ferreira A, Verdier R.** Dual mobility cup: dislocation rate and survivorship at ten years of follow-up. *Int Orthop* 2013;37:2345-50. PMID:24026216.
 36. **Combes A, Migaud H, Girard J, Duhamel A, Fessy MH.** Low rate of dislocation of dual-mobility cups in primary total hip arthroplasty. *Clin Orthop Relat Res* 2013;471:3891-900. PMID:23516032.
 37. **Hamadouche M, Arnould H, Bouxin B.** Is a cementless dual mobility socket in primary THA a reasonable option? *Clin Orthop Relat Res* 2012;470:3048-53. PMID:22639330.
 38. **Bauchu P, Bonnard O, Cyrès A, Fiquet A, Girardin P, Noyer D.** The dual-mobility POLARCUP: first results from a multicenter study. *Orthopedics* 2008;31(suppl2):orthosupersite.com/view.asp?rID=37180. PMID:19298026.
 39. **Guyen O, Pibarot V, Vaz G, Chevillotte C, Carret JP, Bejui-Hugues J.** Unconstrained tripolar implants for primary total hip arthroplasty in patients at risk for dislocation. *J Arthroplasty* 2007;22:849-58. PMID:17826276.
 40. **Langlais FL, Ropars M, Gaucher F, Musset T, Chaix O.** Dual mobility cemented cups have low dislocation rates in THA revisions. *Clin Orthop Relat Res* 2008;466:389-95. PMID:18196422.
 41. **Civinini R, Carulli C, Matassi F, Nistri L, Innocenti M.** A dual-mobility cup reduces risk of dislocation in isolated acetabular revisions. *Clin Orthop Relat Res* 2012;470:3542-8. PMID:22700131.
 42. **Simian E, Chatellard R, Druon J, Berhouet J, Rosset P.** Dual mobility cup in revision total hip arthroplasty: dislocation rate and survival after 5 years. *Orthop Traumatol Surg Res* 2015;101:577-81. PMID:26138633.
 43. **Prudhon JL, Steffann F, Ferreira A, Verdier R, Aslanian T, Caton J.** Cementless dual-mobility cup in total hip arthroplasty revision. *Int Orthop*. 2014;38:2463-8. PMID:25078366.
 44. **van Heumen M, Heesterbeek PJ, Swierstra BA, Van Hellemondt GG, Goosen JH.** Dual mobility acetabular component in revision total hip arthroplasty for persistent dislocation: no dislocations in 50 hips after 1-5 years. *J Orthop Traumatol*. 2015;16:15-20. PMID:25245630.

- 45. Jakobsen T, Kappel A, Hansen F, Krarup N.** The dislocating hip replacement – revision with a dual mobility cup in 56 consecutive patients. *Open Orthop J* 2014;8:268–71. PMID:25246992.
- 46. Saragaglia D, Ruatti S, Refaie R.** Relevance of a press-fit dual mobility cup to deal with recurrent dislocation of conventional total hip arthroplasty: a 29-case series. *Eur J Orthop Surg Traumatol* 2013;23:431–6. PMID:23412147.
- 47. Merti P, Combes A, Leiber-Wackenheim F, Fessy MH, Girard J, Migaud H.** Recurrence of dislocation following total hip arthroplasty revision using dual mobility cups was rare in 180 hips followed over 7 years. *HSS J* 2012;8:251–6. PMID:23144637.
- 48. Hailer NP, Weiss RJ, Stark A, Kärrholm J.** Dual-mobility cups for revision due to instability are associated with a low rate of re-revisions due to dislocation: 228 patients from the Swedish Hip Arthroplasty Register. *Acta Orthop* 2012;83:566–71. PMID:23116439.
- 49. Leiber-Wackenheim F, Brunschweiler B, Ehlinger M, Gabrion A, Merti P.** Treatment of recurrent THR dislocation using of a cementless dual-mobility cup: a 59 cases series with a mean 8 years' follow-up. *Orthop Traumatol Surg Res* 2011;97:8–13. PMID:21273156.
- 50. Hamadouche M, Biau DJ, Hutten D, Musset T, Gaucher F.** The use of a cemented dual mobility socket to treat recurrent dislocation. *Clin Orthop Relat Res* 2010;468:3248–54. PMID:20532718.
- 51. Guyen O, Pibarot V, Vaz G, Chevillotte C, Béjui-Hugues J.** Use of a dual mobility socket to manage total hip arthroplasty instability. *Clin Orthop Relat Res* 2009;467:465–72. PMID:18780135.
- 52. Vermersch T, Viste A, Desmarchelier R, Fessy MH.** Prospective longitudinal study of one hundred patients with total hip arthroplasty using a second-generation cementless dual-mobility cup. *Int Orthop* 2015;39:2097–101. PMID:26346372.
- 53. Philippot R, Boyer B, Farizon F.** Intraoperative dislocation: a specific complication of the dual-mobility system. *Clin Orthop Relat Res* 2013;471:965–70. PMID:23054529.
- 54. Oral E, Wannomae KK, Hawkins N, Harris WH, Muratoglu OK.** Alpha-tocopherol-doped irradiated UHMWPE for high fatigue resistance and low wear. *Biomaterials* 2004;25:5515–22. PMID:15142733.
- 55. Banzhof JA, Robbins CE, van der Ven A, Talmo CT, Bono JV.** Femoral head dislodgement complicating use of dual mobility prosthesis for recurrent instability. *J Arthroplasty* 2013;28:543.e1–543.e3.
- 56. Odland AN, Sierra RJ.** Intraoperative dislocation of a contemporary dual-mobility design used during conversion THA. *Orthopedics* 2014;37:e1124–e1128. PMID:25437088.
- 57. Cooper HJ, Della Valle CJ.** Large diameter femoral heads: is bigger always better? *Bone Joint J* 2014;96-B(11)(suppl A):23–6. PMID:25381403.
- 58. Jameson SS, Lees D, James P, et al.** Lower rates of dislocation with increased femoral head size after primary total hip replacement: a five-year analysis of NHS patients in England. *J Bone Joint Surg [Br]* 2011;93:876–80. PMID:21705556.
- 59. Crowninshield RD, Maloney WJ, Wentz DH, Humphrey SM, Blanchard CR.** Biomechanics of large femoral heads: what they do and don't do. *Clin Orthop Relat Res* 2004;410:2–7. PMID:15577473.
- 60. Burroughs BR, Hallstrom B, Golladay GJ, Hoeffel D, Harris WH.** Range of motion and stability in total hip arthroplasty with 28-, 32-, 38-, and 44-mm femoral head sizes. *J Arthroplasty* 2005;20:11–19. PMID:15660054.
- 61. Lombardi AV Jr, Skeels MD, Berend KR, Adams JB, Franchi OJ.** Do large heads enhance stability and restore native anatomy in primary total hip arthroplasty? *Clin Orthop Relat Res* 2011;469:1547–53. PMID:20953855.
- 62. Stroh DA, Issa K, Johnson AJ, Delanois RE, Mont MA.** Reduced dislocation rates and excellent functional outcomes with large-diameter femoral heads. *J Arthroplasty* 2013;28:1415–20. PMID:23602233.
- 63. Garbuz DS, Masri BA, Duncan CP, et al.** The Frank Stinchfield Award. Dislocation in revision THA: do large heads (36 and 40 mm) result in reduced dislocation rates in a randomized clinical trial? *Clin Orthop Relat Res* 2012;470:351–6. PMID:22038174.
- 64. Lachiewicz PF, Soileau ES.** Low early and late dislocation rates with 36- and 40-mm heads in patients at high risk for dislocation. *Clin Orthop Relat Res* 2013;471:439–43. PMID:22576929.
- 65. No authors listed.** National Joint Registry: 10th Annual Report, National Joint Registry of England, Wales and Northern Ireland 2013. http://www.njrcentre.org.uk/njrcentre/Portals/o/Documents/England/Reports/10th_annual_report/NJR%2010th%20Annual%20Report%202013%20B.pdf (date last accessed 26 February 2016).
- 66. No authors listed.** Australian Orthopaedic Association National Joint Replacement Registry: Annual Report 2013. <https://www.aoa.org.au/docs/default-source/annual-reports/annual-report-2012-2013.pdf?sfvrsn=6> (date last accessed 26 February 2016).
- 67. Muratoglu OK, Bragdon CR, O'Connor D, et al.** Larger diameter femoral heads used in conjunction with a highly cross-linked ultra-high molecular weight polyethylene: a new concept. *J Arthroplasty* 2001;16(suppl 1):24–30. PMID:11742447.
- 68. Blumenfeld TJ, McKellop HA, Schmalzried TP, Billi F.** Fracture of a cross-linked polyethylene liner: a multifactorial issue. *J Arthroplasty* 2011;26:666.e5–666.e8. PMID:20851563.
- 69. Duffy GP, Wannomae KK, Rowell SL, Muratoglu OK.** Fracture of a cross-linked polyethylene liner due to impingement. *J Arthroplasty*. 2009;24(1):158.e15–158.e19. PMID:19100926.
- 70. Cooper HJ, Della Valle CJ, Berger RA, et al.** Corrosion at the head-neck taper as a cause for adverse local tissue reactions after total hip arthroplasty. *J Bone Joint Surg [Am]* 2012;94:1655–61. PMID:23289127.
- 71. Lavernia CJ, Iacobelli DA, Villa JM, Jones K, Gonzalez JL, Jones WK.** Trunnion-head stresses in THA: are big heads trouble? *J Arthroplasty* 2015;30:1085–8. PMID:25724112.
- 72. Dyrkacz RM, Brandt JM, Ojo OA, Turgeon TR, Wyss UP.** The influence of head size on corrosion and fretting behaviour at the head-neck interface of artificial hip joints. *J Arthroplasty* 2013;28:1036–40. PMID:23528551.
- 73. Bartelt RB, Yuan BJ, Trousdale RT, Sierra RJ.** The prevalence of groin pain after metal-on-metal total hip arthroplasty and total hip resurfacing. *Clin Orthop Relat Res* 2010;468:2346–56. PMID:20425538.
- 74. Browne JA, Polga DJ, Sierra RJ, Trousdale RT, Cabanela ME.** Failure of larger-diameter metal-on-metal total hip arthroplasty resulting from anterior iliopsoas impingement. *J Arthroplasty* 2011;26:978.e5–978.e8. PMID:21130601.