

Atypical choroid plexus papilloma treated with single agent bevacizumab

Francois G. Kamar,^{1,2} Victor F. Kairouz,³
Selim M. Nasser,^{1,2} Sami G. Faddoul,⁴
Ibrahim C. Saikali^{1,2}

¹Division of Hematology and Oncology, Clemenceau Medical Center, Beirut, Lebanon; ²Lebanese American University, School of Medicine, Byblos, Lebanon; ³Buffalo University, New York, NY, USA; ⁴Columbia University College of Physician and Surgeons, New York, NY, USA

Abstract

Choroid plexus papillomas (CPPs) are usually not malignant and occur in less than 1% of brain tumors in patients of all ages. They represent 3% of childhood intracranial neoplasms with a predilection in younger ages. Papillomas have an indolent course and carry a good long-term outcome if gross total surgical resection is achieved. However malignant evolution may occur, with a 10-30% incidence. Chemotherapy has been used with varied degrees of success. Most series are very small, some are only limited to case reports and cannot lead to guidelines or therapeutic recommendations. We are reporting the first case of recurrent CPP treated with 5 mg/kg of bevacizumab administered once every two weeks. Complete patient evaluations with follow-up contrast-enhanced magnetic resonance imaging (MRI) scans were obtained after the initial two treatments and every 8 weeks thereafter. Only after two treatments, the MRI scans showed radiological stabilization of the tumor, and the patient achieved an excellent clinical response with significant resolution of all skin lesions.

Introduction

Choroid plexus papillomas are usually indolent and occur in less than 1% of brain tumors in patients of all ages.¹ They represent 3% of childhood intracranial neoplasms with a predilection in younger ages,^{1,2} 70% occurring in children less than 2 years old.³⁻⁵

Choroid plexus tumors are graded based on the World Health Organization (WHO) classification scheme and include choroid plexus papilloma (CPP, WHO grade I), atypical choroid plexus papilloma (APP, WHO grade II), and choroid plexus carcinoma (CPC, WHO grade III).⁶ Papillomas have an indolent course and carry a good long-term outcome if gross total

surgical resection is achieved.¹ However, malignant evolution may occur, with a 10-30% incidence.^{2,7,8} Choroid plexus carcinomas are typically malignant, aggressive tumors that have 5-year survival rates reported to be around 40%.⁹

Histological appearance is not always predictive of biologic behavior. Some highly anaplastic choroid plexus tumors can be clinically benign, whereas some histologically inactive tumors are invasive.^{1,7,10,11} When malignant degeneration occurs, these tumors tend to behave like carcinomas and carry a dismal prognosis, with a 5-year survival rate of 26% (Figure 1).^{1,7,11}

Adjuvant radiation therapy has been used in small series and reported to achieve acceptable long-term control when used in subtotally resected tumors.¹¹⁻¹³

Case Report

A 40-year-old woman was referred to us for salvage treatment. She was diagnosed in February 2005 with a 6.5 cm right occipital tumor with small millimetric parenchymal metastases and drop metastases throughout the neuraxis. She presented with clinical evidence of increased intra-cranial pressure (ICP), mass effect with extensive vasogenic edema requiring urgent surgery. She underwent gross tumor resection and pathology reported an atypical choroid plexus papilloma. Her staging work up was obtained following her recovery including brain and full spine contrast enhanced magnetic resonance imaging (MRI) scans. This revealed small drop metastases in the posterior fossa and along the spinal cord. The patient received radiation therapy to the neuraxis (the CSI dose was 36 Gy and the total dose to the primary tumor bed or surgical cavity was 54 Gy). She remained clinically stable for two years, and was able to perform activities of daily living. Repeated contrast enhanced MRI scans of the brain and full spine reported stable appearance in size and enhancement of all drop metastases in the posterior fossa and the spinal canal.

At relapse, she presented with continuous headaches, neck stiffness, altered mental status, and severe ataxia. Imaging revealed metastasis to bilateral cerebello-pontine (CP) angles and intraparenchymal supratentorial lesions (left frontal, right thalamic, and right temporal). She received 2 cycles of nitrosourea without response and worsening symptoms. Hence this was changed to ifosfamide, carboplatin and etoposide based combination. Radiological and clinical stabilization were attained following three cycles, but second progression was documented after the fifth cycle. Further surgeries and performed for rapidly growing and sympto-

Correspondence: Francois G. Kamar, Division of Hematology and Oncology, Clemenceau Medical Center, Beirut, Lebanon.
Tel. +961.334.8858 - Fax: +961.983.2600
E-mail: kamar@idm.net.lb

Key words: choroid plexus papilloma, malignant, bevacizumab, chemotherapy, antiangiogenic.

Contributions: the authors contributed equally.

Conflict of interests: the authors declare no potential conflict of interests.

Received for publication: 6 November 2013.

Revision received: 16 February 2014.

Accepted for publication: 26 February 2014.

This work is licensed under a Creative Commons Attribution NonCommercial 3.0 License (CC BY-NC 3.0).

©Copyright F.G. Kamar et al., 2014
Licensee PAGEPress, Italy
Rare Tumors 2014; 6:4687
doi:10.4081/rt.2014.4687

matic right CP angle metastasis and dorsal brain stem metastasis. Post-operative imaging revealed decrease size of the tumor. With remaining residual disease, the patient was referred to us for salvage treatment.

In this setting of previous craniospinal irradiation, significant chemotherapy toxicity, and only short-lived stabilization of the disease, bevacizumab was offered as single agent treatment in an attempt to spare the patient further toxicities. The first treatment was injected after 8 weeks from last surgery.

The patient received bevacizumab, 5 mg/kg on day 1 and day 15 of each cycle. Cycles were repeated every 4 weeks. Contrast enhanced MRI scans were obtained after the initial two treatments and every 2 cycles thereafter or sooner if required to assess new or worsening symptoms.

The patient was taken off steroids, which was started at first relapse, shortly after starting bevacizumab and did not receive steroids later during the course of her disease. Her symptoms immediately stabilized following the first cycle of bevacizumab and progressively improved. The headaches resolved, the mental status returned to normal, and the ataxia improved very slowly but her cervical pain and stiffness did not. She achieved radiological stabilization with significant decrease of the vasogenic edema, and minimal decrease in the size and enhancement of all metastatic lesions (Figures 2 and 3). This response continued for over 5 months of therapy. A total of five cycles of bevacizumab were administered (10 treatments). An elective cerebello-pontine angle

metastasis resection was opted to relieve her debilitating neck stiffness.

The postoperative course was complicated by respiratory failure requiring tracheostomy, although there was no evidence of disease progression. The patient died from pulmonary infection, in turn complicated by severe sepsis.

Discussion

Choroid plexus tumors typically grow within the choroid plexus tissue. A gross total resection is thought to be curative in CPP. Recurrences are infrequent and the prognosis is good.¹⁴ APPs represent a novel intermediate-grade subtype of CPT. Its clinical features and treatment outcomes have not been well established in the literature. Several studies have suggested that adjuvant therapy, radiation alone, or radiation along with chemotherapy decreases the incidence of local recurrence and improves long-term survival.¹⁵⁻¹⁷

Chemotherapy has been used with varied degrees of success. Pediatric protocols combining cisplatin and etoposide;² cyclophosphamide, cisplatin and Vincristine;¹² ifosfamide, carboplatin and etoposide,¹⁸ or more complex regimens,¹¹⁻¹³ such as the POG (alternating courses of cisplatin/etoposide and cyclophosphamide/vincristine, followed by radiation).¹² Nevertheless most series are very small, some are only limited to case reports and cannot lead to guidelines or therapeutic recommendations.

In this particular case, two lines of chemotherapy had failed, and poor marrow reserve secondary to craniospinal radiotherapy in an adult patient (36 Gy of craniospinal irradiation and 54 Gy to the cranium) prevented further delivery of cytotoxics. Furthermore she has received and failed two chemotherapy lines: single agent nitrosourea and combination of ifosfamide, carboplatin and etoposide.

Experts characterized CCPs with extraordinary degree of vascularity.¹⁹ Recent pathological findings identified most Atypical CCP to be highly vascularized lesions.²⁰ In addition to the vascularized nature of CCPs, the choice of therapy was based on the widely disseminated disease and the extensive vasogenic edema requiring high doses of steroids to maintain a good quality of life. Moreover, the lack of significant toxicities of bevacizumab made it somehow attractive. This option was discussed with the patient, who signed an informed consent, and was approved by the ethical committee of our institution.¹³

A lengthy literature search did not yield any case of choroid plexus tumors treated with bevacizumab; we are reporting the first case. Although there was only minimal radiological improvement, bevacizumab seems to have

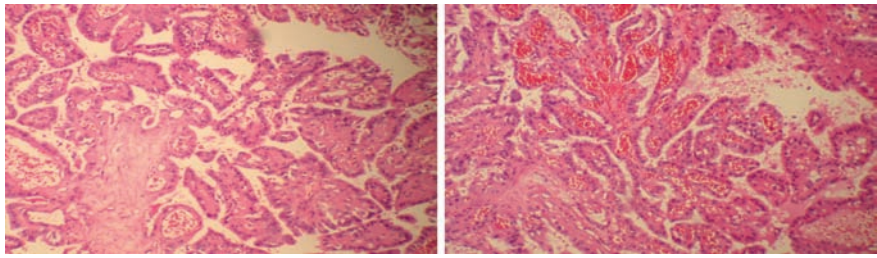


Figure 1. Choroid Plexus Papilloma with atypical features; there is mild to moderate cytological atypia, scattered mitoses and an elevated index of proliferation, but without definite features of malignancy such as cellular anaplasia, tumor necrosis, endothelial cell proliferation or high mitotic activity.

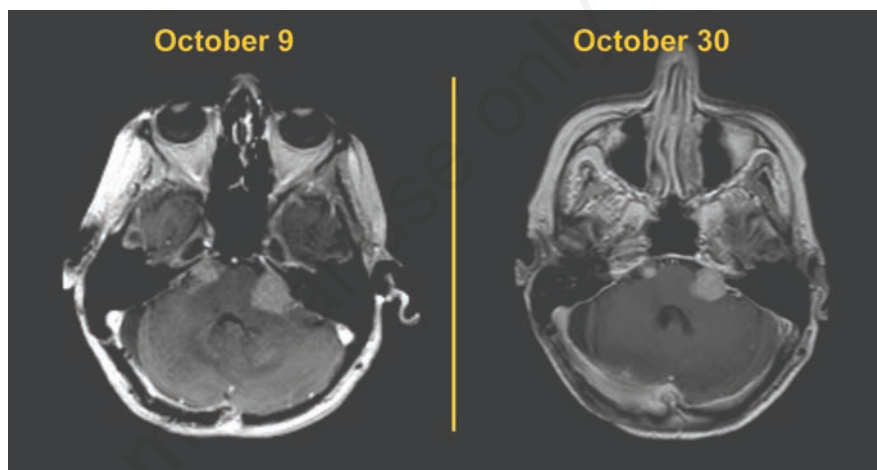


Figure 2. Post contrast T1-weighted axial images of the brain showing bilateral cerebellopontine angle drop metastases. The difference in technique accounts for the different image levels.

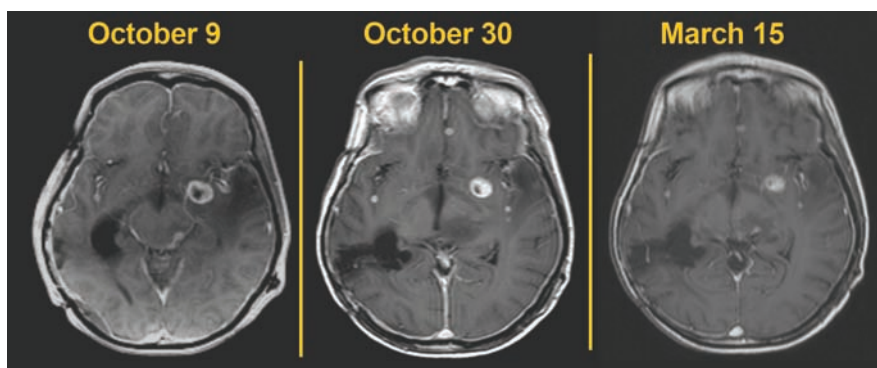


Figure 3. Post contrast T1-weighted axial images of the brain showing stable appearance of the metastases over 5 months of therapy. Despite the difference in technique between these imaging studies a minimal reduction in size of the tumor deposits can be noticed with additional therapy.

some activity in this subtype of richly vascularized tumors and may be worth further evaluation in combination with chemotherapy.

Conclusions

Single agent bevacizumab has achieved stabilization of the disease during the 5 months of therapy and three months later on off therapy. Cases of CPTs are scarce and there are no treatments guidelines. A multicenter collaborative trial combining bevacizumab to chemotherapy may be worth further evaluation for CPTs earlier during the treatment course.

References

1. Chow E, Jenkins JJ, Burger PC, et al. Malignant evolution of choroid plexus papilloma. *Pediatr Neurosurg* 1999;31:127-30.
2. Allen J, Wisoff J, Helson L, et al. Choroid plexus carcinoma-responses to chemotherapy alone in newly diagnosed young children. *J Neurooncol* 1992;12:69-74.
3. Horska A, Ulug AM, Melhem ER, et al. Proton magnetic resonance spectroscopy of choroid plexus tumors in children. *J Magn Reson Imaging* 2001;14:78-82.
4. Sarkar C, Sharma MC, Gaikwad S, et al. Choroid plexus papilloma: a clinicopathological study of 23 cases. *Surg Neurol* 1999;52:37-9.
5. Sharma R, Rout D, Gupta AK, Radhakrishnan VV. Choroid plexus papillomas. *Br J Neurosurg* 1994;8:169-77.
6. Rickert CH, Paulus W. Tumors of the choroid plexus. *Microsc Res Tech* 2001;52:104-11.
7. Leblanc R, Bekhor S, Melanson D, Carpenter S. Diffuse craniospinal seeding from a benign fourth ventricle choroid plexus papilloma. Case report. *J Neurosurg* 1998;88:757-60.
8. Yu H, Yao TL, Spooner J, et al. Delayed occurrence of multiple spinal drop metastases from a posterior fossa choroid plexus papilloma. Case report. *J Neurosurg Spine* 2006;4:494-6.
9. Wrede B, Liu P, Wolff JE. Chemotherapy improves the survival of patients with choroid plexus carcinoma: a meta-analysis of individual cases with choroid plexus tumors. *J Neurooncol* 2007;85:345-51.
10. Barreto AS, Vassallo J, Queiroz Lde S. Papillomas and carcinomas of the choroid plexus: histological and immunohistochemical studies and comparison with normal fetal choroid plexus. *Arq Neuropsiquiatr* 2004;62:600-7.
11. Uff CE, Galloway M, Bradford R. Metastatic atypical choroid plexus papilloma: a case report. *J Neurooncol* 2007;82:69-74.
12. Duffner PK, Kun LE, Burger PC, et al. Postoperative chemotherapy and delayed radiation in infants and very young children with choroid plexus carcinomas. The Pediatric Oncology Group. *Pediatr Neurosurg* 1995;22:189-96.
13. Greenberg ML. Chemotherapy of choroid plexus carcinoma. *Childs Nerv Syst* 1999;15:571-7.
14. McGirr SJ, Ebersold MJ, Scheithauer BW, et al. Choroid plexus papillomas: long-term follow-up results in a surgically treated series. *J Neurosurg* 1988;69:843-9.
15. Geerts Y, Gabreels F, Lippens R, et al. Choroid plexus carcinoma: a report of two cases and review of the literature. *Neuropediatrics* 1996;27:143-8.
16. Griffin BR, Stewart GR, Berger MS, et al. Choroid plexus carcinoma of the fourth ventricle. Report of a case in an infant. *Pediatr Neurosci* 1988;14:134-9.
17. Hashizume A, Kodama Y, Hotta T, et al. Choroid plexus carcinoma in the lateral ventricle-case report. *Neurol Med Chir (Tokyo)* 1995;35:742-4.
18. Noh CH, Yi JS, Lee HJ, Lee IW. Efficacy of preoperative chemotherapy in a choroid plexus carcinoma. *J Korean Neurosurg Soc* 2004;35:309-12.
19. Packer RJ, Perilongo G, Johnson D, et al. Choroid plexus carcinoma of childhood. *Cancer* 1992;69:580-5.
20. Lee SH, Park BJ, Kim EJ, Lim YJ. Atypical choroid plexus papilloma in an adult. *J Korean Neurosurg Soc* 2009;46:74-6.