

“ФУНДАМЕНТАЛЬНАЯ НАУКА В СОВРЕМЕННОЙ МЕДИЦИНЕ 2017”



**Сборник материалов
сателитной дистанционной научно-практической
конференции
студентов и молодых ученых**

УДК 61:001(043.2)

ББК 5:72

Ф 94

Рецензенты: докт. мед. наук, проф. Артишевский Н.И.; канд. мед. наук, доц. Беспальчук П. И.; канд. мед. наук, доц. Борис А.Н.; канд. мед. наук, доц. Борисенко Л.Г.; канд. мед. наук, доц. Борисова Т.С.; канд. мед. наук, доц. Буцель А.Ч.; докт. мед. наук, проф. Висмонт Ф.И.; канд. мед. наук, доц. Гриб В.М.; канд. биол. наук, доц. Замбржицкий О.Н.; канд. мед. наук, доц. Журавков Ю.Л.; канд. мед. наук, доц. Курак Т.А.; канд. мед. наук, доц. Логинова И.А.; канд. мед. наук, доц. Месникова И.Л.; канд. мед. наук, доц. Павлович Т. П.; докт. мед. наук, проф. Походенько-Чудакова И.О.; канд. мед. наук, доц. Романенко З.В.; канд. мед. наук, доц. Савченко М.А.; канд. мед. наук, доц. Солтан М.М.; канд. мед. наук, доц. Статкевич Т.В.; докт. мед. наук, проф. Терехова Т.В.; докт. мед. наук, проф. Трисветова Е.Л.; канд. мед. наук, доц. Хомич С.Ф.; канд. мед. наук, доц. Якубовский С.В.

Редакционный совет: Д.А. Соловьёв, А.Р. Сидорович, Е.В. Мовкаленко, А.В. Давидян, А.А. Рачинская, И. Ю. Пристром, Е.А. Подголина, С.Г. Лепешко, П.А. Парейко, Д.В. Парамонов

Фундаментальная наука в современной медицине 2017: материалы сателл. дистанционной науч.- практич. конф. студентов и молодых ученых / под. ред. А.В. Сикорского, О.К. Дорониной, Т.В. Горлачёвой, Ф.И. Висмонта - Минск : БГМУ, 2017 -

ISBN 978-985-567-689-9

Сборник содержит научные статьи, отражающие результаты собственных исследований молодых учёных и студентов, посвящённые актуальным вопросам современной медицины.

ISBN 978-985-567-689-9



УДК 61:001(043.2)

ББК 5:72

Ф 94

Кордунян А.Э. АНГИОТЕНЗИОРЕОПЛЕТИЗМОГРАФИЯ – СОВРЕМЕННЫЙ МЕТОД ДИАГНОСТИКИ И КОНТРОЛЯ ЛЕЧЕНИЯ БОЛЬНЫХ С АРТЕРИАЛЬНЫМИ ГИПЕРТЕНЗИЯМИ	147
Костенко М. К., Дороженкова Т.Е. ЭПИДЕМИЧЕСКИЙ ПРОЦЕСС ПЕДИКУЛЕЗА В ГОРОДЕ МИНСКЕ ЗА 2005-2016 ГОДА.....	152
Krechun ¹ Anastasiya, Mykchailenko ² Olga, Kovalev ¹ Vladimir PRIMARY SCREENING OF COMPOSITION OF IRIS HUNGARICA (WALDST ET KIT.) THE BIOLOGICAL ACTIVE SUBSTANCES	158
Курганская Ю.И., Гайдук А.Р., Саросек В.Г. ИСПОЛЬЗОВАНИЕ СОВРЕМЕННЫХ ТЕХНОЛОГИЙ ЛУЧЕВОЙ ДИАГНОСТИКИ В ОНКОЛОГИЧЕСКОЙ ПРАКТИКЕ	161
Khomko B.O.*, Randiuk R.Y., Khomko O.Y., Sydorhuk R.I., Knut R.P. MORPHOLOGICAL CHANGES IN PURULENT-NECROTIC PROCESSES OF SOFT TISSUES IN PATIENTS IN LOCAL APPLICATION OF SORBENT-ANTIBIOTIC COMPOSITION.....	166
Khomko B.O.*, Randiuk R.Y., Sydorhuk R.I., Kyfiak P.V., Khomko O.Y. AN EXPERIMENTAL STUDY FOR CALCULATING PATIENTS SEVERITY STATUS IN EMERGENCY SURGERY	170
Khomko B.O.*, Randiuk R.Y., Sydorhuk R.I., Kyfiak P.V., Khomko O.Y. ABDOMINAL SEPSIS AND ACUTE RESPIRATORY DYSFUNCTION.....	173
Лабузко А.В., Гомзякова М.А.* ПРИЧИНЫ РАЗВИТИЯ ГИДРОЦЕФАЛИИ У ДЕТЕЙ	176
Лойко В.С., Ланкевич Т.С., Дронина А.М., Бандацкая М.И., Рашкевич * И.И., Крамник ** Т.И. ДИНАМИКА ЭПИДЕМИЧЕСКОГО ПРОЦЕССА СКАРЛАТИНЫ В ПЕРВОМАЙСКОМ И ПАРТИЗАНСКОМ РАЙОНАХ Г. МИНСКА	182
Мазуркевич Д.А., Неверов П.С. ЭКСТРЕННАЯ МЕДИЦИНСКАЯ ПОМОЩЬ И ВОЗМОЖНОСТИ ОТСРОЧЕННЫХ ВМЕШАТЕЛЬСТВ ПРИ КРОВОТЕЧЕНИЯХ ИЗ ВАРИКОЗНО РАСШИРЕННЫХ ВЕН ПИЩЕВОДА.....	188

Khomko B.O., Randiuk R.Y., Khomko O.Y., Sydoruk R.I., Knut R.P.*

MORPHOLOGICAL CHANGES IN PURULENT-NECROTIC PROCESSES OF SOFT TISSUES IN PATIENTS IN LOCAL APPLICATION OF SORBENT-ANTIBIOTIC COMPOSITION

Higher education institution in Ukraine "Bukovinian State Medical University"

Department of General Surgery

**RMI "Emergency Hospital"*

Chernivtsi, Ukraine

Ключевые слова: гнойно-некротические процессы, морфологические изменения, местный сорбент.

Аннотация. Местное применение композиции сорбент-антибиотик, приводит к сокращению продолжительности фазы экссудации и активно снижает размер раневой поверхности и улучшает формирование новых грануляционных тканей, при этом деструкция и лизис вновь образованного эпителия отсутствуют.

Keywords: purulent-necrotic process, morphological changes, local sorbent.

Abstract. Local use of sorbent-antibiotic composition reduce the duration of exudation phase and actively reduce wound surface and formation of new granulation tissue, destruction and lysis of newly formed epithelium is absent.

Introduction. Treatment and prevention of inflammatory diseases of the soft tissue and postoperative inflammatory complications of inflammatory origin remains one of the most important tasks in modern surgery [1, 2]. Local treatment of purulent necrotic processes (PNP) of soft tissues remains extremely difficult, especially under the burdened status of patients with dysmetabolic disorders, such as diabetes mellitus, disorders of blood circulation and influence of other factors inhibiting regenerative and reparative processes and contributing to the development of infection [3,4].

It is known that the most powerful local treatment of patients with PNP loses its effectiveness if it is not combined with technologies that help clean purulent wound and create favorable conditions for regenerative processes [5]. Thereby there should be found local treatments that would have absorptive and antibacterial properties.

The aim of this study is to determine local morphological changes of purulent necrotic processes of soft tissue in patients under local use of sorbent-antibiotic composition.

Tasks: 1. Determine local morphological changes of purulent necrotic processes of soft tissue in patients under local use of sorbent-antibiotic composition.

Material and methods. The object of study is the marginal zone biopsies of skin wounds of purulent necrotic processes of soft tissue in target patients. A comprehensive pathologic study includes biopsy material of 215 cases of surgical treatment of PNP. The main group consisted of 120 (55.8%) patients, who along with common treatment locally received applications of sorbent-antibiotic composition in exudation phase. The control group consisted of 95 (44.2%) patients with common treatment according to existing protocols. Both groups did not differ significantly by age and sex composition. General treatment in both groups was similar. Complied with the re-

quirements of bioethics, all patients signed informed consent application forms to participate in the study.

To assess the evolution of wound healing in all patients, dynamics of reduction of wound surface and formation of new granulation tissue was studied, and morphopathologic monitoring of the wound healing was carried out. Histological sections were studied, analyzed and photographed by means of image analysis-based computer system consisting of a light microscope Olympus CX-21 and digital camera Olympus C 450.

Complex of histometric research was applied. Volumetric density of irreversibly damaged tissue, edematous fluid, vascular capillary bed, leukocyte infiltration of fibrous, epithelial, muscle and adipose tissues indices were calculated. Measurements were carried out using a computer image analysis system (Image Tools 2.1.2 software). Statistical processing of the results was carried out by methods of variation statistics using the Statistica 7.0 software package.

Results and discussion. Tissue samples (biopsates) of the wound edges at the time of administration of the patients to the hospital, and primary surgery, and at 3rd, 6th, 9th and 15th day after initiation of treatment were examined. On the background of necrotic changes, elements of granulation tissue in the form of short thin strands of proliferating fusiform fibroblasts, accompanied by capillaries were observed, while in 61 (28.4%) patients no such phenomena were present. At a distance of 0.1-0.3 mm from the edges of the wound the phenomenon of regeneration of the epidermis in small thin layers of newly formed keratinocytes was observed. In both investigated groups there was histologically determined reduction of edema, cellular infiltration, microcirculatory disorders in the marginal zone in the dynamics of wound treatment.

At 6th day after starting treatment, mature granular tissue in biopsies was found. It consisted of a large number of vascular loops, oriented perpendicular to the wound surface, and numerous strands of fibroblasts (Fig. 1).

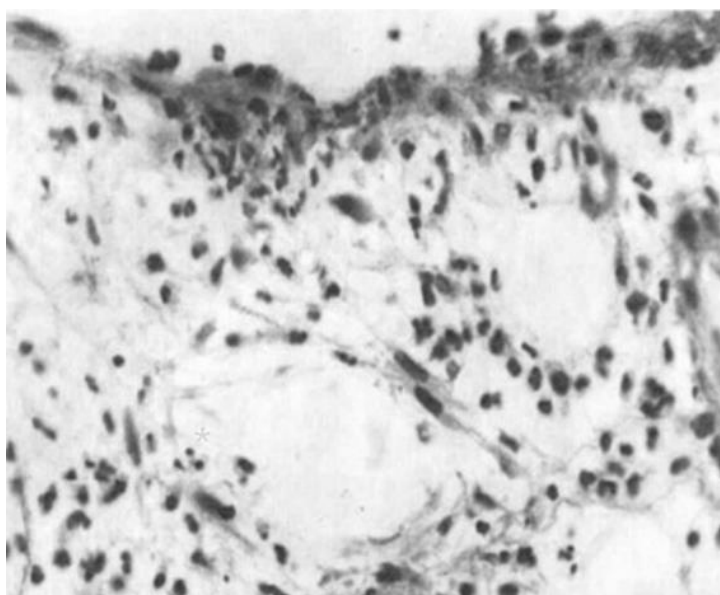


Fig. 1 Boundary wounds' zone. 3^d day of treatment. Neoangiogenesis. 3rd day of treatment. Formation of granulous tissue. Coloration: hematoxylin and eosin, $\times 400$.

Thin-walled vessels were located evenly throughout the granular tissue, almost of the same diameter. Vascular network occupies $16,6 \pm 1,5\%$ of regenerate. Among fibroblasts, mitotic cells were discovered. Swelling significantly decreased, although we have not seen abundant leukocyte infiltration in regenerate. A characteristic feature was the discovery of large number of mast cells in granular tissue and in the dermis of adjacent intact skin unlike in the control group, where they were more evident.

Meanwhile, in the control group by 6th-9th day the affected area remained with swelling and neutrophilic infiltration of tissues, with the spread of necrotic changes of hypodermis and adjacent skeletal muscle in some cases, which can be interpreted as a sign of prolonged exudative phase of inflammation (Fig. 2).

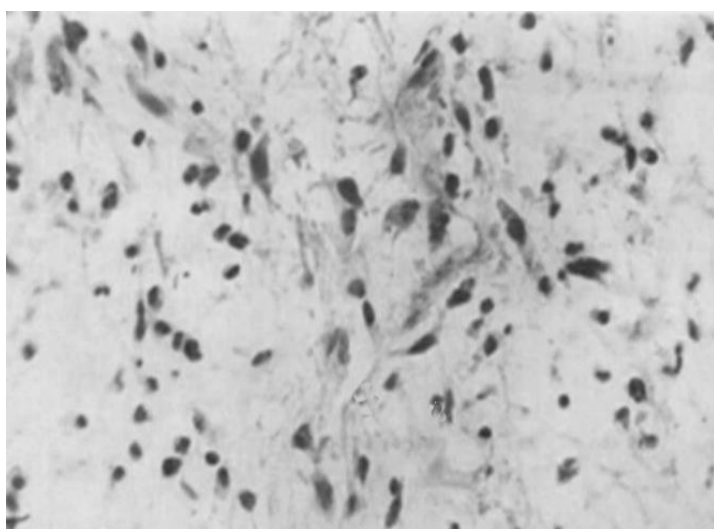


Fig. 2 Boundary wounds' zone. 6th day of treatment. Neoangiogenesis. Formation of delicate fibrous stroma. Coloration: hematoxylin and eosin, $\times 400$.

Microcirculatory disorders were expressed in the form of venules plethora, phenomena of capillarostasis, erythrocytes hemolysis and regional clotting elements formed in venules and capillaries. Vascular network occupies $11,7 \pm 1,0\%$, but vascular loops were irregularly arranged and in different in size.

At 15th day there was active epithelialization of the wound defect, and if at the edge of the deffect in control group there was not more than two layers of cells, in the main group up to 4 layers were found. A newly formed layer covered the wound surface from the preserved skin. Epithelium formed characteristic light layers of cells with broad cytoplasm. Fibroblasts with mitosis (Fig. 3) can be seen in the dermis.

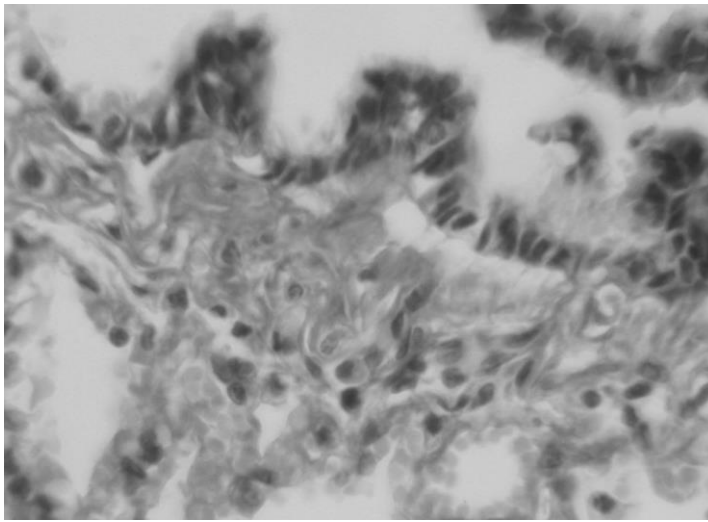


Fig. 3 Boundary wounds' zone. 15th day of treatment. The initial (boundary) epithelization. Mature granulation with the presence of collagen fibers. Color: trichrome by G. Gömöri, × 400

The appearance of destruction and lysis of newly formed epithelium was observed in the comparison group, which we have not seen in the main group. The formation of granulation tissue in the control group in comparison is slow, in the form of amorphous formation of connective tissue, whereas in the main group, this process occurs uniformly throughout the lesion with the formation of classic granulation.

Conclusions. 1. Under the local treatment of purulent necrotic processes of soft tissue in patients with complicated general condition in both groups we histologically determined reduction of edema, cellular infiltration, microcirculatory disorders in the marginal area of the wound in the dynamics of treatment. 2. Use of local sorbent-antibiotic composition reduced duration of exudation phase, actively reduced the wound surface and caused formation of new granulation tissue ($p < 0.05$), no destruction and lysis of newly formed epithelium was observed

Literature

1. Fonder M.A. Treating the chronic wound: A practical approach to the care of nonhealing wounds and wound care dressings / M.A. Fonder, G.S. Lazarus, A.J. Mamelak [et al.] // *J. Am. Acad. Dermatol.* – 2008. – Vol. 58, № 2. – P. 185-206.
2. Mekkes J.R. Causes, investigation and treatment of leg ulceration / J.R. Mekkes, M.A.M. Loots, A.C. van der Wal, J.D. Bos // *British Journal of Dermatology.* – 2003. – Vol.148. – P. 388-401.
3. Morino R.J. Interactive Dressings and Topical Agents / R.J. Morino, N.L. Tomaselli // *Clinics in Plastic Surgery.* – 2007. – Vol. 34. – P. 643-658.
4. Puri V. Trophic ulcers – Practical management guidelines / Vinita Puri, N Venkateshwaran, Nishant Khare // *British Journal of Dermatology.* – 2012. – Vol.45. – P. 340-351.
5. Skorkowska-Telichowska K. The local treatment and available dressings designed for chronic wounds / K. Skorkowska-Telichowska, M. Czemplik, A. Kulma, J. Szopa // *J. Am. Acad. Dermatol.* – 2011. – Vol. 6. – P. e1-e10.