
Оригінальні дослідження

© Akhtemiichuk Yu.T., Slobodian O.M., Skoreiko P.M.

UDC 611.342.013-07

CHARACTERISTICS OF DUODENAL MORPHOGENESIS DURING THE PERINATAL PERIOD***Yu.T.Akhtemiichuk, O.M.Slobodian, P.M.Skoreiko****Department of Anatomy, Topographic Anatomy and Operative Surgery (Head – Prof. Yu.T.Akhtemiichuk) of Bukovinian State Medical University, City of Chernivtsi*

ОСОБЛИВОСТІ МОРФОГЕНЕЗУ ДВАНДЦЯТИПАЛОЇ КИШКИ В ПЕРИНАТАЛЬНОМУ ПЕРІОДІ

Резюме. Методами анатомічного дослідження встановлено, що типовою формою дванадцятипалої кишки у перинатальному періоді є кільцеподібна. Починаючи з 7-го місяця внутрішньоутробного розвитку, чітко диференціюються тканинні шари кишкової стінки. Упродовж перинатального періоду для дванадцятипалої кишки властиві два періоди прискореного розвитку (5 і 8-10 місяці) та період сповільненого розвитку (6-7 місяці).

Ключові слова: дванадцятипала кишка, анатомія, перинатальний період.

In recent years researchers concentrate their attention on the diagnosis and treatment of congenital malformations of the digestive organs that require surgical treatment [1, 2]. Within the mortality pattern of children with surgical diseases the share of lethal sequelae reaches 90% [3]. Particular attention is given to timely perinatal diagnostics which permits to determine a policy of pregnancy management [4]. An expansion of anatomic investigations of man during the perinatal period of ontogenesis is a bare necessity since numerous diseases of children and adults are etiologically linked with the intrauterine period of the development [5].

Bibliographical findings, dealing with the consistent patterns of the structure of the duodenum during the perinatal period are fragmentary, not numerous and unsystematic. They deal mainly with a study of the anatomy of the duodenum of a certain age group or embryonal transformations at the early stages of the development [6-8]. The absence of papers, concerning an evaluation of the dynamics of the morphometric parameters of the duodenum during the perinatal period de-

termine the topicality of the research.

This particular research is a fragment of a planned scientific research of Bukovinian State Medical University entitled "Sex-age-related regularities of the structure and topographo-anatomical interrelations of the organs and structures during human ontogenesis. The specific characteristics of age and sex-related embryotopography" (№ 0105U002927).

The object of the research. To establish standard and variant anatomy and correlations of the morphometric parameters of the duodenum during the perinatal period of human ontogenesis.

Material and methods. The study was carried out on 120 specimens of fetuses and newborn infants *in situ*, using the methods of macromicrodissection, preparation of consecutive microscopic sections, roentgenography, morphometry. A statistical analysis of the obtained findings was carried out by means of computerized programs "Statgraphics", "Excel 7.0" and "Statistica".

Research results and their discussion. A chronological order of spatio-temporal transformations of organs and structures, exerting a

syntopic effect on the forming of the topography and form – building of the duodenum, in particular, the visceral surface of the liver, the head of the pancreas, the kidneys, the sigmoid colon has been traced in the perinatal period of the development.

Taking into account a marked character of the anatomical portions of the duodenum in the perinatal period, the presence of the principal 4 forms of the organ has been corroborated by us. The typical form of the duodenum is annular that is observed in $64\pm 5\%$ of cases. V – ($16\pm 1\%$) and C – like ($11\pm 3\%$) forms of the colon are less common, the least common is a U – shaped variant ($8\pm 2\%$). With the development of fetuses the number of cases of the ring – shaped and C – shaped forms decreases, that of the U – shaped one increases, whereas the V – shaped form has almost identical percentages throughout the perinatal period of ontogenesis (Fig 1).

A relation to the peritoneum of the anatomical parts of the duodenum throughout the perinatal period changes. A retroperitoneal localization of the duodenum is characteristic of early fetuses (4-5 months), except the upper portion and duodenojejunal flexure. In 6-10 month old fetuses and newborns the upper portion, the superior and duodenojejunal flexures are more often located intraperitoneally, the

upper third or half of the descending portion and the ascending portion of the duodenum – mesoperitoneally, the rest – retroperitoneally.

The skeletotopical projection of the duodenum in the perinatal period is changeable. The upper portion of the duodenum is displaced cranially by one intervertebral space (in early fetuses it corresponds to the superior margin of vertebra Th₁₂, in late fetuses – to the inferior margin of vertebra Th₁₁) the lower part of the duodenum is displaced caudally by the height of the vertebral body and two intervertebral spaces up to the level of the L₂ vertebra.

According to our findings the villi of the mucous membrane of the duodenum are clearly revealed, starting from the 7th month of the development. At the end of the 5th month single primary crypts are observed. The epithelium in 6-7 month old fetuses is well developed, representing an enterocyte of a cubical or cylindrical form. Transparent and distributed irregularly goblet cells are located in the mucous membrane of 8-10 month old fetuses. The number of cells in the mucous tunic of the duodenum increases with the development of fetuses. Starting from the 6th month the proper mucous plate of the mucous tunic is well marked. The number of blood vessels in the submucous layer increases as fetuses develop. Isolated Brunner's glands in the submucous

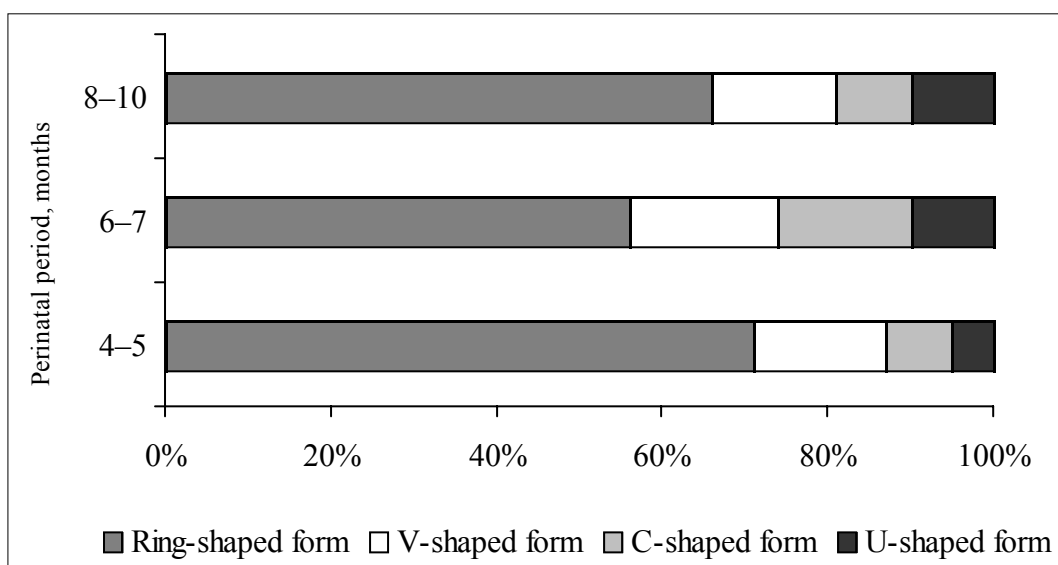


Fig. 1. Dynamics of changes of the duodenal forms during the perinatal period of ontogenesis.

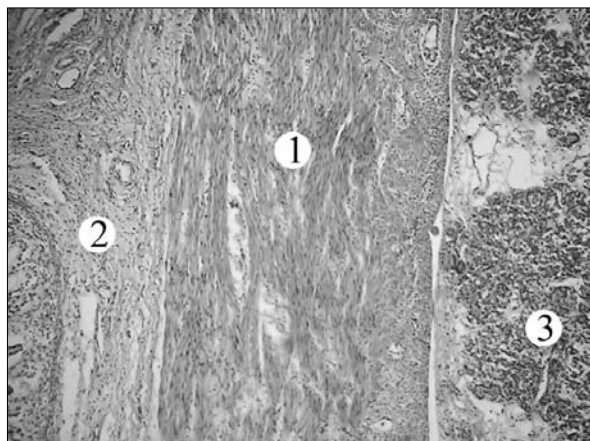


Fig. 2. A longitudinal section of the duodenal wall of a fetus 410.0 mm of the parietocalcaneal length. Staining with hematoxylin and eosin. A microscopic specimen. Ob. 3.5 \times , oc. 10 \times : 1 – the muscular tunic; 2 – the submucous layer; 3 – the pancreas.

layer are revealed in 7 month old fetuses which embrace practically the entire thickness of the submucous layer at the end of the fetal period.

The circular and longitudinal layers are differentiated in the muscular tunic of the duodenum. If the longitudinal layer in 4-7 month old fetuses is interrupted sometimes, then it is of almost identical thickness with the circular one in 8-10 month old fetuses (Fig. 2). A feebly marked character of the serous tunic of the duodenum is characteristic of 4-5 month old fetuses, in 6-10 month old fetuses and newborns it contains a great number of connective tissue fibers and blood vessels. A fusion of the serous membrane of the duodenum with the glandular capsule is observed in the region of a close contiguity of the pancreas to the duodenum.

On the basis of the obtained findings we have singled out two periods of an accelerated development of the duodenum (months 5 and 8-10) and a period of their slowed down development (months 6 and 7). A relatively delayed development in 6- and 7 month old fetuses is not intrinsic to all, but only to 50 % of the stu-

died morphometric parameters of the anatomical parts of the duodenum.

Direct correlation dependencies of the parietocalcaneal length of the body with the diameters and lengths of the body with the diameters and lengths of different anatomical parts of the duodenum stipulated by an identical speed of the biosynthetic processes of the morphometric parameters of the duodenum and the body as a whole have been established throughout the entire perinatal period.

In the process of the research direct correlation dependencies between the morphometric parameters of different anatomical parts of the duodenum during the perinatal period of ontogenesis point out to a considerable degree of integration and essential synergism of an accelerated and slowed down development of the structures under study.

Conclusions. 1. A typical form of the duodenum during the perinatal period of human ontogenesis is circular (64 \pm 5 %). 2. Histologically the wall of the duodenum at the beginning of the perinatal period (4-5 months) is characterized by the presence of primary crypts and the muscle plate of the mucous tunic, a diverse thickness of the layers of the muscular coat; the villi of the mucous membrane, goblet cells, Brunner's glands in the submucous layer, an almost identical thickness of the layers of the muscular tunic take shape in the duodenum of 8-10 month old fetuses and newborns. 3. Two periods of an accelerated development (months 5 and 8-10) and a period of a retarded development (months 6-7) are intrinsic to the duodenum during the perinatal period.

Outlooks of further research. It is expedient to determine the topographo-anatomical characteristics of the papillary segment of the duodenum in fetuses and newborns.

References

1. Natural history of experimental intestinal atresia: morphologic and ultrastructural study / S.M.Baglaj, J.Czernik, J.Kuryszko [et al.] // *J. of Pediatric Surg.* – 2001. – V. 36, № 9. – P. 1428-1434.
2. Bueno J. Analysis of patients with longitudinal intestinal lengthening procedure referred for intestinal transplantation / J.Bueno, J.Guiterrez // *J. of Pediatric Surg.* – 2001. – V. 36, № 1. – P. 178-183.
3. Давиденко В.Б. Ефективність та діагностичне значення

пренатального дослідження плода у покращенні наслідків лікування вродженої патології травного тракту у періоді новонародженості / В.Б.Давиденко, В.В.В'юн, Н.Р.В'юн // *Ультразвук. перинат. діагностика.* – 2005. – № 20. – С. 127. 4. Торлопова В.А. Алгоритм антенатальной диагностики и тактики при пороках развития пищеварительного тракта / В.А.Торлопова // *Дет. хирургия.* – 2006. – № 4. – С. 19-22. 5. Ахтемійчук Ю.Т. Нариси ембріотопографії / Ахтемійчук Ю.Т. – Чернівці: Вид. дім "Букрек", 2008. – 200 с. 6. Ахтемійчук Ю.Т. Ембріотопографічні взаємовідношення дванадцятипалої кишки з органами та структурами черевної порожнини / Ю.Т.Ахтемійчук // *Таврич. мед.-биол. вестн.* – 2002. – Т. 5, № 3. – С. 23-25. 7. Становление топографии внутренних органов человека в раннем плодном периоде как отражение их структурных преобразований / Л.М.Железнов, Э.Н.Галева, С.В.Лисицкая [и др.]: матер. междунар. науч. конф., посв. 450-летию города Астрахани // *Астрах. мед. ж.* – 2007. – Т. 2, № 2. – С. 76. 8. Цивковский А.А. Формы двенадцатиперстной кишки человека и их топографическое положение / А.А.Цивковский // *Biomedical and Biosocial Anthropology.* – 2007. – № 9. – С. 271.

ОСОБЕННОСТИ МОРФОГЕНЕЗА ДВЕНАДЦАТИПЕРСТНОЙ КИШКИ В ПЕРИНАЛЬНОМ ПЕРИОДЕ

Резюме. Методами анатомического исследования установлено, что типичной формой двенадцатиперстной кишки в перинатальном периоде есть кольцевидная. Начиная с 7-го месяца внутриутробного развития, четко дифференцируются тканевые слои кишечной стенки. На протяжении перинатального периода для двенадцатиперстной кишки характерно два периода ускоренного развития (5 и 8-10 месяцы) и период замедленного развития (6-7 месяцы).

Ключевые слова: двенадцатиперстная кишка, анатомия, перинатальный период.

CHARACTERISTICS OF DUODENAL MORPHOGENESIS DURING THE PERINATAL PERIOD

Abstract. It has been established by means of the methods of an anatomical research that a ring-shaped form is typical of the duodenum during the perinatal period. Starting from the 7th month of the intrauterine development the tissue layers of the duodenal wall are clearly differentiated. Two periods of an accelerated development (months 5 and 8-10) and a period of a slowed down development (months 6-7) are characteristic of the duodenum throughout the perinatal period.

Key word: duodenum, anatomy, perinatal period.

Bukovinian state medical university (Chernivtsi)

Надійшла 02.03.2009 р.

Рецензент – проф. М.С.Гнатюк (Тернопіль)

© Akhtemiichuk Yu.T., Slobodian O.M., Skoreiko P.M.