

# DEEP BRAIN STIMULATION SYMPOSIUM

## INTRAOPERATIVE NEUROPHYSIOLOGY AND RESULTS IN DYSTONIA AND OTHER MOVEMENT DISORDER PATIENTS TREATED WITH GPI DBS

Jay Shils

Lahey Clinic, Intraoperative Monitoring Department of Neurosurgery, Burlington, USA

Dystonia is a neurological movement disorder characterized by sustained muscle contractions which can cause twisting, repetitive movements, or abnormal postures. Dystonia may become a cause of severe motor disability and even in some cases (with the so - called “dystonic storms”) life-threatening. Dystonia may be hereditary or caused by other factors such as trauma, infection, poisoning or reaction to pharmaceutical drugs, particularly neuroleptics. Treatment is difficult and has been limited to minimizing the symptoms of the disorder, since there is no cure available. Surgical approaches to the treatment of dystonia have been around since the 1950’s.

In the early 1950’s Dr. Irving Cooper accidentally ligated the anterior choroidal artery in a Parkinson’s (PD) patient, when the patient awoke from surgery their Parkinsonian symptoms were dramatically reduced. When Dr. Cooper investigated possible causes for the surgical outcome he noted that the basal ganglia, and more specifically the internal Globus Pallidum, is supplied by the anterior choroid artery thus opening the door to modern pallidotomy. During Dr. Cooper’s Parkinson’s surgery he noticed that not only were the main symptoms of PD (Tremor, Rigidity, and Bradykinesia) reduced, the patient dystonic movement was also dramatically reduced. Dr. Cooper then started to operate on Dystonia patients with very good results<sup>1</sup>. Not only did Dr. Cooper investigate pallidal lesions, he and others also placed lesions in the ventral thalamus, as well as placing electrodes into the cerebellum and other target motor areas of the basal ganglia for stimulation treatment of dystonia with limited success<sup>2</sup>. With the advent of Levodopa and the lack of true investigations into the benefits of these procedures surgery for movement disorders started to decline in the late 1960’s until the mid 1980’s when the first true Parkinsonian model

was developed<sup>3</sup>. With a better understanding of the basal ganglia’s role in movement and the effect of lesions in various nuclei, surgery for movement disorders gained a second wind. Modern DBS for dystonia started almost as immediately as PD treatments, but primary credit for the GPi DBS for dystonia can go to a group in Montpellier with their publications on results, especially in DYT-1 dystonias<sup>4</sup>.

Surgical treatment of dystonia not only requires the targeting of the internal globus pallidum (GPi), which is not difficult with modern MRI scanners, but also making sure that the electrode goes to the proper functional area inside that nucleus, which is not visible, even on the 3 and higher Tesla magnets. Intra-operatively this is done using some form of neurophysiological testing. This testing may take the form of stimulating at the target and observing the patients for specific evoked responses. Another localization technique, and the one used at the Lahey Clinic, involves recording single units as a microelectrode (10 to 50  $\mu\text{m}$  at the tip) is advanced from above the target to just past the target and characterizing the recordings based on the knowledge of the firing patterns of the single units in the area. As the figures below shows, not only do the different nuclei in the brain have different firing characteristics, different diseases also have different firing characteristics. (Figs. 1 and 2).

This lecture will present specific case examples of a dystonia patient treated with DBS as well as an overview of the intraoperative neurophysiological localization methodology for proper DBS placement in the GPi for dystonia patients.

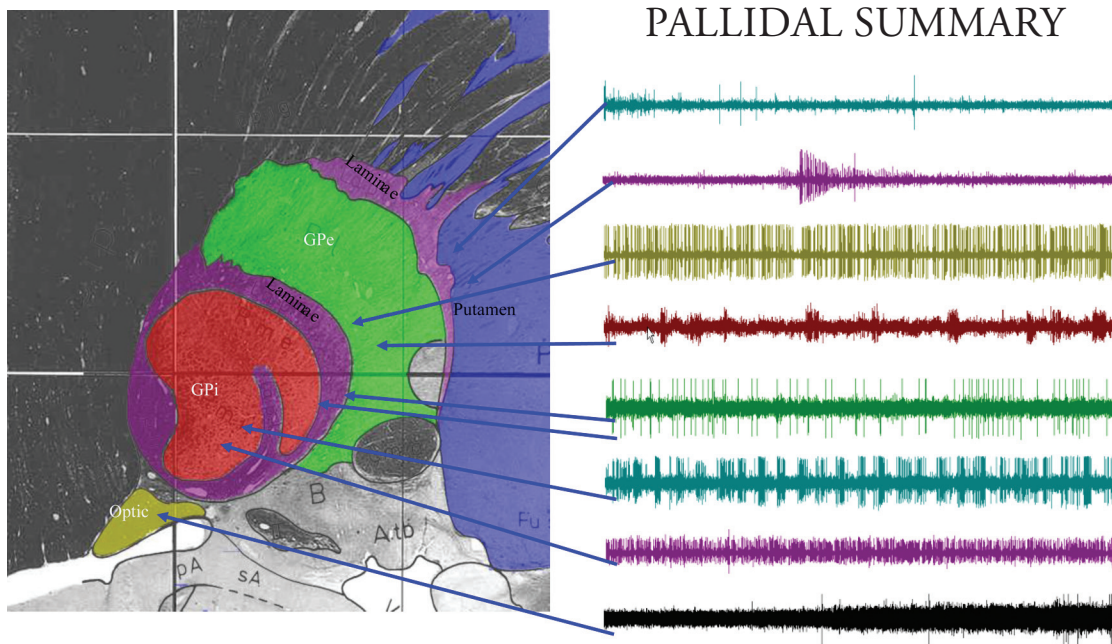


Fig. 1 Firing characteristics of the GPi and related structures encountered during procedures involving the placement of a DBS electrode in the GPi




Fig 2. GPi recordings in four different diseases. Note that in the status dystonicus patient propofol was used to minimally sedate the patient.

#### References:

1. Cooper IS. 20-year follow-up study of the neuro-surgical treatment of dystonia musculorum deformans. *Adv. Neurol.*, 1976, 14 : 423.
2. Cooper IS, Upton ARM, Amin I. Chronic cerebellar stimulation (CCS) and Deep brain stimulation (DBS) in Involuntary movement disorders. *Appl. Neurophysiol.*, 1982, 45:209-217.
3. Alexander GE, DeLong MR, Strick PL. Parallel organization of functionally segregated circuits linking basal ganglia and cortex. *Annual Review of Neuroscience*, 9:357-81, 1986.
4. Coubes P, Roubertie A, Vayssiere N, Hemm S, Echenne B., 2000, Treatment of DYT1-generalised dystonia by stimulation of the internal globus pallidus. *Lancet*, 355: 2220-2221.