

Pathophysiology of Osteonecrosis of the Jaw in Patients Treated with Bisphosphonate

Tomislav Badel¹, Ivana Savić Pavičin², Andreja Jelinić Carek³, Kata Rošin-Grget⁴ and Đurđica Grbeša⁵

¹ University of Zagreb, School of Dental Medicine, Department of Removable Prosthodontics, Zagreb, Croatia

² University of Zagreb, School of Dental Medicine, Department of Dental Anthropology, School of Dental Medicine, Zagreb, Croatia

³ University of Zagreb, School of Dental Medicine, Department of Fixed Prosthodontics, Zagreb, Croatia

⁴ University of Zagreb, School of Dental Medicine, Department of Pharmacology, School of Dental Medicine, Zagreb, Croatia

⁵ University of Zagreb, School of Medicine, Department of Histology and Embryology, Zagreb, Croatia

ABSTRACT

Apart from the well-known mechanism of bisphosphonates' cellular effect, embryonic development and the specific features of alveolar bone homeostasis have been discussed. The unique ethiopathogenic mechanism which relates osteonecrosis of the jaw and bisphosphonates treatment has not been explained. The emphasis lies on the toxicological effects of bisphosphonates on the physiology of the alveolar bone and on the lasting effect of tooth extraction followed by an infection of the extraction wound and consequent progression into deeper layers of osseous tissue. Epithelial infection includes microbiological findings of Actinomyces species. The risk is pronounced in oncological patients treated with bisphosphonates intravenously in relatively large doses and during a longer period of time, especially with highly potent nitrogen-containing bisphosphonates pamidronate and zoledronate. This review of bisphosphonate-related osteonecrosis of the jaw stresses the significance of some other risk factors (corticosteroids, chemotherapy, tumour tissue etc.) of necrosis development – more precisely of osteomyelitis of the jaw if the microbiological component of the diseases has been taken into account, while the role of the bisphosphonates becomes minor. There is no gold standard for the treatment of jaw osteonecrosis; rather, palliative and minimally invasive treatment is applied, without subsequent oral surgical interventions. Since there is a significant risk of jaw osteonecrosis in oncological patients, the level of oral health is an important factor for the indication of intravenous bisphosphonates treatment.

Key word: bisphosphonates, osteonecrosis, jaw, pathophysiology, embryology

Introduction

Since 2003, when the special subtype of osteonecrosis, which develops on jaw bones after use bisphosphonates (BPs) and is therefore called BPs-related osteonecrosis of the jaw (BRONJ), was first identified, it has become a public health issue¹. The aim of the paper is to review current scientific facts which explain the causal relationship between the onset of jaw osteonecrosis and the effects of BPs.

Bone Homeostasis

In the course of embryonic development, mineralisation of non-mineralised osseous tissue occurs via intramembranous and endochondral ossification. Intramem-

branous ossification is mineralisation of osteoids as young non-mineralised bone originating from the primitive connective tissue (mesenchyme) without the presence of cartilaginous tissue. Endochondral ossification is the formation of the osteoid within a hyaline cartilage model. It is typical for long bones and bone matrix replaces the cartilage model. Primary centre of ossification develops in the central part of the diaphysis and subsequently, the secondary centres of ossification develop in epiphysis. Process of bone elongation occurs at ossification centres' junction via the still present cartilage which is called epiphyseal growth plate and at the same time, the whole skeleton develops²⁻⁴.

Bone mineralisation of the mandible occurs via two types of ossification of the base of one mesenchymal bone originating from the neural crest cells. A major part of the mandible, including the alveolar bone is ossified intramembranously and laterally from the first branchial arch cartilage (Meckel's cartilage). A carrot shaped cartilaginous condyle wherein the endochondral type of ossification occurs in a later phase is placed posteriorly. The bones of the membranous viscerocranium including the maxillary bone develop exclusively by intramembranous ossification from the maxillary process of the first pharyngeal arch^{5,6}.

Formation and resorption are two opposing processes of continuous internal remodelling and renewal of the bone tissue throughout adult life. Mineralised bone tissue is continually remodelled by the action of the basic multi-cellular unit². Osteoblasts, cells responsible for the formation of new bone together with osteoclasts, cells responsible for the resorption of the existing bone, opposing each other in their effects, but still within a complex system of mutual signals (cross-talk), are directly important for the understanding of BPs' effects^{7,8}.

In the physiological bone-renewal cycle, the osteoclast begins the bone resorption process, in response to the parathyroid hormone and occupies a shallow concavity called Howship's lacuna^{2,3}. In the initial phase (called according to Matsuo and Irie⁸, non-differentiated hematopoietic stem cells (monocytes/macrophages) are recruited into osteoclast precursors. The presence of cell surface receptors called receptor activator of nuclear factor kappaB ligand (RANKL) and monocyte-colony stimulating factor (M-CSF) is necessary for the regulation of osteoclastogenesis maturation as well as for osteoclasts' function as giant multinucleated cells^{2,9,10}.

RANKL is a cytokine (transmembrane glycoprotein) and the essential osteoclastogenic ligand which belongs to tumour necrosis factor ligand family. RANKL is produced by stromal cells, especially by bone lining cells. RANKL attaches itself to RANK (receptor activator of nuclear factor kappaB), a receptor on the cell surface of osteoclasts and osteoclast precursors, in order to stimulate proliferation and differentiation of cells to form the osteoclast phenotype and also to inhibit apoptosis. Bone lining cells belong to the fully differentiated osteoblasts which are situated on the bone surface. Unlike osteoblasts, which are cuboidal and produce M-CSF, the bone lining cells are flat and are not bone-forming⁸⁻¹⁰.

Osteocytes are embedded in the bone matrix and belong to the osteoblast lineage. Osteocytes are considered to be the mechanosensors of bone tissue. Bone lining cells transmit the majority of mechanical signals to osteocytes. Bone remodelling takes place in response to osteocyte apoptosis due to microcrack damage or lack of mechanical loading. There is a correlation between osteoclastogenesis and both osteoblast lineage cells – osteocytes and osteoblasts: osteoclastogenesis is regulated by RANKL-expressing osteoblasts and RANK-expressing osteoclast precursors. The catabolic effects of RANKL are prevented by osteoprotegerin (OPG), a key modulator

of activation of RANK by RANKL. OPG binds RANKL and thereby prevents activation of RANK. The osteoclast actively resorbs bone by developing a ruffled border on its surface to the bone surface. The formation of this folded membrane is caused by massive hydrochloric acid (to a pH of 1) secretion in the area of Howship's lacuna for demineralisation of apatites. The organic matrix is degraded by specific enzymes (eg. proteases like cathepsin K)^{2,8,11}.

During the transition phase osteoclasts induce osteoblast differentiation by producing membrane-bound molecules, such as cytokine transforming growth factor. It is believed that the released calcium binds to polyphosphates in the course of osteoclastic bone resorption since it is a biologically available reservoir of high-concentration calcium and orthophosphates which are necessary for the further process of bone remodelling. The phosphoanhydride bond (P-O-P) enables the hydrolytic polyphosphate degradation at neutral pH, the degradation of which enables the precipitation of free calcium into the newly-formed apatites. In the transition phase osteoclastic bone resorption is stopped because osteoclasts undergo apoptosis in Howship's lacuna¹².

While bone resorption lasts about 3 weeks, the termination phase develops slowly, about 3 months. The osteoclasts differentiation is suppressed in this phase, mostly through OPG secreted by osteoblasts. After the formation of an osteid within the resorbed lacuna by osteoblasts, osteocytes are differentiated within the young bone whereas osteoblasts transform into flattened bone lining cells^{8,13}.

BPs

BPs are analogues of pyrophosphates, wherein the carbon atom (P-C-P) is the geminal atom of the molecule in the phosphate-etheric chain, which makes them resistant to hydrolysis and also to the effects of pyrophosphatase in a cellular medium (Table 1). Two additional secondary covalent chains (R1 and R2) which may contain different atoms such as carbon, oxygen, chlorine, sulphur and nitrogen^{12,13} are bound to the geminal carbon atom^{14,15}.

R1 chain determines the first important property of BP; they bind to bivalent metal ions, calcium being the most important to bones, via lateral oxygen atoms. This enables binding of BPs to the apatites of the skeletal system, where they remain firmly bound to the structure of bone tissue. The pronounced affinity towards calcium ions is achieved by adding the hydroxyl group to R1 secondary molecular chain, which is the structure of most bisphosphonates^{14,15}.

R2 lateral chain structure also affects inhibition of bone resorption. Since the efficacy of etidronates with the methyl group (–CH₃) and some others from the group of non-nitrogen BPs (colodronate, tiludronate) is limited, a new clinically relevant nitrogen-containing group of BPs was created by inserting nitrogen into the molecular structure. Alkyl-amino (pamidronate, alendronate, ibandronate) and the heterocyclic nitrogen group (risedro-

TABLE 1
PHARMACOLOGIC PROPERTIES OF BISPHOSPHONATES

	Primary indication	Nitrogen containing	Dosage forms	Relative potency†	Elimination half-life
Etidronate (Didronel)	Paget disease Malignancy-related hypercalcaemia	No	Oral 300–750 mg day ⁻¹ for 6 months	1	1–6 hrs
tiludronate (Skelid)	Paget disease	No	Oral 400 mg day ⁻¹ for 3 months	10	150 hrs
Clodronate (Bonefos)	Malignancy-related hypercalcaemia	No	Oral 1600–3200 mg day ⁻¹ IV 60 mg	10	15 hrs
alendronate (Fosamax)	Osteoporosis	Yes	Oral 10 mg day ⁻¹ Oral 70 mg week ⁻¹	100–1000	10 yrs
risedronate (Actonel)	Osteoporosis	Yes	Oral 5 mg day ⁻¹ Oral 35 mg week ⁻¹	1000–10000	Initial 1.5 hrs Terminal 480 hrs
ibandronate (Boniva)	Osteoporosis Malignancy-related hypercalcaemia	Yes	Oral 2.5 mg day ⁻¹ Oral 150 mg month ⁻¹ IV 3 mg every 3 months	1000–10000	37–157 hrs
pamidronate (Aredia)	Bone metastases Malignancy-related hypercalcaemia, Multiple myeloma	Yes	IV 90 mg every 3 weeks	100	21–35 hrs
zoledronate (Zometa)	Bone metastases Paget disease	Yes	IV 4 mg every 3 weeks	>10000	Initial 0.24–1.87 hrs Terminal 146 hrs

†Relative to etidronate; IV intravenous

nate, zoledronate) at the end of the R2 chain increases the affinity of BPs to bone tissue and its anti-resorption activity^{15,16}.

The cellular effect of BPs is twofold depending on whether they have the nitrogen component. Non-nitrogen-containing BPs have less complex effects. They could be metabolised in the osteoclast cytosol to nonhydrolyzable methylene-containing (AppCp-type) analogues of adenosine triphosphate (ATP) that contain the P-C-P group of the BP in place of P-O-P. The accumulation of ATP analogues in osteoclasts has a cytotoxic effect, inhibiting numerous intracellular metabolic enzymes, and inducing osteoclast apoptosis. Nitrogen-containing BPs inhibit a key enzyme farnesyl diphosphate synthase (FPP-synthase) in the mevalonate pathway. Apart from the cholesterol synthesis, the function of this pathway is prenylation, that is, a process of hydrophobe molecule (isoprenoid lipids, the so-called GTPases, farnesyl and more important geranylgeranyl) binding to the proteins

of the cell membrane. They anchor to the proteins in cell membranes and are also required for protein to protein interactions, and finally apoptosis. The molecular mechanism of nitrogenous BPs on osteoclasts may actually be due to the accumulation of unprenylated small GTPases in their active state rather than loss of the prenylated proteins. This leads to osteoclasts' apoptosis^{15–18}.

BRONJ

The osteonecrosis of the jaw is not a new pathological condition since the direct etiopathogenic relation to toxic effects of yellow phosphorus on human body has been known for a long time^{19,20}. The BRONJ diagnosis (Table 2) includes the following criteria: present or past bisphosphonate treatment and open necrotic wound lasting more than 8 weeks with no history of radiotherapy to the maxillofacial region. The three basic stages of BRONJ

TABLE 2
PRESENTING FEATURES OF BISPHOSPHONATES-RELATED OSTEONECROSIS OF THE JAW

Symptoms	Signs
Bone pain	Alveolar bone loss
Paraesthesia	Resorption
Neuropathic pain	Inferior alveolar canal narrowing
Loosening of teeth	Dense woven alveolar bone
Odontalgia	Thickening of the periodontal ligament
After extraction, persistently dry socket and persistence	Changes in the trabecular pattern of the bones involved

which also determine the extent of conservative surgical procedures are the following: stage 1, symptomatic, exposed and necrotic bone without infection; stage 2, painful exposed and necrotic bone with clinically evident infection; and stage 3, complications which include extending, exposed and necrotic bone, pathological fractures, fistulisation and osteolysis of inferior border of the mandible or sinus floor on the maxilla. Since the development of asymptomatic BRONJ is possible, the 0 stage has been introduced, which is defined as condition with no clinical evidence of necrotic bone with various nonspecific clinical signs²¹.

There is a discrepancy in BRONJ prevalence regarding a number of medication parameters^{22–24}:

- Underlying disease due to BPs use is more prevalent in patients with malignant conditions (tumor related hypercalcemia or bone metastasis) than in other patients with rheumatological and metabolic diseases;
- Osteonecrosis is more related to intravenous than oral BPs treatment;
- Incidence of osteonecrosis is related to alkyl-BPs; in case of non-nitrogenous BPs it is possible but very rare.

Described incidences for BRONJ range from 3 to 17% in multiple myeloma patients^{25–27}, 1.2 to 11% in breast cancer patients^{28–30}, and 3 to 19% in prostate cancer patients³¹. The risk of developing BRONJ in osteoporosis patients treated with BPs is lower and is estimated at one event per 20,000 to 100,000 patient-years³². The most common aminoBPs associated with BRONJ are pamidronate and zoledronate, followed by ibandronate or alendronate²³. Only a few cases of BRONJ in patients taking alkyl-BPs have been published. There were relatively few patients taking alkyl-BPs described, 28 altogether, and out of that group 17 were also using nitrogen BPs, which are also related to osteonecrosis³³.

Apart from the dose, time and way of BPs use, a key pharmacological feature is their binding affinity for bone, which depends on molecular stereochemistry. Risedronate has a weaker binding affinity to bone tissue, which results in: higher desorption, lower re-attachment, and finally more diffusion in the bone^{34,35}. The highest BRONJ prevalence is in patients who received zoledronate intravenously (53%); those who received pamidronate followed by zoledronate (27%), and finally, those who only received pamidronate (19%). The prevalence of risedronate is only 0.5% as well as the combination of alendronate followed by zoledronate (0.5%)²³.

Tooth extraction which can be an osteonecrosis trigger is the main dental procedure associated with BRONJ (67% of cases). Prosthetic appliances have an equally important role in BRONJ. Apart from the mylohyloid ridge, critical sites for excessive pressure of the denture base are palatine tori, and less frequently, mandibular tori (7% of cases). A case of osteonecrosis associated with BPs in patients with removable dentures was described³⁶. Even a case of direct nicotine effect (nicotine replacement chewing gum) on the development of osteonecrosis

of the jaw without the effect of BPs was described³⁷. Filleul et al.²³ found a spontaneous BRONJ development in 26% of cases, without any particular trigger.

In contrast, Abu-Id et al.³⁸ discovered that in 37.8% of gathered cases BRONJ can be associated with prior tooth extraction and in 28.6% of gathered cases with acute periodontitis. Other risk factors are the following oral surgical procedures: periodontal surgery (11.2%), dental implants (3.4%) and apicotomy (0.8% of cases). Other cases were identified as spontaneous BRONJ development without any relation to any oral or dental factors.

Pathophysiological model for BRONJ

Some features of medications belonging to nitrogen BPs, their application (peroral, intravenous), doses, the relatively long-lasting half-life as well as simultaneous intake of some other drugs such as corticosteroids and comorbidity with other diseases (diabetes) contribute to the vague clinical picture of a specific etiopathogenic BRONJ model^{17,18,22}.

Remodeling suppression

Antiosteoclastic pharmacological activity of BPs is the cornerstone of the hypothesis of the development of osteonecrosis of the jaw. It has been determined on the animal model that high doses of risedronates and alendronates administered orally (16 times higher than those in clinical practice) reduced remodeling of the jaw in one year from 40% to 5% whereas in the same period, remodeling of rib bones was reduced from 15% to 5%³⁹. It is a known fact that the alveolar bone shows ten times faster bone turnover and the osteoclasts have a greater resorptive activity⁴⁰. Physiological balance between osteoclast and osteoblast interaction can be compromised by bisphosphonate treatment. Oral infection or dental intervention may increase remodeling rate in the jaw cortex⁴¹. Hansen et al.⁴² obtained controversial results: while comparing patients with osteoradionecrosis and those with BRONJ, and control subjects, a significantly larger number of osteoclasts in both groups of patients with osteonecrosis was determined.

Vascular compromise

BPs have an antiangiogenic effect on malignant tissues and this is a part of their therapeutic effect⁴³. However, the alveolar bone is highly vascularised bone tissue and osteonecrotic lesions of the alveolar bone histologically still reveal the presence of hematologic elements. Also, a clinically osteonecrotic lesion does not show avascularity, but bleeds profusely during surgical procedures^{40,44}.

BPs toxicity

BPs cytotoxicity is possible on two levels: toxicity to bone tissue and toxicity to soft oral tissue. With regard to the vital enzyme effect of BPs in mevalonate cycle; during the use of BPs, non-prenylated proteins are accumu-

lated in the cells. It is less possible to expect the lack of prenylated proteins to be the basis of cytotoxicity to bone since the synthesis of new proteins depends on concentration of those which are non-prenylated⁴⁵. Toxicity could depend on the dose and duration due to long lasting (up to 12 years) BPs retention in bone tissue. However, there is no systemic toxicity of BPs to bone tissues; it is localized to the jaw. Burr and Allen⁴⁶ have showed on animal model that treatment during 1–3 years with oral BPs or 6 months with intravenous was associated with development of necrotic areas with dead osteocytes in the mandible and the rib. However, is it unclear whether the toxic effect of BPs at high dose, natural process of cell death or suppressed remodelling was responsible for development of areas of necrotic tissue. It has been hypothesised that BPs accumulated in bones directly cause epithelial toxicity. This is explained by slow healing of osteonecrotic lesions. During *in vitro* tests, BPs showed strong inhibition of osteogenic as well as non-bone cells', such as fibroblasts, vitality⁴⁷. BP toxicity to soft tissue may be the reason why the skeletal system is directly exposed to the oral environment through teeth and periodontal ligaments. Bone resorption and apposition are biological processes occurring during physiological function of the stomatognathic system and during each orthodontic treatment. Using properly adjusted orthodontic force does not cause excessive bone and/or tooth root resorption.⁴⁸ The results of the *in vitro* study by Coxon et al.⁴⁹ showed that if bone surfaces were not present, BPs moved and acted on non-bone cells. In contrast, in presence of bone tissue, BPs were tightly bound to hydroxyapatite and induced apoptosis of osteoclasts.

Infection

Polymicrobial infection and periodontal disease may contribute to development of BRONJ as a biofilm-associated infection. Periodontopathic bacteria, especially when organized as microbial biofilms, could extend to the bone through fistulas in the absence of mucosal breakdown^{50,51}. Lipopolysaccharide production from gram-negative microbes stimulates bone resorption, for example, *Porphyromonas gingivalis* species stimulates the formation of osteoclasts in periodontal tissues⁵². However, the *Actinomyces* species is dominant: in the recent review by Filleul et al.²³ *Actinomyces* was present in 70% of all cases in which microbiological data were presented. Thumbigere-Math et al.⁵³ found *Actinomyces*-like microorganisms in all bone specimens of 12 patients during microbiological examination. Histological and microbiological findings revealed that chronic *Actinomyces* infection was identical to chronic osteomyelitis. In all 11 radiologically examined patients with BRONJ, Šurlan Popovič and Kočar⁵⁴ found *Actinomyces* infection.

Discussion

Alveolar bone traumatization factor can be important for explanation of spontaneous osteonecrosis development on the mylohyoid ridge after endotracheal intuba-

tion⁵⁵. The mylohyoid ridge is a site of thin oral mucosis which is often placed on the sharp edge in the posterior sublingual region which serves as a point of attachment to the mylohyoid muscle.

Bones without osteoclastic activity lack resorption thus increasing bone mass but the long-term quality is compromised due to continuous accumulation of microfractures⁵⁶. Osteonecrosis of the external auditory canal which appeared in the form of non-healing ulceration in only one patient with multiple myeloma undergoing BPs treatment can be explained by embryonic development⁵⁷. Since osteonecrosis only appears on the bones of the jaw (in 65% of cases on the mandible, 8% on both jaws), it can be assumed that embryonic origin and biological features of jaw bones in which remodelling occurs 10 times faster than in other bones, have a part in the etiopathogenic effect. Also, the thin mucoperiosteal flap covering the alveolar bones is important for injury protection unlike the thick layer of soft tissue covering the long bones^{23,40}.

Additional etiopathogenic factors such as corticosteroid therapy or diabetes in BRONJ are questionable. Since the majority of patients undergoing BPs therapy are also treated for their main malignant condition, as much as 55% of them underwent chemotherapy. Corticosteroid treatment was also common (32%), followed by periodontal diseases (16%). However, direct correlation has not been proved and there could also be comorbidities²³. General immunosuppressive effects (corticosteroids) as well as local adverse effects of periodontal diseases on healing of oral mucosa as well as of deeper layers of the alveolar bone can also have a role in BRONJ development. BRONJ were identified in only four patients with rheumatoid arthritis. The patients were using corticosteroids in treatment of the main diseases as well as alendronate⁵⁸.

Sarin et al.⁵⁹ termed the comorbidity effects of several immunosuppressive and/or bone remodelling suppressive factors, including poor oral hygiene and bad habits, »band-wagon« effect. This is supported by the fact that Kos et al.⁶⁰ did not find any differences between BRONJ patients and controls, the latter being exposed to a number of different potential causes of osteonecrosis such as tumours, chemotherapy, corticosteroids and stem cell transplants. However, the role of *Actinomyces* colonies in bone lesions is pointed out whereas BPs do not have a dominant predisposing role in the development of osteomyelitis of the jaw.

An exact model of BRONJ etiopathogenesis does not exist (Figure 1), yet some points of view have been definitely changed. Previously considered to be avascular necrosis, BRONJ is, due to its pronounced infectious component, more often related to osteomyelitis associated with BPs⁶¹. BPs are important because of their cytotoxicity to bone tissue and possibly also to epithelial tissue of the alveolar bone. Local trauma plays an important role, in the form of a local surgical procedure such as tooth extraction but as many as 26% of cases occur spontaneously according to Filleul et al.²³. For this reason, radiological diagnostics which enables an early detection of

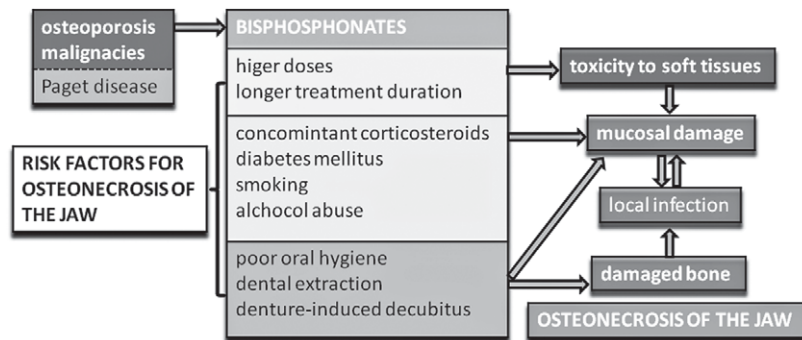


Fig. 1. Possible interactions of etiopathogenetic factors on the development of bisphosphonates-related osteonecrosis of the jaw.

BRONJ is very important. In spite of this, higher bone matrix density does not often provide sufficiently differential radiological diversity with respect to the healthy structure of the bone⁶². Panoramic dental radiography is a radiological method in everyday dental practice, however, especially at stage 0, multi slice CT, cone beam CT, and MRI diagnostics can more specifically determine bone abnormalities^{53,61}.

In conclusion, the main principle in BRONJ treatment is minimally invasive surgery. It is important to take a microbiological swab due to high incidence of *Actinomyces*-like microorganisms. It is questionable

whether BPs treatment should be interrupted if BRONJ is diagnosed – a multidisciplinary approach should be taken for each patient in order to determine the benefits and possible consequences of drug therapy cessation since BPs remain in the body for years after the beginning of use.

Acknowledgements

This study was partially presented at the 6th Croatian Congress of Pharmacology with International Participation (Opatija, Croatia, September 15-18 2010).

REFERENCES

1. MARX RE, *J Oral Maxillofac Surg*, 61 (2003) 1115. DOI: 10.1016/S0278-2391(03)00720-1. — 2. FAWCETT DW, JENSH RP, Bloom & Fawcett's Concise Histology (Arnold, London, 2002) — 3. OVALLE WK, NAHIRNEY PC. *Netter's Essential Histology* (Saunders and Elsevier, Philadelphia, 2008) — 4. STINI WA, *Coll Antropol*, 22 (1998) 411. — 5. LEE SK, KIM YS, OH HS, YANG KH, KIM EC, CHI JG, *Anat Rec*, 263 (2001) 314. DOI: dx.doi.org/10.1002/ar.1110 — 6. BADEL T, SAVIĆ PAVIČIN I, PODOREŠKI D, MAROTTI M, KROLO I, GRBEŠA D, *Acta Clin Croat*, 50 (2011) 49 — 7. MIHALJEVIĆ I, MUDRI D, SMOLIĆ R, SMOLIĆ M, TUCAK-ZORIĆ S, *Coll Antropol*, 33 Suppl 2 (2009) 21. — 8. MATSUO K, IRIE N, *Arch Biochem Biophys*, 473 (2008) 201. DOI: 10.1016/j.abb.2008.03.027. — 9. KEARNS AE, KHOSLA S, KOSTENIUK PJ, *Endocrine Reviews*, 29 (2008) 155. DOI: 10.1210/er.2007-0014. — 10. JULES J, ASHLEY JW, FENG X, *Expert Opin Ther Targets*, 14 (2010) 923. DOI: 10.1517/14728222.2010.511179. — 11. CAETANO-LOPES J, CANHÃO H, EURICO FONSECA J, *Acta Reum Port*, 32 (2007) 103. — 12. OMELON S, GEORGIU J, HENNEMAN ZJ, WISE LM, SUKHU B, HUNT T, WYNNICKYJ C, HOLMYARD D, BIELECKI R, GRYPNAS MD, *PLoS One*, 4 (2009) e5634. DOI: 10.1371/journal.pone.0005634. — 13. MARTIN TJ, NATALIE A. SIMS NA, QUINN JMW. *Interactions Among Osteoblasts, Osteoclasts, and Other Cells in Bone*. In: LORENZO J, YONGWON CHOI Y, HOROWITZ M, TAKAYANAGI H (Eds), *Osteoimmunology* (Elsevier, Amsterdam, 2011). DOI: 10.1016/B978-0-12-375670-1.10008-1. — 14. FLESICH H, *Breast Cancer Res*, 4 (2002) 30. DOI: 10.1186/bcr414. — 15. PAPAPOULOS SE. *Bisphosphonates*. In: ROSEN CJ, GLOWACKI J, BILEZIKIAN JP (eds): *The Aging Skeleton*. (Academic Press, San Diego, 1999). — 16. ROELOFS AJ, THOMPSON K, GORDON S, ROGERS MJ, *Clin Cancer Res*, 12 (2006) 20 Suppl:6222S. DOI: 10.1158/1078-0432.CCR-06-0843. — 17. COXON FP, K. THOMPSON K, ROGERS MJ, *Curr. Opin Pharmacol*, 6 (2006) 307. DOI: 10.1016/j.coph.2006.03.005. — 18. THOMPSON K, MICHAEL J. ROGERS MJ, *Clinic Rev Bone Miner Metab*, 5 (2007) 130. DOI: 10.1007/s12018-007-9004-0. — 19. BADEL T, KEROS J, KRAPAC L, SAVIĆ PAVIČIN I, *Arh Hig Rada Toksikol*, 61 (2010) 371. DOI: 10.2478/10004-1254-61-2010-2032. — 20. DURIĆ M, RAKOČEVIĆ Z, BUMBASIREVIĆ M, LESIĆ A, KELECEVIĆ J, *Coll Antropol* 28 Suppl 2 (2004) 273. — 21. MCLEOD NM, PATEL V, KUSANALE A, ROGERS SN, BRENNAN PA, *Br J Oral*

Maxillofac Surg, 49 (2011) 335. DOI: 10.1016/j.bjoms.2010.08.005. — 22. REID IR, *Bone*, 44 (2009) 4. DOI: 10.1016/j.bone.2008.09.012. — 23. FILLEUL O, CROMPOT E, SAUSSEZ S, *J Cancer Res Clin Oncol*, 136 (2010) 1117. DOI: 10.1007/s00432-010-0907-7. — 24. KNIGHT RJW, REDDY C, RTSHILADZE MA, LVOFF G, SHERRING D, MARUCCI D, *J Craniofac Surg*, 21 (2010) 25. DOI: 10.1097/SCS.0b013e3181c347a0. — 25. MARX RE. *Oral and intravenous bisphosphonate-induced osteonecrosis of the jaw: history, etiology, prevention, and treatment* (Quintessence Publishing, Hanover Park (IL), 2007). — 26. CETINER S, SUCAK GT, KAHRAMAN SA, AKI SZ, KOCAKAHYAAGLU B, GULTEKIN SE, CETINER M, HAZNEDAR R, *J Bone Miner Metab*, 27 (2009) 435. DOI: 10.1007/s00774-009-0047-9. — 27. BOONYAPAKORN T, SCHIRMER I, REICHAERT PA, STURM I, MASSENKEIL G, *Oral Oncol*, 44 (2008) 857. DOI: 10.1016/j.oraloncology.2007.11.012. — 28. HOFF AO, TOTH BB, ALTUNDAG K, JOHNSON MM, WARNEKE CL, HU M, NOOKA A, SAYEGH G, GUARNERI V, DESROULEAUX K, CUI J, ADAMUS A, GAGEL RF, HORTOBAGYI GN, *J Bone Miner Res*, 23 (2008) 826. DOI: 10.1359/jbmr.080205. — 29. AGUIAR BUJANDA D, BOHN SARMIENTO U, CABRERA SUÁREZ MA, AGUIAR MORALES J, *Ann Oncol*, 18 (2007) 556. DOI: 10.1093/annonc/mdl408. — 30. WALTER C, GRÖTZ KA, KAŠAJ A, ALBRICH S, SCHMIDT M, NAUROTH B, AL-NAWAS B, *Acta Stomatol Croat*, 43 (2009) 271. — 31. WALTER C, GRÖTZ KA, KAŠAJ A, ALBRICH S, SCHMIDT M, NAUROTH B, AL-NAWAS B, *Eur Urol*, 54 (2008) 1066. DOI: 10.1016/j.eururo.2008.06.070. — 32. GRBIC JT, LANDESBURG R, LIN SQ, MESENBRINK P, REID IR, LEUNG PC, CASAS N, RECKNOR CP, HUA Y, DELMAS PD, ERIKSEN EF, *J Am Dent Assoc*, 139 (2008) 32. — 33. CRÉPIN S, LAROCHE ML, SARRY B, MERLE L, *Eur J Clin Pharmacol*, 66 (2010) 547. DOI: 10.1007/s00228-010-0822-5. — 34. GILJEVIĆ Z, *Reumatizam*, 55 (2008) 78. — 35. RUSSELL RG, XIA Z, DUNFORD JE, OPPERMAN U, KWAASI A, HULLEY PA, KAVANAGH KL, TRIFFITT JT, LUNDY MW, PHIPPS RJ, BARNETT BL, COXON FP, ROGERS MJ, WATTS NB, EBETINO FH, *Ann. N.Y. Acad. Sci*, 1117 (2007) 209. DOI: 10.1196/annals.1402.089. — 36. TAKAGI Y, SUMI Y, HARADA A, *J Prosthet Dent*, 101 (2009) 289. DOI: 10.1016/S0022-3913(09)00049-3. — 37. Loo YK, *Dent Update*, 36 (2009) 289. — 38. ABU-ID MH, WARNEKE PH, GOTTSCHALK J, SPRINGER I, WILTFANG J, ACIL Y, RUSSO PA, KREUSCH

- T, J Craniomaxillofac Surg, 36 (2008) 95. DOI: 10.1016/j.jcms.2007.06.008. — 39. MASHIBA T, TURNER CH, HIRANO T, FORWOOD MR, JACOB DS, JOHNSTON CC, BURR DB, Bone, 29 (2001) 271. DOI: 10.1016/S8756-3282(01)00575-0. — 40. CHENG A, DALY CG, LOGAN RM, STEIN B, GOSS AN, Austr Dent J, 54 (2009) 1 Suppl:S51. DOI: 10.1111/j.1834-7819.2009.01143.x. — 41. ALLEN MR, Cells Tissues Organs, 189 (2009) 289. DOI: 10.1159/000151371. — 42. HANSEN T, KIRKPATRICK CJ, WALTER C, KUNKEL M, Virchows Arch, 449 (2006) 448. DOI: 10.1007/s00428-006-0261-y. — 43. FOURNIER PG, STRESING V, EBETINO FH, CLÉZARDIN P, Neoplasia, 12 (2010) 571. — 44. HANSEN T, KUNKEL M, WEBER A, KIRKPATRICK CJ, J Oral Pathol Med, 35 (2006) 155. DOI: 10.1111/j.1600-0714.2006.00391.x. — 45. RUSSELL RGG, WATTS NB, EBETINO FH, ROGERS MJ, Osteoporosis Int, 19 (2008) 733. DOI: 10.1007/s00198-007-0540-8. — 46. BURR DB, ALLEN MR, Orthod Craniofac Res, 12 (2009) 221. DOI: 10.1111/j.1601-6343.2009.01456.x. — 47. WALTER C, KLEIN MO, PABST A, AL-NAWAS B, DUSCHNER H, ZIEBART T, Clin Oral Invest, 14 (2010) 35. DOI: 10.1007/s00784-009-0266-4. — 48. SAVIĆ PAVIČIN I, IVOSEVIĆ-MAGDALENIĆ N, BADEL T, BASIĆ K, KEROS J, Coll Antropol, 36 (2012) 779. — 49. COXON FP, THOMPSON K, ROELOFS AJ, EBETINO FH, ROGERS MJ, Bone 42 (2008) 848. DOI: 10.1016/j.bone.2007.12.225. — 50. ŠKRLIN J, Liječ Vjesn, 132 Suppl 1 (2010) 24. — 51. KUMAR SK, GORUR A, SCHAUDINN C, SHULER CF, COSTERTON JW, SEDGHIZADEH PP, Curr Osteoporos Rep, 8 (2010) 40. DOI: 10.1007/s11914-010-0008-1. — 52. WARA-ASWAPATI N, SURARIT R, CHAYASADOM A, BOCH JA, PIPHAT W, J Periodontol, 78 (2007) 1062. DOI: 10.1902/jop.2007.060398. — 53. THUMBIGERE-MATH V, SABINO MC, GOPALAKRISHNAN R, HUCKABAY S, DUDEK AZ, BASU S, HUGHES PJ, MICHALOWICZ BS, LEACH JW, SWENSON KK, SWIFT JQ, ADKINSON C, BASI DL, J Oral Maxillofac Surg, 67 (2009) 1904. DOI: 10.1016/j.joms.2009.04.051. — 54. ŠURLAN POPOVIĆ K, KOČAR M, Radiol Oncol, 44 (2010) 215. — 55. ALMAZROOA SA, CHEN K, NASCIMBEN L, WOO SB, TREISTER N, Anesth Analg, 111 (2010) 437. DOI: 10.1213/ANE.0b013e3181e0cdcd. — 56. ALLEN MR, Clin Oral Invest, 13 (2009) 481. DOI: 10.1007/s00784-009-0336-7. — 57. POLIZZOTTO MN, COUSINS V, SCHWARER AP, Br J Haematol, 132 (2006) 114. DOI: 10.1111/j.1365-2141.2005.05833.x. — 58. JUNQUERA L, GALLEGO L, PELAZ A, OLAZ S, 14 (2009) E292. — 59. SARIN J, DEROSI SS, AKINTOYE SO, Oral Dis, 14 (2008) 277. DOI: 10.1111/j.1601-0825.2007.01381.x. — 60. KOS M, BRUSCO D, KUEBLER J, ENGELKE W, Int J Oral Maxillofac Surg, 39 (2010) 1097. DOI: 10.1016/j.ijom.2010.04.054. — 61. PAZIANAS M, RUSSELL RG, FOGELMAN I, J Nucl Med, 50 (2009) 6. DOI: 10.2967/jnumed.108.057885. — 62. ALLEN MR, RUGGIERO SL, J Oral Maxillofac Surg, 67 (2009) 1373. DOI: 10.1016/j.joms.2009.03.048.

T. Badel

University of Zagreb, School of Dental Medicine, Department of Removable Prosthodontics, Gundulićeva 5, 10000 Zagreb, Croatia
e-mail: badel@sfzg.hr

PATOFIZIOLOGIJA OSTEONEKROZE ČELJUSTI U BOLESNIKA LIJEČENIH BISFOSFONATIMA

SAŽETAK

Bez obzira na dobro poznat mehanizam djelovanja bisfosfonata na stanice, raspravljen je embrionalni razvoj i specifična zbivanja u homeostazi alveolarne kosti. Etiopatogenetski mehanizam osteonekroze čeljusti kosti povezanih s liječenjem bisfosfonatima nije jedinstveno objašnjen. Stavljene su naglasak na toksikološki učinak bisfosfonata na fiziologiju alveolarne kosti i trajni učinak ekstrakcije zuba koju prati infekcija ekstrakcijske rane i njezina daljnja progresija u dublje slojeve koštanog tkiva. Infekcija epitela uključuje mikrobiološki nalaz roda *Actinomyces*. Izražen je rizik u onkoloških pacijenata pod intravenskom terapijom bisfosfonatima u relativno visokim dozama i tijekom duljeg vremenskog perioda, posebice visokopotentnim nitrogenim bisfosfonatima pamidronatom i zoledronatom. Ovaj pregled osteonekroze čeljusti povezane s bisfosfonatima stavlja ulogu bisfosfonata čak u drugi plan, a ističe se značaj drugih predisponirajućih čimbenika (kortikosteroidi, kemoterapije, tumori itd) za nastanka nekroze – točnije osteomijelitisa čeljusti ako se uzme u obzir mikrobiološka komponenta bolesti. Ne postoji zlatni standard u liječenju osteonekroze čeljusti, češće palijativna i minimalno invazivna, a ne oralno-kirurška terapija. Sve dok postoji znatan rizik za osteonekrozu čeljusti u onkoloških bolesnika, oralno zdravlje je važan čimbenik u indikaciji intravenskog liječenja bisfosfonatima.