

Human β -Defensin 4 Expression in Gianotti-Crosti Syndrome

Rosario Caltabiano¹, Giada Maria Vecchio¹, Rocco De Pasquale²,
Carla Loreto³, Rosalia Leonardi⁴, Enrico Vasquez¹

¹Department G.F. Ingrassia, Section of Anatomic Pathology; ²Department of Dermatology, G. Rodolico Polyclinic; ³Department of Biomedical Science, Section of Anatomy; ⁴Department of Dentistry, Faculty of Dentistry, University Polyclinic, University of Catania, Catania, Italy

Corresponding author:

Rosario Caltabiano, MD
Department G.F. Ingrassia, Section of
Anatomic Pathology
University of Catania
Santa Sofia 87
Catania 95123
Italy
rosario.caltabiano@unict.it

Received: May 23, 2012

Accepted: November 15, 2012

SUMMARY The Gianotti-Crosti syndrome is a relatively common children dermatosis characterized by a monomorphous erythematous papular rash limited to the face and extensor surface of the arms and legs. Although the pathogenesis is still unclear, infections are considered as the most important factor. Human β -defensins are cationic antimicrobial peptides closely related to bacterial and viral infections of many epithelia. We herein report a case of Gianotti-Crosti syndrome in a 7-year-old Caucasian girl presented with prominent eruption consisting of dome-shaped lichenoid papules on her upper and lower extremities, with spontaneous resolution. Skin biopsy revealed a dense lichenoid lymphohistiocytic infiltrate and showed strong cytoplasmic immunopositivity for human β -defensin-4 in the stratum corneum, stratum granulosum, and stratum spinosum. Considering that β -defensins have been described to be induced by infections, we investigated the expression of human β -defensin-4 by immunohistochemistry in a case of Gianotti-Crosti syndrome, in order to demonstrate that it represents a cutaneous response to skin infections.

KEY WORDS: papular acrodermatitis of childhood, lichenoid dermatitis, human β -defensin-4, morphology

INTRODUCTION

The Gianotti-Crosti syndrome (GCS), or papular acrodermatitis of childhood, is a self-limited childhood exanthema associated with bacterial or viral infections or immunization. It is characterized by the acute onset of monomorphous, symmetric flat-topped papules or papulovesicles, which range in color from pink to red or brown and are usually located on the face, buttocks and extensor surfaces of the forearms

and legs, with the trunk typically being spared. The lesions are occasionally pruritic and are self-limiting, lasting for up to 3 weeks. Mucous membranes are not affected. Systemic signs include hepatosplenomegaly and axillary and inguinal lymphadenopathy (1). The pathogenesis of GCS is still unknown, although a number of hypotheses have been proposed. Considering that neither viral particles nor viral antigens

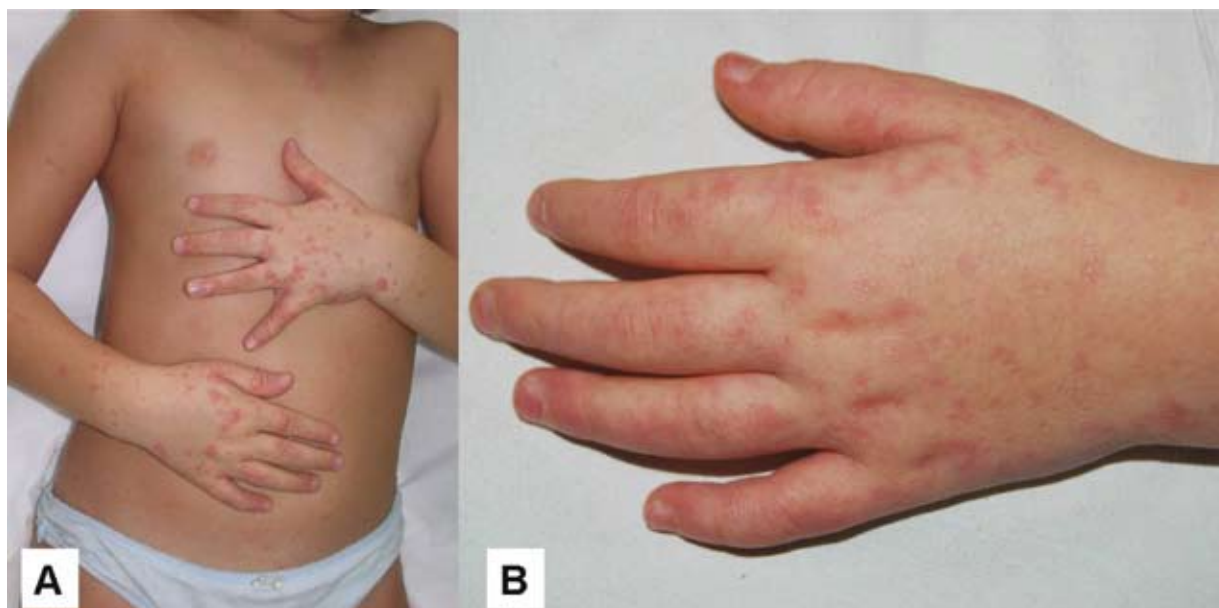


Figure 1. (A) Prominent eruption consisting of non pruritic pink 1-2 mm flat-topped and dome-shaped lichenoid papules on upper extremities of the patient; (B) at 3-week follow-up, partial spontaneous healing with flattening of the papules was observed.

have been retrieved in the skin lesions of GCS (2), it has been postulated that the lesion development does not involve direct local interaction between viral antigens and immune-competent cells in the skin.

Human β -defensins (hBD) are small cationic peptides with a broad spectrum of antimicrobial activity. hBD-4 exhibited the same genomic organization as other β -defensins, with two exons flanking an intron of 4495 bp (3). Because β -defensins have been

described to be induced by infections, we investigated the expression of hBD-4 by immunohistochemistry in a case of GCS, in order to deepen the insight into its pathogenesis.

CASE REPORT

A previously healthy 7-year-old Caucasian girl presented with a two-week history of rash associated

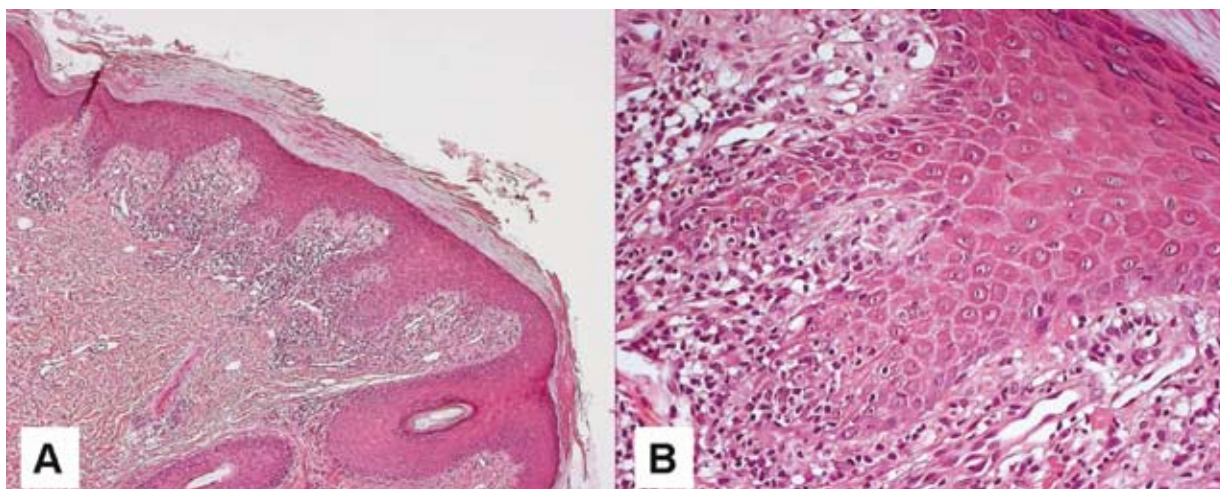


Figure 2. (A) Histologic examination showed compact orthokeratosis, focal parakeratosis, hypergranulosis, psoriasiform epidermal hyperplasia, and a dense lichenoid lymphohistiocytic infiltrate (H&E, X100x); (B) at higher magnification, the lichenoid pattern was evident (H&E, X200).

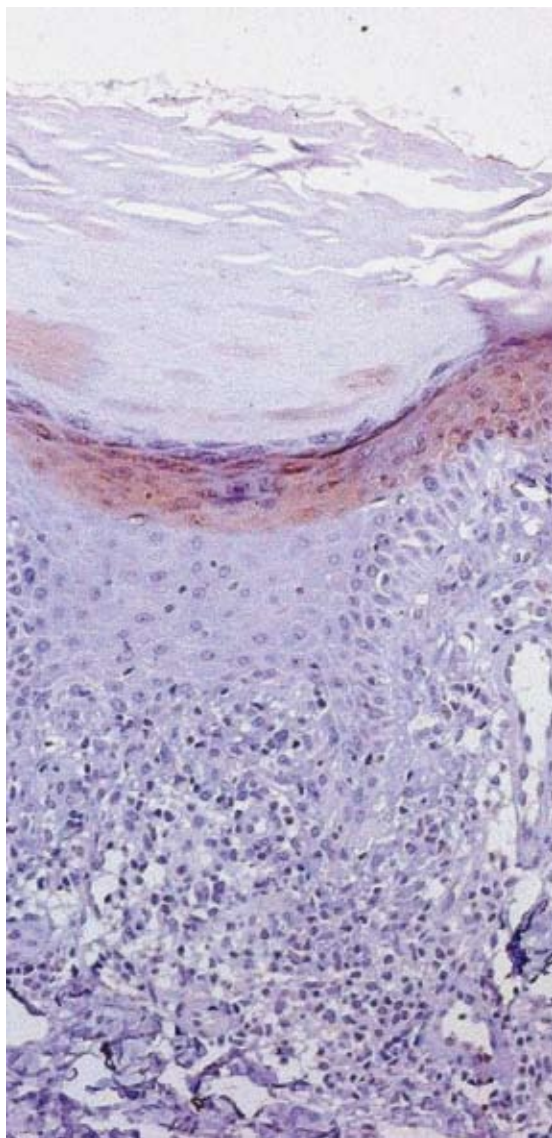


Figure 3. Intense cytoplasmic immunoreactivity for human β -defensin-4 (hBD-4) in the cells of the upper spinous, granular and keratinized layers (IHC, X200).

with low-grade fever and lymphadenopathy. Family history was unremarkable. The patient was taking no medications, and her past medical history revealed a respiratory syncytial virus infection before the onset of the rash. On physical examination, the patient was a normally developed playful child. A prominent eruption consisting of non pruritic pink 1-2 mm flat-topped and dome-shaped lichenoid papules was present on her upper and lower extremities (Fig. 1A). No lesions of the mouth and nails were observed. Enlarged, soft, freely movable lymph nodes were appreciated at the axillary and inguinal region. Throat

culture, mononucleosis test, serologic tests for hepatitis viruses and routine blood tests were within the normal limits. Therefore, we decided to perform an incisional biopsy on the dorsum of the left hand. No therapy was administered and partial spontaneous healing with flattening of the papules (Fig. 1B) ensued in approximately 3 weeks.

MATERIALS AND METHODS

Surgical specimen was fixed in 10% buffered formalin, routinely processed and embedded in paraffin. The 4- μ m thick sections were stained with hematoxylin and eosin. Additional sections were cut for immunohistochemical procedures. The immunohistochemical assay was performed on 4- μ m sections cut from the blocks and float-mounted on Super Frost/Plus slides. Slides were deparaffinized and rehydrated through xylenes and graded ethanol solutions to water. Antigen retrieval was performed by the heat method in which the specimens were placed in a citric acid solution (Target Retrieval Solution, pH 6.1; Dako Cytomation, Glostrup, Denmark), for 30 min at 94 °C using a vegetable steamer and then brought to room temperature for 20 min. All slides were quenched for 5 min in 0.03% hydrogen peroxide (EnVision+ System-HRP (DAB), Dako Cytomation) to block for endogenous peroxidase. The primary antibody, mouse anti-human β -defensin-4 antibody (Santa Cruz Biotechnology), diluted 1:50, was applied for 60 min in moist chamber. After washing in Tris-buffered saline (TBS) at pH 7.6, secondary antibody (Goat IgG antibody, Donkey polyclonal to Goat IgG-H&L (HRP), Abcam, Cambridge, UK) was applied for 30 min in moist chamber. The sections were again washed in TBS. Staining was completed by 10-min incubation with 3,3'-diaminobenzidine (DAB) substrate-chromogen (Dako Cytomation). Slides were then counterstained in hematoxylin and dehydrated through graded ethanol solutions. Slides were mounted using the Faramount aqueous medium (Dako).

RESULTS

Histologic examination of the biopsy specimen obtained from the dorsum of the left hand revealed compact orthokeratosis, focal parakeratosis, hypergranulosis, psoriasiform epidermal hyperplasia, and a dense lichenoid lymphohistiocytic infiltrate (Fig. 2A-B). The clinical and histopathologic features were consistent with the diagnosis of lichen planus. Nevertheless, the absence of pruritus, the absence of mouth and nail lesions, and the coexistence of systemic manifestations led us to consider the diagnosis of papular acrodermatitis of childhood (Gianotti-Crosti

syndrome, GCS) presenting as lichenoid dermatitis. On immunohistochemistry, immunoreactivity for hBD-4 in the stratum corneum, stratum granulosum, and stratum spinosum was observed (Fig. 3).

DISCUSSION

Gianotti-Crosti syndrome, which was first described in 1955 (4), is a rare disease representing a cutaneous response to a number of viral infections. It is a self-limiting dermatosis occurring more common in children, without racial predilection. It was first related to hepatitis B virus infection; however, it may be associated with several other viral infections including cytomegalovirus (5), Epstein-Barr virus (2), respiratory syncytial virus, parainfluenza (6), enterovirus (7), and coxsackie virus (8). Primary lesions are usually papules or papulovesicles sometimes coalescing into plaques over the elbows and knees. The eruption is usually acraly distributed with involvement of the thighs, buttocks, extensor aspects of the arms, legs and the face. Although biopsies of skin lesions show nonspecific histologic features, both vesicular and non-vesicular patterns can be seen. Unlike our case, the upper dermis usually shows interstitial dermatitis with mild to moderate perivascular lymphohistiocytic infiltrate and occasional scattered eosinophils in the superficial and mid-dermis (9). As previously reported in the literature (10), the histopathology of the lesions in our patient revealed a diffuse lichenoid infiltrate. The histopathologic differential diagnosis of a lichenoid infiltrate in childhood includes different diseases. In lichen planus, the papules are distributed over the flexural areas and, unlike GCS, are intensely pruritic. Mouth and nails are usually affected. Histopathologically, in lichen planus, globular eosinophilic deposits (Civatte bodies) and melanophages are evident at the dermoepidermal junction. Rare cases of drug induced lichenoid eruption in children exhibit mouth lesions and a less band-like infiltrate with eosinophils (11).

Antimicrobial peptides represent very important mediators of the innate immune response widely distributed from invertebrates to mammals. They are mainly expressed in the skin and mucosal epithelia, where they prevent colonization by pathogens (12). Most of them are small, cationic and hydrophobic molecules that insert into biological membranes and lyse a broad spectrum of pathogens such as bacteria, viruses, fungi and protozoa. One characteristic abnormality of lesional skin in psoriasis is the excessive production of beta defensins (13). Patients with atopic dermatitis are predisposed to infection with *Staphylococcus aureus*, which worsens their skin disease; it has been postulated that the lack of antimicrobial pep-

tides, due to aberrant allergic inflammation in the skin with atopic dermatitis, could mediate this enhanced bacterial susceptibility (14). hBD-4 is an endogenous salt-dependent antimicrobial peptide that inhibits the growth of gram-positive bacteria, gram-negative bacteria, yeasts and viruses. hBD-4, constitutively expressed in the testis, the gastric antrum, the uterus, the thyroid, the lung and the kidney, is not normally expressed in skin samples (3). Nevertheless, the inducible expression of hBD-4 by keratinocytes has also been confirmed (15). As reported in the literature (16), hBD-4 stimulates gene expression and production of various proinflammatory cytokines and chemokines by human primary keratinocytes probably related to immune complex-mediated mechanisms of GCS. Also, unlike hBD-1, gene expression of hBD-4 was strongly upregulated by skin infections (17). Our case of GCS showed strong cytoplasmic positivity for hBD-4 in the upper spinous, granular, and keratinized layers. For this reason, it demonstrates that GCS induces transcription of the gene coding for hBD-4 in the skin. Considering that defensins play an important role in host defense against the invading pathogens, our observation indicates that hBD-4 may have a function in response to viral infection in GCS that is related to pathogen elimination. This observation might indicate that viral antigenemia rather than the formation of immune complexes has a crucial role in the pathogenesis of the syndrome. With regard to the antiviral activity of defensins, their mechanisms have not yet been thoroughly understood. Viral infection can induce the expression of defensins, defensins act as chemotactic agents, and defensins can directly affect the virion. Regarding this direct effect, one aspect involves direct interaction with viral envelopes, and the other involves indirect antiviral activity through interactions with the potential target cells (18).

CONCLUSION

Our case represents one of the different kinds of histopathologic presentation of GCS and it should be considered in the diagnosis of lichenoid dermatitis in children in order to avoid unnecessary treatment. Although a type of delayed hypersensitivity reaction is speculated as a cause, our observation of hBD-4 expression in GCS may suggest direct local interaction between viral antigens and immune-competent cells in the skin.

References

1. Brandt O, Abeck A, Gianotti R, Burgdorf W. Gianotti-Crosti syndrome. *J Am Acad Dermatol* 2006;54:136-45.

2. Lowe L, Hebert AA, Duvic M. Gianotti-Crosti syndrome associated with Epstein-Barr virus infection. *J Am Acad Dermatol* 1989;20:336-8.
3. García JR, Krause A, Schulz S, Rodríguez-Jiménez FJ, Klüver E, Adermann K, *et al.* Human beta-defensin 4: a novel inducible peptide with a specific salt-sensitive spectrum of antimicrobial activity. *FASEB J* 2001;15:1819-21.
4. Gianotti F. Report on a special case of toxic infection characterized by a desquamative erythematous-infiltrative eruption with lenticular foci and a selective localization at the extremities. *Soc Ital Dermatol Sifilogr Sezioni Interprov Soc Ital Dermatol Sifilogr* 1955;96:678-97.
5. Berant M, Naveh Y, Weissman I. Papular acrodermatitis with cytomegalovirus hepatitis. *Arch Dis Child* 1983;58:1024-5.
6. Spear KL, Winkelmann RK. Gianotti-Crosti syndrome. A review of ten cases not associated with hepatitis B. *Arch Dermatol* 1984;120:891-6.
7. Draelos ZK, Hansen RC, James WD. Gianotti-Crosti syndrome associated with infections other than hepatitis B. *JAMA* 1986;256:2386-8.
8. James WD, Odom RB, Hatch MH. Gianotti-Crosti-like eruption associated with coxsackievirus A-16 infection. *J Am Acad Dermatol* 1982;6:862-6.
9. Erkek E, Senturk GB, Ozkaya O, Bukulmez G. Gianotti-Crosti syndrome preceded by oral polio vaccine and followed by varicella infection. *Pediatr Dermatol* 2001;18:516-8.
10. Stefanato CM, Goldberg LJ, Andersen WK, Bhanwan J. Gianotti-Crosti syndrome presenting as lichenoid dermatitis. *Am J Dermatopathol* 2000;22:162-5.
11. Tilly JJ, Drolet BA, Esterly NB. Lichenoid eruptions in children. *J Am Acad Dermatol* 2004;51:606-24.
12. Schröder JM, Harder J. Antimicrobial skin peptides and proteins. *Cell Mol Life Sci* 2006;63:469-86.
13. Morizane S, Gallo RL. Antimicrobial peptides in the pathogenesis of psoriasis. *J Dermatol* 2012;39:225-30.
14. Travers JB, Kozman A, Yao Y, Ming W, Yao W, Turner MJ, *et al.* Treatment outcomes of secondarily impetiginized pediatric atopic dermatitis lesions and the role of oral antibiotics. *Pediatr Dermatol* 2012;29:289-96.
15. Pazgier M, Hoover DM, Yang D, Lu W, Lubkowski J. Human beta-defensins. *Cell Mol Life Sci* 2006;63:1294-313.
16. Niyonsaba F, Ushio H, Nakano N, Ng W, Sayama K, Hashimoto K, *et al.* Antimicrobial peptides human beta-defensins stimulate epidermal keratinocyte migration, proliferation and production of proinflammatory cytokines and chemokines. *J Invest Dermatol* 2007;127:594-604.
17. Harder J, Meyer-Hoffert U, Wehkamp K, Schwichtenberg L, Schröder JM. Differential gene induction of human beta-defensins (hBD-1, -2, -3, and -4) in keratinocytes is inhibited by retinoic acid. *J Invest Dermatol* 2004;123:522-9.
18. Klotman ME, Chang TL. Defensins in innate antiviral immunity. *Nat Rev Immunol* 2006;6:447-56.

