

# Influence of Teeth Loss on Morphometric Characteristics of the Maxilla

Sanja Percač  
Vasilije Nikolić

Department of Anatomy  
»Drago Perović«  
School of Medicine,  
University of Zagreb

Utjecaj gubitka zuba na morfometrijske karakteristike  
gornje čeljusti

## Summary

*Using Martin and Saller's method in analyzing 90 skulls which belonged to adults of both sexes established are twelve basic morphometric characteristics of maxillas in the recent population of Croatia. Presented are differences in the morphology of dentate and edentulous jaws.*

*Morphometric characteristics of maxillas in the recent population of Croatia do not significantly differ from maxillar characteristics of other white ethnic groups of the same absolute age.*

*By the change of biomechanical conditions and interaction of forces caused by the loss of teeth, reabsorption of bones occurs. The alveolar process atrophies the first, causing the reduction in the maxillar length and width in the molar, as well as in the anterior part of the bone. Although the width of the palate is constant, the reduction of its length occurs. The foramen infraorbitale approaches the alveolar margin of the bone due to the reabsorption of the alveolar ridge, but its distance from the orbital edge gets reduced too, due to the overall atrophy the bone. Advancing of age, if not accompanied with the loss of teeth, does not significantly influence morphometric characteristics of the maxilla.*

Key words: *maxilla, morphology, teeth loss*

Acta Stomatologica Croatica  
1991; 25:199-205

ORIGINAL  
SCIENTIFIC PAPER

CODEN: ASCRBK  
ISSN: 0001-7019  
Received: 15. september 1991.

## Introduction

During the philogenetic and ontogenetic development of the human skull intensified growth of the neurocranium occurs, while the development of the face skeleton is reduced to the region under the sphenoid angle (1). The maxilla, being the central and biggest bone of the viscerocranium (2), significantly influences dimensions and aesthetic harmony of the face. Studying the characteristics of this bone in the light of a functional cranial analysis a great number

of changes occurring the development and growth of an individual is determined (3, 4).

In 1928 already, Testut (5) described that teeth loss causes changes in the appearance of the jaw, particularly alveolar ridges. According to biomechanical laws (6) the bone is being constantly influenced by forces acting upon it. The loss of the function is followed by reabsorption of relevant bone parts. In order to form a new bearing for prosthesis new methods used in the oral surgery enable the adding of bone auto-

grafts, cartilage or some other new alloplastic material to the reabsorbed part of the jaw (7-9). Due to it, a detailed study of edentulous jaw anatomy would be indispensable.

The aim of this study is to present the basic morphometric characteristics of maxillas in the recent population of Croatia and to describe the changes occurring in the jaw following the loss of teeth.

### Material and methods

The material for this research consists of well preserved, macerated maxillas (bases of the skull) from the Collection of the Institute of Anatomy »Drago Perović«, School of Medicine, Zagreb. Morphometric characteristics have been determined on 90 maxillas which belonged to adults of both sexes. Classic measuring analyses according to Martin and Saller (10) usual for this kind of research are performed by a mobile electronic measurer with a possible error of 0.01 mm. Characteristics of the maxilla are measured on all three levels (Figures 1, 2).

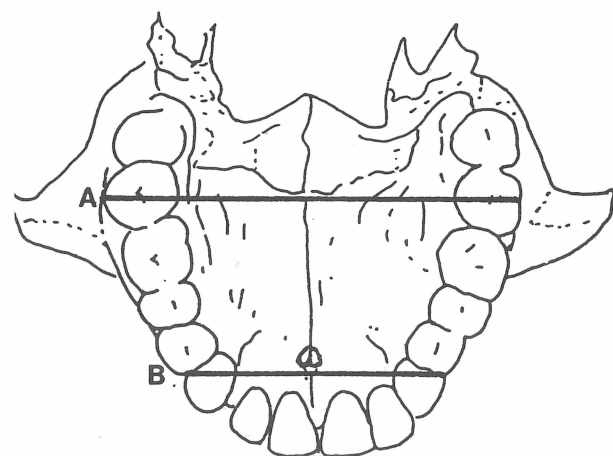


Figure 1. Horizontal measurements of the maxilla  
A— posterior width B— anterior width  
Slika 1. Mjerenja maksile u horizontalnoj ravnini

1. anterior width of the maxilla – the distance between canines and the first premolar on the left up to the same measuring point on the right of the exterior side of the alveolar process,

2. posterior width – the distance between the left and right second molar from the exterior side of the bone,

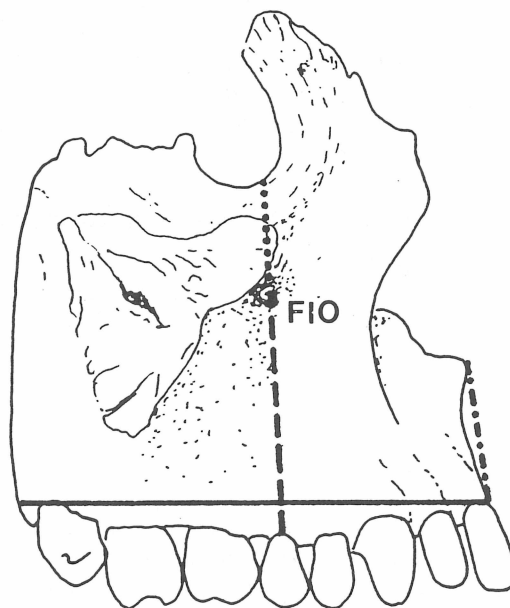


Figure 2. Vertical and sagittal measurements of the maxilla  
FIO – foramen infraorbitale  
— maxillo-alveolar length  
- - - - - height of the maxilla  
- - - - - from the alveolar margin to the foramen infraorbitale  
..... from the orbital lower margin to the foramen infraorbitale

Slika 2. Mjerenja maksile u vertikalnoj i sagitalnoj ravnini

3. maxillo-alveolar length – the distance from the prosthion to the link which connects the end of the alveolar process,

4. height of the maxilla – the distance from the prosthion to the nasospinallae.

Four dimensions are observed on the palate (Figure 3):

1. length of the palate – the distance from the orale to the staphylon,

2. anterior length of the palate – the distance from the orale to the sutura palatina transversa,

3. width of the palate – the distance between the left and the right second molar in the interior side of the alveolar process,

4. anterior width of the palate – the distance between canin and the first premolar on the left and the same measuring point on the right of the interior side of the bone.

The localization of the foramen infraorbitale is determined regarding the tooth above which it is situated. The accurate position is obtained by measuring the distance from the opening to

the lower edge of the orbit and the distance from the vestibular edge of the alveolar process.

The studied sample is grouped in two: dentate and edentulous jaws, then variances in morphometric characteristics of these two maxillar groups statistically analysed. Age adjusted distribution of samples has enabled determination of changes conditioned by the involution of an individual.

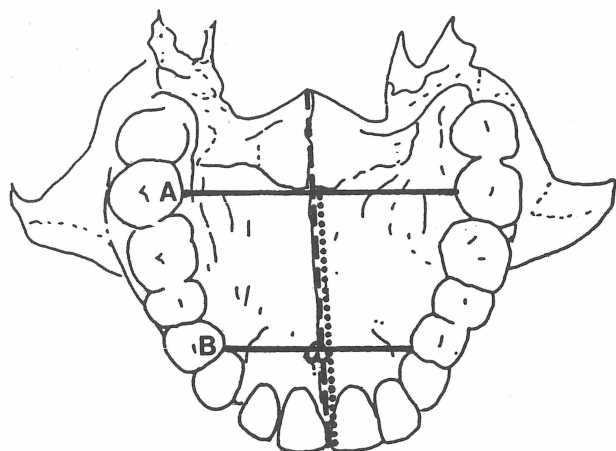


Figure 3. The palate measurements

----- length ..... anterior length  
A— width B— anterior width

Slika 3. Mjerenja nepca

## Results

The results of this research are presented in tables. In the first four tables values of morphometric parameters of the overall sample are reviewed. Beside the mean value ( $\bar{x}$ ) and standard deviation ( $s$ ), presented is dimensional range ( $R$ ), namely the studied parameter minimum and maximum value measured.

Values of basic dimensions of measured maxillas are given in Table I. Maxillo-alveolar length is 54.6 mm, posterior maxillo-alveolar width 37.9 mm, while the mean height value of measured corpus maxillae is 17.6 mm. The maximum variability, along with a high standard deviation is observed in the anterior maxillo-alveolar ( $R = 9.0-48.8$  mm). Other dimensions range within 2 cm. Table II presents dimensions of the palate of all measured maxillas. The length of the palate reads 50.1 mm, length to the sutura palatina transversa 36.5 mm, while the width in the region of the second molar (38.9 mm) is ten mi-

Table 1. Basic Dimensions of Measured Maxillas

Tablica 1. Osnovne dimenzije mjerenih maksila

	$\bar{x}$ (mm)	s	R (mm)
maxillo-alveolar length	54,6	3,9	44,6-64,6
posterior maxillo-alveolar width	37,9	5,5	9,0-48,8
height of corpus maxillae	17,6	4,2	5,2-26,9

Table 2. Dimensions of the Palate

Tablica 2. Dimenzije nepca

	$\bar{x}$ (mm)	s	R (mm)
palatal length	50,1	4,2	41,7-63,6
anterior palatal length	36,5	4,1	26,8-46,3
palatal width	38,9	3,2	30,8-46,2
anterior palatal width	28,5	3,8	17,2-42,5

limeters bigger than the anterior palate width. The range in all variables measured is almost the same about 2 cm. Table III presents the localization of the foramen infraorbitale, while in Table IV distances from the vestibular edge of the alveolar process and the lower edge of the orbit are observable. Recorded are four possible localizations of the foramen infraorbitale in the observed sample of maxillas: above the first premolar in four maxillas, above the interval between two premolar teeth in five maxillas, above the interval between the second premolar and first molar in six, but, most of all, in 37 observed maxillas the foramen is found localized above the second premolar. Results presented in Table IV reveal that the foramen infraorbitale is localized four times closer to the lower edge of the orbit than to the vestibular edge of the

Table 3. Localization of the Foramen Infraorbitale

Tablica 3. Lokalizacija foramena infraorbitale

teeth level	n	%
P <sup>1</sup>	4	4,4
P <sup>1</sup> -P <sup>2</sup>	5	5,6
P <sup>2</sup>	37	41,1
P <sup>2</sup> -M <sup>1</sup>	6	6,7
unknown	38	42,2

Table 4. *Hight of the Maxilla in the Region of the Foramen infraorbitale*Tablica 4. *Visina maksile u području foramena infraorbitale*

	$\bar{x}$ (mm)	s	R (mm)
from the alveolar margin to the foramen infraorbitale	31,4	3,9	20,6–38,5
from the lower margin of the orbit to the foramen infraorbitale	7,0	1,8	4,0–12,7

alveolar process. Both variables measured show great degree of variability, especially the distance from the foramen infraorbitale to the alveolar process, where the range between the maximum and minimum value is almost 2 cm. In more than two thirds of examined maxillas only one foramen incisivum (67.4%) has been found. 23.3% of examined maxillas has two foramina, and very rarely there are more than two (in 8 maxillas). In the studied sample 38 maxillas (42.2%) are edentulous. Teeth have been lost *intra vitam*, and the conclusion is based on the appearance of the alveolar process. All alveoli are healed, and intraradicular and interdental septums are not observed. Table V presents statistically significant difference in basic dimen-

sions of dentate maxillas in respect to the same variables in edentulous ones. The loss of teeth causes the reduction of the maxillo-alveolar length, reduction of the anterior and posterior width, as well as of the hight of the edentulous maxilla. Comparing the mean values of measured variables an average reduction of all dimensions for four milimetres is observed. Table VI presents statistically significant differences in dimensions of the palate with dentate jaw in comparison with the edentulous one. The loss of teeth influences the length of the palate which is reduced for three to four milimetres, while a statistical analysis reveals that the width of the palate is not significantly changed by the loss of teeth. From the results presented in Table VI the difference in the hight in the region of foramen infraorbitale in dentate and edentulous maxillas, is observed. By the teeth loss the distance between the foramen and alveolar margin is particularly reduced, but the results reveal that there is a statistically significant reduction of the distance between the foramen infraorbitale and lower orbital edge. By statistically processed variable values measured in maxillas belonging to various age groups, established is that changes in the posterior maxillo-alveolar width and hight of the maxillar body occur with age, while other changes are not proved as statistically significant.

Table 5. *Influence of the Teeth Loss on Basic Dimensions of the Maxilla*Tablica 5. *Utjecaj gubitka zuba na osnovne dimenzije maksile*

	$\bar{x}^*$ (mm)	s*	$\bar{x}^{**}$ (mm)	s**	T	DF	P
length	52,6	3,6	56,0	3,5	-4,4	88	0,00001
posterior width	53,1	4,6	58,5	4,2	-5,8	88	0,00001
anterior width	35,5	4,2	39,7	5,7	-3,8	88	0,00003
hight of the corpus	15,4	3,9	19,1	3,6	-4,5	86	0,00001

\* = dentulous  
\*\* = edentulous

Table 6. *Influence of the Teeth Loss on the Length of the Palate*Tablica 6. *Utjecaj gubitka zuba na duljinu nepca*

	$\bar{x}^*$ (mm)	s*	$\bar{x}^{**}$ (mm)	s**	T	DF	P
length	47,8	3,8	51,6	3,7	-4,6	86	0,0001
anterior length	34,5	3,6	37,8	3,8	-4,1	87	0,0001

\* = dentulous  
\*\* = edentulous

Table 7. Influence of the Teeth Loss on the Maxillar Hight in the Region of the Foramen infraorbitale

Tablica 7. Utjecaj gubitka zuba na visinu maksile u području foramena infraorbitale

	$\bar{x}^*$ (mm)	s*	$\bar{x}^{**}$ (mm)	s**	T	DF	P
alveolar margin to foramen infraorbitale	30,1	3,9	32,3	3,6	-2,8	87	0,0056
lower margin of the orbit to foramen infraorbitale	6,3	1,3	7,4	1,8	-2,9	87	0,0036

\* = dentulous

\*\* = edentulous

Table 8. Age Influence on Maxillar Dimensions

Tablica 8. Utjecaj dobi na dimenzije maksile

	$\bar{x}^*$ (mm)	s*	$\bar{x}^{**}$ (mm)	s**	$\bar{x}^+$ (mm)	s+	F	DF	P
posterior width	57,5	4,4	58,2	5,2	53,9	4,8	6,8	2,80	0,017
hight of the corpus	18,6	3,3	18,7	4,1	15,9	4,4	4,3	2,78	0,0159

\* = adultus from 21 to 40 years of age

\*\* = maturus from 41 to 60 years of age

+ = senilis over 60

## Discussion

That morphogenetic characteristics of the studied sample comply with values described in maxillas belonging to the European whites of the same absolute age, can be determined by comparing the presented results with more recent craniometric researches of the maxilla by Rotstock and col. (11) and with other authors (10, 12-15) comprehensive studies. The loss of teeth causes changes in biomechanical conditions and in interaction of forces which act upon the maxillar region. Besides, one should take into consideration that the mechanical entriety consists of the whole skeleton of the face with frontal bones and the anterior and medial cranial cavity. This mechanical entriety, beside the minimum weight, should have the maximum rigidity and ability to take up and distribute strains which occur in the process of mastication (16-18). Strains occurring in the process of mastication are not evenly distributed to all parts of the jaw. According to Champy and Lodde (19), these strains is averagely 6.6 MP in the region of molars, 4.8 MP in the region of canines,

and 2.9 MP in the region of incisives. By the loss of teeth the distribution and absolute values of strains change. In edentulous jaws, forces and consequent strains in mastication are significantly smaller, resulting in the partition and reduction of bones. Geometry changes, according to Moss (20) at least in the area where the »functional matrix« is being responsible, so to say in the component of the above mentioned parametres for which epigenetic factors assume responsibility. Atrophy of the alveolar ridge causes the reduction of the length and width of the edentulous jaw, in the molar as well as in the anterior part of the bone. Considerately stronger reabsorption of the anterior part of the maxilla, as Mercier (21) described it, is also recorded in the measured sample, and it is manifested as the corpus hight reduction for more than one fifth. The primary supporting area for the complete upper prosthesis is the hard palate, namely processus palatinus maxillae and processus horisontalis ois palatini (22) which are not reabsorbed by the loss of teeth. Our results, however, reveal that although constant the width of the palate, the

loss of teeth causes the reduction of its anterior and overall length. Keros (23) studied the localization of the foramen infraorbitale in order to obtain a more accurate performance of conductive anaesthesia of n. infraorbitalis. By the loss of teeth the opening comes closer to the alveolar margin of the bone, but the presented results show that in the same time a significant reduction in the distance from the foramen infraorbitale and the lower edge of the orbit occur. In the literature, changes in jaws are frequently connected with age (24–26). By age adjusted distribution of the studied sample and by comparing the morphometric characteristics, established is that age does not have any influence on most of measured variables. The reduction of the maxillar body and the posterior width of the maxilla evident only in the group of maxillas belonging to persons over sixty, are probably the result of the teeth loss, rather than age (a statistic cross-analysis show that edentulous jaws are most frequent in the most advanced age

group). Clinical studies (21, 27) also show that these two variables in fact, are first liable to changes caused by the loss of teeth.

### Conclusion

Morphometric characteristics of maxillas belonging to the recent adult population of Croatia do not differ from characteristics of maxillas of other white ethnic groups studied up to now. The maxilla changes with the loss of teeth. First of all, the bone reabsorption in the alveolar process occur manifested in the reduction of width and height of the maxilla, while the width of the palate remains unchanged. In the later stage, the complete loss of teeth leads up to overall atrophy of the maxilla. By the change of shape and dimensions of the upper jaw, the appearance of the medial third of the face changes, and the whole physiognomy as well. Advancing of age, if not accompanied by the loss of teeth, does not have a significant influence on morphometric characteristics of the upper jaw.

## UTJECAJ GUBITKA ZUBA NA MORFOMETRIJSKE KARAKTERISTIKE GORNJE ČELJUSTI

### Sažetak

*Analizom 90 lubanja odraslih osoba, oba spola metodom po Martinu i Salleru utvrđeno je 12 osnovnih morfometrijskih karakteristika maksila recentne populacije Hrvatske. Prikazane su razlike u morfologiji čeljusti sa zubima i onih bez zuba.*

*Utvrđeno je da se morfometrijske karakteristike gornjih čeljusti recentne populacije Hrvatske bitno ne razlikuju od karakteristika maksila drugih etničkih skupina pripadnika bijele rase iste apsolutne tarosti.*

*Promjenom biomehaničkih uvjeta i sprega sila uslijed gubitka zuba dolazi do resorpcije kosti. Prvo atrofira alveolarni nastavak, uslijed čega se maksila skraćuje i postaje uža kako u molarnom ako i u prednjem dijelu kosti. Širina nepca je konstantna, međutim, dolazi do smanjenja njegove duljine. Foramen infraorbitale se resorpcijom alveolarnog grebena približava alveolarnom rubu kosti, međ tim uslijed cjelokupne atrofije kosti smanjuje se i njegova udaljenost od orbitalnog ruba.*

*Porast dobi, ukoliko ne postoji istovremeni gubitak zuba, nema načajni utjecaj na morfometrijske karakteristike maksile.*

*Ključne riječi: maksila, morfologija, gubitak zuba*

Address for correspondence:  
Adresa autora:

Sanja Percač, M.D. Ph.D.  
Department of Anatomy  
»Drago Perović«  
School of Medicine,  
University of Zagreb  
Šalata 11, 41000 Zagreb  
Croatia

## Literatura

1. ŠERCER A, KRMPOTIĆ-NEMANIĆ J. Rezultati naših istraživanja na području evolucije čovječe baze lubanje. Rad Med Fak 1960; 8:215–222.
2. KRMPOTIĆ-NEMANIĆ J. Anatomija čovjeka. 3. izd. Zagreb: JUMENA, 1982.
3. RADIONOV D. Rast gornje čeljusti – funkcionalna kranijalna analiza (Magisterij). Zagreb: Stomatološki fakultet Sveučilišta u Zagrebu, 1978.
4. RUDAN P. Odnos širine nosne šupljine prema interorbitalnoj udaljenosti: prilog proučavanju rasta interorbitalnog područja (funkcionalna kranijalna analiza) (Disertacija). Zagreb: Medicinski fakultet Sveučilišta u Zagrebu, 1974.
5. TESTUT L. Traité d'anatomie humaine. Paris: G. Doin, 1928.
6. NIKOLIĆ V, HUDEC M. Principi i elementi biomehanike. Zagreb: Školska knjiga, 1988.
7. KOBLER P, VIRAG M. Povećanje alveolarnog nastavka maksile koštanim transplantatom rebra. Chir Maxillofac Plast 1983; 13(1):19–23.
8. MALONEY PL, WELCH TB, DOKU HC. Augmentation of the atrophic edentulous maxilla with hydroxylapatite. Oral surg oral med oral pathol 1990; 69(5):533–538.
9. BROOK IM, CRAIG GT, DOUGLAS CWI, LAMB DI, VAN NOORT R. Management of mobile fibrous ridge in the atrophic maxilla using porous hydroxylapatite blocks. Brit Dent J 1987; 162:413.
10. MARTIN R, SALLER K. Lehrbuch der Anthropologie. Dritte Auflage. Stuttgart: Gustav Fischer, 1957.
11. ROTTOSTOCK F, MAUTRICH U, ZUHRT R. Kranimetrische Untersuchungen am Oberkifer als Hilfsmittel zur Populationsunterscheidung. Gegenbaurs morph Jah 1983; 129(5):533–538.
12. MARTIN R. Lehrbuch der Anthropologie. Jena: Gustav Fischer, 1914.
13. JO A, BUKOVIĆ D. Morfološka istraživanja svoda usne šupljine. Rad Med Fak 1970; 18(3):239–250.
14. KALLAY J. Komparativne napomene o čeljustima krapinskih praljdi s obzirom na položaj među hominidima. U: Zbornik radova Naučnog skupa prigodom 70-godišnjice otkrića krapinskih praljdi. Zagreb, 1969. Zagreb: Izdavački zavod JAZU 1970:153–164.
15. WOLPOFF MH. Paleoanthropology. New York: Alfred A Knopf, 1980.
16. KEROS-NAGLIĆ J. Istraživanje deformacija koštane strukture orofacijalnog skeleta u stomatološki značajnim područjima (Disertacija). Zagreb: Stomatološki fakultet Sveučilišta u Zagrebu, 1984.
17. KEROS J, MUFTIĆ O. Orofacial skeleton firmness as the basis of the mechanical theory of fracture in shock effect. Acta med iug 1986; 40:249–262.
18. FERRE JC, CHEVALIER C, ROBERT R, DEGREZ J, LE CLOAREC AY, LEGOUX R, ORIO E, BARBINN JY. Reflection on the mechanical structure of the base of the skull and on the face Part 1: Classical theories, observed structures. Surg Radiol Anat 1989; 11:41–48.
19. FERRE JC, CHEVALIER C, ROBERT R, LE CLOAREC AY, BARBIN JY. Reflection on the mechanical structure of the base of the skull and on the face Part 2: Discussion, current concepts and theories. Surg Radiol Anat 1989; 11:35–140.
20. MOSS ML. Twenty years of functional cranial analysis. Am J Orthodont 1972; 61:479–485.
21. MERCIER P. Ridge reconstruction with hydroxylapatite, Part 1. Anatomy of the residual ridge. Oral Surg Oral Med Oral Pathol 1988; 65:505–510.
22. JACOBSON TE, KROL AJ. Acontemporary review of the factors involved in complete dentures, Part III: Support. J Prosthet Dent. 1983; 49:306–313.
23. KEROS P. Anatomska podloga uspješne provodne anestezije u plastičnoj kirurgiji glave i vrata (Disertacija). Zagreb: Medicinski fakultet Sveučilišta u Zagrebu, 1962.
24. DOMNIĆ-STOŠIĆ T, BOGDANOVIĆ D, MRVALJEVIĆ D. O promjenama alveolarnog dela donje vilice u odmaklom životnom dobu. Stomatol Glas Srb 1978; 25:209–213.
25. PERCAČ S. Biometrijske karakteristike donje čeljusti –promjene u odrasloj dobi. Medicinar 1978–88; 36(1):9–15.
26. CANKI N, KOSTOVIĆ I, RUDAN P, RUKAVINA V. Promjene alveolarnog nastavka donje čeljusti u odmakloj životnoj dobi. Medicinar 1966; 17:171–180.
27. MERCIER P. Ridge reconstruction with hydroxylapatite. Part 2. Ridge reconstruction based on residual anatomic structure. Oral Surg Oral Med Oral Pathol 1988; 65(6):641– 653.