

# First Quadricuspid Aortic Valve to Be Reported in Croatia

Ranko Ugljen<sup>1</sup>, Robert Blažeković<sup>1</sup>, Krunoslav Šego<sup>1</sup>, Grgur Dulić<sup>1</sup>, Igor Lekšan<sup>1</sup> and Nikola Gotovac<sup>2</sup>

<sup>1</sup> »J. J. Strossmayer« University, Osijek University Hospital Centre, Department of Cardiac Surgery, Osijek, Croatia

<sup>2</sup> Požega County Hospital, Department of Radiology, Požega, Croatia

## ABSTRACT

*Quadricuspid aortic valve is a rare congenital malformation of the aortic valve. Even in the era of a transthoracic and transesophageal ultrasound the occurrence is sometimes missed. Aortic incompetence occurs usually in 5th or 6th decade of life requiring surgical intervention. We report on a 70-year-old woman who presented with exertional dyspnea. In a diagnostic setting transthoracic ultrasound, helical computed tomography scan of the chest and coronary angiography including aortography were performed. Unusual aortic valve anatomy was not described as it was not expected. Finally, the diagnosis of this congenital malformation was established intraoperatively.*

**Key words:** heart valve diseases, aortic valve insufficiency, cardiovascular abnormalities

## Introduction

Quadricuspid aortic valve (QAV) is extremely rare congenital aortic valve malformation. Usually it appears as isolated malformation, but it can be associated with other congenital cardiac abnormalities such as pulmonic valve stenosis, nonobstructive cardiomyopathy, ventricular septal defect, patent ductus arteriosus and subaortic fibromuscular stenosis<sup>1,2</sup>. QAV is, however, mostly associated with abnormally placed coronary ostia. Therefore, caution is necessary when placing aortic prosthesis<sup>2</sup>.

## Case Report

A 70-year-old woman was admitted to a county hospital due to shortness of breath and chest discomfort. Prior to admission symptoms had progressed. Since her adolescence she was treated for »cardiac enlargement«. She didn't have any medical documentation.

On examination her blood pressure was 130/80 mm Hg and auscultation revealed mild systolic and diastolic murmur on the second right intercostal space. Surface ECG demonstrated regular sinus rhythm with signs of left ventricular hypertrophy.

The patient underwent two-dimensional (2D) echocardiography showing mild aortic stenosis with maximal transvalvular gradient of 28 mmHg and severe aortic re-

gurgitation. Left ventricle was severely dilated with end-diastolic diameter of 71 mm. Accordingly, ejection fraction was reduced to 43%. At that time, mitral regurgitation 3+ was verified with enlargement of left atrium up to 52 mm. A computed tomography chest scan with intravenous administration of a contrast was primarily performed to rule out an aortic dissection. None of the pathologic changes in the chest were observed and aortic valve anatomy was not described. The patient was then transferred to the tertiary institution for the invasive cardiac evaluation. Coronary angiogram was normal. Figure 1 presents the aortography which was performed

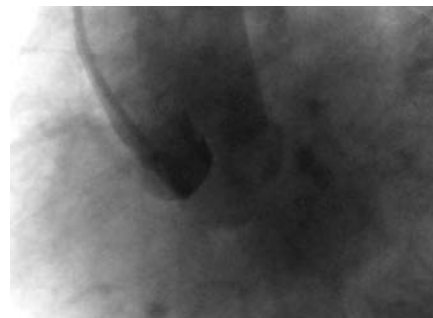


Fig. 1. Aortography. By careful viewing we can notice four cusps of the aortic valve.

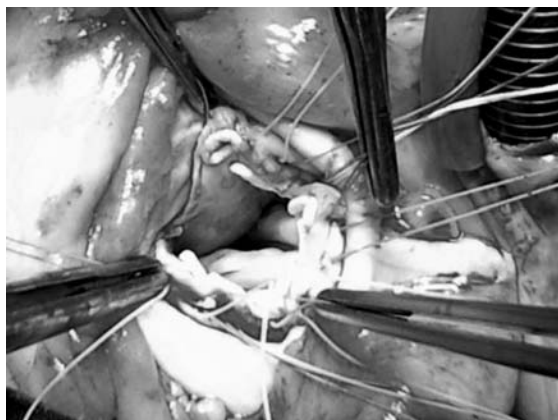

Fig. 2. The aortic valve is excised. Four forceps holding four sutures reinforced by felt pladgets on the aortic valve commissures.

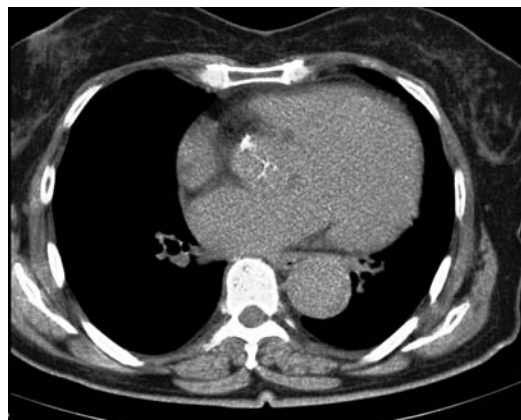

Fig. 3. Helical computed tomography of the aortic valve, not cardiac gated, showing typical X-, instead of Y-shaped closure of the aortic valve.

during the invasive evaluation. Left ventriculography did not confirm mitral regurgitation. The patient was then scheduled for surgical correction. Prior to the surgery, transesophageal echocardiography had been performed. There was a trace of mitral regurgitation even at the state of the volume overload and blood pressure of 170/110 mmHg. Therefore, we decided to perform aortic valve replacement. QAV was noticed at that time for the first time, although thorough diagnostic procedures were done (Figure 2). Retrospectively, we evaluated anatomy of the aortic valve obtained by the helical computed tomography chest scan (Figure 3). According to her life expectancy, we have implanted bioprosthetic valve (diameter of 21 mm). The patient made an uneventful postoperative recovery.

## Discussion

Roughly, 200 case reports of QAV have been published until now. Simods report an incidence of 0,008% in a pooled series of 25666 autopsies<sup>3</sup>. There are some suggestions that Simods' autopsy incidence of QAVs is probably an underestimate. Feldman reports a slightly higher echocardiographic incidence of 0,043% in 13805 echocardiograms<sup>4</sup>. According to Hurwitz and Roberts there are seven anatomic variations of quadricuspid semilunar valves<sup>5</sup>. Type A, according to the same authors, is the an-

atomic variation having four equally sized cusps and this type appeared to be present in our case as well. Type A (four equal cusps), type B (three equal cusps, one smaller cusp) and type C (two equal larger cusps, two equal smaller cusps) are reported in over 85% of all cases. Balington reported the first case of QAV and Robicsek reported the first aortic valve replacement due to QAV<sup>6</sup>. At that time QAV was mainly diagnosed at autopsy and during the surgery. The first case diagnosed by aortography was reported by Peretz<sup>7</sup>. In our case we failed to describe the anatomy of the aortic valve prior to the surgery, even though comprehensive diagnostic procedures were carried out. This is important since additional congenital cardiac malformation could be associated. The most prevalent is displacement of coronary orifice<sup>1</sup>. Therefore, caution is necessary to avoid occlusion of the coronary ostium when placing a prosthesis. Recently, there were some attempts to repair the aortic valve. Tricuspidization of regurgitant tricuspid as well as bicuspid aortic valves was reported in children and young adults. However, when compared to bicuspidization or preservation of native bicuspid valve, tricuspidization has been found to be risk factor for late repair failure<sup>8</sup>.

Luciani et al. proposed bicuspidization of QAV which throws a new light on the management of QAV, although long-term results are not available<sup>9</sup>.

## REFERENCES

1. TUTAREL O, J Heart Valve Dis, 13 (2004) 534. — 2. TIMPERLEY J, MILNER R, MARSHALL JA, GILBERT TJ, Clin Cardiol, 25 (2002) 548. DOI: 10.1002/clc.4950251203. — 3. SIMONDS JP, Am J Med Sci, 166 (1923) 584. DOI: 10.1097/00000441-192310000-00013 — 4. FELDMAN BJ, KHANDHERIA BK, WARNES CA, SEWARD JB, TAYLOR CL, TAJIK AJ, Am J Cardiol, 65 (1990) 937. DOI: 10.1016/0002-9149(90)91446-D — 5. HURWITZ LE, ROBERTS WC, Am J Cardiol, 31 (1973) 623. DOI: 10.1016/0002-9149(73)90332-9 — 6. ROBICSEK F, SANGER PW, DAU-

GHERTY HK, MONTGOMERY CC, Am J Cardiol, 23 (1969) 288. DOI: 10.1016/0002-9149(69)90080-0 — 7. PERETZ DI, CHANGFOOT GH, GOURLAY RH, Am J Cardiol, 23 (1969) 291. DOI: 10.1016/0002-9149(69)90081-2 — 8. LANGER F, AICHER D, KISSINGER A, WENDLER O, LAUSBERG H, FRIES R, SCHÄFERS HJ, Circulation, 110 (11 Suppl 1) (2004) 1167. DOI: 10.1161/01.CIR.0000138383.01283.b8 — 9. LUCIANI GB, MORJAN M, FAGGIAN G, MAZZUCCO A, Interact Cardiovasc Thorac Surg, 11 (2010) 348. DOI: 10.1510/icvts.2010.237404.

R. Blažeković

»J. J. Strossmayer« University, Osijek University Hospital Centre, Department of Cardiac Surgery, J. Huttlera 4,  
31000 Osijek, Croatia  
e-mail: blazekovic.robert@kbo.hr

## IZVJEŠTAJ O PRVOM SLUČAJU KVADRIKUSPISNOG AORTNOG ZALISTKA U HRVATSKOJ

### SAŽETAK

Kvadrikuspisni aortni zalistak rijetka je kongenitalna malformacija aortnog zaslitka. Čak se i u eri transtorakalnog i transezofagijskog ultrazvuka njezina pojavnost ponekad propusti. Aortna se insuficijencija obično javlja u petoj ili šestoj dekadi života zahtijevajući kiruršku intervenciju. Prijavljujemo slučaj 70-godišnje gospođe koja je imala simptome zaduhe u naporu. Tijekom dijagnostičke obrade učinjeni su transtorakalni ultrazvuk srca, kompjuterska tomografija prsišta s kontrastom te koronarografija uključujući aortografiju. S obzirom da nije očekivana, ova neobična anatomija aotnog zalistka nije opisana. U konačnici, dijagnoza ove kongenitalne malformacije postavljena je intraoperacijski.