

Acute Oxcarbazepine-Induced Hepatotoxicity in a Patient Susceptible to Developing Drug-Induced Liver Injury

Miljenka Planjar-Prvan¹, Ana Bielen², Ana Sruk¹, Marinko Marušić³ and Ivan Bielen¹

¹ University of Zagreb, »Sveti Duh« University Hospital, University Department of Neurology, Zagreb, Croatia

² University of Zagreb, Faculty of Food Technology and Biotechnology, Laboratory for Biology and Microbial Genetics, Zagreb, Croatia

³ University of Zagreb, »Sveti Duh« University Hospital, Department of Hepatogastroenterology, Zagreb, Croatia

ABSTRACT

Oxcarbazepine (OXC) is generally accepted as a drug without risk of severe drug-induced hepatotoxicity, but according to recently reported pharmacovigilance data this statement has been challenged. However, in the literature there have been no reports of acute OXC-induced hepatotoxicity without systemic manifestations of Drug Rash with Eosinophilia and Systemic Symptoms (DRESS) syndrome. We present a female with seizures one month after delivery who had borderline elevated liver enzymes prior to the initiation of OXC treatment. Two weeks after introducing OXC, highly elevated liver enzymes were found. After discontinuation of OXC the enzymes continued to rise for another week, and afterward gradually decreased. The causal relationship with OXC intake was determined to be highly probable. Two years later, the transitory elevation of liver enzymes was observed during the treatment of acute tonsilopharyngitis with amoxicillin + clavulanic acid. The repeated elevation of liver enzymes related to use of different drugs might indicate patient's susceptibility for drug induced liver injuries. We suggest that monitoring of liver function tests would be clinically rational for early detection of acute OXC-induced liver hepatotoxicity in the patients with clinical and/or laboratory features which might be interpreted as possible risk factors of the increased susceptibility to drug induced liver injuries.

Key words: oxcarbazepine, hepatotoxicity, reactive metabolite, 9-acridan, idiosyncratic reaction

Introduction

Hepatotoxicity of the antiepileptic drugs (AEDs) is a complex phenomenon with a wide spectrum of clinical manifestations ranging from a mild increase of serum liver enzyme levels to a potentially fatal drug-induced liver failure¹. Albeit rare, these side effects can be life threatening, and so it is of paramount importance to recognize them early^{1,2}.

Oxcarbazepine (OXC) is generally accepted as a drug with a lower incidence of adverse side effects than carbamazepine (CBZ). In the Summary of Product Characteristics (SPC) of OXC it is reported that, according to the Council for International Organizations of Medical Sciences (CIOMS) classification system, the incidence of hepatitis is very rare (<1/10000), so that the liver function testing is recommended only when liver disease is suspected³. However, according to recently reported pharmacovigilance data, it has been proposed that low frequency of the OXC-induced Drug Rash with Eosinophilia

and Systemic Symptoms (DRESS) syndrome, which includes hepatotoxicity, mainly reflects a less frequent use of OXC in comparison to CBZ⁴. Except for DRESS syndrome⁵, in a recent study the case of OXC-induced liver adenoma has been reported⁶. To our knowledge, there have been no reports of acute OXC-induced hepatotoxicity.

The objective of our manuscript is to present a young female patient with severe OXC-induced hepatotoxicity and to discuss possible mechanisms that could have caused the observed hepatotoxicity.

Case Report

The patient is a twenty-three year old woman who experienced several seizures one month post partum. OXC was initiated for seizure control.

Family history was positive for epilepsy in a paternal uncle. The patient had febrile seizures at the ages of 6 and 18 months, for which she was treated with phenobarbital. She had no other risk factors for epilepsy. She was hospitalized for uterine bleed in the first trimester of her pregnancy and treated with dydrogesterone for 10 days. She gained 20 kg during pregnancy, while her baseline weight was 53 kg. The borderline alanine aminotransferase (ALT) elevation was reported during pregnancy. One month after delivery, the patient experienced several partial complex seizures with oral automatisms and change in consciousness. A diagnosis of localization related epilepsy was established based on clinical description and EEG changes. A routine EEG revealed non-specific abnormalities in the baseline activity with minor left frontotemporal changes. The EEG following sleep deprivation confirmed left frontotemporal irritative changes. The brain MRI scan was unremarkable.

She was not breastfeeding and OXC was prescribed at 300 mg twice a day (19th April 2007). Previously made baseline laboratory studies were normal except for borderline elevated aspartate transaminase (AST) and gamma glutamyl transpeptidase (GGT) (13th April). Because of these slight abnormalities, a laboratory checkup was made on May 4th and revealed significantly elevated liver enzymes (Table 1). The patient did not report these laboratory abnormalities until 10 days later, when she was subsequently hospitalized. She reported fatigue and appetite loss; she was afebrile and her physical and neurological examinations did not reveal any clinically significant abnormalities. She was not taking any concomitant medication and an OXC-induced liver injury was suspected. On May 15th, OXC was discontinued and therapy with gabapentin was initiated. After three days maintenance dose of gabapentin (900 mg/day) was achieved.

TABLE 1
DYNAMICS OF AST, ALT, GGT AND ALP THAT ARE EXPRESSED IN UPPER LIMITS OF NORMAL (ULN) VALUES

Date	AST	ALT	GGT	ALP
April 13th	1.2	1.0	1.2	
April 19th	OXC introduced			
May 7th	5.2	6.6	6.8	
May 14th	5.0	8.9	6.1	2.0
May 15th	OXC switched to GBP			
May 16th	4.8	8.3	10.0	2.2
May 19th	10.8	13.0	9.9	
May 21st	11.6	17.3	10.4	
May 24th	5.1	12.5	9.9	1.8
May 28th	4.0	9.6	10.4	2.0
July 11th	1.5	3.7	3.5	
Sept 10th	0.7	1.0	2.3	1.0

AST – aspartate transaminase, ALT – alanine transaminase, GGT – glutamyl transpeptidase, ALP – alcal phosphatase

However, liver enzyme abnormalities continued for another six days, followed by a gradual improvement, as it is presented in Table 1.

The findings of bilirubin, coagulopathy testing, and proteinogram were normal. The blood count did not reveal an eosinophilia; only slight lymphocytosis was present (WBC $5.28 \times 10^9/L$, lymphocytes 46.6%). The ultrasound of the liver showed hyperechogenic liver parenchyma with a normal-caliber common bile duct without evidence of obstruction or other biliary tract abnormalities. The patient had mildly elevated total cholesterol (5.41 mmol/L). Additional studies were performed to rule out preexisting liver conditions. The patient had elevated anti-HBs (615 IU/L) as a result of previous vaccination against Hepatitis B, as well as other negative markers for hepatitis B and hepatitis C. Epstein Barr virus (EBV) and cytomegalovirus (CMV) serology revealed a previous EBV (VCA IgG 142 AU/mL; EBNA IgG > 200 AU/mL) and CMV (IgG 1.3 IU/mL) infection. Additional testing excluded liver metabolic abnormalities (Fe, UIBC, TIBC, serum ferritin level, transferrin saturation; serum Cu/24-hour urine; serum ceruloplasmin; Alpha 1 – antitrypsin) as well as autoimmune hepatitis. Subsequently, the good clinical remission was achieved and she was under regular follow-up by epileptologist and gastroenterologist. Two years later, in the May of the 2009 the transitory elevation of liver enzymes was observed again during the treatment of acute tonsilopharyngitis with amoxicillin + clavulanic acid (maximum upper limits of normal values (ULN) were: AST 1.6, ALT 3.7, GGT 2.3).

Discussion

It is widely regarded that OXC and CBZ have a similar efficacy, but that OXC is better tolerated. OXC can induce mild to moderate liver enzyme abnormalities, but not a clinically significant hepatotoxicity⁷. However, similar to the experience with other AEDs, the evaluation of rare adverse effects requires the years-long post-marketing monitoring of a large number of patients. According to the recently reported pharmacovigilance data, the safety of OXC in regards to liver function has been challenged⁴.

Based on clinical presentation and diagnostic workup, we conclude that the reported patient had an OXC-induced liver injury. Additional diagnostic studies have confirmed a previous CMV and EBV infection, and excluded hepatitis B and C, metabolic liver abnormalities (Wilson's disease, hemochromatosis, alpha-1-antitrypsin deficiency, and autoimmune hepatitis). According to the CIOMS scale^{8,9}, causal relationship between the OXC intake and hepatotoxicity would be »probable« (score 8). Further association with pregnancy, as one of the risk factor for drug induced liver injury, would increase this causal relationship in our patient to »highly probable or definite« (score 9).

It is reported that a hepatocellular lesion may represent an additional signal needed to initiate the process of a

hypersensitivity reaction¹⁰. Our patient had borderline values of laboratory liver tests prior to OXC treatment and we believe that these abnormalities might indicate slight hepatic dysfunction. It is known that hepatic metabolism can be altered during pregnancy^{11,12}, but a minimal elevation of liver enzymes might have also been due to liver steatosis, associated with 20 kg weight gain during pregnancy. We are aware that idiosyncratic type of drug induced liver injuries cannot be predicted and that routine check of liver tests after starting antiepileptic drug therapy has not been considered to be cost-effective¹³. However, based on the clinical course of the reported patient, it seems that the association between the hypothetical risk factors (previous pregnancy, abnormalities of liver enzymes) might have not been interpreted as accidental, and we believe that monitoring of liver enzymes after introducing of OXC in this case was clinically rational.

The fact that our patient also had transitory elevation of liver enzymes during the treatment with amoxicillin + clavulanic acid might be interpreted as our patient's susceptibility for drug induced liver injuries. In regard to possible pathophysiological mechanisms leading to OXC-induced idiosyncratic hepatotoxicity, it is important to emphasize structural similarities between CBZ and OXC. While the mechanisms of idiosyncratic reactions are not yet elucidated, it is assumed that they are caused by reactive metabolites, which are generated in small amounts during the drug metabolism. In susceptible individuals these metabolites are generated at increased rate and/or are not effectively cleared. Reactive metabolites may cause hepatotoxicity directly or by inducing immunologic reactions¹.

It has been hypothesized that the reactive CBZ metabolite which induces hepatotoxicity is an arene oxide, or, more specifically, an unstable and reactive CBZ epoxide¹⁴.

However, some new studies have not confirmed this hypothesis, in part because of the difficulties in achieving a definitive proof of the arene-oxide due to its high instability¹⁵. Furst and Utrecht identified some other CBZ metabolites as reactive: 9-acridine carboxaldehyde, imino-stilbene and iminoquinone¹⁶. In addition, based on the structural similarity, they proposed 9-hydroxymethyl-10-carbamoyl-acridan (9-acridan), acridine and acridone to be potentially reactive¹⁷. Recently, in the sera of patients treated with OXC monotherapy and those with CBZ monotherapy, shared metabolites 9-acridan and 3-hydroxycarbamazepine were detected². Figure 1 shows metabolic routes leading to formation of potentially reactive metabolite 9-acridan during biotransformation of CBZ and OXC. An additional reactive metabolite iminoquinone can be generated from 3-hydroxycarbamazepine².

In conclusion, we would like to emphasize that OXC and CBZ have some shared metabolites, a few of which are reactive. Those reactive metabolites, by analogy with CBZ hepatotoxicity, could also induce OXC hepatotoxicity. Possible common mechanisms of adverse reactions for these two drugs are also supported by similar side effect profile and observed skin cross-reactivity¹⁸.

To our knowledge, this is the first time that the acute OXC-induced hepatotoxicity is reported without systemic symptoms of DRESS syndrome. We suggest that routine monitoring of liver function tests would be indicated for early detection of acute OXC-induced liver hepatotoxicity in the patients with clinical and/or laboratory features which might be interpreted as possible risk factors for drug induced liver injuries (e.g. previously known borderline values of laboratory liver tests, pregnancy, liver steatosis, elevation of liver enzymes during the treatment with other drugs etc.).

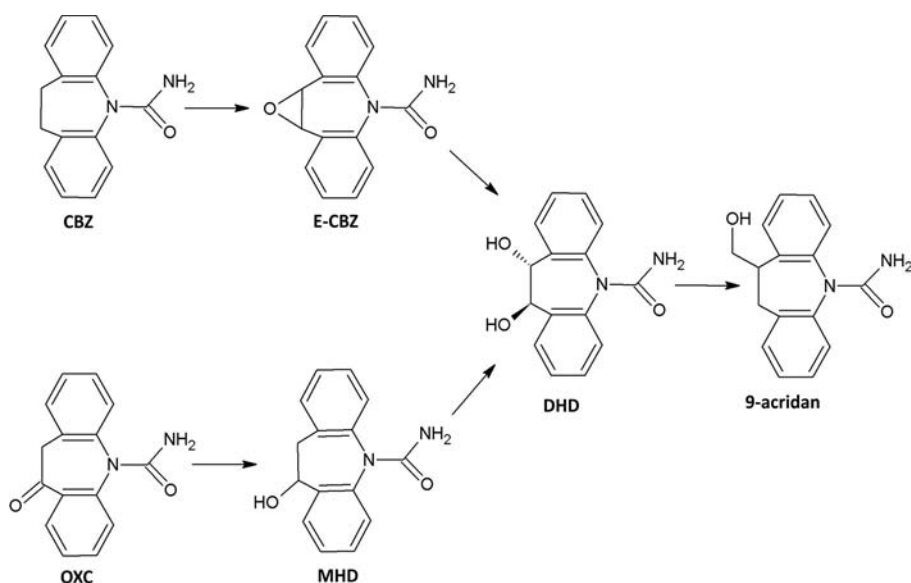


Fig. 1. Formation of 9-acridan during metabolism of CBZ and OXC (modified from Breton et al., 2005). The figure presents only CBZ and OXC metabolic pathways that take part in the generation of 9-acridan; other biotransformation pathways of CBZ and OXC are not presented here. Abbreviations: MHD – 10-hydroxy-10,11-dihydro-carbamazepine, E-CBZ – carbamazepine-10,11-epoxide, DHD – 10,11-dihydro-10-carbamoyl-acridan, 9-acridan-9-hydroxymethyl-10-carbamoyl acridan.

REFERENCES

1. BJÖRNSSON E, Acta Neurol Scand, 118 (2008) 281. DOI: 10.1111/j.1600-0404.2008.01009.x. — 2. BRETON H, COCIGLIO M, BRESOLLE F, PEYRIERE H, BLAYAC JP, HILLAIRE-BUYS D, J Chromatogr B Analyt Technol Biomed Life Sci, 828 (2005) 80. — 3. The electronic Medicines Compendium (eMC): Summary of Product Characteristics last updated on the eMC: 01/09/2009., accessed 08.01.2010. Available from: URL: http://emc.medicines.org.uk/emc/assets/c/html/DisplayDoc.asp?DocumentID=2673#UNDESIRABLE_EFFECTS. — 4. LE LOUËT H, THOMAS L, BABAI S, Eur J Neurol, 15 (2008) e43. DOI: 10.1111/j.1468-1331.2008.02111.x. — 5. BOSDURE E, CANO A, ROQUELAURE B, TEYNAURD R, BOYER M, VIARD L, SARLES J, Arch Pediatr, 11 (2004) 1073. — 6. LAUTZ TB, FINEGOLD MJ, CHIN AC, SUPERINA RA, J Pediatr Surg, 43 (2008) 751. DOI: 10.1016/j.jpedsurg.2007.11.036. — 7. REINIKAINEN KJ, KERÄNEN T, HALONEN T, KOMULAINEN H, RIEKKINEN PJ, Epilepsy Res, 1 (1987) 284. — 8. DANAN G, BENICHOU C, J Clin Epidemiol, 11 (1993) 1323. — 9. ANDRADE RJ, ROBLES M, FERNÁNDEZ-CASTAÑER A, LÓPEZ-ORTEGA S, LÓPEZ-VEGA MC, LUCENA MI, World J Gastroenterol, 13 (2007) 329. — 10. CASTELL JV, CASTELL M, Curr Opin Allergy Clin Immunol, 6 (2006) 258. — 11. PENELL PB, Neurology, 61 (2003) S35. — 12. DELLUC C, COSTEODAT-CHALEMAEU N, LEROUX G, IMBERT G, LE THI HUONG D, VAUTHIER-BROUZES D, PIETTE JC, CHAZOULLERES O, CACOUB P, Rev Med Interne, 30 (2008) 508. DOI: 10.1016/j.revmed.2008.09.012. — 13. CAMFIELD P, CAMFIELD C, DOOLEY J, FARRELL K, HUMPHREYS P, LANGEVIN P, CMAJ, 140 (1989) 1303. — 14. LEEDER JS, PIRMOHAMED M, Anticonvulsant agents. In: KAPLOWITZ N, DELEAVE LD (Eds) Drug-induced liver disease (Marcel Dekker Inc, New York, 2003). — 15. BU HZ, KANG P, DEESE AJ, ZHAO P, POOL WF, Drug Metab Dispos, 33 (2005) 1920. — 16. FURST SM, UETRECHT JP, Int J Immunopharmacol, 17 (1995) 445. — 17. FURST SM, UETRECHT JP, Biochem Pharmacol, 45 (1993) 1267. — 18. DAM M, Epilepsia, 35 (1994) S23.

M. Planjar-Prvan

University of Zagreb, »Sveti Duh« University Hospital, University Department of Neurology, Sveti Duh 64, 10000 Zagreb, Croatia
e-mail: mplanjarprvan@net.hr

AKUTNA HEPATOTOKSIČNOST INDUCIRANA OKSKARBAZEPINOM U OSOBE PODLOŽNE RAZVOJU JETRENOG OŠTEĆENJA UZROKOVANOG LIJEKOVIMA

SAŽETAK

Okskarbazepin (OXC) je općenito prihvaćen kao lijek koji nije rizičan za razvoj teškog jetrenog oštećenja uzrokovanog lijekovima, međutim navedena je tvrdnja osporena nedavno objavljenim podacima farmakovigilancije. Prema našim saznanjima, u literaturi nema objavljenih slučajeva akutne okskarbazepinom inducirane hepatotoksičnosti bez sistemskih manifestacija DRESS sindroma (Drug Rash with Eosinophilia and Systemic Symptoms). U prikazu slučaja, radi se o ženi koja je 6 tjedana nakon poroda imala nekoliko epileptičkih napadaja zbog čega joj je propisan okskarbazepin. Prije započetog liječenja zabilježene su granično povišene vrijednosti jetrenih enzima. Nakon dva tjedna provođenja terapije okskarbazepinom nađene su izrazito povišene vrijednosti jetrenih enzima koje su nastavile rasti još tjedan dana nakon prekida terapije, a tada su se počele postupno smanjivati. Prema CIOMS/RUCAM skali uzročna povezanost s primjenom okskarbazepina je ocijenjena kao »visoko vjerojatna«. Dvije godine kasnije, za vrijeme liječenja akutnog tonzilofaringitisa kombinacijom amoksicilina i klavulonske kiseline, zamiječeno također je prolazno povišenje jetrenih enzima. Opetovano povišenje jetrenih enzima povezano uz primjenu drugih lijekova moglo bi upućivati na podložnost razvoju jetrenog oštećenja uzrokovanog lijekovima. Smatramo da je monitoriranje testova jetrene funkcije klinički racionalno u ranoj detekciji akutne okskarbazepinom inducirane hepatotoksičnosti u svih pacijenata s kliničkim i/ili laboratorijskim obilježjima koja bi mogla biti interpretirana kao mogući rizični čimbenici za povećanu podložnost razvoju jetrenog oštećenja uzrokovanog lijekovima.