

# Mometasone Furoate and Nasal Vascularisation in Allergic Patients

Milodar Kujundžić<sup>1</sup>, Emina Babarović<sup>2</sup>, Marija Petković<sup>3</sup>, Ira Pavlović-Ružić<sup>3</sup>, Miran Čoklo<sup>4</sup> and Gordana Zamolo<sup>2</sup>

<sup>1</sup> University of Rijeka, Rijeka University Hospital Center, Department of Otorhinolaryngology, Head and Neck Surgery, Rijeka, Croatia

<sup>2</sup> University of Rijeka, School of Medicine, Department of Pathology, Rijeka, Croatia

<sup>3</sup> University of Rijeka, Rijeka University Hospital Center, Department of Radiotherapy and Oncology, Rijeka, Croatia

<sup>4</sup> University of Rijeka, School of Medicine, Department of Forensic Medicine, Rijeka, Croatia

## ABSTRACT

Angiogenesis, the growth and proliferation of new blood vessels, is important in a variety of pathophysiological processes. However the role of angiogenesis in allergic rhinitis has not been well studied. Hence, the aim of this study was to compare the vascularisation of the nasal mucous membrane of non-allergic, non-treated allergic and allergic patients treated with mometasone furoate. A small piece of the nasal mucous membrane was taken from the frontal pole of the lower nasal shell from 90 patients. The patients were divided in three groups, each containing 30 patients. First group of patients (GP1) had a negative inhalatory allergen test, patients in second group (GP2) had positive test but were not under treatment and the third group of patients (GP3) had positive results with the same test and were treated with mometasone furoate for 15 days before analysis. Immunohistochemical staining with anti-CD31 and VEGF-C was performed. Vascular phase was determined by using length density. Differences in expression of CD31 and VEGF-C were compared using one-way ANOVA and Tukey HSD post-hoc tests. Significantly lower values of CD31 and VEGF-C expression were observed in GP1 in compare with GP2 and GP3 ( $p < 0.001$ ,  $p = 0.013$ , respectively). In GP3 the microvessel density was significantly lower than in GP2 ( $p < 0.001$ ), but higher than in GP1. Our results demonstrated that 15-day treatment with mometasone furoate results in a significant reduction of the density of vascular parameters in allergic patients.

**Key words:** vascularisation, nasal mucous membrane, allergy, mometasone furoate

## Introduction

Allergy represents an inappropriate response of our immunological system to various factors from our surroundings<sup>1-3</sup>. Allergic rhinitis affects 10–40% of the population<sup>4</sup>. It is provoked by inflammatory reactions mediated through immunoglobulin E after exposure to the allergen. Angiogenesis has an important role in various pathological mechanisms<sup>5-7</sup>. It is supposed that the vascularisation in nasal mucous membrane differs from that in the healthy person. Augmentation of the number of blood vessels, which could be expected in allergic patients, may be one of the factors that significantly affects total augmentation of vasculature surface, with consequently greater number of eosinophiles and other inflammatory cells penetrating into the surrounding tissues<sup>8,9</sup>. The greater the number of blood vessels, the greater permeability and subsequent inflammatory reac-

tion are. The aim of this study is to prove whether the blockage of allergic reaction and, in consequence, the reduction in vascularisation of the nasal mucous membrane would follow topic application of mometasone furoate, the topic corticosteroid with local anti-inflammatory properties.

## Materials and Methods

### Patients

The small piece of the nasal mucous membrane specimens, taken from the frontal pole of the lower nasal shell, analyzed in this study were obtained from a total of 90 patients. After allergy tests to inhalatory allergens including grass, weed, tree pollen, feathers, herbal fibers,

fungi, fabric, animal hair, domestic dust, Dermatophagoides pteronyssimus and bacteria, the patients were divided into three groups, each group included 30 patients. The first group (GP1) consisted of patients without allergies and with negative allergic reaction to all allergens, and it included 15 female and 15 male patients, with age range from 19–58 years (median 35 years). The second group (GP2) consisted of allergic patients with positive allergic reaction to one or more allergens; it included 12 female and 18 male patients, with age range from 20–64 years (median 35 years). The third group consisted of allergic patients treated with mometasone furoate, and it included 14 female and 16 male patients, with age range from 18–65 years (median 33 years). The patients included in this study voluntarily participated and all have signed the informed consent agreement before investigation started. Also, the study has been approved by The Ethics Committee, of the School of Medicine, University of Rijeka, Croatia.

### Immunohistochemistry and vascular density analysis

A small piece of the nasal mucous membrane, measuring 5x5 mm, was excised from the lower nasal shell, formalin fixed and embedded in paraffin. A 4µm thick sections were cut and immunohistochemically examined for the expression of CD31 (1:50, clone JC 70A, DAKO/S, Glostrup, DK) and VEGF-C (1:100, clone F 8/86, DAKO)<sup>10–13</sup>. The vascular phase of the nasal mucous membrane was determined by the stereological method using the length density variable. Length density is a relative stereological variable that gives us the length of a certain curve in a unit of volume. The property of length density has an exponent of  $-2$  ( $\text{cm}^1/\text{cm}^3 = \text{cm}^{-2}$  – our research made use of  $\text{mm}^{-2}$ ). The trace of a one-dimensional curve in a plane is a dimensionless value called a transection point, marked Q. Its density in the test plane is referred to as density transection (QA). The formula used to calculate the length density was  $L_{v,f} = 2 \times Q_t / A_t$ ; where  $Q_t$  stands for the number of transections, and  $A_t$  for the test plane surface, which in our case equals 0.013  $\text{mm}^2$ . Approximately 100 measurements *per* specimen were taken during the study and mean values were calculated for each sample.

### Statistical analysis

Statistical analysis was performed using Statistica 6.1 software (StatSoft, Inc., Tulsa, OK, USA). The distribution of data was tested for normality using Kolmogorov-Smirnov test. The measures of central tendency for continuous data such as CD31 and VEGF-C expression were compared for differences between all three groups by one-way ANOVA and Tukey HSD as a post-hoc test. All statistical values were considered significant at the p level of 0.05 or less.

## Results

Immunohistochemical expression of CD31 and number of microvessels in all groups of patients are summarized in Table 1. Statistical analysis revealed the significant differences of microvessel density between all three groups of patients ( $p < 0.001$ ). Significantly higher CD31 expression (microvessel density) was observed in GP2 group (allergic non-treated patients) in comparison to other two GPs ( $p < 0.001$ ). In GP3 (treated allergic patients) the microvessel density was significantly lower than in non-treated patients ( $p < 0.001$ ), but higher than in GP1 group (control, non-allergic patients).

**TABLE 1**  
THE AVERAGE NUMBER AND DIFFERENCES OF BLOOD VESSELS (CD31 EXPRESSION) IN ALL THREE GROUPS OF PATIENTS

Group	N	Number of blood vessels CD31		Statistics
		$\bar{X} \pm \text{SD}$	95% CI	
Control (GP1)	30	340.9±33.3	(325.4–356.5)	
Allergic non-treated patients (GP2)	30	1198.0±87.2	(1157.4–1238.8)	one-way ANOVA F=1063.94 p<0.001*
Allergic treated patients (GP3)	30	900.3±44.4	(879.5–921.1)	

\*Significant difference between all three groups

Table 2 shows values of VEGF-C expression and lymph vessels density in all three GPs. Histologically there was a significant decrease in the number of lymph vessels in the allergic patients following mometasone therapy (Figure 1). Significantly lower values of VEGF-C expression was observed in GP1 group (non-allergic patients) ( $p < 0.001$ ). Increased levels of VEGF-C expression and lymph vessels was observed in the GP3 (allergic treated patients) when comparing with GP1 ( $p = 0.013$ ).

**TABLE 2**  
THE AVERAGE NUMBER AND DIFFERENCES OF LYMPH VESSELS (VEGF-C EXPRESSION) IN ALL THREE GROUPS OF PATIENTS

Group	N	Number of lymph vessels VEGF-C		Statistics
		$\bar{X} \pm \text{SD}$	95% CI	
Control (GP1)	30	85.9±8.0	(81.9–89.4)	
Allergic non-treated patients (GP2)	30	113.0±15.9	(105.6–120.4)	one-way ANOVA F=27.66 p<0.001*
Allergic treated patients (GP3)	30	96.5±9.7	(91.9–101.1)	

\*Significant difference between all three groups

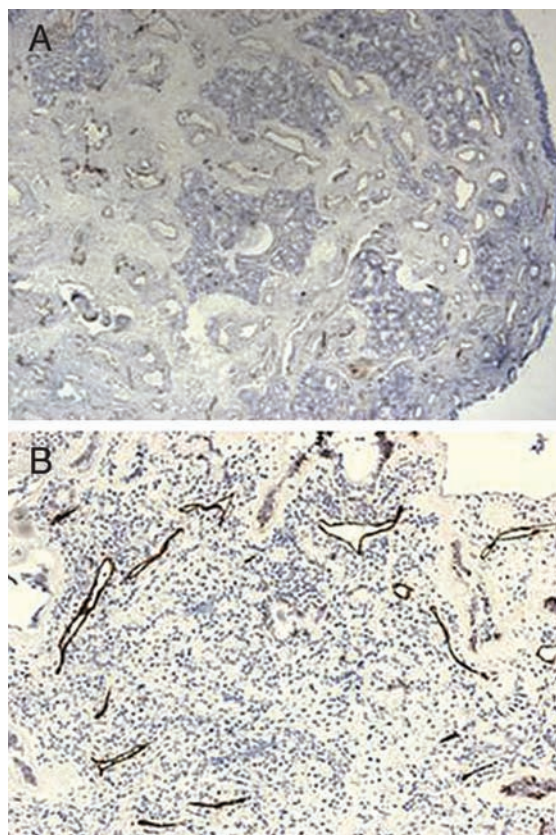


Fig. 1. Immunohistochemical staining for VEGF-C. A) Mucosa of patients with allergy shows oedema and high number of VEGF-C positive lymph capillaries. B) Histologically there was a significant decrease of epithelial oedema and VEGF-C positivity (lymph capillaries) in allergic patients following mometasone therapy. Magnification 100x and 200x, respectively.

## Discussion

By definition allergic rhinitis is the most presented chronic illness of the respiratory tract in the developed

## REFERENCES

- TURČIĆ P, LIPOZENČIĆ J, MILAVEC-PURETIĆ V, MARINOVIĆ KULIŠIĆ S, Coll Antropol, 35 (2011) 83. — 2. MEHULIĆ M, MEHULIĆ K, MALOČA VULJANKO I, KUKULJ S, POPOVIĆ GRLE S, DUGAC VUKIĆ A, BARIŠIĆ B, PLAVEC D, Coll Antropol, 35 (2011) 529. — 3. JUKIĆ T, ABIDOV M, IHAN A, Coll Antropol, 35 (2011) 1219. — 4. MORI S, FUJIEDA S, SUNAGA H, FOX SB, SAITO H, Clin Exp Allergy, 30 (2000) 1637. DOI: 10.1046/j.1365-2222.2000.00903.x. — 5. DOBRILA-DINTINJANA R, VANIS N, DINTINJANA M, RADIĆ M, Coll Antropol, 36 (2012) 1063. — 6. PIGAC B, DMITROVIĆ B, MARIĆ S, MASIĆ S, Coll Antropol, 36 (2012) 227. — 7. JAKOVLJEVIĆ G, CULIĆ S, STEPAN J, KOSUTA I, SEIWERTH S, Coll Antropol, 35 (2011) 1071. — 8. ONRUST S, LAMB HM, Drugs, 56 (1998) 725. DOI: 10.2165/00003495-199856040-00018. — 9. SCHENKEL E, Expert Opin Pharmacother, 4 (2003) 1579. DOI: 10.1517/14656566.4.9.1579. — 10. NICHOLSON SA, MC DERMOTT MB, DE YOUNG BR, SWANSON PE, Appl Immunohistochem Mol Morphol, 8 (2000) 19. — 11. JOUKOV V, PAJUSOLA K, KAIPAINEN A, CHILOV D, LAHTINEN I, KUKK E, SAKSELA O, KALKKINEN N, ALITALO K, EMBO J, 15 (1996) 290. — 12. BERSE B, BROWN LF, VAN DE WATER L, DVORAK HF, SINGER DR, Mol Biol Cell, 3 (1992) 211. — 13. ZAMOLO G, GRUBER F, CABRIJAN L, MICOVIĆ V, ITERNICKA Z, JONJIĆ N, Acta Med Okayama, 55 (2001) 289. — 14. LUNDBACK B, Clin Exp Allergy, 28 (1998) 3. — 15. BOUSQUET J, VAN CAUWENBERGE P, KHALTAEV N, J Allergy Clin Immunol, 108 (2001) 147. DOI: 10.1067/mai.2001.118891. — 16. FRIERI M, THERATTIL J, CHAVARRIA V, COSACHOV J, KUMAR NS, WANG SF, SANSONE G, ETZEL J, DELLEVECCHIA D, ZITT M, MESARINA-WICKI B, NOLOP KB, Ann Allergy Asthma Immunol, 81 (1998) 431. DOI: 10.1016/S1081-1206(10)63141-9. — 17. AUSTIN RJ, MASCHERA B, WALKER A, FAIRBAIRN L, MELDRUM E, FARROW SN, UINGS LJ, Eur Respir J, 20 (2002) 1386. DOI: 10.1183/09031936.02.02472001. — 18. BERKOWITZ RB, BERNSTEIN DI, LAFORCE C, PEDINOFF AJ, ROOKLIN AR, DAMARAJU CR, MESARINA-WICKI B, NOLOP KB, Allergy, 54 (1999) 64. DOI: 10.1034/j.1398-9995.1999.00713.x. — 19. SPECTOR SL, Ann Allergy Asthma Immunol, 75 (1995) 463. — 20. BERLUCCHI M, PEDRUZZI B, Clinical Medicine Insights, 2 (2010) 761.

countries. It is presented by abnormal inflammation of nasal mucous membrane characterised by nasal obstruction, aqueous rhinorrhea, sneezing, nasal itching and postnasal drip<sup>14,15</sup>. It is a prototype of IgE mediated illness that is manifested as a response to seasonal allergens or permanent allergens and has the genetic component<sup>15</sup>. Angiogenesis plays an important role in the pathological mechanisms considering the facts that the vascularisation of the nasal mucosa of the allergic patients differs from the nasal mucosa of healthy individuals. Mometasone furoate is a corticosteroid drug<sup>16</sup>. It presents a powerful anti-inflammatory agent for reducing symptoms of seasonal and permanent allergic rhinitis<sup>8,9,17</sup>. Mometasone furoate has minimal system activity and is very well tolerated by the patients. It affects the nasal glucocorticoid receptors thus inhibits synthesis and/or secretion of inflammatory mediators<sup>16</sup>. Mometasone furoate inhibits leukotrien synthesis diminishing blood vessels permeability<sup>18–20</sup>. In vitro experiments have shown that mometasone furoate induces an inhibition of pro-inflammatory Th2 cytokines<sup>16</sup>.

## Conclusion

The intensity of the allergic reaction is, therefore, proportional to the permeability of the blood vessels. When is Mometasone furoate applied 15 days before the surgical procedure, it inhibits interleukin release and release of other cytokines together with inhibition of the synthesis of leukotriens. The consequence is a reduction of vascular permeability and the reduction of the number of blood vessels in the nasal mucous membrane. Thus, all the results show that along with the permeability of the blood vessels for the intensity of the allergic reaction, the density of the blood vessels is of the same importance. The results presented in this study have confirmed our results from previous pilot study. We have shown that after a 15-day treatment with mometasone furoate nasal mucous membrane of allergic patients shows significant reduction of density of the vascular elements.

G. Zamolo

University of Rijeka, School of Medicine, Department of Pathology, Braće Branchetta 20, 51000 Rijeka, Croatia  
e-mail: gordanazamolo@yahoo.com

## VASKULARIZACIJA SLUZNICE NOSA U ALERGIČNIH BOLESNIKA LIJEČENIH MOMETAZON FUROATOM

### SAŽETAK

Angiogeneza, rast i proliferacija novih krvnih žila, važna je u različitim patofiziološkim procesima. Međutim, uloga angiogeneze u alergijskom rinitisu još nije detaljno proučena. Stoga je cilj ove studije usporediti vaskularizaciju sluznice nosa ne-alergičara, neliječenih alergičara i alergičnih bolesnika liječenih mometazon furoatom. Mali komadić sluznice nosa uzet je s prednjeg dijela donje nosne školjke 90 bolesnika. Pacijenti su podijeljeni u tri skupine, svaka s po 30 bolesnika. Prva skupina bolesnika (GP1) bila je negativna na inhalatorne alergene, bolesnici u drugoj skupini (GP2) bili su pozitivni na inhalatorne alergene, ali nisu liječeni, a treću skupinu pacijenata (GP3) čine pacijenti s pozitivnim testom na inhalatorne alergene koji su tijekom 15 dana prije uzimanja uzorka bili liječeni mometazon furoatom. Provedeno je imunohistokemijsko bojenje anti-CD31 i VEGF-C. Vaskularna faza određena je korištenjem dužinske gustoće. Razlike u ekspresiji CD31 i VEGF-C su komparirane korištenjem one-way ANOVA i Tukey HSD post-hoc testova. Značajno niže vrijednosti CD31 i VEGF-C ekspresije dobivene su u GP1 u usporedbi s GP2 i GP3 ( $p < 0,001$ ,  $p = 0,013$ , slijedom). U skupini GP3 gustoća krvnih žila je značajno niža nego u GP2 ( $p < 0,001$ ), ali viša nego u GP1. Dobiveni rezultati pokazuju da 15-dnevni tretman mometazon furoatom rezultira značajnim smanjenjem gustoće krvnih žila u alergičnih bolesnika.