

VETERINARSKI ARHIV 83 (1), 115-124, 2013

Eyelid neoplasm in a white tiger (*Panthera tigris*) - a case report

Atul Gupta¹, Kajal Jadav², Parag Nigam^{3*}, Devendra Swarup⁴,
and Avadh B. Shrivastava²

¹Van Vihar National Park Bhopal, Madhya Pradesh, India

²Centre for Wildlife Forensic and Health, M.P. Pashu Chikitsa Vigyan Vishwavidyalya, South Civil Lines,
Jabalpur, Madhya Pradesh, India

³Wildlife Institute of India, Chandrabani, Dehra Dun, Uttarakhand, India

⁴Central Institute for Research on Goats, Makhdoom, Farah, Mathura, UP, India

GUPTA, A., K. JADAV, P. NIGAM, D. SWARUP, A. B. SHRIVASTAVA: Eyelid neoplasm in a White Tiger (*Panthera tigris*) - a case report. Vet. arhiv 83, 115-124, 2013.

ABSTRACT

An 18-year-old captive white tiger (*Panthera tigris*) was evaluated for a progressive growth on the lower eyelid that showed ulceration and mucoid to purulent discharge. The growth was surgically excised and histopathological examination revealed a squamous cell carcinoma (SCC). The growth however showed recurrence at 28 days after excision. Further management was done employing 2 stage chemotherapy using cyclophosphamide (50 mg/kg) with different regimens. The blood profile, food intake and general health of the animal showed improvement after first course of chemotherapy though it was not evident after second chemotherapy. The animal survived for three months following second course of chemotherapy. Post mortem findings revealed metastasis in lungs, liver and lymph nodes. The present case is an attempt to document squamous cell carcinoma in a white tiger.

Key words: Bengal tiger, squamous cell carcinoma, eyelid, chemotherapy, metastasis

Introduction

Wide varieties of neoplastic proliferations of a benign or malignant nature have been reported in felids (LOMBARD and WITTE, 1959; MONTALI, 1980; PORT et al., 1981; HUBBARD et al., 1983; HRUBAN et al., 1988; CHAKRAVARTY et al., 1991; MURALEEDHARAN et al., 2010). These have been observed in the integumentary-mammary, endocrine, reproductive, hematopoietic-lymphoreticular, digestive and hepatobiliary systems in

*Corresponding author:

Dr. Parag Nigam, M.V.Sc. (Veterinary Microbiology), Scientist -D, Wildlife Institute of India, Post Box No. 18, Chandrabani, Dehra Dun, Uttarakhand, 248001, India, Phone: +91 135 2640 111 115; Fax: +91 135 2640 117; E-mail: nigamp@wii.gov.in

felines (OWSTON et al., 2008). Tumors of the eyes and adnexal structures are important tumors in cats that are reported to impair the patient's vision, quality of life and survival (MORRIS and DOBSON, 2001). A comprehensive study of the prevalence of feline eyelid tumors, published in 1993 by the Veterinary Medical Data Program and the Purdue Comparative Oncology Program, listed squamous cell carcinomas (SCCs), squamous papillomas, unclassified carcinomas, basal cell carcinomas, fibromas, fibrosarcomas, adenomas, cystadenomas, adenocarcinomas (ACAs), lymphomas, histiocytomas, mast cell tumors (MCTs), hemangiomas, hemangiosarcomas (HSAs), melanomas, neurofibromas and trichoepitheliomas (McLAUGHLIN et al., 1993).

Cutaneous malignant epithelial tumors are reported as the most common neoplasm in felids (MORRIS and DOBSON, 2001; JOHNSON, 1998) of which SCCs are predominant tumors that result from neoplastic proliferation of squamous stratified epithelium (PAUL et al., 2002; MORRIS and DOBSON, 2001). SCCs of the eyelid is a common domestic feline adnexal tumor that is a malignant, locally invasive tumor originating in the epidermis (MARLAR, 2002; BOSE et al., 2002; SABAPARA, 2003; CALIGIURI et al., 1988) and mostly affects white and older cats. These are characterized by a papillary or a cauliflower appearance having broad base and are usually seen in white cats with nonpigmented eyelids. Development of SCCs has been attributed to insult to the keratinocyte that may result from repeated exposure to UV radiation in susceptible animals (PEIFFER, 1981). Solar radiation may predispose the skin to SCC by damaging it, thus resulting in a preinvasive actinic precursor lesion, capable of malignant transformation (PEIFFER, 1981; MORRIS and DOBSON, 2001).

The report describes a case of a squamous cell carcinoma of the eyelid in an aged white tigress (*Panthera tigris*) and its surgical and post surgical management.

Case report

An 18-year-old captive bred white tigress (*Panthera tigris*), housed at Van Vihar National Park, Bhopal, Madhya Pradesh, developed a proliferative growth on the right lower eyelid (Fig. 1) that was observed to be growing and showed ulcerations, with mucoid to purulent discharge. The conjunctivae showed reddening and animal exhibited frequent pawing, increased blinking and increased lacrimal flow.

The animal was restrained in a squeeze cage for closer examination. Examination of the growth on the eyelid was not possible due to the non-cooperation of the tigress and it was decided to immobilize the animal. Blood was collected from the caudal vein for complete blood count and serum chemistry profile. The significant preoperative clinical laboratory findings included decreased haemoglobin concentration (Hb) (10.3 gm/dL), low packed cell volume (PCV) (32%), marked leucocytosis ($39000 \times 10^3/\text{mL}$), lymphocytopenia (6%), elevated bilirubin (0.86 mg%) and elevated serum enzymes,

namely: Aspartate amino transferase (AST) (62 IU/L), Alanine amino transferase (ALT) (129 IU/L) and Alkaline phosphatase (ALP) (178 IU/L).

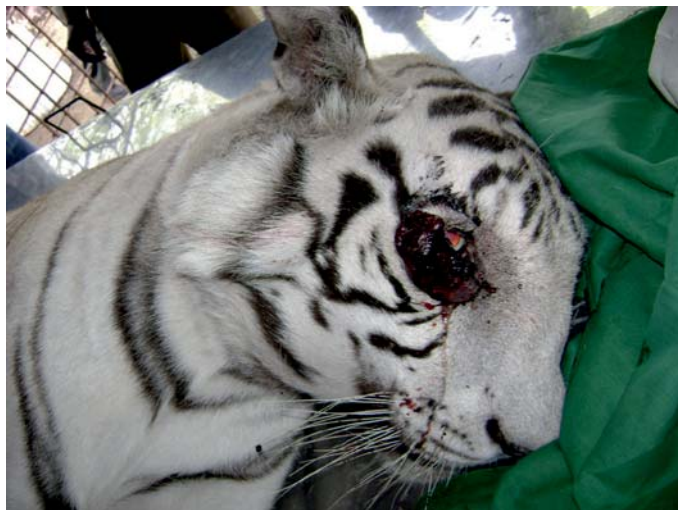

Fig. 1. Clinical rapid cancerous growth on the lower right eyelid

The animal (estimated to weight 150 kg) was fasted for 24 hours and immobilized with a combination of xylazine (Xylazil-100, Troy laboratories, Australia; 150 mg i.m., 1 mg/kg) and ketamine (Ketamil, Troy laboratories, Australia; 300 mg i.m., 2 mg/kg). The drug combination provided light anesthesia with excellent analgesia for the required procedures. Atropine sulphate (Martin and Brown pharmaceuticals, Hissar, India; 0.6 mg, 0.004 mg/kg body weight) was given as a pre-anesthetic.

The left eye, the adnexal structures, anterior segment, the lens were found to be normal, however, the right eye, lower eyelid, third eyelid and conjunctiva showed thickening with the latter being hyperemic. On physical examination, a firm growth was observed (approximately 6.5 × 3.5 × 2.3 cm) involving the lower eyelid extending all along the margin. The growth showed ulcerations with mucoid to purulent discharge.

Following surgical preparation and local infiltration with Lignocaine hydrochloride (Xylocaine 2%, Astra Zeneca Pharma India Ltd., Bangalore, India), the mass was excised from the lower margin (palpebral border) of the eyelid. Bleeding was controlled by ligation of blood vessels and swabbing with adrenaline. The open wound was plugged with cotton-gauze and providone-iodine lotion (Betadine lotion; Win-Medicare Pvt Ltd., New Delhi 19). The animal was administered cefotaxim sodium (Taxim; Alkem Laboratories Ltd., Mumbai; 2 gm), meloxicam (Melonex, Intas Pharmaceuticals Ltd.;

75 mg. i.m., 0.5 mg/kg) and pheniramine maleate (Avil, Aventis pharma Ltd., 100 mg) intramuscularly. The animal was revived from sedation using yohimbine hydrochloride (Reverzine, Parnell Laboratories (Aust) Pty. Ltd.; 20 mg) given intramuscularly. Post operative recovery was uneventful. The excised mass of tissue was fixed in 10% phosphate buffered formalin, routinely processed and stained with hematoxylin and eosin (H&E) for light microscopic examination. The histopathological sections of the tumor tissue revealed malignancy and consisted of various sizes of islands and fronds of squamous cell with acidophilic cytoplasm, pleomorphic and vesicular nuclei with prominent nucleoli, raised nuclear cytoplasmic ratio and the presence of numerous mitotic figures (Figs 2 and 3). The tissue section showed focal areas of inflammatory cells having degenerated neutrophils. Poorly differentiated lesions consisted of polyhedral cells with large nuclei and very little cytoplasm. The cells were hyper chromic. The malignant cells did not form acini, but were arranged in an elongated column. Connective tissue stroma was scarce. The tumor was diagnosed as a squamous cell carcinoma. Based on the microscopic appearance of the neoplastic cells, these were graded as G 3 (poorly differentiated, high grade) (GREENE et al., 2002).

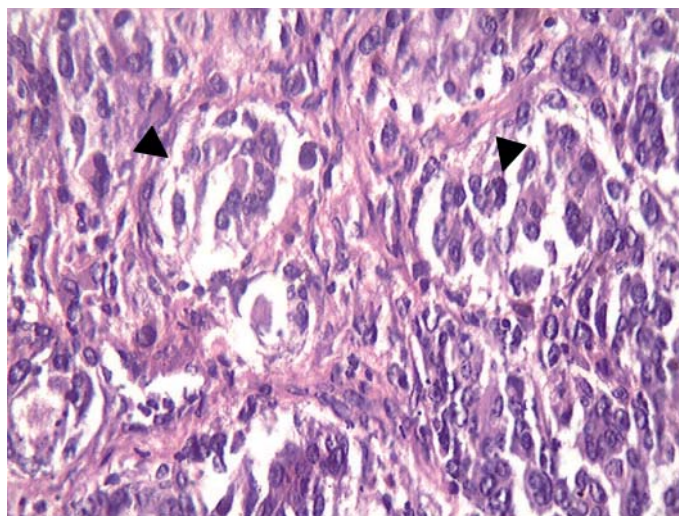


Fig. 2. Histopathological image showing various sizes of islands and fronds of squamous cell with acidophilic cytoplasm. H&E $\times 400$.

A. Gupta et al.: Eyelid neoplasm in a white tiger (*Panthera tigris*)

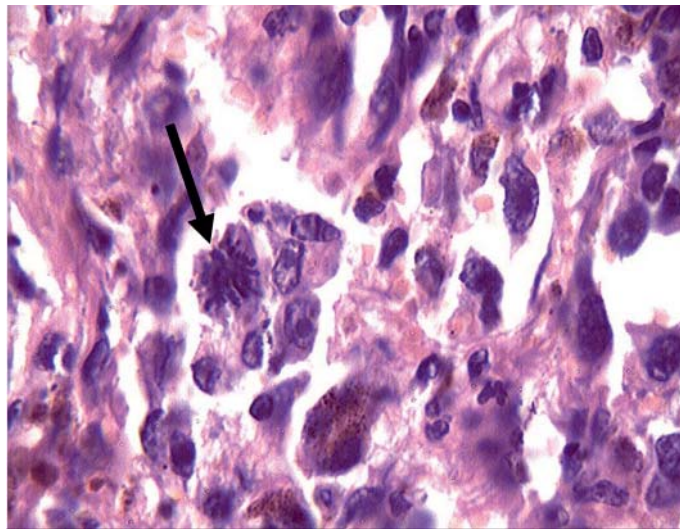


Fig. 3. Histopathological image showing degeneration with mitotic figures and acidophilic cytoplasm in the cells. H&E $\times 400$.

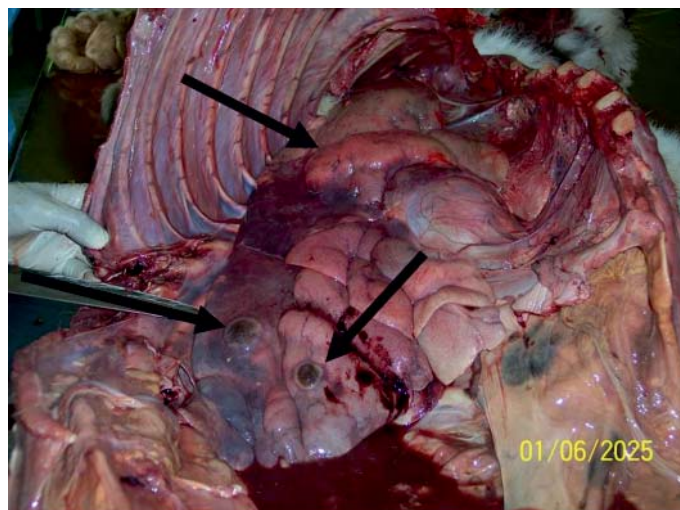


Fig. 4. Multiple metastatic tumors in the lung parenchyma

Post operative medication for wound healing (Cefotaxim sodium 2.0 gm Bid, Vitamin B complex and liver extract) was administered for ten days, following which complete healing of the surgical wound was noticed. The growth however reoccurred after 28 days and it necessitated chemotherapy. The tigress was subjected to chemotherapy in two phases along with necessary supportive therapy. The animal was kept under close observation throughout the chemotherapy. The initial course of chemotherapy included oral medication with cyclophosphamide (Endoxan, German Remedies Ltd; 50 mg/kg given thrice weekly for 4 week) and prednisolone (Omnacortil 40, Macleods Pharmaceuticals Ltd, India; 10 mg/kg daily for one week) along with parenteral Mesna (Mesna, Cipla Ltd, India, 200 mg intravenously weekly for 4 week) to prevent toxicity to the urinary passage caused by cyclophosphamide. The therapy was discontinued for 3 weeks, following which the second course was initiated. The second course included oral medication with cyclophosphamide (at similar doses once weekly for 2 weeks) and Prednisolone (2 mg/kg daily for one week) along with parenteral Vincristine sulphate (Cytocristin, Cipla Ltd., India; 0.5mg/kg intravenously once weekly for 3 weeks on days 0, 7 and 14). Blood was collected after 7 days from each chemotherapy course.

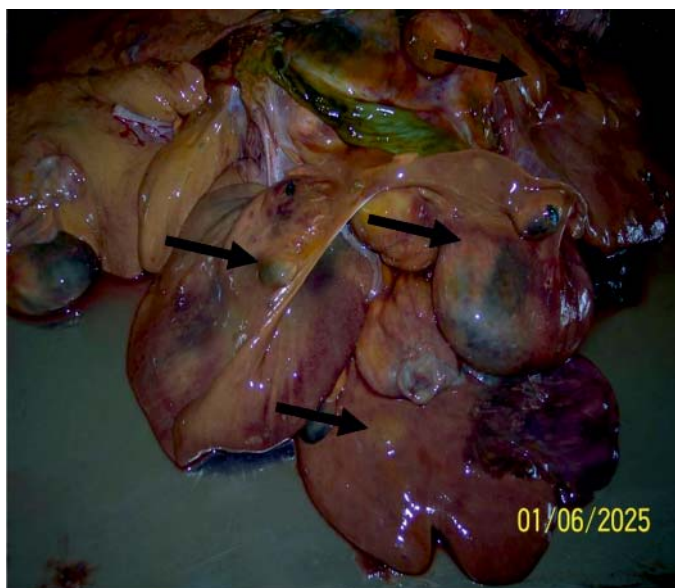

Fig. 5. Multiple tumors in the liver parenchyma

Certain blood parameters showed slight improvement [Hb concentration (11 gm/dL), mild decrease in total leucocyte count (as compared to previous count) ($27100 \times 10^3/$

mL), improved percent lymphocytes (22%), slight increase in PCV (38.4%)] however the serum enzymes did not show any significant change [AST (67.6 IU/L), ALT (128.5 IU/L) and ALP (162 IU/L)] after the first course of chemotherapy. The blood profile after the second therapy revealed anaemia (Hb 7.2 mg/dl), low total erythrocyte count ($4.35 \times 10^6/\text{mL}$), low PCV (24.8%), leucocytosis ($32400 \times 10^3/\text{mL}$), lymphocytopenia (16%), elevated total bilirubin (2.9 mg%) and elevated AST (151.5 IU/L), ALT (269.6 IU/L) and ALP (80.5 IU/L).

Average feed consumption increased immediately after the first phase of chemotherapy, however it decreased after the second phase of chemotherapy. The tigress survived for three months following the second phase of chemotherapy. Postmortem examination revealed neoplastic nodules of varying sizes (0.5 cm to 4.0 cm) in the lungs, liver, pancreas and spleen. The submaxillary and prescapular lymphnodes were grossly enlarged and contained blood mixed with pus (Fig. 4 and 5). The gross lesions were suggestive of metastasis of the neoplasia, resulting in failure in function of the affected visceral organs.

Discussion

A recent 10 year retrospective study (June 1999 to June 2008) of eyelid tumors in cats conducted at the University of Tennessee revealed SCCs, MCTs, HSAs, ACAs, peripheral nerve sheath tumors, lymphomas, apocrine hidrocystomas and hemangiomas (NEWKIRK and ROHRBACH, 2009). SCCs were the most common carcinoma that accounted for 28% of the tumors. Though SCCs are common neoplasm in domestic cats (MORRIS and DOBSON, 2001), information on their incidence in wild felids is limited.

The present case documents the development of a SCC of the eyelid in a captive white tigress. Though etiological factors could not be singled out for its development, the location of the Tropic of Cancer ($23^{\circ}26'22''$) near Bhopal, India, where the sun shines directly overhead at midday during the summer and the display history of the tigress in the zoo could have played a key role in developing SCC.

Squamous cell carcinomas in domestic and exotic cats are treated with similar surgical techniques (CALIGIURI et al., 1988). After surgical excision, further treatment may consist of photodynamic therapy, radiation therapy or chemotherapy (THEILEN and MADEWELL, 1979; MELEO, 1997; MAULDIN et al., 1988; STELL, 2001; MORRIS and DOBSON, 2001; MORRISON, 2002). The neoplastic growth in the present case was excised surgically as practiced by PAUL et al. (2002), however it showed recurrence after 28 days. Similar findings of local recurrence have been reported by HEAD (1990) and may be attributed to inadequate resection. Chemotherapy was attempted as a treatment, as other therapies were not feasible in the given conditions due to the non-availability of resources and the

non-co-operation of the animal. Though the blood profile, food intake and general health of the animal showed improvement after the first course of chemotherapy, it was not evident after the second chemotherapy. The animal survived for three months following the second course of chemotherapy, compared to the average survival time of 7.4 months for domestic cats with SSC as reported by NEWKIRK and ROHRBACH (2009), which indicates the aggressiveness of the neoplasm.

Although only the eyelid was grossly involved, it was not determined whether this was a primary SCC of the eyelid or just an extension from the surrounding tissue based on histological examination. Therefore, the true origin of the neoplasia was undetermined. The post mortem findings revealed metastatic lesions in the visceral organs. Similar findings of metastasis have been reported by other authors (DHALIWAL and KUFUOR-MENSAH, 2007; KENNEDY and STRAFUSS, 1976; PORT et al., 1981; SABAPARA et al., 2003) in domestic cats.

The SCC in this case report involved the eyelid and showed invasiveness. It is empirical to note that white tigers housed in different zoos of similar geographical location need special care to prevent excessive exposure to the ultra violet component of the sun's rays, as they are a potential carcinogen (BRASH et al., 1991).

The present case is an attempt to document SCC in a white tiger.

Acknowledgements

The authors would like to thank the Director, Van Vihar National Park, Bhopal, Madhya Pradesh for providing support and encouragement during the entire study. Special thanks are due to two anonymous reviewers for their constructive comments and helpful suggestions for improvement of the manuscript.

References

- BOSE, V. S. C., I. NATH, J. MOHANTY, S. K. PANDA, A. T. RAO (2002): Epidermoid carcinoma of the eyelid in a tiger (*Panthera tigris*). *Zoos' Print*. 17, 965-966.
- BRASH, D. E., J. A. RUDOLPH, J. A. SIMON, A. LIN, G. J. MCKENNA, H. P. BADEN, A. J. HALPERIN, J. PONTER (1991): A role for sunlight in the skin cancer: UV induced p53 mutations in squamous cell carcinoma. *Proc. Natl. Acad. Sci.* 80, 10124-10128.
- CALIGIURI, R., M. CARRIER, E. R. JACOBSON, C. D. BUERGELT (1988): Corneal squamous cell carcinoma in a cheetah (*Acinonyx jubatus*). *J. Zoo Anim. Med.* 19, 219-222.
- CHAKRAVARTY, P., P. RAJASUBRAMANIAM, P. SALVI (1991): A case of fibrosarcoma in a panther (*P. pardus*). *Zoos' Print*. 6, 14.
- DHALIWAL, R. S., E. KUFUOR-MENSAH (2007): Metastatic squamous cell carcinoma in a cat. *J. Feline Med. Surg.* 9, 61-66.

- GREENE, F. L., D. L. PAGE, I. D. FLEMING, A. G. FRITZ, C. M. BALCH, D. G. HALLER, M. MORROW, Eds. (2002): AJCC Cancer Staging Manual, 6th ed. New York: Springer-Verlag. pp. 435.
- HEAD, K. W. (1990): Tumors of the alimentary tract. In: Tumors in Domestic Animal (Moulton. J. E., Ed.), 3rd ed. University of California Press, Berkeley, California, pp. 347-435.
- HRUBAN, Z., W. E. CARTER, T. MEEHAN, P. WOLFF, W. A. FRANKLIN, S. GLAGOV (1988): Complex mammary carcinoma in a tiger (*Panthera tigris*). *J. Zoo Anim. Med.* 19, 226-230.
- HUBBARD, G. B., R. E. SCHMIDT, K. C. FLETCHER (1983): Neoplasia in zoo animals. *J. Zoo Anim. Med.* 14, 33-40.
- JOHNSON, P. J. (1998): Dermatologic tumors (excluding sarcoids). *Vet. Clin. North Am. Equine Pract.* 14, 625-658.
- KENNEDY, G. A., A. C. STRAFUSS (1976): Multiple neoplasms in an aged cougar. *J. Zoo Anim. Med.* 7, 24-26.
- LOMBARD, L. S., E. J. WITTE (1959): Frequency and types of tumors in mammals and birds of Philadelphia Zoological Gardens. *Cancer Res.* 19, 127-141.
- MARLAR, A. B. (2002): Eyelid neoplasms. In: Small Animal Ophthalmology Secrets (Riis, R.C., Ed.). Publisher-Hanley and Belfus, Philadelphia. pp. 169-175.
- MAULDIN, G. N., R. E. MATUS, A. K. PATNAIK, B. R. BOND, S. C. MOONEY (1988): Efficacy and toxicity of doxorubicin and cyclophosphamide used in the treatment of selected malignant tumors in 23 cats. *J. Vet. Intern. Med.* 2, 60-65.
- McLAUGHLIN, S. A., R. D. WHITLEY, B. C. GILGER, J. C. WRIGHT, D. M. LINDLEY (1993): Eyelid neoplasms in cats: a review of demographic data (1979-1989). *J. Am. Anim. Hosp. Assoc.* 29, 63-67.
- MELEO, K. A. (1997): The role of radiotherapy in the treatment of lymphoma and thymoma. *Vet. Clin. North Am.* 27, 115.
- MONTALI, R. J. (1980): An overview of tumors in zoo animals. In: The Comparative Pathology of Zoo Animals. (Montali, R. J., and G. Migaki, Eds.). Smithsonian Institution Press, Washington, D.C. pp. 531-542.
- MORRIS, J., J. DOBSON (2001): Small animal Oncology. Iowa State University Press. A Blackwell Science Company, Iowa. pp 50-68.
- MORRISON, W. B. (2002): Cancer drug pharmacology and clinical experience. In: Cancer in Dogs and Cats: Medical and Surgical Management (Morrison, W. B. Ed.). 2nd ed. Teton New Media, Jackson, WY.
- MURALEEDHARAN, K., S. J. SESHADRI, R. N. S. GOWDA, P. APPAJI (2010): Cancer of eye in a jaguar (*Panthera onca*). *Zoos' Print* (web version). 25, p. 33.
- NEWKIRK, K. M., B. W. ROHRBACH (2009): A retrospective study of eyelid tumors from 43 cats. *Vet. Pathol.* 46, 916-927.
- OWSTON, M. A., E. C. RAMSAY, D. S. ROTSTEIN (2008): Neoplasia in felids at the Knoville Zoological Gardens 1979-2003. *J. Zoo Wildl. Med.* 39, 608-613.

- PAUL, J. C., G. L. GHOSH, A. BISWAS, S. K. NANDI, B. K. BISWAS (2002): Surgical management of squamous cell carcinoma of tail in a jaguar. *Indian J. Anim. Hlth.* 41, 141-144.
- PEIFFER, R. L. (1981): Feline ophthalmology. In: *Textbook of Veterinary Ophthalmology* (Gelatt, K. N., Ed.). Lea & Febiger, Philadelphia. pp. 563-564.
- PORT, C. D., E. R. MASCHGAN, J. POND, D. G. SCARILY (1981): Multiple neoplasia in a jaguar. *J. Comp. Pathol.* 91, 115-122.
- SABAPARA, R. H., R. G. JANI, P. R. PATEL (2003): Squamous cell carcinoma of lungs in an Indian leopard (*Panthera pardus*). *Zoos' Print.* 18, p. 1056.
- STELL, A. J., J. M. DOBSON, K. LANGMACK (2001): Photodynamic therapy of the feline superficial squamous cell carcinoma using topical 5-aminolaevulinic acid. *J. Small Anim. Pract.* 42, 164-169.
- THEILEN, G. H., B. R. MADEWELL (1979): *Veterinary Cancer Medicine*. Lea&Febiger, Philadelphia. pp. 129-140.

Received: 8 August 2011

Accepted: 5 December 2012

GUPTA, A., K. JADAV, P. NIGAM, D. SWARUP, A. B. SHRIVASTAVA: Novotvorina na vjedi bijelog tigra (*Panthera tigris*) - prikaz slučaja. *Vet. arhiv* 83, 115-124, 2013.

SAŽETAK

Bijeli tigar (*Panthera tigris*) držan u zatočeništvu, u dobi od 18 godina, pretražen je zbog progresivne izrasline na lijevoj vjedi na kojoj je ujedno zapažena ulceracija i sluzavi do gnojni iscjedak. Izraslina je bila kirurški uklonjena, a patohistološkom pretragom dijagnosticiran je karcinom skvamoznih stanica. Izraslina je recidivirala 28 dana nakon odstranjivanja. Daljnje liječenje sastojalo se od dvije kure kemoterapije ciklofosamidom (50 mg/kg) s različitim protokolom. Krvna slika, uzimanje hrane i opće zdravstveno stanje životinje poboljšalo se nakon prvog postupka kemoterapije. Poboljšanje nije bilo primijećeno nakon druge kure kemoterapije. Životinja je živjela još tri mjeseca nakon druge kure kemoterapije. Post mortem su bile dokazane metastaze u plućima, jetri i limfnim čvorovima.

Ključne riječi: bengalski tigar, karcinom skvamoznih stanica, vjeđa, kemoterapija, metastaze
