

# Juvenile Angiofibroma of the Maxillary Sinus

Goran Malvić<sup>1</sup>, Dubravko Manestar<sup>1</sup>, Mira Krstulja<sup>2</sup>, Davor Čorak<sup>3</sup>, Barbara Čandrlić<sup>4</sup>,  
Milodar Kujundžić<sup>1</sup>, Marko Velepić<sup>1</sup> and Radan Starčević<sup>1</sup>

<sup>1</sup> University of Rijeka, Rijeka University Hospital Center, Clinic of Otorhinolaryngology, Head and Neck Surgery, Rijeka, Croatia

<sup>2</sup> University of Rijeka, Rijeka University Hospital Center, Department of Pathology, Rijeka, Croatia

<sup>3</sup> University of Rijeka, Rijeka University Hospital Center, Department of Epidemiology, Rijeka, Croatia

<sup>4</sup> University of Rijeka, Rijeka University Hospital Center, Clinic of Radiology, Rijeka, Croatia

## ABSTRACT

*Juvenile angiofibromas are benign fibro-vascular tumours of the nasopharynx that develop in prepubertal and adolescent males. Typical symptoms are longstanding unilateral nasal obstruction occasionally followed by epistaxes and frequent severe intraoperative haemorrhage of the discovered mass. We report the case of a 14-year-old boy histologically diagnosed with a juvenile angiofibroma in spite of the atypical localisation of the polyploid mass of the left maxillary sinus.*

**Key words:** excessive bleeding, diagnostic, juvenile angiofibroma, maxillary sinus

## Introduction

Juvenile angiofibromas are benign fibro-vascular tumours that typically occur in prepubertal and adolescent males and account for 0.05 to 0.5 percent of all benign tumours of the head and neck<sup>1,2</sup>. The most common site of origin of the tumour is sphenopalatine foramen<sup>3</sup> and due to its vicinity to nasopharynx they are also called nasopharyngeal angiofibromas. Benign but biologically aggressive, juvenile nasopharyngeal angiofibromas are locally very invasive with consequently life threatening complications secondary to intracranial extension and strong tendency to bleed<sup>4,5</sup>. Although rarely, cases of these tumours occurring on atypical locations like nasal cavities and paranasal sinuses even in patients who did not match the classic gender or age profile (report of the tumours in small children, older people and also pregnant women<sup>6,7</sup>) have been described in literature. Longstanding unilateral nasal obstruction occasionally followed by epistaxes<sup>8,9</sup> and frequent excessive intraoperative haemorrhage of the discovered mass are common in almost all cases<sup>1,10–12</sup>. We report the case of the histologically diagnosed juvenile angiofibroma, in spite of the atypical localisation of the polypoid mass of the paranasal cavity.

## Case Report

In May 2011 a 14-year-old boy diagnosed with polyp of the left maxillary sinus and allergic rhinitis was admit-

ted to our Clinic. The medical history allegedly involved difficult breathing through the nose, especially through the left nostril and occasional hypersecretion over the year, which deteriorated despite medicamentous anti-allergy therapy. He denied nose bleeding and hearing problems. An endoscopic examination detected a type 5 septal deviation to the left, according to Mladina, hypertrophic inferior and middle nasal conchae respectively and a polypoid mass in the left nasal cavum. The mass was of a pale pink colour arising from the left ostiomeatal complex obstructing the left nasal cavum and the left part of the epipharynx. CT confirmed the endoscopic findings (Figure 1).

Functional endoscopic sinus surgery (FESS) and RFITT of the middle and inferior nasal conchae was performed on the patient. Despite hypotensive anaesthesia (RR90/55) excessive bleeding occurred after meatotomy media and initial excision of the mass from the sinus that did not stop after repeated application of vasoconstrictors patches. In order to continue the surgery on maxillary sinus lower antrostomy was done and aspirator was inserted. The bleeding completely stopped after the curettage. Extracted material was sent for pathohistological analysis (Figure 2a and 2b). Antibiotic tampons were placed and removed the following day. The patient felt subjectively well, had no bleeding and was released home. During the follow-up period after 7 days, one

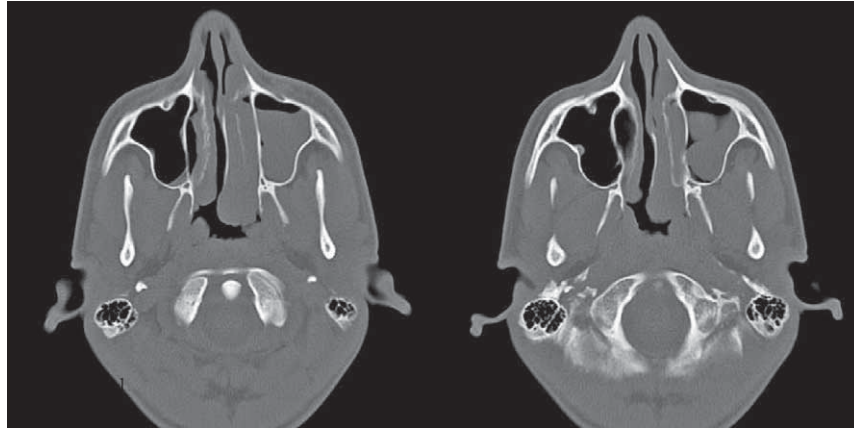


Fig. 1. Native CT, axial slices, bone window. Soft tissue polypoid mass filling the left maxillary sinus and middle nasal meatus, following and spherically bulging into nasopharynx. The origin of the mass is a lateral side of the maxillary sinus.

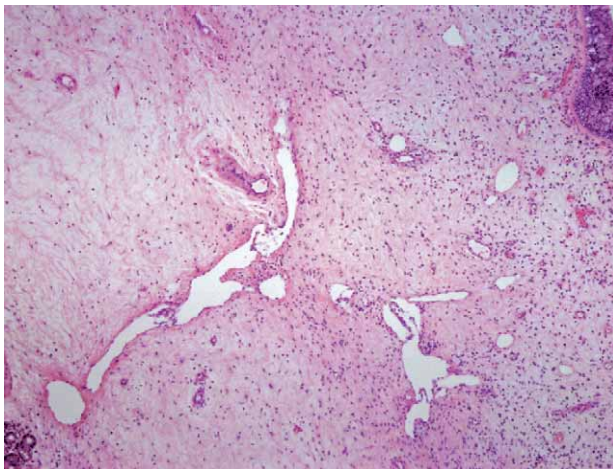

Fig 2a. The polypoid inflamed mucosa overlying the neoplastic tissue, with peculiar large vessels giving the impression of highly vascularized nasal polyp.

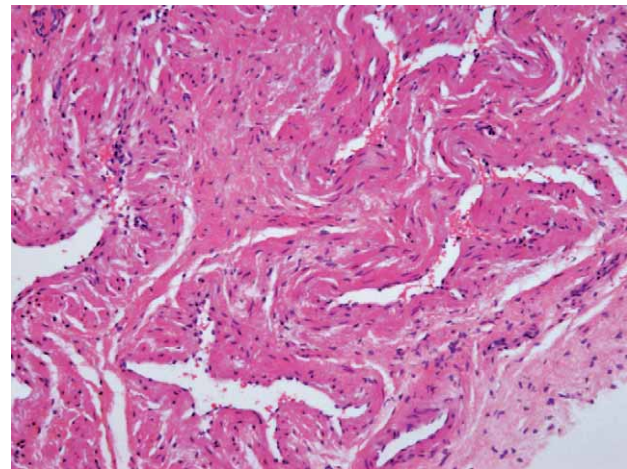


Fig 2b. A highly vascularized tissue composed of fibroblastic/myofibroblastic stroma containing large vessels, different from haemangiopericytoma, pyogenic granuloma, angioma or congenital myofibroma vessels and typical of nasopharyngeal angiofibroma by the plump endothelial cells gradually intermingling with pericytes and fibroblasts.

month and three months there were no signs of recurrence (normal postoperative findings).

## Discussion

Hippocrates is considered to be the first who described the juvenile angiofibroma in the 5<sup>th</sup> century BC, however Freidberg first used the official term in 1940. Today juvenile angiofibroma is one of the most commonly diagnosed tumours of nasopharynx which primarily affects adolescent males<sup>9,13</sup>. Median age at clinical diagnosis is 15 years. Juvenile angiofibromas are non-encapsulated neoplasms composed of rich vascular network set in a fibrous stroma<sup>14</sup>, which in spite its benign histological structure exhibit locally very invasive behaviour and sometimes result in life-threatening complications. The most common site of origin of the tumour is sphenopalatine foramen<sup>3</sup>, however extranasopharyngeal primary sites have been sporadically reported. So far, several

cases of extranasopharyngeal primary sites of juvenile angiofibromas, most often maxillary sinus, ethmoidal sinus, sphenoidal sinus, larynx and pterygomaxillary fissure<sup>15</sup>, have been described in literature. They are usually manifested in clinical features of unilateral nasal obstruction and hypersecretion while other clinical presentations depend on location and tumour extension. The diagnosis is made on the basis of anamnesis and endoscopic examination along with radiology methods, CT and MR, while biopsy is often contraindicated due to a risk of bleeding.

Irradiation, chemotherapy and hormone therapy are some methods for the treatment but surgery is still the method of choice for the treatment of juvenile angiofibroma, however preoperative angiography and embolisation is recommended due to a risk of excessive bleeding.

## Conclusion

Extranasopharyngeal angiofibromas do not frequently conform to classic clinical features typical for nasopharyngeal juvenile tumours. Anamnesis and endoscopic examination along with radiology methods are of key importance in differential diagnosis, since biopsy is often contraindicated. Our case shows that taking in consideration great variations of clinical features in extranasopharyngeal angiofibromas<sup>9</sup> and in spite of endoscopic

findings of polyp, we have histologically confirmed diagnosis of juvenile angiofibroma. Knowing that due to its locally aggressive behaviour each juvenile angiofibroma is a potential life-threatening neoplasm, and due to a risk of excessive bleeding it frequently demands special pre-operative preparations, we believe that today juvenile extranasopharyngeal angiofibroma should be included in the differential diagnostic procedure of all polypoid masses of nasal and paranasal cavities.

## REFERENCES

1. ELOY PH, WATELET JB, HATERT AT, DE WISPELAERE J, B BERTRAND, *Rhinology*, 45 (2007) 24. — 2. GARÇA MF, YUCA SA, YUCA K, *Eur J Gen Med*, 7 (2010) 419. — 3. HARRISON DFN, *Arch Otolaryngol Head Neck Surg*, 113 (1987) 936. DOI: 10.1001/archotol.1987.01860090034015 — 4. RADKOWSKI D, MCGILL T, HEALY GB, OHLMS L, JONES DT, *Arch Otolaryngol Head Neck Surg*, 122 (1996) 122. DOI: 10.1001/archotol.1996.01890140012004 — 5. WALDMAN SR, LEVINE HL, ASTOR F, WOOD BG, WEINSTEIN M, TUCKER HM, *Arch Otolaryngol*, 107 (1981) 677. DOI: 10.1001/archotol.1981.00790470025007 — 6. WITT TR, SHAH JP, STERNBERG SS, *Am J Surg*, 146 (1983) 521. DOI: 10.1016/0002-9610(83)90245-3 — 7. HERMAN P, LOT G, CHAPOT R, *Laryngoscope*, 109 (1999) 140. DOI: 10.1097/00005537-199901000-00027 —
8. PANESAR J, VADGAMA B, ROGERS P, RAMSAY AD, HARTLEY BJ, *Rhinology*, 42 (2004) 171. — 9. WINDFUHR JP, REMMERT S, *Acta Otolaryngologica*, 124 (2004) 880. DOI: 10.1080/00016480310015948 — 10. TANG IP, SHASHINDER S, GOPALA KRISHNAN G, NARAYANAN P, *Singapore Med J*, 50 (2009) 261. — 11. PARK CK, KIM DG, PAK SH, CHUNG HT, JUNG HW, *J Korean Med Sci*, 21 (2006) 773. DOI: 10.3346/jkms.2006.21.4.773 — 12. GOHAR MS, RASHID D, AHMED B, *Pak J Med Sci*, 20 (2004) 377. — 13. HUANG RY, DAMROSE EJ, BLACKWELL KE, *Int J Pediatr Otorhinolaryngol*, 54 (2000) 59. DOI: 10.1016/S0165-5876(00)00404-3 — 14. ALVI A, MYSSIOREK D, FUCHS A, *J Otolaryngol*, 25 (1996) 346. — 15. PRYOR SG, MOORE EJ, KASPERBAUER JL, *Laryngoscope*, 115 (2005)1201

G. Malvić

*University of Rijeka, Rijeka University Hospital Center, Department of Otorhinolaryngology, Head and Neck Surgery, Krešimirova 42, 51000 Rijeka, Croatia*  
e-mail: goran.malvic@gmail.com

## JUVENILNI ANGIOFIBROM MAKSILARNOG SINUSA

### SAŽETAK

Juvenilni angiofibromi su benigni vaskularni tumori nazofarinksa koji se javljaju u predpubertetnih i adolescentnih dječaka. Karakteristični simptomi su dugotrajna unilateralna nazalna opstrukcija ponekad praćena epistaksama te da nađena tvorba prilikom kirurške obrade često obilato krvari. U našem primjeru donosimo slučaj 14 godišnjeg dječaka kod kojega je histološkom analizom postavljena dijagnoza juvenilnog angiofibroma, unatoč netipičnoj lokalizaciji polipozne tvorbe lijevog maksilarnog sinusa.