

PAX8-PPAR γ Oncogene in Follicular Thyroid Tumors: RT-PCR and Immunohistochemical Analyses

Biljana Pauzar^{1,4}, Ivan Karner^{2,4}, Ljubica Glavaš-Obrovac^{2,4}, Mario Štefanić^{2,4} and Branko Dmitrović^{3,4}

¹ »J. J. Strossmayer« University, Osijek University Hospital Center, Department of Clinical Cytology, Osijek, Croatia

² »J. J. Strossmayer« University, Osijek University Hospital Center, Clinical Institute of Nuclear Medicine and Radiation Protection, Osijek, Croatia

³ »J. J. Strossmayer« University, Osijek University Hospital Center, Department of Pathology and Forensic Medicine, Osijek, Croatia

⁴ University of Osijek, School of Medicine, Osijek, Croatia

ABSTRACT

US-guided fine needle aspiration cytology is currently the best diagnostic tool for thyroid nodules. However, it is not sensitive and specific enough for differentiating between benign and malignant follicular tumors. A potentially useful marker for this differentiation is the PAX8-PPAR γ rearrangement, identified in follicular thyroid carcinomas, but not in follicular adenomas or other types of thyroid tumors. The aim of this research was to determine the clinical significance of the PAX8-PPAR γ oncogene in diagnostics follicular thyroid tumors. The study included 62 patients with follicular or Hürthle cell tumors. Gene expression was determined by reverse transcription-polymerase chain reaction (RT-PCR) from paraffin embedded tissues, and PCR products were checked using the agarose gel electrophoresis. The immunohistochemical analysis was performed on archive paraffin embedded tissues with the monoclonal PPAR γ antibody. The statistical analysis has indicated that neither the expression of PAX8-PPAR γ mRNA, nor the immunohistochemical analysis with the PPAR γ antibody correlate with the patohystological diagnosis. The oncogene PAX8-PPAR γ has not met the expectations as a reliable tumor marker for differentiation between benign and malignant thyroid tumors, which makes the only reliable histological criteria – capsular and vascular invasion.

Key words: follicular thyroid tumors, PAX8-PPAR γ rearrangement, RT-PCR, immunohistochemistry

Introduction

According to the 2004 World Health Organization classification of thyroid tumors, they occur as carcinoma, adenomas and related tumors, and other thyroid tumors¹.

Whereas for most thyroid tumors there are clear cytological criteria, the boundaries between adenomatoid nodule, a follicular adenoma and well differentiated follicular carcinoma are not cytologically well defined. It is therefore necessary to find clinically reliable tumor markers which would make this differentiation possible and thus reduce the number of unnecessarily surgeries^{2–5}.

The most common mutations of follicular carcinomas include RAS mutations and PAX8-PPAR γ rearrangement, chromosomal translocation between the thyroid transcription factor PAX8 and the nuclear receptor perox-

isome proliferator-activated receptor γ (PPAR γ). PAX8-PPAR γ was, et first, thought to be restricted to FCa (Kroll et al., 2000)⁶, but other groups have detected the expresion of PAX8-PPAR γ gene not only in FCa but also in follicular thyroid adenomas^{7–13}. In the present study, we report the analysis of PAX8-PPAR γ gene in a series of follicular thyroid tumors, as well as immunohistochemical analysis with PPAR γ antibody.

Methods

The research included 62 patients with cytologically diagnosed follicular or Hürthle cell tumors, histologically verified as follicular or Hürthle cell adenomas or carcinomas.

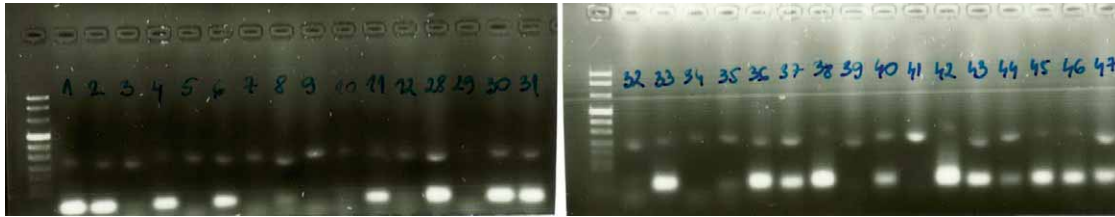


Fig. 1. RT-PCR analysis of thyroid tumors. 362 bp: presence of exons 7, 8 and 9 of the PAX8 gene; 68 bp: fusion between PAX8 exon 7 and exon 1 of PPAR γ .

Gene expression was determined by reverse transcription-polymerase chain reaction (RT-PCR). Total mRNA was isolated from paraffin embedded tissues using High Pure RNA Paraffin Kit (Roche Applied Science, EU) and translated into cDNA by reverse transcriptase PCR (Superscript II RT, Invitrogen, EU). PAX8-PPAR γ rearrangements were detected by PCR using one reverse (PAX8-R) and three forward pairs of primers (PAX8-7, PAX8-8 and PAX8-9). The nucleotide sequence of the primers was based on the mRNA sequences deposited in GenBank. Human hypoxanthine phosphoribosyl-transferase 1 (hHPRT1) was used as a referent housekeeping gene. Products of PCR reactions were separated by 1% agarose gel electrophoresis and analyzed. A 362-bp amplification band corresponds to the presence of exons 7, 8 and 9 of the PAX8 gene, a 173-bp band corresponds to PAX8 exons 7 and 9 and a 68-bp band is the result of the fusion between PAX8 exon 7 and exon 1 of PPAR γ .

Immunohistochemistry was performed on formalin-fixed paraffin-embedded sections attached to silanized slides. Microwave antigen retrieval was performed at 95 °C for 30 minutes in 10-mM citrate buffer (pH 6.0). Slides were incubated with PPAR γ monoclonal antibody E8 (SC-7273P, 1:100, Santa Cruz, CA, USA) for 60 minutes on a DAKO Autostainer. The Universal DAKO LSAB-Plus Kit detection system (avidin-biotin complex) and DAB chromogen (DAKO) were used according to manufacturer’s protocol for immune complex detection. Sections were counterstained with Mayer’s haematoxylin, dehydrated and mounted. A tumor with PAX8-PPAR γ rearrangement detected by RT-PCR was used as a positive control. Nuclear staining was scored as none (0), weak (1+), moderate (2+), or strong (3+)

The statistical analysis was conducted using the SPSS 9.0, and included the analysis of categorical variables (2x2 and RxC contingency tables), as well as the analysis of correlation and variance^{14–16}.

Results

Detection of the PAX8-PPAR γ rearrangement

RT-PCR method has proven the expression of PAX8-PPAR γ mRNA in 33% of follicular carcinomas, 14% of Hürthle cell carcinoma, but also in 33% of follicular and 19% of Hürthle cell adenoma (Figure 1). Therefore, neither individually nor globally (steam comparison of individual categories) there is no differences in expression

PAX8-PPAR γ mRNA among the analyzed histologic categories $p=0.631$, Freeman-Halton exact test, Table 1). Furthermore, there is no difference in expression between different cytological categories ($p=0.281$, Fisher exact test), or between adenomas and carcinomas ($p=0.177$, Fisher exact test).

TABLE 1
ANALYSIS OF PAX8-PPAR γ mRNA EXPRESSION IN PARAFFIN EMBEDDED TISSUES

PAX8-PPAR γ	FAd	FCa	HAd	HCa
–	9	11	11	10
+	7	7	4	3

$p=0.631$, Freeman-Halton exact test; FAd – follicular adenoma, FCa – follicular carcinoma, HAd – Hürthle adenoma, HCa – Hürthle carcinoma

Immunohistochemistry

Immunohistochemical staining with PPAR γ antibodies revealed medium and strong positive results in 3/16 follicular adenomas (18%), 3/18 follicular carcinomas (17%), 1/15 Hürthle cell adenomas (7%), 2/13 Hürthle cell carcinomas (15%) (Figure 2). Contingency table analysis has shown that there are no differences in PAX8-PPAR γ expression, neither globally nor in individually-paired comparisons of individual categories, between the analyzed histological (global $p=0.911$, Freeman-Halton exact test, Table 2) and cytological categories (global $p=0.926$, Freeman-Halton exact test).

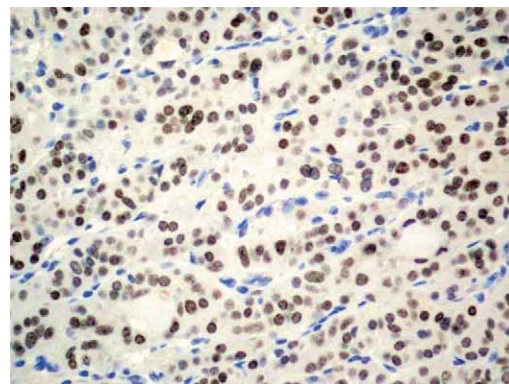


Fig. 2. Immunohistochemical staining with PPAR γ antibody; strong nuclear staining (3+).

TABLE 2
IMMUNOHISTOCHEMICAL ANALYSIS OF PAX8-PPAR γ
EXPRESSION IN PARAFFIN EMBEDDED TISSUES
(SEMIQUANTITATIVE ANALYSIS)

Pathohistological diagnosis	N	Immuno histochemistry*			
		0	1	2	3
Follicular adenoma	16	12	1	1	2
Follicular carcinoma	18	12	3	1	2
Hürthle cell adenoma	15	13	1	0	1
Hürthle cell carcinoma	13	8	3	1	1

none (0), weak (1+), moderate (2+), strong (3+)

Moreover, adenomas and carcinomas do not differ concerning the PAX8-PPAR γ immunopositivity ($p = 0.501$, Freeman-Halton exact test).

Discussion and Conclusion

This research included 62 patients with cytologically diagnosed follicular (34 patients) or Hürthle cell tumors (28 patients). Histologically, we have confirmed 16 follicular adenomas, 18 follicular carcinomas, 15 Hürthle cell adenomas and 13 Hürthle cell carcinomas.

As is well known, cytologic diagnosis has its limitations and the cytological criteria are unable to distinguish follicular lesions on smears.

Searching for a better diagnostic indicator and parameter which could be reliable in differentiating between malignant and non-malignant changes in the thyroid tissue, Kroll et al. in 2000. described the translocation of the PAX8 and PPAR γ gene [t(2;3)(q13;p25)], chimeric oncogene PAX8-PPAR γ , responsible for follicular oncogenesis. As it was found only in follicular carcinomas, and not in follicular adenomas, papillary carcinomas and nodular hyperplasia, the authors indicated it could be a potentially useful marker for distinguishing malignant and benign follicular tumors. Immunohistochemical staining with PPAR γ antibodies showed that all tumors for which the presence of PAX8-PPAR γ gene was found using RT-PCR, show strong and diffuse positivity of the nucleus to PPAR γ ⁶.

Many authors have only partially confirmed the research results described above. In 2002 Nikoforova et al. found PAX8-PPAR γ gene in 53% of follicular carcinomas, but also in 8% of follicular adenomas⁸. According to their research, follicular carcinomas in which this gene was isolated are highly invasive, as opposed to minimally invasive PAX8-PPAR γ negative carcinomas. In 2002, Marques et al.⁹ isolated PAX8-PPAR γ in 56% carcinomas, but also in 13% follicular adenomas. This translocation was not found for papillary and anaplastic carcinomas, or in nodular hyperplasia, so the authors consider this marker to be specific for follicular tumors, but not reliable enough to differentiate between carcinomas and adenomas. Similar conclusion was made by Cheung et al. in 2003, who

found the PAX8-PPAR γ oncogene in 35% follicular carcinomas, and in as many as 55% of follicular adenomas¹⁰.

Hibi et al. have analysed the expression of PAX8-PPAR γ gene in Japanese with nodular thyroid changes. They explain the negative findings in follicular adenomas and carcinomas, papillary carcinomas, nodular hyperplasia, and in normal thyroid tissue by a likely ethnic-based tendency for translocation¹⁷.

The expression of PAX8-PPAR γ gene results in the increased synthesis of PPAR γ protein. In most studies cited above, immunohistochemical staining using PPAR γ antibody was also conducted. In PAX8-PPAR γ positive tumors was found strong positivity of the nucleus to PPAR γ antibodies^{6,18}. Light and medium positivity of the nucleus and cytoplasm is found in adenomas, non-tumour changes, and in normal thyroid tissue. In 2005 Sahin et al. analysed a group of 108 patients with histologically determined follicular tumors and performed the immunohistochemical staining using PPAR γ antibody in order to determine the value of immunohistochemistry as an alternative RT-PCR method to distinguish between adenomas and carcinomas. They found the immunopositivity in 57% follicular carcinomas, 4% Hürthle cell carcinomas, and in 13% follicular adenomas, and concluded that this method is useful in distinguishing between these diseases. Moreover, according to the clinical findings they collected, they state that there is a better prognosis for patients with immunopositivity to PPAR γ antibody¹⁹. Most authors state the opposite, stressing a more frequent vascular invasion and worse long-term prognosis for patients with PAX8-PPAR γ ^{7,14,22}.

In this research we used the method of polymerase chain reaction with reverse transcription to determine the expression of PAX8-PPAR γ mRNA from paraffin embedded tissues in 62 patients with cytologically and histologically verified follicular or Hürthle cell carcinomas. RT-PCR method has proven the expression of PAX8-PPAR γ mRNA in 33% of follicular carcinoma, 14% of Hürthle cell carcinoma, but also in 33% of follicular and 19% of Hürthle cell adenoma. Therefore, neither individually nor globally (steam comparison of individual categories) there is no differences in expression PAX8-PPAR γ mRNA among the analyzed histological categories. Similarly, adenomas and carcinomas do not differ regarding the expression of mRNA. These findings support the results reported in the studies discussed above^{9,10,23,24}.

Immunohistochemical staining with PPAR γ antibody in archive paraffin embedded tissues revealed medium and strong positivity in 18% follicular adenomas, 17% follicular carcinomas, 7% Hürthle cell adenomas, and in 15% Hürthle cell carcinomas. Contingency table analysis has shown that there are no differences in PAX8-PPAR γ expression, neither globally nor in individually-paired comparisons of individual categories, between the analyzed histological and cytological categories. Moreover, adenomas and carcinomas do not differ concerning the PAX8-PPAR γ immunopositivity.

The comparison of the PAX-PPAR γ gene expression and immunohistochemical positivity showed no statistical significance.

This investigation has shown that the expression of PAX8-PPAR γ mRNA, as well as the immunohistochemical positivity do not correlate with pathohistological diagnosis.

The aim of these study was to determine the value of the PAX8-PPAR γ oncogene in differentiating between follicular adenoma and carcinoma. Its relation to follicular thyroid tumors is undoubtedly proven, but our results do not confirm the value of this oncogene as a reli-

able marker for distinguishing these tumors. Therefore, it is questionable whether all patients with cytologically diagnosed follicular tumors may avoid surgery.

Preliminary studies on the significance of PAX8-PPAR γ gene for differentiating between follicular tumors were conducted on a small number of patients. To confirm the significance of this oncogene as a prognostic factor for thyroid tumors further studies and larger samples are required.

REFERENCES

1. ČUPIĆ H, VUČIĆ M, Acta Clin Croat, 46 (2007) 25. — 2. ERSÖZ C, FIRAT P, UGUZ A, Cancer Cytopathol, 102 (2004) 302, DOI: 10.1002/cncr.20610. — 3. KOCJAN G, Current Diagnostic Pathology, 8 (2002) 201, DOI: 10.1111/j1365-2303.2010.00751.x. — 4. BULEY ID, The Thyroid gland. In: GRAY W, McKEE G (Eds) Diagnostic Cytopathology (Churchill Livingstone, Oxford, 2003), DOI: 10.1016/B978-0-7020-3154-0.00017-x. — 5. CLARY KM, KONDEL JL, LIU Y, Acta Cytol, 49 (2005) 378, DOI: 10.1159/000326169. — 6. KROLL TG, SARRAF P, PECCIARINI L, CHEN CJ, MUELLER E, SPIEGELMAN BM, FLETCHER JA, Science, 289 (2000) 1357, DOI: 10.1126/science.289.5483.1357. — 7. CERRUTI JM, DELCEO R, AMADEI MJ, J Clin Invest, 113 (2004) 1234, DOI: 10.1172/JCI19617. — 8. NIKIFOROVA MN, BIDDINGER PW, CAUDILL CM, KROLLTG, NIKIFOROV YE, Am J Surg Pathol, 26 (2002) 1016, DOI: 10.1097/00000478-200208000-00006. — 9. MARQUES AR, ESPADINHA C, CATARINO AL, MONIZ S, PEREIRA T, SOBRINHO LG, LEITE V, J Clin Endocrinol Metab, 87 (2002) 3947, DOI: 10.1038/sj.bjc.6601989. — 10. CHEUNG L, MESSINA M, GILL A, CLARKSON A, LEAROYD D, DELBRIDGE L, WENTHWORTH J, PHILIPS J, CLIFTON-BLIGH R, ROBINSON BG, J Clin Endocrinol Metab, 88 (2003) 354, DOI: 10.1210/jc.2002-021020. — 11. CASTRO P, REBOCHO AP, SOARES RJ, J Clin Endocrinol Metab, 91 (2006) 213, DOI: 10.1210/jc.2005-1336. — 12. CHEUNG CC, EZZAT S, RAMYAR L, FREEMAN JL, ASA SL, J Clin Endocrinol Metab, 85 (2000) 878, DOI: 10.1210/jc.85.2.878. — 13. KOENIG JR, Clinical Chemistry, 56 (2010) 331, DOI: 10.1373/clinchem.2009.137679. — 14. FISHER RA, Journal of the Royal Statistical Society, 87, 442. — 15. FREEMAN GH, HALTON JH, Biometrika, 38, 141, DOI: 10.2307/2332323. — 16. AGRESTI A, YANG MC, Computational Statistics and Data Analysis 5 (1987) 9, DOI: . — 17. HIBI Y, NAGAYA T, KAMBE F, Endocrine Journal, 51 (2004) 361, DOI: 10.1507/endocrj.51.361. — 18. NIKIFOROV EY, Modern Pathology, 21 (2008) 37, DOI: 10.1038/mpath.2008.10. — 19. SAHIN M, ALLARD BL, YATES M, POWELL JG, WANG XL, HAY ID, ZHAO Y, GOELLNER JR, SEBO TJ, GREBE SK, EBERHARDT NL, MCIVER B, J Clin Endocrinol Metab, 90 (2005) 463, DOI: 10.1210/jc.2004-1203. — 20. NIKIFOROVA MN, LYNCH RA, BIDDINGER PW, ALEKSANDER EK, DORN GW, TALLINI G, J Clin Endocrinol Metab, 88 (2002) 231, DOI: 10.1210/jc.2002-021907. — 21. FRENCH C, ALEXANDER EK, CIBAS ES, NOSE V, LAGUETTE J, FAQUIN W, Am J Pathol, 162 (2003) 1053, DOI: 10.1016/S0002-9440(10)63902-8. — 22. SHERMAN FJ, LEIMAN G, NAUD S, Acta Cytol, 52 (2008), 659, DOI: 10.1159/000325618. — 23. LACROIX L, MIAN C, BARRIER T, TALBOT M, CAILLOU B, SCHLUMBERGER M, BIDART JM, Eur J Endocrinol, 151 (2004) 367, DOI: 10.1530/eje.0.1510367. — 24. FISCHER S, ASA SL, Arch Pathol Lab Med, 132 (2008) 132.

B. Pauzar

»J. J. Strossmayer« University, Osijek University Hospital Center, Department of Clinical Cytology, J. Huttlera 4, Osijek 31000, Croatia
e-mail: pauzar.biljana@kbo.hr

ONKOGEN PAX8-PPAR γ U FOLIKULARNIM TUMORIMA ŠTITNJAJE – RT-PCR I IMUNOHISTOKEMIJSKA ANALIZA

SAŽETAK

Ciljana citološka punkcija pod kontrolom ultrazvuka metoda je izbora u u dijagnostici čvorastih promjena, no nedovoljno osjetljiva i specifična za razlikovanje benignih i malignih folikularnih tumora. Potencijalno koristan marker za njihovu diferencijaciju je onkogen PAX8-PPAR γ , identificiran kod folikularnog karcinoma, a ne kod folikularnog adenoma ni drugih tumora štitnjače. Cilj ovog istraživanja je određivanje kliničkog značaja PAX8-PPAR γ gena u dijagnostici folikularnih tumora štitnjače. U istraživanje su uključena 62 ispitanika s folikularnim ili Hürthleovim tumorom. Ekspresija gena je određena metodom lančane reakcije polimeraze s obrnutom transkripcijom (RT-PCR) iz parafinskih rezova, a PCR produkti provjereni elektroforezom na agaroznom gelu. Na arhivskim parafinskim rezovima je izvršeno imunohistokemijsko bojanje monoklonalnim protutijelom PPAR γ . Ekspresija PAX8-PPAR γ mRNA, kao ni imunohistokemijska analiza PPAR γ protutijelom ne korelira s patohistološkom dijagnozom. Onkogen PAX8-PPAR γ nije opravdao očekivanja u smislu pouzdanog tumorskog markera koji bi omogućio diferencijaciju benignih i malignih tumora štitnjače, te je i dalje jedino pouzdan histološki kriterij – proboj kapsule i vaskularna.