

# Skip Metastases in Papillary Thyroid Cancer

Elena Klišeska and Irena Makovac

University of Zagreb, Zagreb University Hospital Centre, Department of Otorhinolaryngology and Head and Neck Surgery, Zagreb, Croatia

## ABSTRACT

*Papillary thyroid carcinoma (PTC) is the most common malignant thyroid disease characterized by a high rate of cervical metastases (30–80%), especially due to paratracheal lymph node involvement. »Skip metastasis« are defined as a lateral lymph node metastasis without central lymph node involvement. The aim of this prospective study was to establish the lateral nodal metastasis pattern according to neck level, general occurrence and significance of skip metastasis in PTC. Forty-two previously untreated patients who presented between 2007 and 2011 with concomitant diagnosis of papillary thyroid cancer and metastatic disease of the lateral neck, underwent total thyroidectomy and central and lateral neck dissection. Skip metastases were encountered in 8(19.5%) patients, four female and four male, with a mean age of 43.3 years. In all patients with lateral skip metastasis, level III nodes were most frequently involved (75%) followed by level IV(50%), while no metastatic disease was found in level IIb. Based on our research, skip metastasis are not uncommon (a lateral lymph node metastasis without central lymph node involvement) and present in approximately 1/5 of PTC patients with cervical lymph node metastasis.*

**Key words:** papillary thyroid cancer, skip metastasis, central and lateral neck dissection

## Introduction

Papillary thyroid carcinoma (PTC) is the most common form of thyroid gland malignancy with a tendency of lymphatic spread. Lymph node metastases develop in approximately 30–80% of PTC patients<sup>1–3</sup>. Clinicopathological investigations have revealed that dissemination of tumor cells through the lymphatic system evolves in a stepwise sequential fashion: spreading from the thyroid gland, the central (pre- and paratracheal nodes and upper mediastinal) and lateral (levels II–V) lymph node compartments on the side of the thyroid tumor represent the first level of lymphatic drainage, followed by opposite lateral and the mediastinal lymph node compartments<sup>4</sup>.

»Skip metastasis« are defined as a lateral lymph node metastasis without central lymph node involvement. The incidence of skip metastasis in PTC is reported to be about 2–38%<sup>5–7</sup>. The aim of this prospective study was to establish the lateral nodal metastasis pattern according to neck level, general occurrence and significance of skip metastasis in PTC.

## Methods

This prospective study included 42 previously untreated patients who presented between 2007. and 2011.

with concomitant diagnosis of papillary thyroid cancer and metastatic disease of the lateral neck. All patients preoperatively underwent ultrasonography. Diagnosis of primary tumor and lymph node metastasis has been confirmed by fine-needle aspiration cytology (FNAC). Thyroidectomy and neck dissection specimens were histologically examined. All surgical procedures were carried out by a single surgeon. Excluded were patients with any previous treatment of the thyroid gland and/or neck (including irradiation). All patients underwent total thyroidectomy and therapeutic neck dissection of both central and lateral compartments. Bilateral lateral neck dissection was carried out in six patients.

The central compartment dissection included four nodal sublevels: pretracheal, both ipsilateral and contralateral paratracheal and superior mediastinal below the sternal notch. In all patients complete removal of lateral cervical lymph nodes was performed (levels II to V)<sup>8,9</sup>. The neck levels, sublevels (IIa and IIb, respectively) and central nodal sublevels were marked and sent for histological examination. Sublevel IIb contents were always processed as a separate specimen. A diagnosis of skip metastasis was made exclusively after histological confirma-

tion of nodal metastasis in the lateral neck, leaping the central lymph node compartment.

**Results**

The study group of 42 patients underwent total thyroidectomy and therapeutic neck dissection (both central and lateral). Bilateral lateral neck dissection was carried out in six patients. One patient was excluded from the study based on false positive FNAC, showing no metastasis disease in lymph nodes following histological examination; therefore the final number of analyzed patients was 41.

The main observation of this prospective study was group of patients with skip lateral metastasis and no metastatic involvement of central lymph nodes. Skip metastases were encountered in eight (19.5%) patients, four female and four male, with a mean age of 43.3 years. No single patient from this group had bilateral neck dissection. Ipsilateral lateral neck dissection was carried out in seven (87.5%) patients and contralateral lateral neck dissection in one patient.

Primary tumor was in right thyroid lobe in four, in left thyroid lobe in three patients, while one patient presented with primary tumor in both thyroid lobes.

Assessment of the primary tumor stage revealed T1 lesions in one patient, T2 in one patient and T3 tumor in six patients (75%). Multicentric lesions were found in six (75%) and extrathyroid spread in five patients (62.5%), respectively.

Out of eight lateral neck dissection tissues, six patients (75%) showed nodal disease at multiple levels and two had single level disease. Out of latter two specimens with single level disease, one had metastatic disease in level II and one in level IV. In all patients with lateral skip metastasis, level III nodes were most frequently involved (75%) followed by level IV(50%), while no metastatic disease was found in level IIb. Level V involvement was always associated with multiple level disease (Figure 1).

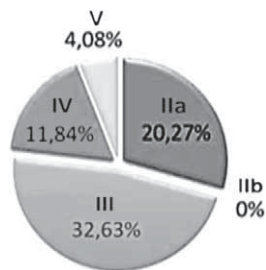


Fig. 1. Percentage of lateral neck involvement: level IIa (20.27%), level IIb (0%), level III (32.63%), level IV (11.84%), level V (4.08%).

In all lateral neck dissection specimens, 263 lymph nodes were observed and 41 were found positive (Figure 2). In four patients (50%) extracapsular spread was found (total of 10 metastatic lymph nodes). In one patient

IIa	74/15
IIb	24/0
III	52/17
IV	59/7
V	49/2

Fig. 2. Total number of isolated lymph nodes in eight patients (total thyroidectomy and lateral neck dissection) from level IIa-V was 263, and number of positive metastatic lymph nodes in lateral neck level (IIa-V) was 41.

extracapsular spread in two metastatic levels (III and IV) was observed.

**Discussion**

This prospective study comprised eight patients with skip lateral metastasis, singled out from very homogeneous group of 41 previously untreated patient, presented with concomitant diagnosis of PTC and metastatic disease of the lateral neck. All patients underwent total thyroidectomy and a comprehensive central and lateral neck dissection in an uniform fashion by a single surgeon.

Lymph node metastases develop in approximately 30–80% of papillary thyroid carcinoma patients<sup>1-3</sup>. Cervical metastases occur first to the nodes in the tracheoesophageal groove and subsequently in the lateral neck<sup>1,10</sup>. Skip metastasis with its erratic mode of lymphatic spread (a lateral lymph node metastasis without central lymph node involvement), are a genuine phenomenon of low-intensity nodal dissemination in thyroid cancer<sup>11</sup>. The incidence of skip metastasis in previous studies was shown to be between 2–38%<sup>5-7</sup>. According to our study occurrence of skip metastasis was relatively high (19.5%), similar to one reported in a previous study by Pinkpank et al.<sup>7</sup>. Byung-Joo Lee et al. believe that high rate of skip metastases can be explained by including patients with previous neck treatment (total thyroidectomy or lateral cervical surgery)<sup>12</sup>. However, according to our study which included only previously untreated patients, this hypothesis was refuted. Ultrasonography and FNAC of primary tumor and lymph node metastasis have proved to be valid preoperative diagnostic procedures. Hwang HS et al. and Joon Y et al. in their recent work concur that preoperative neck ultrasonography due to it’s high sensitive and specific nature in predicting cervical lymph node metastasis provides reliable information to assist in surgical management of PTC patients<sup>13,14</sup>. On the other side, this was opposed by Imidat Yuce et al. who suggested routine computed tomography (CT) evaluation for all patients with palpable jugular lymph node metastasis because retropharyngeal metastases will be missed by routine ultrasonography<sup>15</sup>. Regarding the high occurrence of central and lateral lymph node metastasis and on the other hand rare presence of retropharyngeal metastasis

in PTC patients, we believe CT takes role in patient follow up especially in the setting of recurrent disease.

In the present study, the lateral nodal metastasis pattern according to neck level was similar to that reported previously and first described by Sivanadan and Soo et al. The majority of patients presented with multiple-level metastasis. The nodal groups of levels II, III and IV were found to be at greatest risk of metastatic disease, with level III nodes being the most frequently involved. The results of this study correspond with the results of previous studies<sup>7,9,10,12,15–22</sup>. However, Ducci et al. and Roh JL at al, reported that level IV nodes are the most frequent metastatic lymph nodes<sup>5,23</sup>.

Neck dissection of the lymph node at level IIb in PTC is associated with the risk of spinal accessory nerve injury, despite preservation, resulting from traction and elevation during removal of metastatic lymph nodes. Therefore, it is essential to investigate the incidence of level IIb lymph node metastasis in patients with lateral cervical metastatic lymph node in PTC<sup>12</sup>. In our prospective study in all revised lateral neck dissection specimens, in

level IIb no metastatic disease was found. This findings were slightly different from those of prior studies<sup>20,21</sup>. Although mentioned authors also found level IIb to be the least represented site of metastatic disease, at least a small percentage (7–21%) of positive lymph nodes was found. In the future we plan to establish whether neck dissection of the lymph node at level IIb is necessary in patients if level IIa is uninvolved.

## Conclusion

Based on our research, skip metastasis are not uncommon (a lateral lymph node metastasis without central lymph node involvement) and present in approximately 1/5 of PTC patients with cervical lymph node metastasis. Ultrasonography and FNAC of primary tumor and lymph node metastasis have proved to be valid preoperative diagnostic procedures. Most patients had multilevel nodal involvement at the time metastatic disease was found.

## REFERENCES

1. SHAHA AR, Otolaryngol Clin North Am, 31 (1998) 823. DOI: 10.1016/S0030-6665(05)70090-6 — 2. SHAHA AR, SHAH JP, LOREE TR, Am J Surg, 172 (1996) 692. DOI: 10.1016/S0002-9610(96)00310-8 — 3. MCGREGOR GI, LUOMA A, JACKSON SM, Am J Surg, 149 (1985) 610. DOI: 10.1016/S0002-9610(85)80137-9 — 4. MACHENS A, HINZE R, THOMUSCH O, DRALLE H, World J Surg, 26 (2002) 22. — 5. DUCCI M, APPETECCIA M, MARZETTI M, J Exp Clin Cancer Res, 16 (1997) 333. — 6. COATESWORTH AP, MACLENNAN K, Int J Clin Pract, 56 (2002) 241. — 7. PINGPANK JF JR, SASSON AR, HANLON AL, FRIEDMAN CD, RIDGE JA, Arch Otolaryngol Head Neck Surg, 128 (2002) 1275. — 8. ROBBINS KT, CLAYMAN G, LEVINE PA, Arch Otolaryngol Head Neck Surg, 128 (2002) 751. — 9. WADA N, DUH QY, SUGINO K, Ann Surg 237 (2003) 399. DOI: 10.1097/00000658-200303000-00015 — 10. NOGUCHI S, NOGUCHI A, MURAKAMI N, Cancer, 26 (1970) 1053. DOI: 10.1002/1097-0142(197011)26:5<1053::AID-CNCR2820260513>3.0.CO;2-X — 11. MACHENS A, HOLZHAUSEN HJ, DRALLE H, Arch Surg, 139 (2004) 43. — 12. LEE BJ, WANG SG, LEE JC, SON SM, KIM IJ, KIM YK, Arch Otolaryngol Head Neck Surg, 133 (2007) 1028. DOI: 10.1001/archotol.133.10.1028 — 13. HWANG HS, ORLOFF LA, Laryngo-

- scope, 121 (2011) 487. DOI: 10.1002/lary.21227 — 14. YOON JH, KIM JY, MOON HJ, YOON JH, SON EJ, KIM EK, HAN KH, KWAK JY, Ann Surg Oncol, 18 (2011) 1734. — 15. YÜCE I, CAGLI S, BAYRAM A, KARASU F, GÜNEY E, Eur Arch Otorhinolaryngol, 267 (2010) 437. DOI: 10.1007/s00405-009-1032-6 — 16. GIMM O, RATH FW, DRALLE H, Br J Surg 85 (1998) 252. DOI: 10.1046/j.1365-2168.1998.00510.x — 17. SIVANANDAN R, SOO KC, Br J Surg 88 (2001) 1241. DOI: 10.1046/j.0007-1323.2001.01843.x — 18. KUPFERMAN ME, PATTERSON M, MANDEL SJ, LIVOLSI V, WEBER RS, Arch Otolaryngol Head Neck Surg, 130 (2004) 857. DOI: 10.1001/archotol.130.7.857 — 19. WADA N, DUH QY, SUGINO K, IWASAKI H, KAMEYAMA K, MIMURA T, ITO K, TAKAMI H, TAKANASHI Y, Ann Surg, 237 (2003) 399. DOI: 10.1097/01.SLA.0000055273.58908.19 — 20. YANIR Y, DOWECK I, Laryngoscope, 118 (2008) 433. DOI: 10.1097/MLG.0b013e31815ae3e4 — 21. FARRAG T, LIN F, BROWNLEE N, KIM M, SHETH S, TUFANO RP, World J Surg, 33 (2009) 1680. DOI: 10.1007/s00268-009-0071-x — 22. KOO BS, YOON YH, KIM JM, CHOI EC, LIM YC, Ann Surg Oncol, 16 (2009) 1344. — 23. ROH JL, KIM JM, PARK CI, Ann Surg Oncol, 15 (2008) 1177.

E. Klišeska

University of Zagreb, Zagreb University Hospital Center, Department of Otorhinolaryngology and Head and Neck Surgery, Kišpatičeva 12, 10000 Zagreb, Croatia  
e-mail: kliseska\_elen@yahoo.com

## SKIP METASTAZE KOD PAPILARNOG KARCINOMA ŠTITNJAČE

### SAŽETAK

Papilarni karcinom štitnjače (PTC) je najčešća maligna bolest štitnjače, karakterizirana visokom stopom vratnih metastaza (30-80%), osobito zbog uloge paratrahealnih limfnih čvorova. »Skip metastaze« su definirane kao metastaze u lateralnim regijama vrata, bez zahvaćenosti središnjih limfnih čvorova. Cilj ove prospektivne studije bilo je utvrditi karakteristike metastaza u lateralne regije vrata kod PTC, učestalost pojave skip metastaza i njihov značaj. Kod četir-

deset i dva prethodno neliječena pacijenta između 2007. i 2011. sa istodobnom dijagnozom papilarnog karcinoma štitnjače i metastaze u lateralnim regijama vrata, učinjena je totalna tireoidektomija, te centralna i lateralna disekcija vrata. Skip metastaze su dokazane u 8 (19,5%) bolesnika, četiri žene i četiri muškarca, s prosječnom dobi od 43,3 godina. U svih bolesnika sa lateralnim metastazama, najučestalija regija metastaziranja je bila regija III (75%), zatim regija IV (50%), dok u regiji IIb nije pronađena metastatska bolest. Na temelju naših istraživanja, skip metastaze nisu rijetkost (metastaze u lateralnim limfnim čvorovima bez zahvaćenosti središnjih limfnih čvorova) i prisutne su u oko 1/5 od PTC bolesnika.