

# Morphometry in Differential Diagnosis of Pathologically Altered Parathyroid Glands: Adenoma and Hyperplasia

Ljubica Fuštar-Preradović<sup>1</sup>, Božena Šarčević<sup>2</sup> and Davorin Đanić<sup>3</sup>

<sup>1</sup> »Dr. Josip Benčević« General Hospital, Department of Pathology, Forensic Medicine and Cytology, Slavonski Brod, Croatia

<sup>2</sup> University of Zagreb, »Sestre Milosrdnice« University Hospital Center, Department of Pathology, University Hospital for Tumors, Zagreb, Croatia

<sup>3</sup> »Dr. Josip Benčević« General Hospital, Department of Otorhinolaryngology and Maxillofacial Surgery, Slavonski Brod, Croatia

## ABSTRACT

Simple morphological identification of a sample as parathyroid gland tissue is not always sufficient for optimal patient treatment. Instead, patients with parathyroid gland lesions that increase the risk of disease relapse should be identified. To assess the possibility of differentiating adenoma from hyperplasia in preoperative material by use of computerized morphometric analysis in order to enable better preoperative work-up in patients with hyperparathyroidism. Samples obtained by US guided fine-needle aspiration biopsy of 67 parathyroid glands without known histopathologic diagnosis were dried and stained by May-Grünwald-Giemsa. Fifty nuclei per sample were analyzed and designated automatically with manual correction using image analyzer and specific software. The area, circumference, convexity, minimal and maximal radius, length and width, and factors of regularity, i.e. form factor and factor of nucleus elongation, were determined for each nucleus. Basic descriptive parameters and measures of variability (variation coefficient and standard deviation) were calculated for each continuous variable. The correlation of continuous variables was analyzed by use of Mann-Whitney test. Computer analysis of cell image classified the cell nuclei into two groups. The area, circumference, minimal radius, convexity and width of the nuclei showed higher values in the hyperplasia group as compared with the adenoma group. Standard deviation also showed higher values of each of the study parameters in the former group. Our own observations and subjective assessment of variations in nucleus size to represent substantial characteristics differentiating parathyroid adenoma and hyperplasia in cytologic smear were quantitatively verified by the use of objective morphometric measurement and should therefore be considered valid parameters on differentiating these two entities.

**Key words:** parathyroid gland cytology, adenoma, hyperplasia, morphometry

## Introduction

Since the first morphological description of parathyroid gland cells in cytologic smear, attempts have been made to identify morphological differences between parathyroid adenoma and parathyroid hyperplasia. Such an approach has greatly contributed to the development of parathyroid cytomorphological diagnosis. Differentiation between adenoma and hyperplasia exclusively based on morphology remains an issue for debate to the present. Morphological diagnosis relies on visual perception or diagnostic criteria for various tissue samples, which require specific training of the morphologist. Although the

majority of morphological criteria have been clearly defined for each disease, differences in their interpretation are still possible, as reported in numerous studies for various neoplasms, inflammatory diseases and other pathologic processes. The problem of reproducibility is even more pronounced when other parameters such as prognostic criteria (level of differentiation, mitotic activity) or sample quality (type, method and time of fixation, staining technique) are introduced<sup>1</sup>.

Simple morphological identification of a sample as parathyroid gland tissue is not always sufficient for opti-

mal patient treatment at long term. Parathyroid gland hyperplasia is known to recur frequently in spite of radical and properly done operation<sup>2,3</sup>. Thus, additional information is necessary to identify patients with tumors that increase the risk of recurrence in patients with parathyroid gland hyperplasia. Many parameters have been investigated using immunocytochemistry and other methods, e.g., total mass of parathyroid parenchyma, nodular growth pattern, absence of adipose cells, and mitotic index<sup>3</sup>. On immunocytochemistry, parathyroid gland cells show positive reaction to cytokeratin 8, 18 and 19, chromogranin A and parathormone, and negative reaction to thyroglobulin (positive in parathyroid gland epithelial cells). As chromogranin A and parathormone are positive in the cells of normal, hyperplastic and neoplastic parathyroid glands, they cannot be used to differentiate the nature of alteration<sup>4,5</sup>. Recently, however, immunohistochemistry of operative material has demonstrated that high Ki-67 may be indicative of an increased risk of recurrence in patients with parathyroid hyperplasia<sup>3,6</sup>. Development of molecular biology and cytogenetics was expected to solve the everlasting problem of differential diagnosis between parathyroid adenoma and hyperplasia through clonality studies; however, it failed. Adenoma was found to show clonality, which was also observed in parathyroid diseases characterized by clinical and morphological features of primary or secondary hyperplasia where a nodular component was detected<sup>7–9</sup>. Thus, the presence of clonality need not imply the presence of neoplasia and the issue of differential diagnosis of parathyroid pathologic lesions remains unsolved<sup>10,11</sup>.

According to literature data, computerized morphometric analysis of cell pattern in cytologic aspirate of various tissues can differentiate tumor from other pathologic states, as well as various histopathologic tumor types and degree of tumor differentiation, based on some quantitative parameters<sup>12–18</sup>.

In the present study, cytomorphological features of the parathyroid gland cell nuclei obtained by target ultrasound guided fine-needle aspiration biopsy (US-FNAB) were objectively tested in aspirate smears. The aim was to assess the possibility of differentiating parathyroid adenoma from parathyroid hyperplasia in preoperative material, which would upgrade the preoperative work-up in patients with hyperparathyroidism, reduce the operation time, improve therapeutic results, and in case of solitary tumors spare the patient from bilateral neck exploration, while reducing the rate of hyperparathyroidism recurrence that requires major reoperation of uncertain prognosis.

## Materials and Methods

Sixty-seven parathyroid gland US-FNAB smears with unknown histopathologic diagnosis were included in the study. The aspirates were subsequently divided according to histopathologic diagnosis into two groups of parathyroid hyperplasia and parathyroid adenoma. The group of parathyroid hyperplasia included 53 (79%) aspi-

rates of patients with chronic renal insufficiency currently on hemodialysis (21 male and 32 female), mean age 49.5 (range 25–75) years. The group of parathyroid adenoma included 14 (21%) aspirates from 3 male and 11 female patients, mean age 62.2 (range 45–83) years (Table 1).

**TABLE 1**  
PATIENT MEAN AGE AND AGE RANGE ACCORDING TO  
PARATHYROID GLAND DIAGNOSIS

Diagnosis	n (%)	Patient age (yrs)		P*
		Mean (SD*)	Range	
Parathyroid hyperplasia	53 (79)	49.5 (14.6)	25–75	0.005
Parathyroid adenoma	14 (21)	62.2 (9.9)	45–83	

\*Mann-Whitney test

Ultrasonographic studies were performed on an ALOKA SSD-256 US device with a 5-MHz probe for superficial tissues and a DIASONICS CV 400 device with 7.5-, 10- and 13-MHz probes. US-FNAB was performed by free-hand technique.

All US-FNAB smears were air dried and stained by the standard May-Grünwald-Giemsa method. Each slide was examined under Olympus BX 50 microscope connected to computer image analyzer, initially at low magnification to select a representative area; then the selected area was systematically explored under immersion objective (magnification X1000). Morphometric measurements were done on a PC using the SFORM (VAMSTEC, Zagreb, Croatia) software. The system consists of a high-resolution color camera, which digitalizes microscope image and transfers it to the PC.

Fifty nuclei were analyzed *per* sample. Cytoplasm were not measured because they mostly are unsharply demarcated, and bare nuclei of parathyroid epithelial cells are quite frequently found in aspirate smear. Cell borders were designated automatically with manual correction. In order to obtain some possibly reproducible parameters for cytologic differentiation of parathyroid tumor and hyperplasia, the features determining average nucleus size and features determining the grade of anisokaryosis including nucleus area, circumference, convexity, minimal and maximal radius, length and width, and factors of regularity (form factor and factor of nucleus elongation (nucleus length to width ratio) were determined for each nucleus. Upon testing completion, patients were divided into two groups based on histopathologic findings: parathyroid hyperplasia and parathyroid adenoma. The basic descriptive parameters (minimal/maximal value and arithmetic mean) and variability measures (coefficient of variation and standard deviation) were calculated for each continuous variable. The pattern of distribution was assessed for each continuous variable. The mean value as a measure of central tendency and a central value based on the value size, and standard deviation (SD) as a measure of deviation of arithmetic means of the samples from one population

from arithmetic means of the population were determined. The correlation of continuous variables in the two groups was analyzed by the Mann-Whitney test as the most sensitive nonparametric test, along with the rank-sum calculation<sup>19</sup>.

## Results

Measurement results and SD for parathyroid hyperplasia and parathyroid adenoma are shown in Table 2.

The values of nucleus area, nucleus circumference, nucleus minimal radius, nucleus convexity and nucleus width were higher in the group of parathyroid hyperplasia and the difference from the group of parathyroid adenoma was statistically significant (Fig. 1).

The following nucleus parameters showed higher mean values (SD) in parathyroid hyperplasia as compared with parathyroid adenoma, all yielding statistically significant differences (*P*): nucleus area 48.40 (SD 12.76)  $\mu\text{m}^2$  vs. 40.78 (SD 9.45)  $\mu\text{m}^2$  ( $P=0.033$ ); nucleus

**TABLE 2**  
MEAN VALUES OF NUCLEUS PARAMETERS ACCORDING TO PARATHYROID GLAND DIAGNOSIS

Parameter	Parathyroid hyperplasia				Parathyroid adenoma				<i>P</i> <sup>†</sup>
	Mean	SD*	Min	Max	Mean	SD*	Min	Max	
Nucleus area	48.40	12.76	20.60	73.48	40.78	9.45	30.37	59.07	0.033
Nucleus circumference	25.58	3.63	16.61	32.17	23.54	2.79	20.21	28.65	0.039
Nucleus minimal radius	3.32	0.50	2.09	4.24	3.00	0.40	2.52	3.77	0.024
Nucleus maximal radius	4.31	0.58	2.88	5.32	4.01	0.44	3.40	4.78	0.062
Nucleus convexity	49.08	12.95	20.91	74.62	41.39	9.55	30.76	59.86	0.033
Nucleus length	8.25	1.13	5.45	10.16	7.66	0.87	6.46	9.17	0.052
Nucleus width	7.27	1.06	4.71	9.29	6.63	0.82	5.70	8.27	0.030
Factor of nucleus regularity	0.90	0.01	0.88	0.93	0.91	0.01	0.88	0.93	0.963
Factor of nucleus elongation	1.14	0.04	1.07	1.26	1.17	0.05	1.10	1.24	0.131

\*standard deviation; <sup>†</sup>Mann-Whitney test

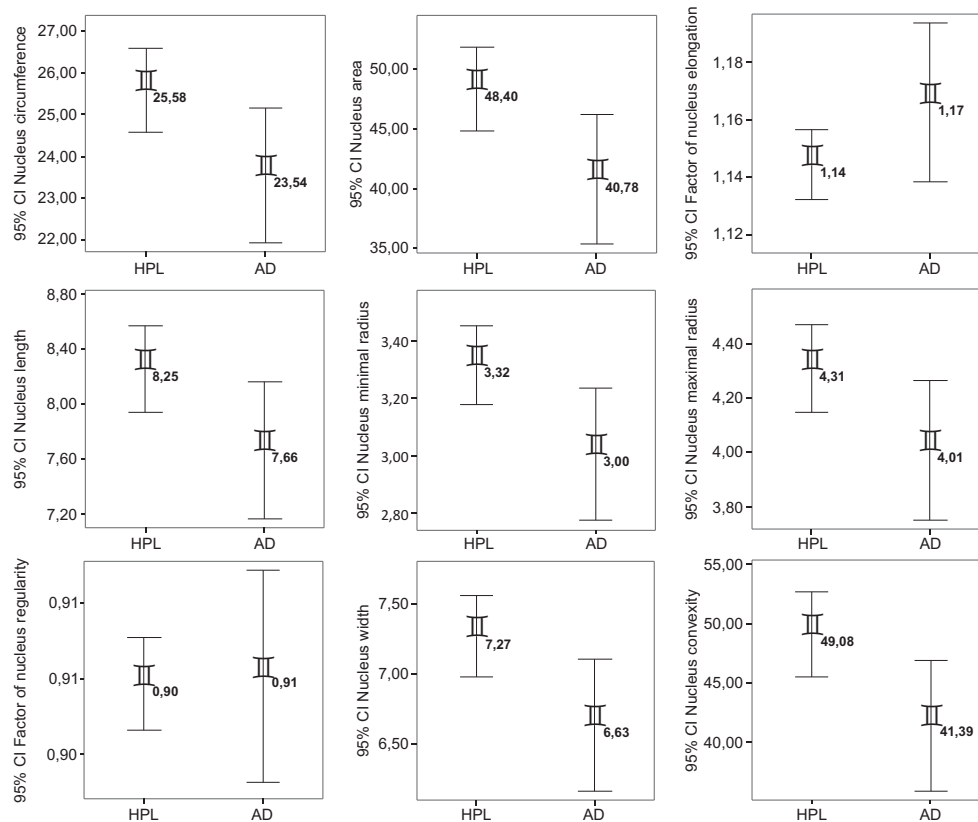


Figure 1. Mean value and confidence interval for nucleus parameters according to diagnostic groups.

circumference 25.58 (SD 3.63)  $\mu\text{m}$  vs. 23.54 (SD 2.79)  $\mu\text{m}$  ( $P=0.039$ ); nucleus minimal radius 3.32 (SD 0.50)  $\mu\text{m}$  vs. 3.00 (SD 0.40) ( $P=0.024$ ); nucleus convexity 49.08 (SD 12.95)  $\mu\text{m}$  vs. 41.39 (SD 9.55)  $\mu\text{m}$  ( $P=0.033$ ); and nucleus width 7.27 (SD 1.06)  $\mu\text{m}$  vs. 6.63 (SD 0.82)  $\mu\text{m}$  ( $P=0.030$ ). The mean values of nucleus maximal radius and nucleus length were higher in parathyroid hyperplasia as compared with parathyroid adenoma, however, the difference did not reach statistical significance ( $P=0.062$  and  $P=0.052$ , respectively). The form factor and factor of nucleus elongation were comparable in the two groups (Figure 1).

## Discussion

Differential diagnosis between parathyroid hyperplasia and parathyroid adenoma remains an open question not only in the analysis of preoperative cytologic samples but also in the analysis of postoperative histopathologic samples<sup>2</sup>. In addition, it is well known and already reported in the literature that relapses of parathyroid hyperplasia also occur after radical and properly performed operative procedures<sup>2,3</sup>. In order to establish a more precise differential diagnosis between these parathyroid gland pathologic lesions, numerous parameters have been investigated in postoperative histopathologic samples, e.g., total mass of parathyroid glands, nodular growth pattern, absence of adipose cells, etc.<sup>3</sup>. However, preoperative localization of the pathologic process in patients with hyperparathyroidism is associated with reduced operation time and improved therapeutic outcome, while patients are spared from bilateral neck exploration in case of solitary lesions. In addition, the rate of hyperparathyroidism recurrence, which requires technically demanding reoperation of uncertain prognosis, is decreased. Therefore, the present study was focused on the search for new and objective possibilities to detect parathyroid gland cells in preoperative FNAB smears and to identify some new morphological parameters for differentiation of parathyroid hyperplasia and parathyroid adenoma in cytologic material.

The parameters related to the mean nuclear size of parathyroid gland cells and the features determining the

grade of anisokaryosis (nucleus area, circumference, convexity, minimal and maximal radius, length and width, and regularity factors, i.e. form factor and factor of nucleus elongation (nucleus length to width ratio) were measured. Based on these parameters, computer analysis of the cell image classified cell nuclei into two groups. Subsequent correlation with histopathologic findings revealed the cell nuclei with higher values of the nucleus area, circumference, minimal nucleus radius, convexity and width to belong to the hyperplasia group, while those showing lower values of these parameters belonged to the adenoma group. On extrapolating these findings to cell morphology, FNAB smears from parathyroid hyperplasia patients contained cells with larger nuclei as compared with FNAB smears from adenoma patients. In addition, standard deviation showed higher values of all study parameters in the group of parathyroid hyperplasia as compared with the group of parathyroid adenoma, suggesting greater cell size heterogeneity and inequality in the former.

The form factor and factor of nucleus elongation were comparable in the two groups, pointing to the uniformity of nucleus shape, thus these parameters cannot be used to differentiate the two entities.

Our observations and subjective assessment of the variation in nucleus size as the substantial characteristic differentiating parathyroid hyperplasia and parathyroid adenoma in FNAB smear were quantitatively confirmed by use of objective morphometric measurement and statistical data analysis. Thus, this variation can be considered a valid parameter for differentiation of the two entities.

In conclusion, based on the results presented, the method can be employed as a routine cytodagnosis procedure, offering better preoperative work-up in patients with pathologic parathyroid lesions and reducing dilemmas in case of hyperparathyroidism treatment with percutaneous alcohol inactivation of pathologically altered parathyroid glands or hypoparathyroidism treatment with remnant parathyroid tissue autotransplantation requiring differentiation of hyperplasia and adenoma.

## REFERENCES

1. MACHEVSKY AM, ERLER BS, Morphometry in pathology. In: MACHEVSKY AM (Eds) Image analysis. A primer for pathologists (Raven Press, New York, 1994).
2. ABBONA GC, PAPOTTI M, GASPARRI G, BUSOLATI G, Endocr Pathol, 7 (1996) 55. DOI: 10.1007/BF02739915.
3. TUCCARI G, ABBONA GC, GIUFFRÉ G, PAPOTTI M, Virchows Arch, 437 (2000) 298. DOI: 10.1007/s004280000228.
4. DELELLIS RA, SHIN SJ, Immunohistology of endocrine tumors. In: DABBS JD (Eds) Diagnostic immunohistochemistry (Churchill Livingstone, Philadelphia, 2006).
5. APEL RL, ASA SL, The parathyroid glands. In: LIVOLSI VA, ASA SL (Eds) Endocrine pathology (Churchill Livingstone, Philadelphia, 2002).
6. ABBONA GC, PAPOTTI M, GASPARRI G, BUSOLATI G, Hum Pathol, 26 (1995) 135. DOI: 10.1016/0046-8177(95)90028-4.
7. KOSHISHI N, CHONG JM, FUKASAWA T, IKENO R, TANAKA A, KANAZAWA K, OGURA M, EBUCHI M, TAKIZAWA T, FUNATA N, FUKUYAMA M, Lab Invest 79 (1999) 1051.
8. SHAN L, NAKAMURA M, NAKAMURA Y, INOUE D, MORIMOTO S, YOKOI T, KAKUDO K,

9. SHAN L, YANG Q, NAKAMURA Y, NAKAMURA M, MIYAUCHI A, TSUJIMOTO M, NAKATANI Y, WAKASA K, MORI I, KAKUDO K, Mod Pathol, 14 (2001) 273. DOI: 10.1038/modpathol.3880302.
10. DELELLIS RA, TISCHLER AS, Endocr Pathol 9 (1998) 281. DOI: 10.1007/BF02739687.
11. SANJUAN X, BRYANT BR, SOBEL ME, MERINO MJ, Endocr Pathol, 9 (1998) 293. DOI: 10.1007/BF02739689.
12. VAN DIEST PJ, BAAK JPA, Morphometry. In: BIBBO M (Eds) Comprehensive cytopathology (WB Saunders Company, Philadelphia, 1991).
13. BARTELS PH, THOMPSON D, KOSS LG, Digital analysis of cells and tissues. In: KOSS LG (Eds) Diagnostic cytopathology and its histopathologic bases (JB Lippincott, Philadelphia, 2006).
14. KARDUM-SKELIN I, Morfometrijski i kinetički parametri kao dijagnostički i prognostički čimbenici leukemij-skih oblika kroničnih limfoproliferativnih bolesti [In Croat] PhD Thesis (University of Zagreb, Zagreb, 2008).
15. MASUDA T, TEZUKA F, KONNO H, TOGASHI A, ITOH Y, SUGAWARA T, Anal Quant Cytol His-

tol, 10 (1988) 294. — 16. CROCKER J, JONES EL, CURRAN RC, J Clin Pathol, 36 (1983) 298. DOI: 10.1136/jcp.36.3.298. — 17. BONDESON L, BONDESON AG, LINDHOLM K, LJUNGBERG O, TIBBLIN S, 27 (1983) 437. — 18. FU YS, FERENCZY A, HUANG I, GELFAND MM, Anal Quant

Cytol Histol, 10 (1988) 139. — 19. IVANKOVIĆ D, Osnove statističke analize za medicinare [In Croat] (Biblioteka udžbenici i priručnici Medicinskog fakulteta u Zagrebu, Zagreb, 1988).

*Lj. Fuštar-Preradović*

»Dr. Josip Benčević« General Hospital, A. Štampara 42, 35000 Slavonski Brod, Croatia

e-mail: ljubica.fustar.preradovic@sb.t-com.hr

## MORFOMETRIJA U DIFERENCIJALNOJ DIJAGNOZI PATOLOŠKI PROMIJENJENIH DOŠTITNIH ŽLIJEZDA

### S A Ž E T A K

Jednostavan odgovor morfologa da se radi o tkivu doštitnih žlijezda nije uvijek dovoljan za optimalno liječenje bolesnika. Potrebno je izdvojiti bolesnike s promjenama koje povećavaju rizik od pojave recidiva. Cilj rada je u materijalima dobivenim prije operacije istražiti mogućnosti razlikovanja adenoma od hiperplazije primjenom kompjutorizirane morfometrijske analize radi što bolje prijeoperacijske obrade bolesnika s hiperparatireoidizmom. Analizirani su razmazi punktata 67 doštitnih žlijezda bez poznate patohistološke dijagnoze, dobiveni ultrazvučno vođenom citološkom punkcijom, osušeni i bojani po May-Grünvald-Giemsu. Analizirano je 50 jezgara po uzorku, označavane su automatski uz ručnu korekciju. Rabio se analizator slike i specifični računalni program. Za svaku jezgru određeni su površina, opseg, zakrivljenost, najmanji i najveći polumjer, duljina i širina jezgre, te faktori pravilnosti, tj. form faktor i faktor izduženosti jezgre. Za svaku kontinuiranu varijablu izračunati su osnovni opisni pokazatelji i mjere varijabilnosti (koeficijent varijacije i standardna devijacija). Mann-Whitney testom analizirana je povezanost kontinuiranih varijabla. Kompjutorska analiza stanične slike klasificirala je jezgre analiziranih stanica u dvije skupine. Površina jezgre, opseg jezgre, minimalni polumjer jezgre, zakrivljenost jezgre i širina jezgre pokazali su veće vrijednosti u skupini hiperplazija negoli u skupini adenoma. Standardna devijacija za svaki izmjereni parametar također je pokazala više vrijednosti u skupini hiperplazija. Primjenom objektivnog morfometrijskog mjerenja su i kvantitativno potvrđena vlastita opažanja i subjektivna prosudba da su razlike u veličini jezgara bitne značajke u razlikovanju adenoma od hiperplazije doštitne žlijezde u citološkom razmazu, te ih treba smatrati valjanim parametrima za razlikovanje ovih dvaju entiteta.