

Non-functional Parathyroid Gland Carcinoma, a Rare Malignant Tumor of the Head and Neck

Željko Kotromanović¹, Darija Birtić¹, Andrijana Včeva¹, Darija Medić², Željko Zubčić¹, Hrvoje Mihalj¹,
Zdenka Kotromanović³, Suzana Erić³, Branko Dmitrović⁴ and Mario Štefanić⁵

¹ »J. J. Strossmayer« University, Osijek University Hospital Centre, Department of Otorhinolaryngology Head and Neck Surgery, Osijek, Croatia

² Polyclinic SUVAG, Osijek, Croatia

³ »J. J. Strossmayer« University, Osijek University Hospital Centre, Department of Radiotherapy and Oncology, Osijek, Croatia

⁴ »J. J. Strossmayer« University, Osijek University Hospital Centre, Department of Pathology, Osijek, Croatia

⁵ »J. J. Strossmayer« University, Osijek University Hospital Centre, Department of Nuclear Medicine and Radiation Protection, Osijek, Croatia

ABSTRACT

Carcinoma of the parathyroid gland is a very rare tumor of the head and neck. The largest number of carcinomas are discovered by chance. (intraoperatively, during surgery removal of the parathyroid gland are adenomas). Around 1% of the primary hyperparathyroidism is caused by the cancer of parathyroid glands. Only 10% of these rare tumors make up dysfunctional cancer of parathyroid glands. There have been 24 cases reported of this disease in the literature. The focus of our study is to present a case of this disease and to review the published literature to date.

Key words: parathyroid gland, hypoparathyroidism, cancer, nonfunctional carcinoma, PTH

Introduction

Carcinoma of the parathyroid gland is exceptionally rare. Most of these tumors secrete elevated parathyroid hormone (PTH), so 1% of cases of primary hyperparathyroidism is caused by parathyroid carcinoma^{1,2}, in which case it is a hyperfunctional parathyroid carcinoma, which accounts about 90% of parathyroid carcinomas. According to the literature so far it was published about 700³ cases of this rare disease, and the largest study to date shows the experience with 286 patients (the American National Center On Base)⁴.

Non-functional parathyroid carcinoma is extremely rare tumor that occurs in 10% of patients with parathyroid carcinoma, and so far the published literature contains only 21 cases of this disease^{6–12} including our case, Table 1. Because of the extremely rare occurrence of this disease, experience and process of treatment are quite limited.

History

Our patient reported to the review in 2007, a 65 year old white male who noticed swelling on the right side of the neck measuring about 4–5 cm, which showed a tendency of rapid growth. He had no subjective problems with breathing and swallowing. Outpatient ultrasound was done and cytological puncture lesion in the neck, and due to cytological suspicion of parathyroid carcinoma he was hospitalized for further treatment. Biochemical analysis showed normal values of PTH 47.2 and Ca 2:28. The thoracic CT was taken: a number of changes in the lung parenchyma nodosum especially basal duplex were noticed. Static scintigraphy with Tc99m MDP showed a pathological accumulation of radiopharmaceuticals in the spinal rib annex IV of the right ribs, vertebrae from L II, and the lower branch of the left buttock bone. Neck ultrasound revealed right thyroid lobe measuring 4.1x 4.5x4.3 cm, and the whole contour of the back, below the edge of the clavicle creating a larger formation with hypoechoic areas and calcifications, compressing and pu-

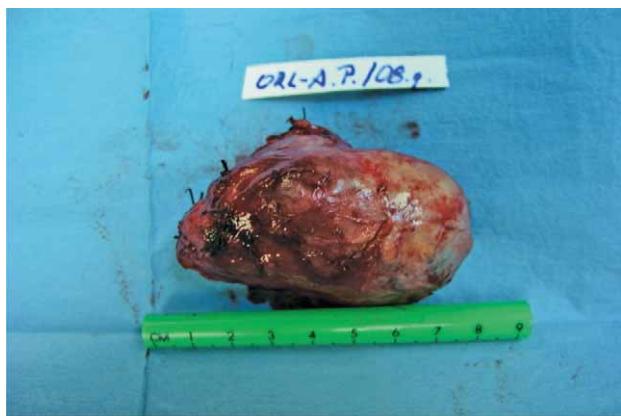

Fig. 1. *En bloc resection non-functional parathyroid carcinoma.*

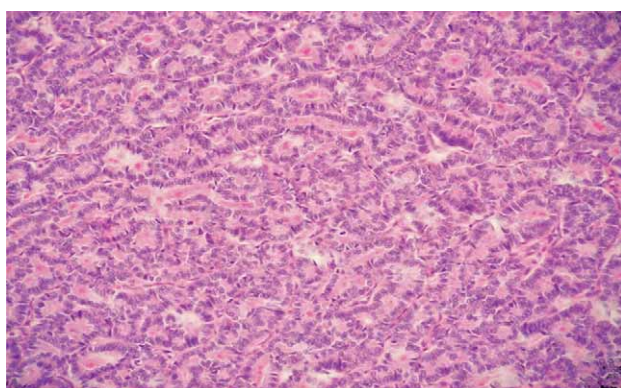


Fig. 2. *Histological appearance tumors trabeculae and small follicle (hemalaun, eosin x 200).*

shing the right lobe, measuring 7.6x4.5x4.3 cm. Cytologic puncture made the formation of the right thyroid lobe – adenocarcinoma, dif.dg. parathyroideae carcinoma. Scintigraphy of the neck and thorax with Tc99m MIBI showed: multiple focal abnormal deposits of activities along the right neck region II-IV with persistent focal retention of radiopharmaceuticals in the field of large expansive lesion in the projected reservoir of the right thyroid lobe. In 2008 the patient underwent right-sided lobectomy and isthmectomy in general endotracheal anesthesia with the extirpation of the tumorous lesion. Tumorous mass of 8x4 cm on the right side of the neck was removed (Figure 1). Histopathological analysis showed parathyroid gland carcinoma with metastases in the lymph nodes of the neck (the tumor cells, and NSE positive thyroglobulin and calcitonin and chromogranin A neurofilaments negative) (Figure 2). Postoperatively it has been done 3 cycles of chemotherapy at the discretion of Oncology Consultations, and has not been implemented radiation therapy. Postoperative values of PTH and Ca were within normal limits. After one year, in 2009,

due to recurrent disease the patient underwent modified radical neck dissection type I. In March 2011, he made the PET CT: pathological accumulation of radiopharmaceuticals in spinal rib annex IV of the right ribs, vertebrae from L II, and the lower branch of the left buttock bone.

After 54 months follow up the patient is alive and in good general condition.

Discussion

Parathyroid carcinoma is a malignant tumor that often originates from malignant alteration of parathyroid adenoma. In 15% of cases it occurs in hyperparathyroidism- jaw tumor (HPT-JT) syndrome^{3,17-19}. It has been published in several studies which have been observed to occur more frequently in patients who had received radiation in the head and neck²⁰⁻²². Most of these tumors secrete elevated parathyroid hormone (PTH), so 1% of cases of primary hyperparathyroidism is caused by parathyroid carcinoma^{1,2}, in which case it is a hyperfunctional parathyroid carcinoma, which accounts about 90% of parathyroid carcinomas. Hyperfunctional cancer is most often manifested by hypercalcemia, elevated PTH, nephrolithiasis, depression and memory problems. Due to the rare occurrence of this illness experience and healing treatments are quite limited. In 1973 Shantz and Castelman have set histological criteria for the diagnosis of parathyroid carcinoma, which are still valid¹³. They include: sheets or lobules of tumor cells separated by dense fibrous bands, mitotic figures, necrosis, capsular invasion, or vascular invasion. There are no classic microscopic criteria to distinguish dysfunctional from hyperfunctional cancer, the diagnosis should be based on the existence of histological criteria and biochemical analysis which shows elevated serum levels of PTH and calcium. Treatment of hyperfunctional and nonfunctional parathyroid carcinoma is primarily surgical, en block resection of the tumor with removal of invalid structure. In the literature there was a debate about the effectiveness of adjuvant therapy. Based on three recent studies¹⁴⁻¹⁶, it was suggested that adjuvant RT can reduce the return of the cancer after surgical removal. I still doubt the effectiveness of chemotherapy, since there is a small number of cases, the systematic monitoring has not been reported in the literature.

Conclusion

Non-functional parathyroid carcinoma is a rare malignant tumor of the head and neck that often manifests as a palpable mass in the neck, without any other distractions. Treatment consists of en block resection of tumor, with postoperative adjuvant RT in order to prevent recurrence.

REFERENCES

1. SHANE E, BILEZIKIAN J, *Endocr Rev*, 3 (1982) 218. — 2. SHANE E, BILEZIKIAN J, Parathyroid carcinoma. In: WILLIAMS CJ, GREEN MR, Raghaven D (Eds) *Textbook of uncommon cancer*, Wiley&Sons, New York, pp 1987; 763–771. — 3. SHANE E, *J. Clin. Metab*, 86 (2001) 485. — 4. HUNDHAL SA, FLEMING ID, FREMGEN AM, AT ALL, *Cancer*, 86 (1999) 538. — 5. BENJAMIN J, WILKINS JS, LEWIS JR, *Head and Neck pathol*, 3 (2009) 140. — 6. FERNANDEZ-RANVIER GG, JENSEN K, KHANAFSHAR E, *Endoc. pract*, 13 (2007) 750. — 7. MERLANO M, CONTE P, SCARSI P ET AL, *Tumori*, 71 (1985) 193. — 8. YAMASHITA H, NOGUCHI S, MURAKAMI N ET AL, *Acta pathol, Jpn* 42 (1992) 279. — 9. MURPHY MN, GLENNON PG, DIOCEE MS, ET AL, *Cancer*, 58 (1986) 2468. — 10. KIRKBY-BOTT J, LEWIS P, HARMER CL, *Eur J Oncol*, 31 (2005) 78. — 11. COLLINS FD, WARREN MC, PALMER FJ, *J surg Oncol*, 31 (1986) 60. — 12. CHAHINIAN AP, HOLLAND JF, NIEBURGS HE, *Am J Med sci*, 282 (1981) 80. — 13. SCHANTZ A, CASTELMAN B, *Cancer*, 31 (1973) 600. — 14. MUNSON ND, FOOTE RL, NORTH CUTT RC, *Cancer*, 98 (2003) 2378. — 15. CHOW E, TSANG RW, BRIERLEY JD, *Int J Radiat Oncol Biol Phys*, 41 (1998) 569. — 16. BU-SAYDY NL, JIMENEZ C, HABRA MA, *Head Neck*, 26 (2004) 716. — 17. DINNEN JS, GREENWOOD RH, JONES JH, *J Clin. Pathol*, 30 (1977) 966. — 18. HAVEN CJ, WONG FK, VAN DAM EW, *J. Clin. Endocrinol. Metab*, 85 (2000) 1449. — 19. HOBBS MR, POLE AR, PIDWIRNY GN, *Am J Hum Genet*, (1999) 518. — 20. CHRISTMAS TH, CHAPPLE CR, NOBLE JG, *Br J Surge* 75 (1988) 873. — 21. MASHBURN MA, CHONKICH GD, CHASE DR, *Laryngoscope*, 97 (1987) 215. — 22. IRELAND J, FLEMING S, LEVISON D, *J Clinic Pathol*, 38 (1985) 1114.

D. Birtić

»J. J. Strossmayer« University, Osijek University Hospital Centre, Department of Otorhinolaryngology, Head and Neck Surgery, 31 000 Osijek, Croatia
e-mail: darijabirtic@yahoo.com

NEFUNKCIONALNI KARCINOM PARATIROIDNE ŽLIJEZDE, RIJETKI TUMOR VRATA – PRIKAZ SLUČAJA

SAŽETAK

Karcinom paratiroidne žlijezde je vrlo rijedak tumor vrata. Najveći broj se otkrije slučajno (intraoperativno tijekom odstranjenja adenoma). Oko 1% svih slučajeva primarnog hiperparatiroidizma je uzrokovano karcinomom. U literaturi su objavljena 24 slučaja ove bolesti. Cilj studije je prezentirati slučaj ove bolesti uz osvrt na objavljenu literaturu o ovoj temi.