

Nuclear Translocation of ATBF1 Is a Potential Prognostic Marker for Skin Cancer

Eiichi Nishio¹, Yutaka Miura², Makoto Kawaguchi³, Akimichi Morita¹

¹Department of Geriatric and Environmental Dermatology, ²Department of Molecular Neurobiology, Nagoya City University Graduate School of Medical Sciences, Nagoya;

³Department of Pathology, Niigata Rosai Hospital, Niigata, Japan

Corresponding author:

Akimichi Morita, MD, PhD

Department of Geriatric and Environmental Dermatology

Nagoya City University Graduate School of Medical Sciences

1-Kawasumi,

Mizuho-cho, Mizuho-ku

Nagoya 467-8601

Japan

amorita@med.nagoya-cu.ac.jp

Received: June 20, 2011

Accepted: October 4, 2012

SUMMARY The AT motif binding factor 1 (ATBF1) is expressed in various tissues, such as brain, liver, lung, and gastrointestinal tract, and has an important role in cell differentiation in organs. ATBF1 interacts with PIAS3, a protein inhibitor for activated signal transducer and activator of transcription (STAT3), to suppress STAT3 signaling, which has critical roles in cell proliferation, migration, and survival. We hypothesized that ATBF1 is a useful prognostic marker for skin cancer. We performed immunohistochemical analyses of squamous cell carcinoma (SCC, n=7), basal cell carcinoma (BCC, n=4), and Bowen's disease (n=4) tissues using an anti-ATBF1 monoclonal antibody. All cases of BCC and Bowen's disease exhibited intense nuclear ATBF1 staining, whereas only some SCC cases exhibited weakly positive nuclear ATBF1 staining. SCC and Bowen's disease showed intense nuclear STAT3 staining, while BCC had few STAT3-positive nuclei. Based on these observations, nuclear ATBF1 staining was associated with low malignancy profiles. The pattern of ATBF1 staining is a potential prognostic marker for skin cancer.

KEY WORDS: ATBF 1, basal cell carcinoma, Bowen's disease, squamous cell carcinoma

INTRODUCTION

The AT motif binding factor 1 (ATBF1, also known as ZFH3), which is expressed in various tissues, such as brain, liver, lung, and gastrointestinal tract, has an important role in cell differentiation (1-4). The *ATBF1* complementary DNA was originally isolated from human hepatoma cells based on the ability of its product to bind to an AT-rich element in the enhancer of the human α -fetoprotein (*AFP*) gene (4). The gene is

located at chromosome 16q22.3-q23.1, which shows a loss of heterozygosity in various malignant tumors (5-7). ATBF1 mRNA is abundant in normal prostate, but scarce in approximately half of the prostate cancers tested (8). In 24 of 66 (36%) prostate cancers examined, 22 unique somatic mutations, many of which impair ATBF1 function, were detected (8). ATBF1 inhibits cell proliferation, thus the loss of ATBF1 func-



tion might be a mechanism through which growth control is lost in prostate cancer (8).

Full-length ATBF1 complementary DNA, containing 23 zinc finger motifs, was isolated in 1995 (9). It is referred to as ATBF1-A (404-kDa, 4 homeodomains, and 23 zinc finger motifs) and is 3.3 kb longer than the previously reported clone, now identified as ATBF1-B (306 kDa, 4 homeodomains, and 17 zinc finger motifs). ATBF1-A suppresses AFP gene expression. The absence of ATBF1-A is a distinct feature of AFP-producing gastric cancer cells, which are characterized by extremely high malignancy (3). In 81 sporadic gastric cancers, loss of heterozygosity at the *ATBF1* locus was detected in 52.9% of informative samples (10). In breast cancer, levels of ATBF1-A mRNA might serve as a predictive indicator of lymph node metastasis because a higher level of ATBF1-A is related to a better prognosis. Therefore, *ATBF1-A* gene expression might be a marker of endocrine responsiveness and a prognostic indicator for breast cancer progression (11). In breast cancer cells, estrogen receptor signaling promotes cell growth and proliferation. ATBF-1 inhibits estrogen receptor function by competing with the steroid receptor coactivator AIB1 to bind to the estrogen receptor in estrogen receptor-positive breast cancer cells. These findings provide an underlying mechanism for the suppression of breast cancer cell proliferation by ATBF1 (12).

Based on the studies using a yeast two-hybrid system, Nojiri *et al.* report that ATBF1 was a negative regulatory factor for signal transducer and activator of transcription (STAT)3-mediated signal transduction through its interaction with PIAS3, an activated STAT3 protein inhibitor (13). STAT3 is an important transcription factor for the development of psoriasis and skin cancers under some conditions (14,15). We hypothesized that ATBF1 expression is related to pathologic differences among skin cancers. Therefore, in the present study we investigated the staining patterns and intensity of ATBF1 and STAT3 in squamous cell carcinoma (SCC), Bowen's disease, and basal cell carcinoma (BCC) using specific monoclonal antibodies.

MATERIALS AND METHODS

Patients and tumor samples

Fifteen skin carcinoma tissues from SCC (n= 7), BCC (n = 4), and Bowen's disease (Bowen, n=4) were used in this study. All tissues were obtained by excision or biopsy from 12 patients (10 men and 2 women; 7 SCC, 4 BCC, and 4 Bowen patients, including 2 cases of double or triple cancer) at the Dermatology Clinic, Nagoya Midori Municipal Hospital, Nagoya,

Japan, from April 2004 to March 2008. A written informed consent was obtained from all patients under institutional approval.

Immunohistochemical staining of ATBF1-A protein

R87-5 rat monoclonal IgG anti-human ATBF1-A antibody (MBL, Nagoya, Japan) and an Ultrateck HRP (DAB) Streptavidin-Biotin Detection System (Beckman Coulter, Marseille, France) were used. Anti-human ATBF1-A antibody was diluted 4000 times (0.68 µg/mL). Tissue sections were deparaffinized and rehydrated. All sections were treated with 3% hydrogen peroxide in water to block endogenous peroxidase activity, and a protein-blocking agent (Beckman Coulter) was used. The slides were incubated with anti-human ATBF1-A antibody for 60 min at room temperature. Immunoreactive products were detected using the streptavidin-biotin system according to the manufacturer's instructions, then visualized after adding 3,3'-diaminobenzidine (DAB) as the chromogen. Tissue sections were counterstained with hematoxylin.

Immunohistochemical staining of STAT-3 and proliferating cell nuclear antigen

Mouse monoclonal IgG anti-human STAT-3 antibody (Santa Cruz Biotechnology, Santa Cruz, CA, USA), mouse monoclonal IgG anti-human proliferating cell nuclear antigen (PCNA; clone PC10, Dako Cytomation, Glostrup, Denmark), a Histofine SAB-PO kit (Nitirei Bioscience, Tokyo, Japan), and DAB (Dako Japan, Kyoto, Japan) were used. Anti-human STAT-3 antibody was diluted 100 times (2.00 µg/mL) and anti-human PCNA antibody was diluted 400 times (1.31 µg/mL). Tissue sections were deparaffinized and rehydrated and boiled in citrate-buffered saline (pH=6.0; Mitsubishi Kagaku Iatron, Tokyo, Japan) to improve staining. All sections were treated for 30 min with methanol containing 3% hydrogen peroxide to block endogenous peroxidase activity, and 10% goat serum to block proteins. The slides were incubated with anti-human STAT-3 antibody or anti-human PCNA antibody for 60 min at room temperature. Immunoreactive products were detected using the streptavidin-biotin system according to the manufacturer's instructions, then visualized using DAB as the chromogen. Tissue sections were counterstained with hematoxylin.

Evaluation of staining intensity

Staining was observed under an Olympus AX80T microscope (Olympus, Tokyo, Japan) and an Olympus

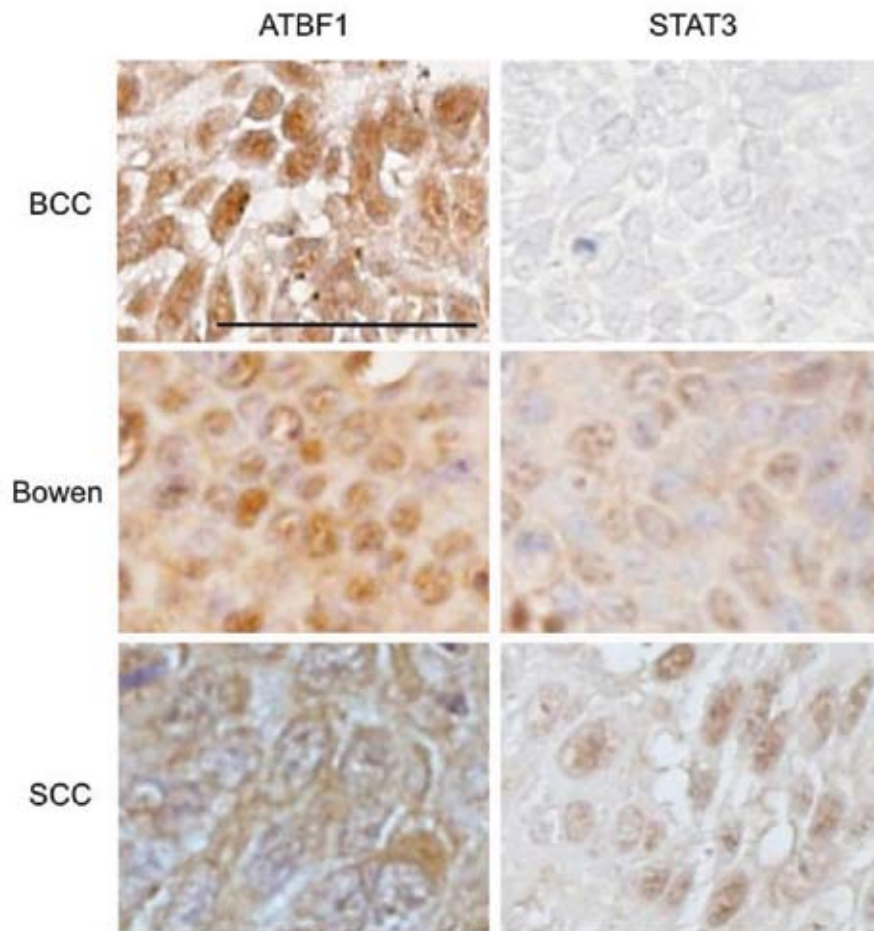


Figure 1. Representative ATBF1 and STAT3 staining patterns. Tissue sections of basal cell carcinoma (BCC), Bowen's disease, and squamous cell carcinoma (SCC) were stained with anti-human ATBF1-A antibody and anti-human STAT-3 antibody. Immunoreactive products were detected using the streptavidin-biotin system and visualized with DAB. Bar indicates 50 µm. Intensive nuclear staining of ATBF1 was observed in BCC and Bowen's disease, but not in SCC. STAT3 staining was not observed in BCC, but was observed in Bowen's disease. In SCC, cytoplasmic staining of ATBF1 was observed and nuclear STAT3 staining was profound.

DP70 color video camera (Olympus, Tokyo, Japan). Immunoreactivity of over 50% of the tumor lesion was defined as positive (+). Immunoreactivity of less than 50% was defined as indeterminate (\pm). A complete lack of immunoreactivity was defined as negative (-). Immunoreactivity was classified as nuclear, cytoplasmic, or both.

RESULTS

ATBF1 staining patterns, i.e., nuclear and cytoplasmic, and intensity were analyzed in BCC, Bowen's disease, and SCC. Representative staining patterns of BCC, Bowen's disease, and SCC are shown in Fig-

ure 1. In BCC, we observed intense nuclear staining of ATBF1, but no STAT3 staining. In Bowen's disease, we observed nuclear and cytoplasmic staining of ATBF1. The cytoplasmic staining was weaker than the nuclear staining. Nuclear STAT3 staining was also observed. In SCC, we observed cytoplasmic staining of ATBF1 and strong nuclear staining of STAT3, as previously reported (14,15). The nuclear staining of ATBF1 occurred in low malignancy cancers such as BCC and Bowen's disease.

The staining patterns in all tested samples are summarized in Table 1 and shown in Figure 2. All



Table 1.	ATBF1, STAT3, and PCNA staining in different skin cancer groups			
	ATBF1 (cytoplasm stain)	ATBF1 (nuclear stain)	STAT3 (nuclear stain)	PCNA (nuclear stain)
BCC1	-	+	-	+
BCC2	±	+	-	+
BCC3	±	+	-	+
BCC4	-	+	-	+
SCC1	-	±	+	+
SCC2	+	±	+	+
SCC3	+	+	+	+
SCC4	+	±	+	+
SCC5	+	±	+	+
SCC6	+	±	+	+
SCC7	±	+	+	+
Bowen1	±	+	+	+
Bowen2	±	+	-	+
Bowen3	±	+	+	+
Bowen4	±	+	+	+

+ = staining over 50%

± = staining under 50%

- = non staining

4 cases of BCC and all 4 cases of Bowen's disease showed nuclear ATBF1 staining (Fig. 2A, 2B). The Bowen's disease samples also had weak cytoplasmic ATBF1 staining. In contrast, 6 of 7 SCC cases showed cytoplasmic ATBF1 staining, and 5 of 7 SCC cases had weakly positive nuclear ATBF1 staining (Fig. 2C). In other cases (2 of 7 SCC), ATBF1 staining was similar to that of Bowen's disease, with both nuclear and cytoplasmic staining (Fig. 2C, bottom). Normal skin showed no nuclear ATBF1 staining, but cytoplasmic staining was observed (data not shown).

The 4 BCC cases had no STAT3-positive nuclei (Fig. 2A). Among the 4 Bowen's disease cases, 3 had nuclear STAT3 staining (Fig. 2B). The SCC cases had intense STAT3 nuclear staining, especially at the growing edges of the tumor (Fig. 2C). Almost all of the BCC, SCC, and Bowen's disease tumors were positive for anti-PCNA (Fig. 2A, B, C).

These observations suggest that nuclear ATBF1 staining is associated with low malignancy profiles.

DISCUSSION

Intense nuclear ATBF1 staining was observed in all cases of BCC and Bowen's disease, whereas only weakly positive nuclear ATBF1 staining was observed in some SCC cases. In contrast, intense STAT3 nuclear staining was observed in SCC, especially at the growing edges of the tumor, while few STAT3-positive nuclei were observed in BCC. These findings indicate that ATBF1 is a potential prognostic marker for skin cancer. In particular, nuclear staining of ATBF1 indicates low biologic malignancy.

Liu *et al.* (15) report STAT3 activation *via* p-STAT3 nuclear translocation in cutaneous SCC. In their study, cytoplasmic distribution and nuclear translocation of STAT3 were observed in either normal (62.5%; 5/8) tissues or tissues with various neoplastic changes. In normal epidermis, only the cells located in the basal layer were p-STAT3 positive, whereas p-STAT3 positive cells were distributed diffusely in the tumor tissue, especially in SCC. Because normal basal cells continuously regenerate to replace aged epithelial cells and

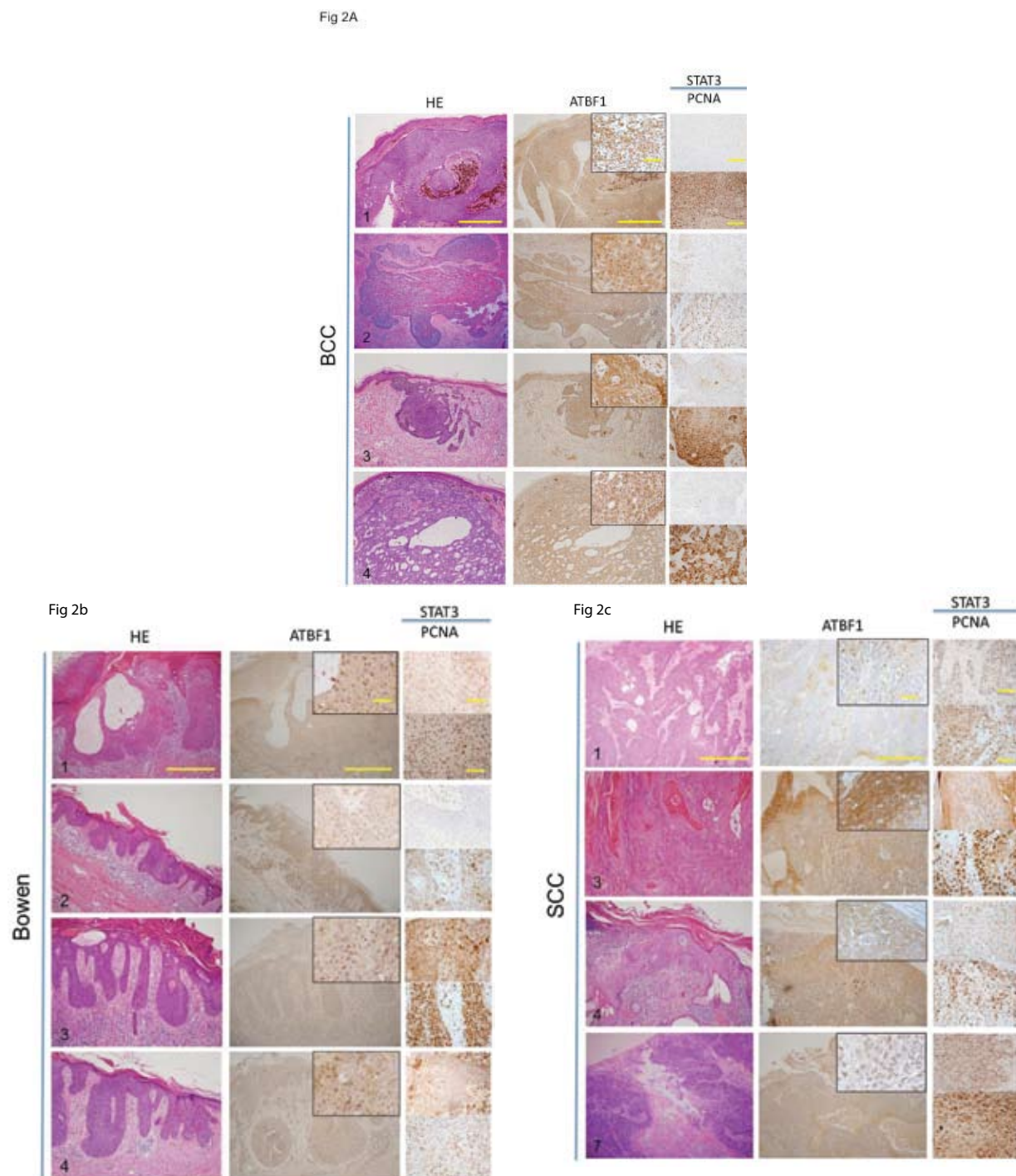


Figure 2. Immunohistochemical staining of ATBF1, STAT3, and PCNA: (A) basal cell carcinoma (BCC); (B) Bowen's disease; (C) squamous cell carcinoma (SCC). All test samples are shown except for 4 of 7 SCC. The case number corresponds to the case number in Table 1. The bar in the lower magnification panels indicates 500 μ m and that in the higher magnification panels indicates 100 μ m for the STAT3 and PCNA panels and 50 μ m for the ATBF1 panel. In BCC (A), the staining pattern was similar in all cases. Intensive nuclear staining of ATBF1 was observed in all 4 cases of BCC. No STAT3-positive nuclei were observed in any of the 4 BCC cases. In Bowen's disease (B), intensive nuclear staining of ATBF1 was observed in all cases. STAT3 nuclear staining was observed in 3 of the 4 cases of Bowen's disease. In SCC (C), cytoplasmic staining was observed in 6 of 7 SCC cases (#3, #4, #7 in this figure), whereas positive nuclear ATBF1 staining was observed in 5 of 7 SCC cases (#1, #3, #4, #7 in this figure). STAT3 nuclear staining was observed in all cases.

STAT3 is required for the survival and proliferation of skin cancers, restricted amounts of p-STAT3 in regenerative normal basal cells and diffuse p-STAT3 in epidermal cancer tissues are not unexpected findings.

ATBF1 is highly expressed in psoriatic skin lesions, especially in the squamous to granular layers, but not in the basal layer (unpublished data). STAT3 is strongly expressed in the cytoplasm in the basal layer and expression gradually decreases in the squamous layer, but, like ATBF1, the activated form is found in the nucleus. Thus, the ATBF1 expression pattern indicates that STAT3 activation is suppressed in psoriatic skin lesions. Nuclear ATBF1 staining was observed in BCC and Bowen's disease, whereas only weak ATBF1 nuclear staining was observed in some SCC. In contrast, nuclear STAT3 staining was observed in SCC. These findings indicate that ATBF1 expression suppresses STAT3 activation in BCC and Bowen's disease, and is associated with low malignancy profiles.

Heat shock proteins (HSP) have also been analyzed as skin cancer markers. Western blot and immunohistochemical staining studies revealed overexpression of HSP105 in extramammary Paget disease and SCC, and minimal expression in BCC (16). Immunohistochemistry analysis indicated that 56% of extramammary Paget disease, 60% of primary SCC, and 100% of metastatic SCC highly expressed HSP105, while only 13% of BCC lesions showed increased HSP105 expression.

HSP27 is member of the small HSP family. In a previous study of 10 BCC, 6 SCC, and 8 Bowen's disease, the HSP27 expression pattern was similar in all of the specimens tested (17). In solid BCC, there was no difference in the HSP27 expression pattern between the peripheral and central cells of the tumor mass. In differentiating BCC, however, positively staining cells in the central parts of the tumor were observed. In SCC tumors, HSP27 was weakly expressed or undetectable. A low level of HSP27 expression was detected in the more highly differentiated parts. No immunoreactivity was detected in the areas of invasion. In Bowen's disease, HSP27 was detected in the upper cell layers in the areas of lesions, where normal stratification seems to be conserved. Atypical cells of Bowen's disease did not express HSP27, and infiltrating cells in carcinoma arising from Bowen's disease were negative.

CONCLUSION

Based on the findings of the present study, ATBF1 is a potential prognostic marker for skin cancer. Further studies are necessary, however, to examine the relation of ATBF1 with other factors, including tumor stage and size, and clinical prognosis.

References

1. Ishii Y, Kawaguchi M, Takagawa K, Oya T, Nogami S, Tamura A, *et al.* ATBF1-A protein, but not ATBF1-B, is preferentially expressed in developing rat brain. *J Comp Neurol* 2003;465:57-71.
2. Miura Y, Kataoka H, Joh T, Tada T, Asai K, Nakanishi M, *et al.* Susceptibility to killer T cells of gastric cancer cells enhanced by mitomycin-C involves induction of ATBF1 and activation of p21 (Waf1/Cip1) promoter. *Microbiol Immunol* 2004;48:137-45.
3. Kataoka H, Miura Y, Joh T, Seno K, Tada T, Tamaoki T, *et al.* Alpha-fetoprotein producing gastric cancer lacks transcription factor ATBF1. *Oncogene* 2001;20:869-73.
4. Morinaga T, Yasuda H, Hashimoto T, Higashio K, Tamaoki T. A human alpha-fetoprotein enhancer-binding protein, ATBF1, contains four homeodomains and seventeen zinc fingers. *Mol Cell Biol* 1991;11:6041-9.
5. Yamada K, Miura Y, Scheidl T, Yoshida MC, Tamaoki T. Assignment of the human ATBF1 transcription factor gene to chromosome 16q22.3-q23.1. *Genomics* 1995;29:552-3.
6. Kai K, Zhang Z, Yamashita H, Yamamoto Y, Miura Y, Iwase H. Loss of heterozygosity at the ATBF1-A locus located in the 16q22 minimal region in breast cancer. *BMC Cancer* 2008;8:262.
7. Lange EM, Beebe-Dimmer JL, Ray AM, Zuhlke KA, Ellis J, Wang Y, *et al.* Genome-wide linkage scan for prostate cancer susceptibility from the University of Michigan Prostate Cancer Genetics Project: suggestive evidence for linkage at 16q23. *Prostate* 2009;69:385-91.
8. Sun X, Frierson HF, Chen C, Li C, Ran Q, Otto KB, *et al.* Frequent somatic mutations of the transcription factor ATBF1 in human prostate cancer. *Nat Genet* 2005;37:407-12. Erratum in: *Nat Genet* 2005;37:652.
9. Miura Y, Tam T, Ido A, Morinaga T, Miki T, Hashimoto T, *et al.* Cloning and characterization of an ATBF1 isoform that expresses in a neuronal differentiation-dependent manner. *J Biol Chem* 1995;270:26840-8.
10. Cho YG, Song JH, Kim CJ, Lee YS, Kim SY, Nam SW, *et al.* Genetic alterations of the ATBF1 gene in gastric cancer. *Clin Cancer Res* 2007;13:4355-9.
11. Zhang Z, Yamashita H, Toyama T, Sugiura H, Ando Y, Mita K, *et al.* ATBF1-a messenger RNA expression is correlated with better prognosis in breast cancer. *Clin Cancer Res* 2005;11:193-8.

12. Dong X-Y, Sun X, Guo P, Li Q, Sasahara M, Ishii Y, *et al.* ATBF1 inhibits estrogen receptor (ER) function by selectively competing with AIB1 for binding to ER in ER-positive breast cancer cells. *J Biol Chem* 2010;285:32801-9.
13. Nojiri S, Joh T, Miura Y, Sakata N, Nomura T, Nakao H, *et al.* ATBF1 enhances the suppression of STAT3 signaling by interaction with PIAS3. *Biochem Biophys Res Commun* 2004;314:97-103.
14. Sano S, Chan KS, Carbajal S, Clifford J, Peavey M, Kiguchi K, *et al.* Stat3 links activated keratinocytes and immunocytes required for development of psoriasis in a novel transgenic mouse model. *Nat Med* 2005;11:43-9.
15. Liu ZL, Li Y, Kong QY, Zhan C, Wang Q, Chen XY, *et al.* Immunohistochemical profiling of Wnt, NF-kappaB, Stat3 and Notch signaling in human epidermal tumors. *J Dermatol Sci* 2008;52:133-6.
16. Muchemwa FC, Nakatsura T, Ihn H, Kageshita T. Heat shock protein 105 is overexpressed in squamous cell carcinoma and extramammary Paget disease but not in basal cell carcinoma. *Br J Dermatol* 2006;155:582-5.
17. Trautinger F, Kindas-Mügge I, Dekrout B, Knobler RM, Metze D. Expression of the 27-kDa heat shock protein in human epidermis and in epidermal neoplasms: an immunohistological study. *Br J Dermatol* 1995;133:194-202.



Illustration from the Svijet magazine; year 1929.
(from the collection of Mr. Zlatko Puntijar)