

## Prikaz slučaja / Case report

## Zamke u evaluaciji težine mitralne regurgitacije

*Pitfalls in evaluation of mitral regurgitation severity*

Nikša Drinković Jr., Vlatka Rešković Lukšić, Kristina Marić Bešić, Nikša Drinković\*

Klinički bolnički centar Zagreb, Zagreb, Hrvatska  
University Hospital Centre Zagreb, Zagreb, Croatia

**SAŽETAK:** Težina mitralne regurgitacije (MR) s multiple regurgitirajućim mlazovima često se podcjeni standardnom transtorakalnom ehokardiografskom (TTE) pretragom, jer se svi mlazovi ne otkriju. Od svih Doppler metoda jedino je kvantitativno PW Doppler mjerenje primjenjivo u ovih bolesnika jer PISA nije točna, a vena contracta je primjenjiva samo kod jednog regurgitacijskog mlaza.

Prikazujemo 57-godišnjeg bolesnika s malim centralnim regurgitacijskim mlazom na TTE u kojeg smo učinili transezofagijskom ehokardiografijom (TEE) zbog smanjene tolerancije napora kod normalne funkcije lijeve klijetke, morfološki nepromijenjene mitralne valvule i normalnog nalaza koronarografije uz prisustvo glasnog apikalnog holosistolickog šuma. TEE je otkrio dva dodatna ekscentrična regurgitirajuća mlaza. Kvantitativnom PW Doppler metodom izračunan je regurgitacijski volumen od 55 ml i ERO 0.35 cm<sup>2</sup>, što odgovara srednje teškoj do teškoj MR.

Želimo naglasiti da se simptomi i fizikalni nalaz ne smiju zanemariti u postupku integrativne ultrazvučne procjene težine MR.

**KLJUČNE RIJEČI:** mitralna regurgitacija, ehokardiografija, Doppler, težina regurgitacije.

**SUMMARY:** The severity of mitral regurgitation (MR) with multiple regurgitant jets is often underestimated on standard transthoracic echocardiography (TTE) examination, since all jets are usually not appreciated. On the other hand, of all Doppler methods only quantitative PW Doppler measurement is applicable in these patients since PISA is not as accurate and vena contracta works well only for single jets.

We present a 57-year-old patient with small and narrow central jet on TTE in whom transesophageal echocardiography (TEE) was performed because of loud apical holosystolic murmur and low effort tolerance in the presence of normal left ventricular function, normal mitral valve and coronary artery anatomy. TEE disclosed two additional significant eccentric jets. Regurgitant volume of 55 ml/beat and ERO 0.35 cm<sup>2</sup> was calculated with quantitative PW Doppler method which corresponded to moderate to severe MR.

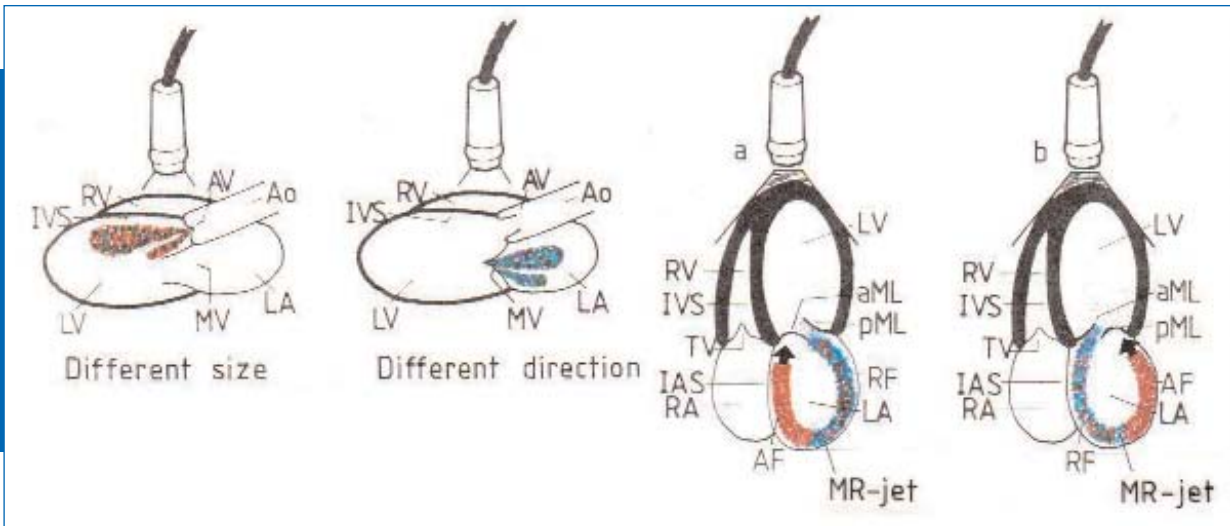
We stress again the importance of integrative approach in the assessment of MR severity, in which symptoms, physical examination and hemodynamic consequences of MR should not be neglected.

**KEYWORDS:** mitral regurgitation, echocardiography, Doppler, severity of regurgitation.

**CITATION:** *Cardiol Croat.* 2012;7(11-12):316-321.

Mitralna regurgitacija (MR) definirana je kao vraćanje krvi u lijevi atrij za vrijeme ventrikulske sistole. Za direktnu potvrdu postojanja ili odsustva MR treba učiniti Doppler ehokardiografiju. Pri tom se koristi obojani Doppler za brzi "scanning" prisustva ili odsustva MR i dostatna je pretraga za dijagnozu blage mitralne insuficijencije koju karakterizira mali uzak regurgitacijski mlaz. Mitralna regurgitacija se može prezentirati kao centralni mlaz, tada ju je najlakše prepoznati, a u procjeni težine regurgitacije primjenjive su sve doplerske metode. Međutim, regurgitacijski mlaz može biti ekscentričan kod prolapsa mitralnog zalistka i tu se ne može primjeniti metoda površine regurgitacijskog mlaza, PISA metoda je manje točna, a *vena contracta* funkcioniše dobro kao kod centralnog mlaza<sup>1,2</sup>. Osobit problem je prepoznavanje i procjena težine MR kod multiplih mlazova kada se težina MR često podcjeni (**Slika 1**).

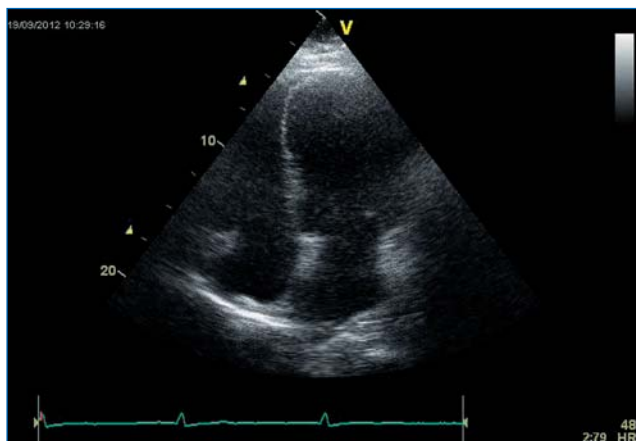
Mitral regurgitation (MR) is defined as the return of blood into the left atrium during ventricular systole. Doppler echocardiography has to be performed for direct confirmation of the existence or absence of MR. For this purpose, we use color Doppler for quick "scanning" for presence or absence of MR and it is a sufficient test for the diagnosis of mild mitral insufficiency, which is characterized by a narrow regurgitant jet. Mitral regurgitation can be presented as a central jet and then it is easiest to recognize, while all Doppler methods are applicable in the assessment of regurgitation severity. However, the regurgitant jet may be eccentric with mitral valve prolapse, and here the regurgitant jet area method cannot be applied, PISA method is less accurate while the *vena contracta* functions well as in the central jet<sup>1,2</sup>. A specific problem is the recognition and assessment of MR severity in multiple jets and where the MR severity is frequently underestimated (**Figure 1**).



**Figure 1.** Eccentric and multiple regurgitant jets of different size and direction (republished with permission from author — B. Jadonić).

### Prikaz slučaja

57-godišnji muškarac upućen je na transtorakalni ultrazvuk srca. Bolesnik se deset godina liječi zbog arterijske hipertenzije. Zadnjih 6 mjeseci ne podnosi umjerene napore zbog čega je učinjena koronarografija kojom je isključena okluzivna koronarna bolest. U 12-kanalnom EKG registrira se sinus ritam i hipertrofija lijevog atrija. Transtorakalnom ehokardiografijom (TTE) prikaže se morfološki nepromijenjen valvularni aparat srca, blago uvećanje lijevog atrija i lijevog ventrikula, čija je sistolička funkcija normalna (Slika 2). Primjenom obojanog Dopplera u apikalnom prikazu 4 srčane šupljine otkriva se mali i uzak centralni regurgitacijski mlaz koji upućuje na blagu MR (Slika 3).

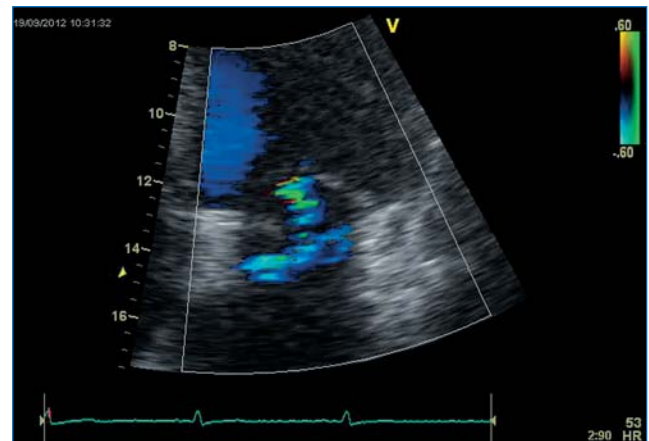


**Figure 2.** TTE apical four chamber view. Normal mitral valve and mild LA and LV enlargement.

Karakteristike blage MR potvrđuju se i u kontinuiranom (CW) Doppleru kao rijedak, nepotpun i paraboličan regurgitacijski mlaz (Slika 4). Međutim, relativno visok E val — 1.2 cm i mali A val uz smanjenu amplitudu sistoličkog protoka u plućnoj veni (Slika 5) prije ukazuje na značajnu MR nego na dijastoličku disfunkciju II. stupnja. Zbog toga, a u sklopu smanjene tolerancije napora uz dobru sistoličku funkciju LV te prisustva glasnog holosistoličkog šuma na iktusu,

### Case report

A 57-year old man was referred for transthoracic echocardiography. The patient had been treated for hypertension for ten years. In the last 6 months, the patient does not tolerate moderate efforts and therefore he underwent coronarography, which excluded occlusive coronary artery disease. The 12-lead ECG records sinus rhythm and left atrial hypertrophy. Transthoracic echocardiography (TTE) shows morphologically unchanged valvular heart apparatus, slight enlargement of the left atrium and the left ventricle, whose systolic function is normal (Figure 2). Color Doppler in the apical four chamber view reveals a small and narrow central regurgitant jet that indicates mild MR (Figure 3).



**Figure 3.** TTE apical four chamber view. Small central color jet indicating mild MR.

Characteristics of the mild MR are confirmed in the continuous (CW) Doppler as a soft density, incomplete and parabolic regurgitant jet (Figure 4). However, the relatively high E wave — 1.2 cm and a small A wave with reduced amplitude of the systolic flow in the pulmonary vein (Figure 5) rather indicates significant MR than the grade II diastolic dysfunction. Therefore, in the reduced effort tolerance with a good LV systolic function and the presence of loud holosystolic

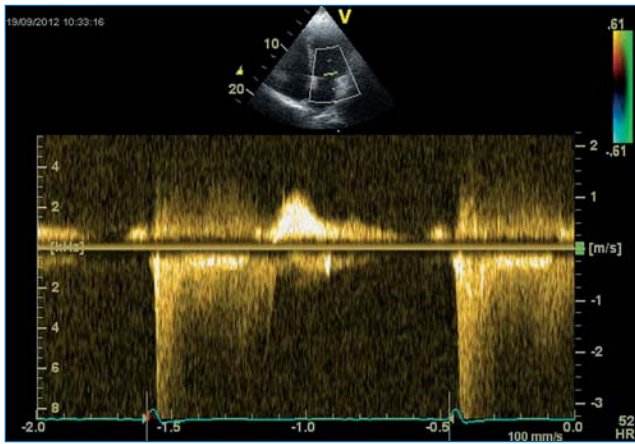


Figure 4. CW Doppler. Soft density, parabolic MR jet.

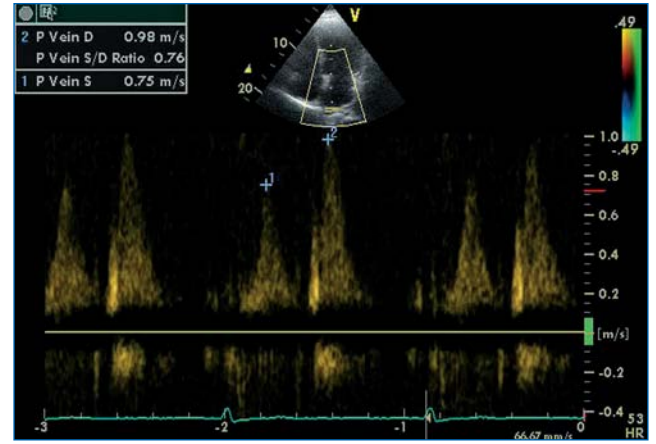


Figure 5. PW Doppler. Diminished systolic flow in pulmonary vein.

predpostavljamo da je MR značajna i indiciramo transezofagijsku ehokardiografiju (TEE). U četverekomornom srednje ezofagusnom (SE) presjeku 0 stupnjeva, mitralni zalistak izgleda normalno, a obojanim Dopplerom potvrđuje se postojanje malog centralnog mlaza blage MR (**Slika 6**). U 92 stupnjeva dvokomornom SE presjeku prepoznaje se sistolički prolaps A1 i otkriva drugi, značajni ekscentrični regurgitacijski mlaz (**Slika 7**). U 126 stupnjeva SE presjeku u dugoj osi prikazuje se sistolički prolaps A2 i treći značajni ekscentrični regurgitacijski mlaz (**Slika 8**).

apical murmur we presume that the MR is significant and we recommend transesophageal echocardiography (TEE). In the 0 degree midesophageal (ME) four chamber cross-sectional view, the mitral valve appears normal, and color Doppler confirms the existence of a small central jet of mild MR (**Figure 6**). Systolic prolapse A1 and another significant eccentric regurgitant jet are observed in ME two chamber view at 92 degrees (**Figure 7**). Systolic prolapse A2 and the third significant eccentric regurgitant jet are observed in ME long axis (LAX) view at 126 degrees (**Figure 8**).

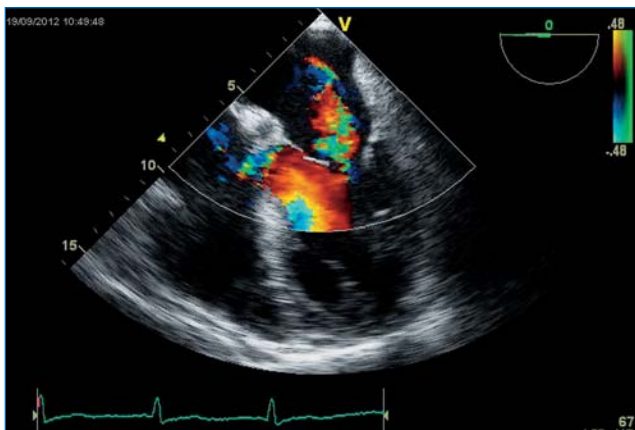

Figure 6. TEE 0° ME four chamber view. Small and narrow central MR jet.

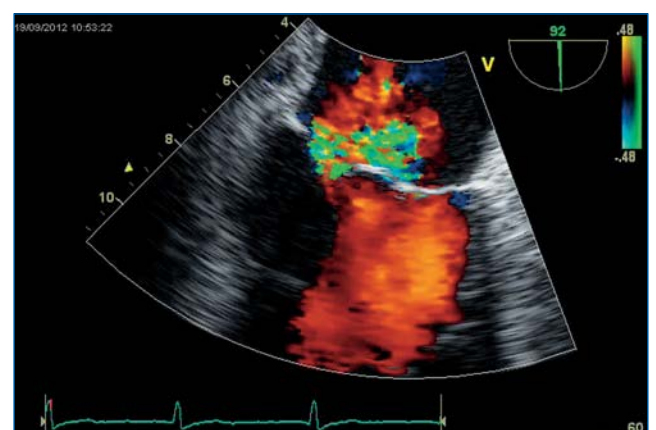


Figure 7. TEE 92° ME two chamber view. A1 segment prolaps and significant eccentric regurgitant jet.

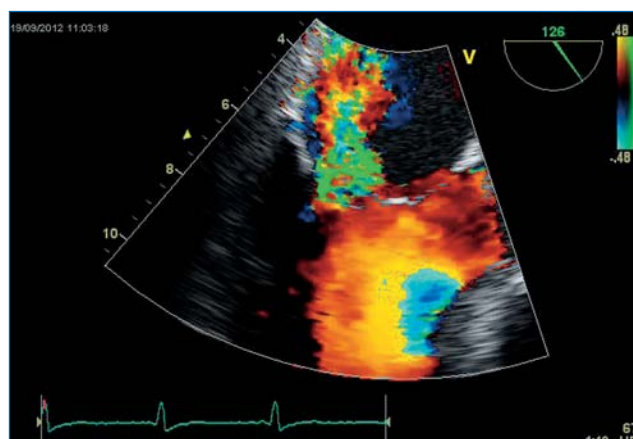
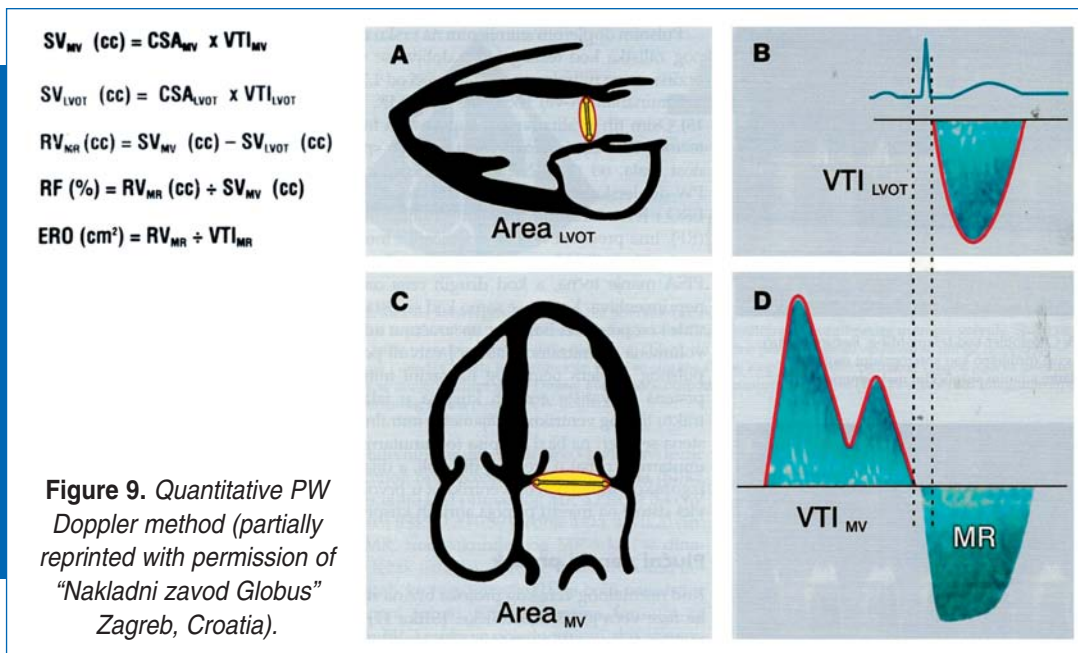


Figure 8. TEE 126° ME LAX view. A2 segment prolaps and second large eccentric jet.

U procjeni težine MR kod ovog bolesnika primjenjiva je jedino kvantitativna pulzirajuća (PW) Doppler metoda<sup>3</sup> (Slika 9). Izračunali smo regurgitacijski volumen od 55 ml po kontrakciji i efektivnu regurgitirajuću areju (ERO) 0.35 cm<sup>2</sup>, što ukazuje na srednje tešku do tešku MR. Metoda se bazira na izračunu udarnih volumena na mitralnoj i aortnoj valvuli, a koristi se samo kad su ostale valvule kompetentne. Dijametar mitralnog anulusa mjeri se na bazi kuspisa (od unutarnjeg do unutarnjeg ruba) u srednjoj dijastoli, a dijametar izlaznog trakta lijevog ventrikula u prvoj polovici sistole na mjestu pripoja aortnih kuspisa. PW Doppler se snima na opisanim mjestima mjerenja.

While assessing the MR severity for this patient, only the quantitative pulsed (PW) Doppler method<sup>3</sup> (Figure 9) is applicable. We have calculated the regurgitant volume of 55 ml/beat and effective regurgitant orifice (ERO) of 0.35 cm<sup>2</sup>, indicating moderate to severe MR. The method is based on the calculation of the stroke volumes on the mitral and aortic valve, which is only used when other valves are competent. Mitral annulus diameter is measured on the basis of cusps (from inner to the inner edge) in the mid diastole, while the diameter of the left ventricular outflow tract is measured in the first half of systole at the site of the aortic cusp attachment. PW Doppler is recorded in the above described measurement sites.



## Diskusija

Ehokardiografija s Dopplerom je metoda izbora u neinvazivnoj detekciji i evaluaciji težine i etiologije mitralne i drugih valvularnih regurgitacija.

U **Tablicama 1 i 2** prikazani su kvantitativni, semikvantitativni i kvalitativni ehokardiografski i Doppler parametri za procjenu težine MR.

## Discussion

Echocardiography with Doppler is the method of choice for the noninvasive detection and evaluation of the severity and etiology of mitral and other valvular regurgitations.

**Tables 1 and 2** show the quantitative, qualitative and semi-quantitative echocardiographic and Doppler parameters for the assessment of MR severity.

**Table 1.**  
Echocardiographic parameters in mild mitral regurgitation.

### Mild MR

- LA and LV size normal
- Mitral leaflets or support apparatus normal or abnormal
- Small central jet <4 cm<sup>2</sup> or <20% of LA area\*
- A-wave dominant mitral inflow (PW Doppler)
- Soft density, parabolic CW Doppler MR jet
- Systolic dominant flow in pulmonary veins (PW Doppler)
- Vena contracta width <0.3 cm
- No or minimal flow convergence radius (PISA) <0.4 cm\*\*
- EROA (cm<sup>2</sup>) <0.20; R Vol (ml/beat) <30

\* At a Nyquist limit of 50-60 cm/s

\*\* At a Nyquist limit of 40 cm/s

**Table 2.**  
*Echocardiographic parameters in severe and moderate mitral regurgitation.*

### Severe MR

Enlarged LA and LV size  
 Prominent flail mitral valve leaflet or ruptured papillary muscle  
 Large central jet  $>10 \text{ cm}^2$  or  $>40\%$  of LA area or variable size wall - impinging jet swirling in LA (eccentric jet)  
 E-wave dominant mitral inflow ( $E \geq 1.5 \text{ m/s}$ )  
 Dense, early peaking-triangular CW Doppler MR jet  
 TVI mitral/TVI aortic  $>1.4$   
 Systolic flow reversal in pulmonary veins (PW Doppler)  
 Vena contracta width  $\geq 0.7 \text{ cm}$   
 Large flow convergence radius (PISA)  $\geq 0.9 \text{ cm}$   
 EROA ( $\text{cm}^2$ )  $\geq 0.40$  Sec  $\geq 0,20$ ; R Vol ( $\text{ml/beat}$ )  $\geq 60$  Sec  $\geq 30$

### Moderate MR

Signs of MR  $>$ mild present, but no criteria for severe MR

Procjena težine MR uvijek se bazira na više varijabli. Primjenjuje se integrativni postupni pristup, a redosljed ehokardiografskih pretraga i mjerenja prikazan je u **Tablici 3.**

The assessment of MR severity is always based on several variables. Integrative gradual approach is applied, while the order of echocardiographic tests and measurements is shown in **Table 3.**

**Table 3.**  
*Integrative stepwise approach in assessment of mitral regurgitation severity.*

### Integrative stepwise approach

LA and LV size, mitral morphology - 2D echo  
 Mitral inflow, pulm. v. flow - PW Doppler  
 MR jet - CW Doppler  
 JRA and VC - Color flow Doppler  
 ↓ (if present)  
 Flow convergence radius (PISA)  
 ↓ (parameters contradictory)  
 Quantitative parameters  
 EROA, R Vol

Kvantitativne varijable ne računaju se ako do tada učinjena mjerenja uključujući PISA radijus, jedinstveno upućuju na blagu ili blagu do srednje tešku MR.

Međutim, težina MR s više mlazeva često se podcjeni TTE pretragom jer se svi mlazevi ne prepoznaju. Od svih Doppler metoda tada je primjenjiva samo kvantitativna PW Doppler metoda, jer PISA nije točna, a vena contracta se može koristiti samo kod jednog regurgitacijskog mlaza. Obzirom da se kod ovih bolesnika oslanjamo samo na jednu Doppler metodu, posebno važan dio u integrativnom pristupu procjene

Quantitative variables are not counted if the measurements performed so far including PISA radius universally indicate a mild or mild to moderate MR severity.

However, severity of the MR with several jets is often underestimated by TTE, because not all the jets are recognized. Of all Doppler methods, only quantitative PW Doppler method is applicable, because PISA is not accurate, while the vena contracta may be used only with one regurgitant jet. Given that in these patients we rely only on one Doppler method, symptoms, physical findings and hemodynamic consequences of MR are an especially important part of the

težine regurgitacije su tegobe, fizikalni nalaz i hemodinamske posljedice MR.

integrative approach in the assessment of the regurgitation severity.

Received: 2<sup>nd</sup> Nov 2012

\*Address for correspondence: Klinički bolnički centar Zagreb, Kišpatičeva 12,

HR-10000 Zagreb, Croatia

Phone: +385-1-2388-888

E-mail: [pimg@zg.t-com.hr](mailto:pimg@zg.t-com.hr)

## Literature

1. Drinković N, Jadonić B, Drinković N Jr. Evaluacija težine mitralne regurgitacije dvodimenzionalnom i doplerskom ehokardiografijom. U: Mirat J, Čorić V i sur. Bolesti srčanih zalistaka. Zagreb: Nakladni zavod Globus, 2011.
2. Agricola E, Oppizzi M, De Bonis M, Maisano F, Toracca L, Bove T, et al; American Society of Echocardiography. Multiplane transesophageal echocardiography performed according to the guidelines of the American Society of Echocardiography in patients with mitral valve prolapse, flail, and endocarditis: diagnostic accuracy in the identification of mitral regurgitant defects by correlation with surgical findings. *J Am Soc Echocardiogr.* 2003;16(1):61-6.
3. Reynolds T. Valvular regurgitation. In: Reynolds T, Kidd P. *The Echocardiographer's Pocket Reference*, Second Edition. 2000; Arizona Heart Institute, Phoenix.
4. Zoghbi WA, Enriquez-Sarano M, Foster E, Grayburn PA, Kraft CD, Levine RA, et al; American Society of Echocardiography. Recommendations for evaluation of the severity of native valvular regurgitation with two-dimensional and Doppler echocardiography. *J Am Soc Echocardiogr.* 2003;16(7):777-802.
5. Authors/Task Force Members, Vahanian A, Alfieri O, Andreotti F, Antunes MJ, Barón-Esquivias G, Baumgartner H, et al. Guidelines on the management of valvular heart disease (version 2012): The Joint Task Force on the Management of Valvular Heart Disease of the European Society of Cardiology (ESC) and the European Association for Cardio-Thoracic Surgery (EACTS). *Eur Heart J.* 2012;33(19):2451-96.



## 3<sup>rd</sup> DUBROVNIK CARDIOLOGY HIGHLIGHTS

AN ESC UPDATE PROGRAMME IN CARDIOLOGY

26/09 - 29/09/2013 | HOTEL EXCELSIOR | DUBROVNIK | CROATIA

DIRECTORS DAVOR MILIČIĆ | OTTO SMISETH  
CO DIRECTORS DAN GAITA | THIERRY GILBERT | ZLATKO FRAS

<http://www.dubrovnikcardiohighlights2013.org> <http://www.kardio.hr>

