

# Journal of Mind and Medical Sciences

Volume 4 | Issue 2

Article 16

2017

## Necrotizing fasciitis of the neck: case presentation

Emil Marginean

*University of Medicine and Pharmacy Oradea, Department of Otorhinolaryngology, Surgery and Neurosurgery, Oradea, Romania*

Ciprian Venter

*University of Medicine and Pharmacy Oradea, Department of Otorhinolaryngology, Surgery and Neurosurgery, Oradea, Romania*

Maria Domuta

*University of Medicine and Pharmacy Oradea, Department of Otorhinolaryngology, Surgery and Neurosurgery, Oradea, Romania*

Oana Valenas

*University of Medicine and Pharmacy Oradea, Department of Otorhinolaryngology, Surgery and Neurosurgery, Oradea, Romania*

Ildiko Sorban

*University of Medicine and Pharmacy Oradea, Department of Otorhinolaryngology, Surgery and Neurosurgery, Oradea, Romania*

*See next page for additional authors*

Follow this and additional works at: <http://scholar.valpo.edu/jmms>

 Part of the [Otolaryngology Commons](#), [Plastic Surgery Commons](#), and the [Surgery Commons](#)

### Recommended Citation

Marginean, Emil; Venter, Ciprian; Domuta, Maria; Valenas, Oana; Sorban, Ildiko; Pantis, Alina; Popescu, Bogdan; and Scăunașu, Razvan V. (2017) "Necrotizing fasciitis of the neck: case presentation," *Journal of Mind and Medical Sciences*: Vol. 4 : Iss. 2 , Article 16.  
DOI: 10.22543/7674.42.P198202

Available at: <http://scholar.valpo.edu/jmms/vol4/iss2/16>

This Case Presentation is brought to you for free and open access by ValpoScholar. It has been accepted for inclusion in Journal of Mind and Medical Sciences by an authorized administrator of ValpoScholar. For more information, please contact a ValpoScholar staff member at [scholar@valpo.edu](mailto:scholar@valpo.edu).

---

# Necrotizing fasciitis of the neck: case presentation

## **Authors**

Emil Marginean, Ciprian Venter, Maria Domuta, Oana Valenas, Ildiko Sorban, Alina Pantis, Bogdan Popescu, and Razvan V. Scăunașu

## *Case Report*

# **Necrotizing fasciitis of the neck: case presentation**

**Emil Marginean<sup>1</sup>, Ciprian Venter<sup>1</sup>, Maria Domuta<sup>1</sup>, Oana Valenas<sup>1</sup>, Ildiko Sorban<sup>1</sup>, Alina Pantis<sup>1</sup>, Bogdan Popescu<sup>2</sup>, Răzvan V. Scăunașu<sup>3</sup>**

<sup>1</sup>University of Medicine and Pharmacy Oradea, Department of Otorhinolaryngology, Surgery and Neurosurgery, Oradea, Romania

<sup>2</sup>Colțea Clinical Hospital, Department of Otorhinolaryngology, Bucharest, Romania

<sup>3</sup>Colțea Clinical Hospital, Department of General Surgery, Bucharest, Romania

### **Abstract**

Necrotizing fasciitis represents a severe and rare infectious disease, which is accompanied by extended necrosis of subcutaneous tissues and fascia layers, having as a result gangrene of the teguments. To reduce mortality associated with this disease, a rapid diagnosis is necessary as well as aggressive surgical treatment, accompanied by adequate, aggressive antibiotic therapy. As a rule, etiology is teeth related, with the condition more common in immunology-depressed patients.

This article presents the experience of the authors regarding a case presentation of necrotizing fasciitis with typical clinical expression and management of the disease in an immunological-depressed patient. Further data on diagnosis, microbiology, clinical manifestations, therapy principles, and prognosis are yet needed for atypical cases.

**Keywords:** cervical necrotizing fasciitis, infection, immunology, depressed patients



## Introduction

Necrotizing fasciitis represents an infection of bacterial origin, with low frequency, but capable of skin and soft tissue destruction, affecting even fascia that cover muscles and subcutaneous fat. Because of its extremely fast evolution, the main agent has been called “flesh eating” bacteria. *Streptococcus pyogenes* cause the occurrence and development of this rare but severe disease with the involvement of the subcutaneous fat tissue and thrombosis of the microvasculature (1).

In 30% of necrotizing fasciitis, fatalities are registered, even if the patients are completely healthy prior to the occurrence of the infection. Classification of the soft tissue necrotizing fasciitis takes into consideration the presence or absence of clostridium bacteria. However, the onset of the purulent collection is due to the polymicrobial association (2). The neck region is one of the anatomic regions with the highest number of anaerobic bacteria (3). Some studies have noted differences between skin and throat strains in their epidemiology and genetic makeup, thus resulting in different levels of virulence (4).

Individuals that are susceptible for developing such an infection are those:

- having a weakened immune system or not having the necessary antibodies to fight infection.
- affected by chronic diseases such as diabetes, cancer, liver or kidney diseases.
- with post-surgical wounds that are healing, such as episiotomy.
- recently affected by smallpox virus or other viral infections which produce cutaneous eruptions.
- using steroid medication causing an impairment of the immune system in fighting infections

However, the anatomical configuration represented by the fibrous attachments between subcutaneous tissues and fascia helps limit the spread of infection (5).

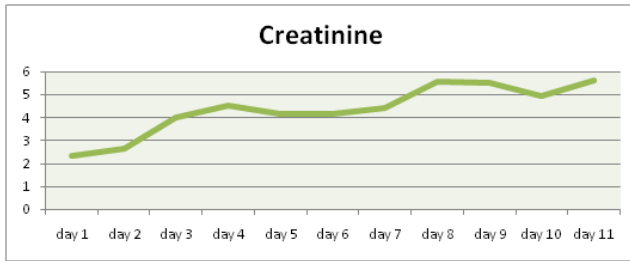
The authors present in this paper the case of a 60 year old woman with multiple morbidities, diagnosed with necrotizing fasciitis. Due to associated morbidities, the patient had a poor and rapid evolution towards death, this occurring on the 11<sup>th</sup> day of hospitalization.

## Case Report

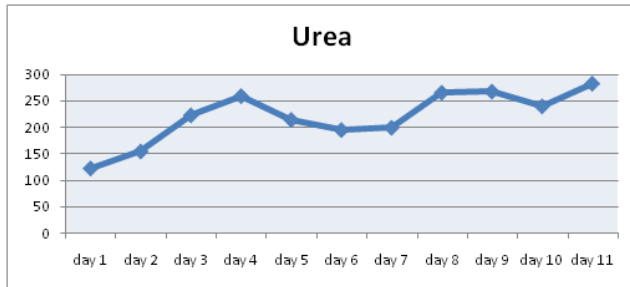
The 60 years old patient had a known personal pathological history: type II diabetes mellitus insulin dependent, chronic bronchitis with asthma, chronic heart disease, and peripheral polyneuropathy. She was admitted to our Otorhinolaryngology/ ENT Department, having been transferred from a city hospital 2 days after admission. She was suffering from: dysphagia, odynophagia, extended feverish syndrome, extended necrosis on the left lateral cervical region, and poor biological status.

ENT clinical examination revealed facial swelling extended to the left anterior and latero-cervical region and edema and congestion of the teguments with some cyanotic regions. The area was painful when touched, infiltrated and crumble, gaseous crepitation were present at palpation. Mouth and pharynx endoscopy was difficult to perform because of the trismus and the odontogenic infection located on the left side. The tongue seemed mobile and the sublingual region was painful with accompanying edema. Indirect laryngoscopy revealed edema of left hemilarynx with salivary stasis, a necrotic area in left piriform sinus which communicated with the left lateral cervical necrosis, with a fistula communicating with the exterior under formation.

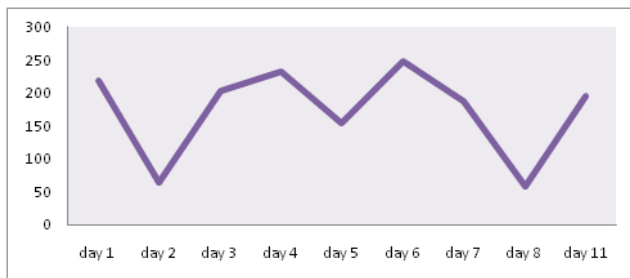
At admission the blood test revealed leukocytosis, along with kidney failure (creatinine: 2,31 mg/dl, urea: 121,98 mg/dl, creatinine clearance: 22 ml/min/1,73m<sup>2</sup> according to MDRD), as well as oscillatory modification of sugar levels (Figures 1, 2, 3).



**Figure 1.** The variation of the creatinine levels during hospitalization.



**Figure 2.** The variation of the urea levels during hospitalization.

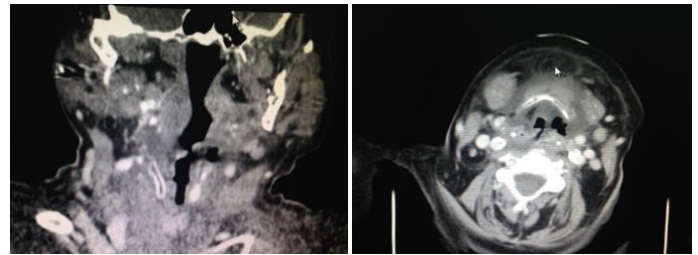


**Figure 3.** Nutrition and diabetes examination was performed to correct blood glucose levels (mg/dL).

Emergency surgical treatment was performed, multiple latero-cervical incisions being made on the left side and all necrotic areas were removed. Hydrogen peroxide and iodine solution were used to cleanse the area.

At admission the patient received broad spectrum antibiotic therapy consisting of Cefort 2x2g/day, Clindamycin 3x2g/day, and Metronidazole 2x1fl/day, rehydration, antipyretics, and treatment for diabetes mellitus, bronchitis, and heart disease, as a primary empiric therapy. Before antibiotherapy, microbial cultures were taken and an antibiogram was performed. The microbiological examination was negative. On the 3<sup>rd</sup> day the cultures from the latero-cervical secretions became positive for *Serratia*.

Paraclinical examination using imaging studies of the cervical and thorax regions revealed consistent collection surrounding the pharynx and the prevertebral space. The pharynx cavity had a reduced asymmetrical lumen. The subcutaneous tissue was infiltrated with extensive edema. Multiple lymph nodes were visible on the left submandibular space with diameters up to 15 mm. Left submandibular gland was infiltrated. The native and contrast thorax CT revealed normally expanded lungs, no spontaneous visible focal lesions or post intravenous contrast, no pleural collections or effusions, and no mediastinal adenopathy of pathological dimensions. The CT diagnosis was possible and revealed parapharynx and submental phlegmon (Figure 4).



**Figure 4.** CT cross-sections of the neck region showing the extension of the neck deep space collection.

During hospitalization, the patient developed acute kidney failure, and therefore nephrology emergency examination was required. Emergency dialysis in the ER was decided 3 days after admission in the ENT Department.

On the 2<sup>nd</sup> day of hospitalization the patient developed suppurated otitis, with the secretion being harvested for culture. Microbiological examination by seriated cultures revealed the presence of *Enterococcus faecium*, sensible to vancomycin and linezolid. On the 3<sup>rd</sup> day the secretions harvested the previous days from the necrotic tissue became positive for *Serratia*, sensible to colistin and amikacin.

Based on the microbiological results, antibiotic treatment was modified with specific antibiotic agents, colistin and vancomycin being used along with

metronidazol. Antipyretics and treatments for diabetes, kidney failure, and bronchitis were administered.

On the 4<sup>th</sup> day the patient's biological status improved and the patient's clinical profile was stable. However, on the 5<sup>th</sup> day the patient's biological and chemical status worsened, with high blood glucose levels, high creatinine and urea levels, and ionic imbalance. On the 6<sup>th</sup> day the patient was transferred to the nephrology department for dialysis. The patient's respiratory, heart, and kidney functions deteriorated continuously and the patient was transferred to the intensive therapy unit with MSOF (multisystem organ failure). The patient underwent two more dialysis sessions in the intensive therapy unit but with no favorable result. Death occurred on the 11<sup>th</sup> day of hospitalization due to kidney failure, septicemia, and MSOF, complications mostly due to the unbalanced and non-responsive diabetes mellitus.

## Discussion

Due to the anatomical complexity of the cervical area, deep space infections frequently represent a challenge for the ENT specialist. Cervical fasciitis is a serious complication with 20-30% mortality, which appears in elderly and immunology-depressed persons. It evolves extremely rapidly as a cervical cellulite, and death may occur in 24 to 96 hours (6, 7). The skin appears like an orange peel as a result of lymphatic drainage blockage and the presence of air trapped beneath the skin, causing crepitations. Antibiotic therapy needs to be targeted by using specific agents following an antibiogram, this being considered a priority of the therapy management. At admission the patient received broad spectrum antibiotic therapy. Pathogenesis and clinical manifestations are important to differentiate between different pathogens involved in the development of the localized infection (8).

The removal of dead necrotic tissue, consisting of friable gray tissue, and brownish, watery, odorous secretions, is the most important part of the therapy management. If the site of infection or necrotic tissue is significant, the local and general status of the organism is impaired and the prognosis worsens. The wound is left open so that seriated debridement and washing can be performed daily. After healing, plastic surgery may be needed. In our case the patient had a rapid and violent deterioration, even though surgery was performed and broad spectrum antibiotics were administered immediately. Specific therapy was later administered according to the antibiogram (9). In our case, it appeared that the complications of diabetes led to patient immunology suppression and kidney failure, septicemia, and MSOF.

Even though surgical and medical treatment were urgently performed by a multidisciplinary medical team representing ENT- Diabetology- Nephrology- Internal Medicine-Radiology, the evolution was unfavorable, due primarily to unbalanced diabetes and late complications.

## Conclusions

Deep space neck infections occur more frequently in adults and only rarely in children. Also, the immunosuppressed elderly population is vulnerable as well as patients with unbalanced diabetes mellitus. To develop an individualized clinical and therapeutic approach for those presenting with deep neck infections, we emphasize the importance of a multidisciplinary team in the therapeutic management of these patients.

Early stage peritonsillar abscesses can be resolved with antibiotics without surgery in 5-7% of the cases. Some 80-90% of cases need to receive surgery therapy by trans-oral incision and drainage. In 3% of the cases the abscess located in the palatine tonsil fossa can spread to the deep neck spaces and mediastinum, worsening the

prognosis and frequently leading to the death of the patient.

## References

1. Cortese A, Pantaleo G, Borri A, Amato M, Claudio PP. Necrotizing odontogenic fasciitis of head and neck extending to anterior mediastinum in elderly patients: innovative treatment with a review of the literature. *Aging Clin Exp Res.* 2017; 29(Suppl 1): 159-65. PMID: 27798811, DOI: 10.1007/s40520-016-0650-2
2. Freischlag JA, Ajalat G, Busuttil RW. Treatment of necrotizing soft tissue infections. The need for a new approach. *Am J Surg.* 1985; 149(6): 751-5. PMID: 4014552
3. Brook I, Frazier EH. Clinical and microbiological features of necrotizing fasciitis. *J Clin Microbiol.* 1995; 33(9): 2382-7. PMID: 7494032
4. Cunningham MW. Pathogenesis of group A streptococcal infections. *Clin Microbiol Rev.* 2000; 13(3): 470-511. PMID: 10885988
5. Muhammad JK, Almadani H, Al Hashemi BA, Liaqat M. The value of early intervention and a multidisciplinary approach in the management of necrotizing fasciitis of the neck and anterior mediastinum of odontogenic origin. *J Oral Maxillofac Surg.* 2015; 73(5): 918-27. PMID: 25795188, DOI: 10.1016/j.joms.2014.12.021
6. Cruz Toro P, Callejo Castillo À, TorneroSaltó J, González Compta X, Farré A, Maños M. Cervical necrotizing fasciitis: report of 6 cases and review of literature. *Eur Ann Otorhinolaryngol Head Neck Dis.* 2014; 131(6): 357-9. PMID: 25002374, DOI: 10.1016/j.anorl.2013.08.006
7. Suárez A, Vicente M, Tomás JA, Floría LM, Delhom J, Baquero MC. Cervical necrotizing fasciitis of nonodontogenic origin: case report and review of literature. *Am J Emerg Med.* 2014; 32(11): 1441.e5-6. PMID: 24919774, DOI: 10.1016/j.ajem.2014.04.018
8. Sarna T, Sengupta T, Miloro M, Kolokythas A. Cervical necrotizing fasciitis with descending mediastinitis: literature review and case report. *J Oral Maxillofac Surg.* 2012; 70(6): 1342-50. PMID: 21820786, DOI: 10.1016/j.joms.2011.05.007
9. Dumitrache MA, Ionescu E, Sfeatcu R, Ginghina O, Burcea Dragomiroiu GTA, Petre A. The pharmacist's role in preventive and pharmaceutical treatment for oral diseases. *Farmacia.* 2016; 64(6): 966-969.