

## Penile Metastasis from Adenocarcinoma of the Prostate in a Patient with Colorectal Carcinoma

Bulent Yildiz<sup>1</sup>, Evren Fidan<sup>1</sup>, Kadriye Yildiz<sup>2</sup>, Fazil Aydin<sup>1</sup>

<sup>1</sup>Department of Medical Oncology, <sup>2</sup>Department of Pathology, Faculty of Medicine, Karadeniz Technical University, Trabzon, Turkey

### Corresponding author:

Bulent Yildiz, MD  
Department of Medical Oncology  
Faculty of Medicine  
Karadeniz Technical University  
61080 Trabzon  
Turkey  
[drbulentyildiz@hotmail.com](mailto:drbulentyildiz@hotmail.com)

Received: March 26, 2010  
Accepted: February 1, 2011.

**SUMMARY** Skin metastasis secondary to cancer of the prostate is rare and the prognosis is poor. A 65-year-old male patient diagnosed with metastatic colon carcinoma presented with polyuria and subcutaneous nodular mass on dorsal side of the corpus penis. The serum prostate specific antigen (PSA) level was 111.1 ng/mL and therefore the patient underwent transperineal prostate biopsy. Pathology reported adenocarcinoma of the prostate. The subcutaneous nodular lesion on the penis was totally excised and removed. Immunohistochemical examination of the excised mass was carcinoembryonic antigen (CEA) negative and PSA positive. Taking all these findings into consideration, the patient was diagnosed with prostate cancer that had metastasized to the penis. FOLFOX-4 chemotherapy regime in addition to bicalutamide and goserelin acetate was administered to the patient who also had metastatic colon cancer.

**KEY WORDS:** colorectal neoplasm, prostatic neoplasm, neoplasm metastasis, penis, skin

### INTRODUCTION

According to 2008 data in USA, when skin cancers are excluded, the prostate cancer prevalence is 25% of newly diagnosed cancer cases, and it is the most common cancer in men (1). Prostate cancer accounts of 10% of cancer related mortality; it is the second most common cancer after lung cancer (1). The most common sites of prostate carcinoma metastases are bone and lymph nodes. Skin metastases are very rare, presented in the literature with case reports.

### CASE HISTORY

A 65-year-old male patient was hospitalized for complaints of fatigue, weight loss and lower gastrointestinal bleeding. There was no other disease (e.g., diabetes mellitus, chronic heart or renal failure) in his

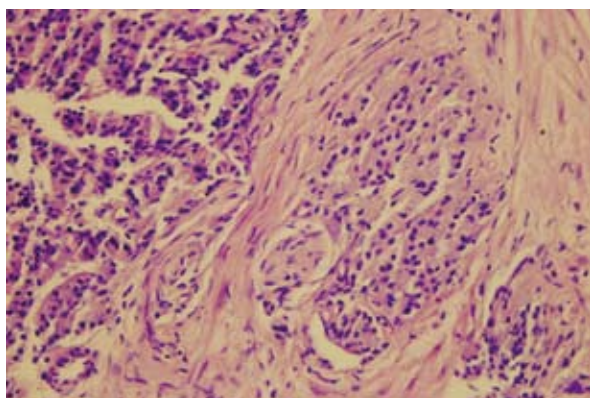
medical history. A mass in the colon was detected with colonoscopy. The result of colonoscopic biopsy was reported as adenocarcinoma of the colon. One week later, the patient developed frequent urination again and a nodule on the dorsal part of the penile corpus while planning thorax and abdominal computed tomography (CT) to detect the metastasis. The patient's hematologic parameters, liver and renal function tests were in the normal range. Serum prostate specific antigen (PSA) level was 111.1 ng/mL. A subcutaneous nodular lesion of 3x1.5 cm in diameter was detected on the dorsum of the penile corpus. Transperineal prostate biopsy was performed simultaneously with total excision of the penile mass. Prostate biopsy report indicated perineural invasion-posi-

tive adenocarcinoma of the prostate (Gleason's score, 8) (Fig. 1). Since immunohistochemical examination of the mass on the penile dorsum revealed carcino-embryonic antigen (CEA)-negative (Fig. 2) and PSA-positive (Fig. 3) staining, it was regarded as a metastasis of adenocarcinoma of the prostate. In addition, in some areas tumoral microemboli were detected in vascular structures (Fig. 4). Multiple metastases were detected in the liver with abdominal CT. Bicalutamide 50 mg/day plus goserelin acetate 3.6 mg/month in addition to 5-fluorouracil/leucovorin plus oxaliplatin (FOLFOX-4) chemotherapy regime was administered to the patient who had metastatic colon and prostate cancer. However, progression was observed in spite of therapy and the patient died 3 months later.

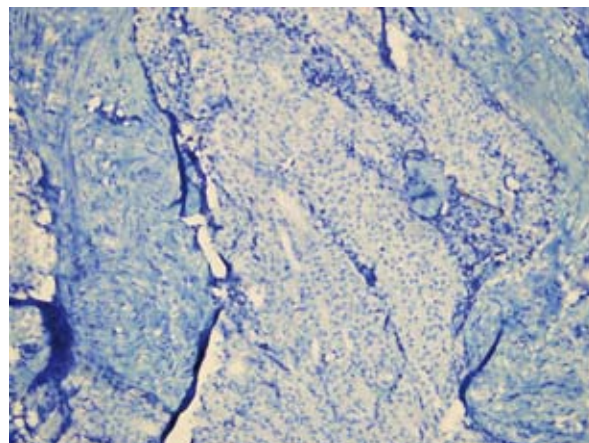
### DISCUSSION

Skin metastases secondary to solid organ malignancies are rare. In a meta-analysis of seven large studies involving 20,380 patients, skin metastases were found in 5.3% of cases. The most frequent malignancy that causes skin metastases is breast cancer with an incidence of 24%, whereas prostate carcinoma is the one having the least percent of metastases with an incidence of 0.7% (2). Skin metastases originating from prostate carcinoma are usually found in the inguinal region and on the penis, but also in abdominal region, head and neck, chest, extremities and dorsal areas, in decreasing order of frequency (3). Clinically, skin lesions manifest as single or multiple nodules, edema, rash, priapism, painful erection and dysuria symptoms (3,4). In our patient, metastatic lesion was identified as a single, painless nodule on the dorsum of the penis.

Metastases to the penis mainly originate from genitourinary system cancers (69%), followed by gastrointestinal system cancers (19%). Prostatic carcinoma



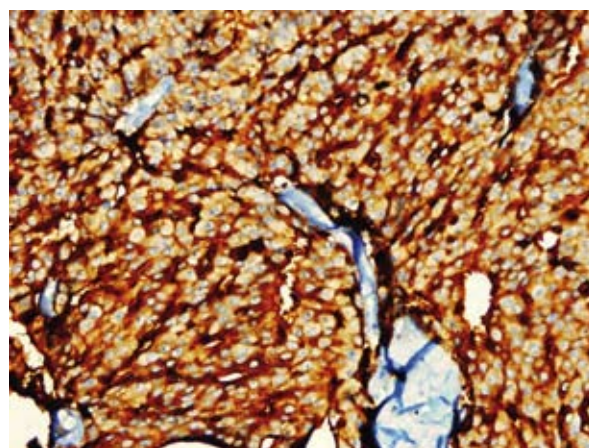
**Figure 1.** Perineural invasion positive prostatic adenocarcinoma (HE; x400).



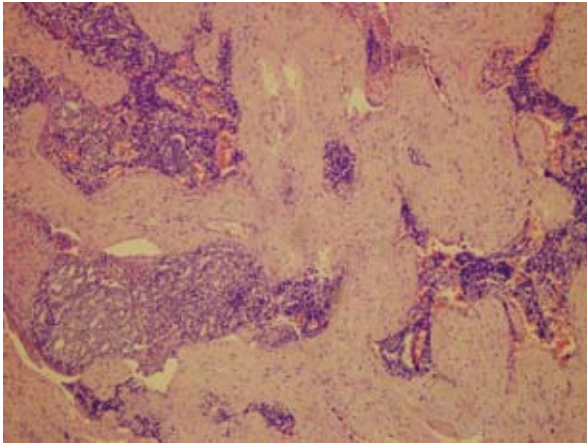
**Figure 2.** CEA-negative immunohistochemical staining of the penile mass (CEA; x200).

ma is responsible for 25% of cases (4). Immunohistochemical examination of skin metastases secondary to gastrointestinal system cancers shows CEA-positive staining, whereas metastases secondary to carcinoma of the prostate show PSA-positive staining (3-5). In our case, immunohistochemical examination indicated CEA-negative and PSA-positive staining. These findings supported our diagnosis of penile metastasis secondary to carcinoma of the prostate.

The probable mechanisms underlying skin metastasis of prostate cancer are hematogenous spreading, lymphatic spreading and direct invasion (3,4). The presence of tumoral emboli in vascular structures in some areas of the pathological specimen obtained from the mass excised from the skin of the penis suggested that this metastasis had followed the hematogenous pathway.



**Figure 3.** PSA-positive immunohistochemical staining of the penile mass (PSA; x400).



**Figure 4.** Vascular invasion positive carcinoma metastasizing to the penis (HE; x 100)

No correlation between PSA level and penile metastasis from prostate cancer has been reported in the literature to date. In most cases, PSA levels were elevated as in our patient (3,6-10). However, Kotake *et al.* and Kobashi-Katoh *et al.* report on patients that had not elevated PSA level at the time of penile metastasis detection (4,11). However, these patients were taking hormonal therapy at that time. Therefore, PSA levels might not be elevated.

Prostate cancer with skin metastases have poor prognosis. The mean survival is 6-7 months (3,6). There is no standard treatment for these patients and individual treatment schemes need to be developed. Therapy should be chosen according to patient performance and symptoms, site and number of metastatic lesions. Treatment options are chemotherapy, hormonal therapy, radiotherapy, total excision of the lesion, and total or partial penectomy (3,6). Since our patient had a subcutaneous solitary nodule, we preferred total excision of the mass followed by hormonal therapy.

Finally, it should be noted that penile metastases mainly originate from genitourinary system cancer, especially adenocarcinoma of the prostate.

## References

1. Jemal A, Siegel R, Ward E, Hao Y, Xu J, Murray T, *et al.* Cancer statistics, 2008. *CA Cancer J Clin* 2008;58:71-96.
2. Krathen RA, Orengo IF, Rosen T. Cutaneous metastasis: a meta-analysis of data. *South Med J* 2003;96:164-7.
3. Wang SQ, Mecca PS, Myskowski PL, Slovin SF. Scrotal and penile papules and plaques as the initial manifestation of a cutaneous metastasis of adenocarcinoma of the prostate: case report and review of the literature. *J Cutan Pathol* 2008;35:681-4.
4. Kotake Y, Gohji K, Suzuki T, Watsuji T, Kusaka M, Takahara K, *et al.* Metastases to the penis from carcinoma of the prostate. *Int J Urol* 2001;8:83-6.
5. Murhekar KM, Majhi U, Mahajan V, Satheesan B. Penile metastasis from rectal carcinoma. *Indian J Cancer* 2007;44:155-6.
6. Philip J, Mathew J. Penile metastasis of prostatic adenocarcinoma: report of two cases and review of literature. *World J Surg Oncol* 2003;1:16.
7. Senkul T, Karademir K, Silit E, Işeri C, Erden D, Baloğlu H. Penile metastasis of prostatic adenocarcinoma. *Int J Urol* 2002;10:597-8.
8. Cortés González JR, Garza R, Martínez R, Gómez L. Prostate adenocarcinoma metastatic to penis. *Actas Urol Esp* 2006;8:832-4.
9. Sawada A, Segawa T, Nakanishi S, Kinoshita H, Yamamoto S, Kamoto T, *et al.* Prostate cancer with penile metastasis: a case report. *Hinyokika Kyo* 2005;11:771-3.
10. Sciarra A, D'Eramo G, Casale P, Di Nicola S, Di Chiro C, De Santis C, *et al.* Penile metastasis from carcinoma of the prostate in a patient with high serum prostate specific antigen levels. *Minerva Urol Nefrol* 1999;3:157-8.
11. Kobashi-Katoh R, Tanioka M, Takahashi K, Miyachi Y. Skin metastasis of prostate adenocarcinoma to glans penis showing no correlation with serum prostate-specific antigen level. *J Dermatol* 2009;2:106-8.